



# A Fatal and Rare Case of Hydatid Cyst in the Pouch of Douglas

Ritu Asnani<sup>1</sup> Sunil Kumar Yeshvanth<sup>1</sup> Lancelot Lobo<sup>2</sup> Shipra Sonkusare<sup>3</sup>

<sup>1</sup>Department of Pathology, K. S. Hegde Medical Academy, Mangalore, Karnataka, India

<sup>2</sup>Department of Surgery, K. S. Hegde Medical Academy, Mangalore, Karnataka, India

<sup>3</sup>Department of Obstetrics and Gynaecology, K. S. Hegde Medical Academy, Mangalore, Karnataka, India

**Address for correspondence** Ritu Asnani, MBBS, Department of Pathology, K. S. Hegde Medical Academy, P.O. Deralakatte, Mangalore, Karnataka 575018, India (e-mail: ritu.asnani111@gmail.com).

J Lab Physicians 2021;13:77–79.

## Abstract

Hydatid cyst is a zoonotic infection and a significant public health problem in low- and middle-income countries. A 79-year-old female patient was presented to the gynecology outpatient department with complaints of pain in the abdomen and difficulty in micturition, with a mass palpable per speculum. The ultrasound was suggestive of an ovarian cystadenocarcinoma, whereas computed tomography of the abdomen favored hydatid cyst with adnexal neoplasm as a differential diagnosis. Considering the contradictory findings, a frozen section was sent to confirm the diagnosis, which showed hooklets of *Echinococcus granulosus*/hydatid cyst under the microscope. This was a rare case of pelvic hydatid cyst mimicking ovarian malignancy and was associated with a less-preferred mode of investigation (frozen section). This article focuses on how a frozen section, despite its limitations and being expensive, can still be considered for accurate patient management.

## Keywords

- ▶ frozen section
- ▶ hydatid cyst
- ▶ ovarian adenocarcinoma
- ▶ zoonotic

## Introduction

Cystic echinococcosis/hydatid cyst is a tropical disease and a significant public health problem, especially in low- and middle-income countries.<sup>1</sup> It is a parasitic disease caused by (infective stage) the larval stage (metacestode) of *Echinococcus granulosus*.<sup>2</sup> It's a zoonotic infection occurring in different parts of the world. This parasite lives in the intestine of dogs, wild canines, and carnivorous animals, which are the definitive hosts, whereas sheep, cattle, goats, pigs, and humans are the intermediate hosts. Once ingested, the larvae pass into the bloodstream through the intestinal mucosa and develop into slow-growing hydatid cysts containing many thousands of protoscolices that form daughter cysts.<sup>3</sup> Although cyst formation can occur in any part of the human body, the most common location is the liver, followed by lungs. Three-fourths of infected individuals

develop one or more hepatic cysts, which grow slowly. The majority occur in the right lobe, but they may be multiple, involving all lobes.<sup>4</sup> Rarely, cysts were found in various other locations such as lumbar spine, seminal vesicles, mediastinum, kidney, breast, and chest wall.<sup>1</sup> We present a case of hydatid cyst in the pouch of Douglas (POD) mimicking an ovarian tumor.

## Case Report

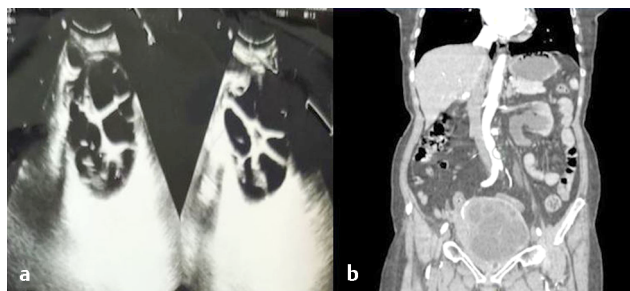A 79-year-old female presented to the gynecology outpatient department of our hospital with complaints of burning sensation and pain in the abdomen for 4 days, along with decreased frequency of micturition. Clinical examination showed a scaphoid abdomen with umbilical hernia. Per speculum examination showed the cervix pushed

**published online**  
May 19, 2021

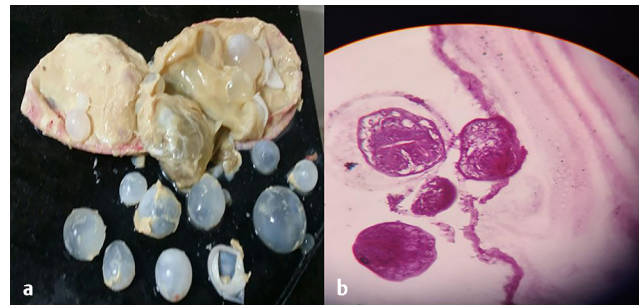
**DOI** <https://doi.org/10.1055/s-0041-1726668>  
**ISSN** 0974-2727.

©2021. The Indian Association of Laboratory Physicians.  
This is an open access article published by Thieme under the terms of the Creative Commons Attribution-NonDerivative-NonCommercial-License, permitting copying and reproduction so long as the original work is given appropriate credit. Contents may not be used for commercial purposes, or adapted, remixed, transformed or built upon. (<https://creativecommons.org/licenses/by-nc-nd/4.0/>).  
Thieme Medical and Scientific Publishers Pvt. Ltd. A-12, 2nd Floor, Sector 2, Noida-201301 UP, India

anteriorly and the uterus of 12 to 14 weeks' size. Per vaginum, a hard mass was felt in the posterior fornix, which was immobile and not felt separately from the uterus. On rectal examination, the same mass was felt and the mucosa was free. Normal breath sounds were heard on auscultation. Ultrasound (USG) showed features highly suggestive of ovarian cystadenocarcinoma and gross hydronephrosis (►Fig. 1a). Contrast-enhanced computed tomography (CT) of the abdomen and pelvis showed a well-defined thin-walled cystic lesion with multiple internal septations in the POD, maintaining fat planes (►Fig. 1b). Calcification was noted along the wall and septations of the lesion. Both ovaries were indistinct. Features were suggestive of a hydatid cyst, with differential diagnosis as adnexal neoplasm. Also noted was a caudate lobe liver calcified lesion, suggestive of a calcified hydatid cyst, and right renal and ureteric calculus with bilateral hydronephrosis likely secondary to the pelvic lesion. Blood parameters showed electrolyte disturbances with high serum creatinine (4.62 mg/dL) and deranged liver function tests (total protein: 4.3; albumin: 2.1; albumin/globulin ratio: 0.95). Leucocyte count was 14,100 cells/cumm (neutrophilia) with thrombocytopenia (53,000 cells/cumm) and low hemoglobin (10.7 mg/dL). Erythrocyte sedimentation rate was 40 mm/hour, and the LDH was very high (1,911 U/L). Peripheral smear showed leucoerythroblastic anemia and thrombocytopenia. An exploratory laparotomy showed a well-defined cystic lesion in POD (►Fig. 2a) adherent to the posterior wall of the uterus, left fallopian tube and ovary, anterior surface of the rectum, and sigmoid colon. Another cystic lesion was noted arising from the caudate liver lobe. Frozen section showed a cystic mass measuring 12 × 12 × 8 cm (►Fig. 2a). Cut surface exuded clear serous fluid and showed multiloculated grape-like cysts with pultaceous material in the inner cyst wall. Microscopy showed the cyst wall having thick fibrocollagenous tissue, laminated membranous tissue, and plenty of scolices with hooklets of *Echinococcus granulosus* (►Fig. 2b), which was confirmed with histopathology. Postoperatively, the patient's condition deteriorated and she later died, with the antecedent cause of death being extensive hydatid disease of the liver and abdominal cavity, anaphylactic shock, sepsis, metabolic acidosis, age, and poor performance.



**Fig. 1** (a) Ultrasound of the pelvis showing complex cystic lesion posterior to the bladder, likely arising from the left adnexa. (b) Computed tomography of the pelvis showing multiloculated cystic lesion in the pouch of Douglas, displacing the pelvic structures with bilateral hydronephrosis.



**Fig. 2** (a) Gross specimen of cystic mass received for frozen section with cut surface exuding clear serous fluid and showing multiloculated grape-like cysts seen with pultaceous material in the inner cyst wall. (b) Microscopy showed scolices with hooklets of *Echinococcus granulosus* and a laminated eosinophilic cyst wall.

## Discussion

Hydatid cyst, being a parasitic infection, has been known to affect all age groups and for a long duration. An association of sex showed males exhibiting lung infection in a higher proportion than females, whereas liver infection was seen to be more common in females. The metacestode (larva) develops in the body of the primary host into an adult tapeworm and releases eggs. Due to ingestion of contaminated food/direct contact with infected dogs, humans become the intermediate carriers. The parasite enters liver through the portal vein and mostly affects the right lobe.<sup>4</sup> The most common cause of hydatid cyst is *Echinococcus granulosus*, whereas other types of parasites causing hydatid cysts are *Echinococcus multilocularis* (more aggressive), causing alveolar hydatid cyst, and *Echinococcus vogeli* and *Echinococcus oliganthus*, causing polycystic hydatid cyst.<sup>4,5</sup>

Most hydatid cysts present with abdominal pain, nausea, and jaundice, considering that liver is the most common site (59–75%).<sup>6</sup> A few patients have presented with a slow-growing occipitocervical mass, a painful mass growing in the left lateral side of the neck, and left gluteal pain and limb weakness, for a cyst in the cervical region,<sup>7</sup> the supraclavicular region,<sup>8</sup> and in the left deep gluteal muscle,<sup>9</sup> respectively. These are the rare presentations of hydatid cyst that have been reported. Our case was unique considering the age of the patient (79 years) and coming from a nonendemic area (for hydatid cyst), presenting with obstructive uropathy and mimicking ovarian carcinoma on USG and CT. A diagnosis of hydatid cyst in this situation was unlikely. Other rare sites include kidney (3%), musculoskeletal system (1–4%), brain (1–2%), and pelvis (0.2–2.5%).<sup>6,10–12</sup> Pelvic hydatid cysts can present as obstructive uropathy, infertility, and irregular menses, and can be either primary or secondary. Primary hydatid cysts can be further rare and are seen when a primary cyst undergoes rupture and spontaneous resolution, but the contents can enter circulation and lead to another cyst, which is now called the primary cyst.<sup>13</sup> In case of a secondary cyst, on the other hand, the mechanism remains the same except that the primary cyst is not completely resolved.

The diagnosis of a hydatid cyst mainly involves USG, CT, and serology. Fine-needle aspiration cytology and biopsy are not recommended due to the risk of rupture. When the findings of USG and CT are compared, CT is preferred and considered superior.<sup>14</sup> Among USGs, transvaginal USG carries weightage because hydatid cyst features, such as the cystic lesion and fluctuating membrane, are clearly visible.<sup>15</sup>

The microscopy of a hydatid cyst shows two layers: an outer chitinous/fibrous layer and an inner germinal layer. The chitinous layer is surrounded by a pericyst made of granulation tissue arising as a result of inflammation due to host response. Surrounding areas may show features such as pressure atrophy, inflammatory infiltrate, and prominent eosinophils.<sup>4</sup>

The treatment of cystic echinococcosis involves surgical excision and antihelminthic drugs. En bloc excision of the cyst without rupture is considered a curative treatment, whereas in the case of adhesion, partial cystectomy is performed.<sup>16</sup> According to the World Health Organization, post-surgery albendazole must be given in case of rupture/residual disease.<sup>17</sup> Recurrence rate is mere 2% after a successful treatment.<sup>18</sup> In case of a complicated or asymptomatic hydatid cyst, only antihelminthic drugs can be given because of their property to decrease the cyst size and tension and to induce calcification.<sup>19,20</sup>

## Conclusion

This is a rare case of pelvic hydatid cyst mimicking ovarian malignancy, which was diagnosed by a less-preferred mode of investigation, that is, frozen section. This helped avoiding a major radical surgery for the patient, since the USG and CT gave contradictory findings. Hence, despite the limitations and the high cost of frozen section, it can be a useful diagnostic procedure for accurate management of a patient.

### Conflict of Interest

None declared.

## References

- 1 Butt A, Khan JA. Cystic echinococcosis: a 10-year experience from a middle-income country. *Trop Doct* 2020;50(2):117–121
- 2 Yuksel M, Demirpolat G, Sever A, Bakaris S, Bulbuloglu E, Elmas N. Hydatid disease involving some rare locations in the body: a pictorial essay. *Korean J Radiol* 2007;8(6):531–540

- 3 Kapatia G, Tom JP, Rohilla M, et al. The clinical and cytomorphological spectrum of hydatid disease. *Diagn Cytopathol* 2020;48(6):547–553
- 4 Lamps LW. Liver: non neoplastic diseases. In: Rosai and Ackerman's Surgical Pathology. 11th ed. Philadelphia, PA: Elsevier; 2018: 726–785
- 5 Perigela HC, Reddy MK, Prasad BV, Narahari J. Giant pelvic hydatid cyst. *J Dr NTR Univ Health Sci* 2013;2:218–221
- 6 Sarkar S, Sanyal P, Das MK, Kumar S, Panja S. Acute urinary retention due to primary pelvic hydatid cyst: a rare case report and literature review. *J Clin Diagn Res* 2016;10(4):PD06–PD08
- 7 Sultana N, Hashim TK, Jan SY, Khan Z, Malik T, Shah W. Primary cervical hydatid cyst: a rare occurrence. *Diagn Pathol* 2012;7:157
- 8 Jarbouy S, Hlel A, Daghfous A, Bakkey MA, Sboui I. Unusual location of primary hydatid cyst: soft tissue mass in the supraclavicular region of the neck. *Case Rep Med* 2012;2012:484638
- 9 Seyedsadeghi M, Ghobadi J, Haghshenas N, Habibzadeh A. Gluteal hydatid cyst: a case report. *Iran J Parasitol* 2019;14(3):487–491
- 10 Parray FQ, Wani SN, Bazaz S, Khan SU, Malik NS. Primary pelvic hydatid cyst: a case report. *Case Rep Surg* 2011;2011:809387
- 11 Sharma A, Sengupta P, Mondal S, Raychaudhuri G. Hydatid cyst of ovary mimicking ovarian neoplasm with its imprint cytology. *Am J Case Rep* 2012;13:276–278
- 12 Kumar S, Chandna A, Manoharan V, Parmar KM, Mandal S. Conquering new battlegrounds: successful management of isolated giant retrovesical hydatid cyst with robotic assistance. *Asian J Urol* 2019 (e-pub ahead of print): doi:10.1016/j.ajur.2019.12.006
- 13 Bhattacharjee PK, Halder SK, Chakraborty S, Mukerjee A, Singh R. Pelvic hydatid cyst: a rare case report. *J Med Sci* 2015;35(3):122–124
- 14 Arora BB, Maheshwari M, Devgan N, Arora DR. Hydatid cyst of the ovary: a case report. *JMM Case Rep* 2015;2(4):e000042
- 15 Cattorini L, Trastulli S, Milani D, et al. Ovarian hydatid cyst: a case report. *Int J Surg Case Rep* 2011;2(6):100–102
- 16 Shahi KS, Bhandari G, Gupta RK, Kashmira M. Pelvic hydatid disease mimicking ovarian cyst. *J Med Soc* 2015;29:177–179
- 17 WHO Informal Working Group on Echinococcosis. Guidelines for treatment of cystic and alveolar echinococcosis in humans. *Bull World Health Organ* 1996;74(3):231–242
- 18 Mehra BR, Thawait AP, Gupta DO, Narang RR. Giant abdominal hydatid cyst masquerading as ovarian malignancy. *Singapore Med J* 2007;48(11):e284–e286
- 19 Seenu V, Misra MC, Tiwari SC, Jain R, Chandrashekhar C. Primary pelvic hydatid cyst presenting with obstructive uropathy and renal failure. *Postgrad Med J* 1994;70(830):930–932
- 20 Katsamagkas T, Tsakiridis I, Evaggelinos D, Skafida P, Dagklis T, Kalogiannidis I. Primary ovarian hydatid cyst in a postmenopausal woman: a rare case report. *Int J Surg Case Rep* 2020;68:221–223