

# Fenton Syndrome: Diagnosis and Treatment with 3D-Printed Models. An Unusual Case Report

## *Síndrome de Fenton: diagnóstico y tratamiento con modelos de impresión 3D. Reporte de un caso inusual*

José Luis Muñoz Sánchez<sup>1</sup> Vladimir Jorge Carrasco<sup>1</sup> Pedro Zorrilla Ribot<sup>1</sup>

<sup>1</sup> Orthopedic Surgery and Traumatology Department, Hospital General Universitario Ciudad Real, Ciudad Real, Spain

Address for correspondence: José Luis Muñoz Sánchez, Calle Obispo Rafael Torija s/n, 13005, Ciudad Real, España  
(e-mail: jmunozsanchez@sescam.jccm.es).

Rev Iberam Cir Mano 2021;49:66–73.

### Abstract

#### Keywords

- Fenton syndrome
- scaphocapitate
- trans-scapholunate
- carpus
- fracture
- dislocation

### Resumen

#### Palabras clave

- síndrome de Fenton
- escafocapitado
- transescafolunar
- carpo
- fractura
- luxación

Scaphocapitate syndrome, also called Fenton syndrome, is a rare, complex condition. Since it is often missed on initial evaluation, it is a diagnostic challenge. A high index of suspicion is required for early surgical treatment, avoiding future palliative surgery or sequelae. Cutting-edge diagnostic technologies, including three-dimensional printed models, are becoming essential tools, enabling the treatment of complex trans-scaphocapitate fracture-dislocations using open reduction and internal fixation with screws, with excellent outcomes at a 12-month follow-up period.

El síndrome escafocapitado, o síndrome de Fenton, es una entidad compleja y muy poco frecuente, que suele pasar desapercibida en su primera atención, por lo que supone un reto diagnóstico. Una alta sospecha es necesaria para llevar a cabo un tratamiento quirúrgico temprano que evite complicaciones futuras, así como cirugías paliativas o de secuelas. La utilización de tecnologías diagnósticas punteras se convierte cada vez más en una herramienta imprescindible, como es la impresión de modelos 3D, que nos ha permitido tratar mediante reducción abierta y fijación interna con minitornillos una compleja fractura-luxación transescafo-hueso grande, obteniendo excelente resultado a los 12 meses de seguimiento.

### Introduction

Perilunate fractures-dislocations at the wrist represent a broad spectrum of complex carpal injuries. They are relatively rare, accounting for approximately 7% of all carpal injuries.<sup>1</sup> Most of these injuries result from high-energy trauma, including motor vehicle accidents, bicycle falls, falls from height, or contact

sports. A particular pattern of these injuries associates a scaphoid fracture to a capitate bone fracture, and it is known as Fenton syndrome, trans-scaphocapitate fracture-dislocation, or scaphocapitate syndrome. This rare, complex wrist injury (accounting for 1–2% of carpal fractures) was first described in 1937 by Perves et al,<sup>2</sup> but it was named Fenton

received  
June 30, 2020  
accepted  
December 21, 2020

DOI <https://doi.org/10.1055/s-0041-1730000>.  
ISSN 1698-8396.

© 2021. SECMA Foundation. All rights reserved.  
This is an open access article published by Thieme under the terms of the Creative Commons Attribution-NonDerivative-NonCommercial-License, permitting copying and reproduction so long as the original work is given appropriate credit. Contents may not be used for commercial purposes, or adapted, remixed, transformed or built upon. (<https://creativecommons.org/licenses/by-nc-nd/4.0/>)  
Thieme Revinter Publicações Ltda., Rua do Matoso 170, Rio de Janeiro, RJ, CEP 20270-135, Brazil

syndrome after the author who described 2 cases in 1956.<sup>3</sup> This injury is important not only because of its difficult diagnosis but also for its treatment, since it is essential to regain range of motion and minimize pain to avoid devastating future complications trans-scaphocapitate fracture-dislocation.

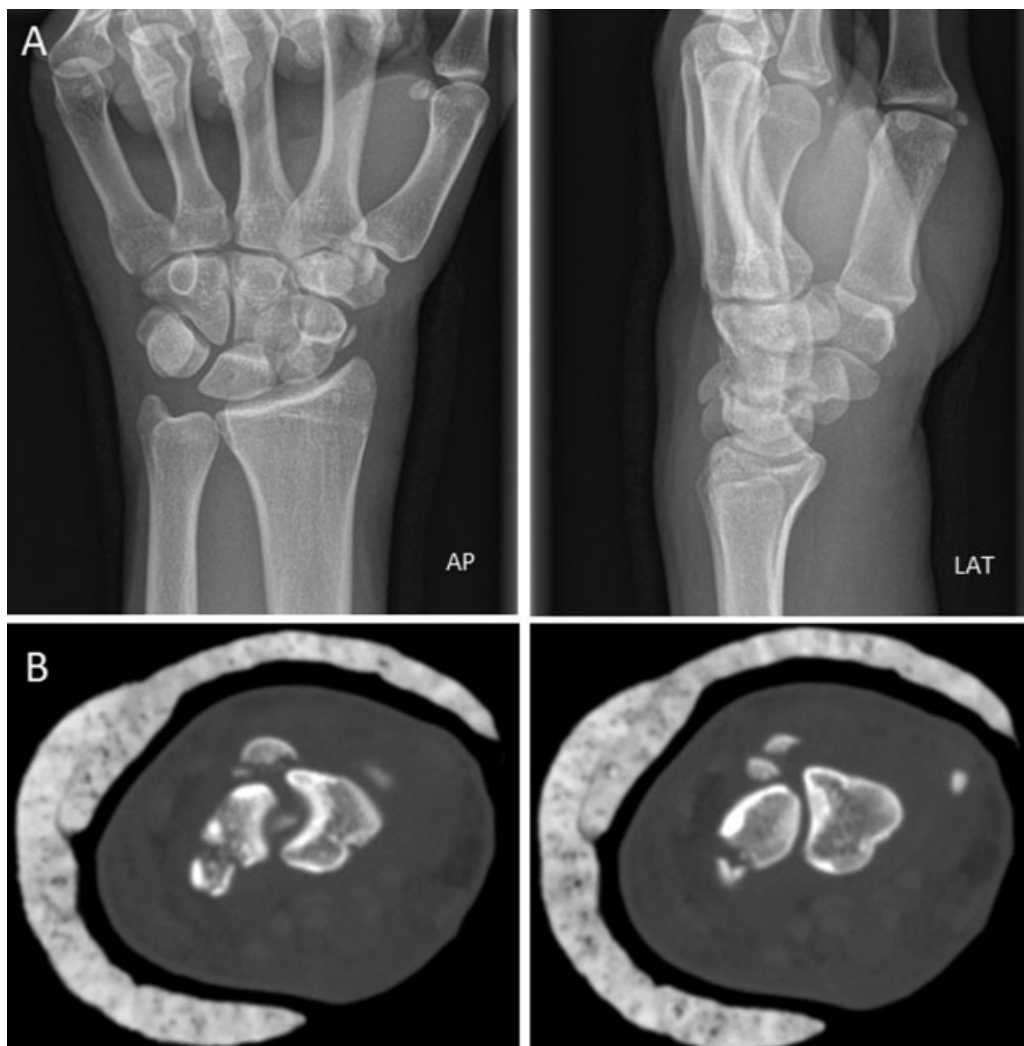The classic method for Fenton syndrome diagnosis includes posteroanterior, lateral and oblique radiographs, potentially complemented with a computed tomography (CT) scan. Even so, the diagnosis can still be difficult due to several causes, such as poor radiological technique, carpal anatomy, and multiple bone fractures, displacement or comminution, which result in uncertainty, insecurity and discordant opinions on the treatment to be carried out. Therefore, new technologies are critical for allowing us to establish the fracture type and to print of a full-scale three-dimensional (3D) model, which is the simplest method to understand the mechanism of injury, diagnose with certainty, and plan surgical procedures with a very high degree of anatomical correlation, since the current therapeutic trend is open reduction with internal fixation.

Here, we report an unusual case of trans-scaphocapitate fracture-dislocation, with displacement and multiple frag-

ments, and also show a novel diagnostic technique for meticulous presurgical planning, a 3D-printed model which helped us to understand and treat this injury in a safe and successful manner.

### Clinical Case

A 17-year-old male went to the emergency room after falling from a bicycle and sustaining direct trauma to the left wrist, with hyperextension and axial compression as a potential lesion mechanism. A physical examination revealed dorsal swelling, pain, and functional disability but no distal neurovascular findings. The posteroanterior and lateral wrist radiographs (►Figure 1A) showed a scaphoid fracture and a complex capitate fracture with two dorsal bone fragments. Due to difficulties in image interpretation, an emergency computed tomography (CT) scan (►Figure 1B) was requested. The CT scan reported “a multiple line fracture at the proximal pole of the scaphoid bone with preserved joint congruence with the trapezium, trapezoid and capitate bones. The distal segment presents a volar angulation. Two bone fragments are observed dorsal to the scaphoid and lunate



**Fig. 1** (A and B) (A) Initial posteroanterior and lateral radiographs. Note the dorsal dislocation of the capitate bone fragments on the lateral image. (B) Axial computed tomography scan showing scaphoid fracture and dorsal bone fragments.

*bones, and they appear to depend on the proximal articular surface of the capitate bone. The capitate bone lost part of its articular congruence with the lunate bone due to a slight volar angulation of its proximal segment."*

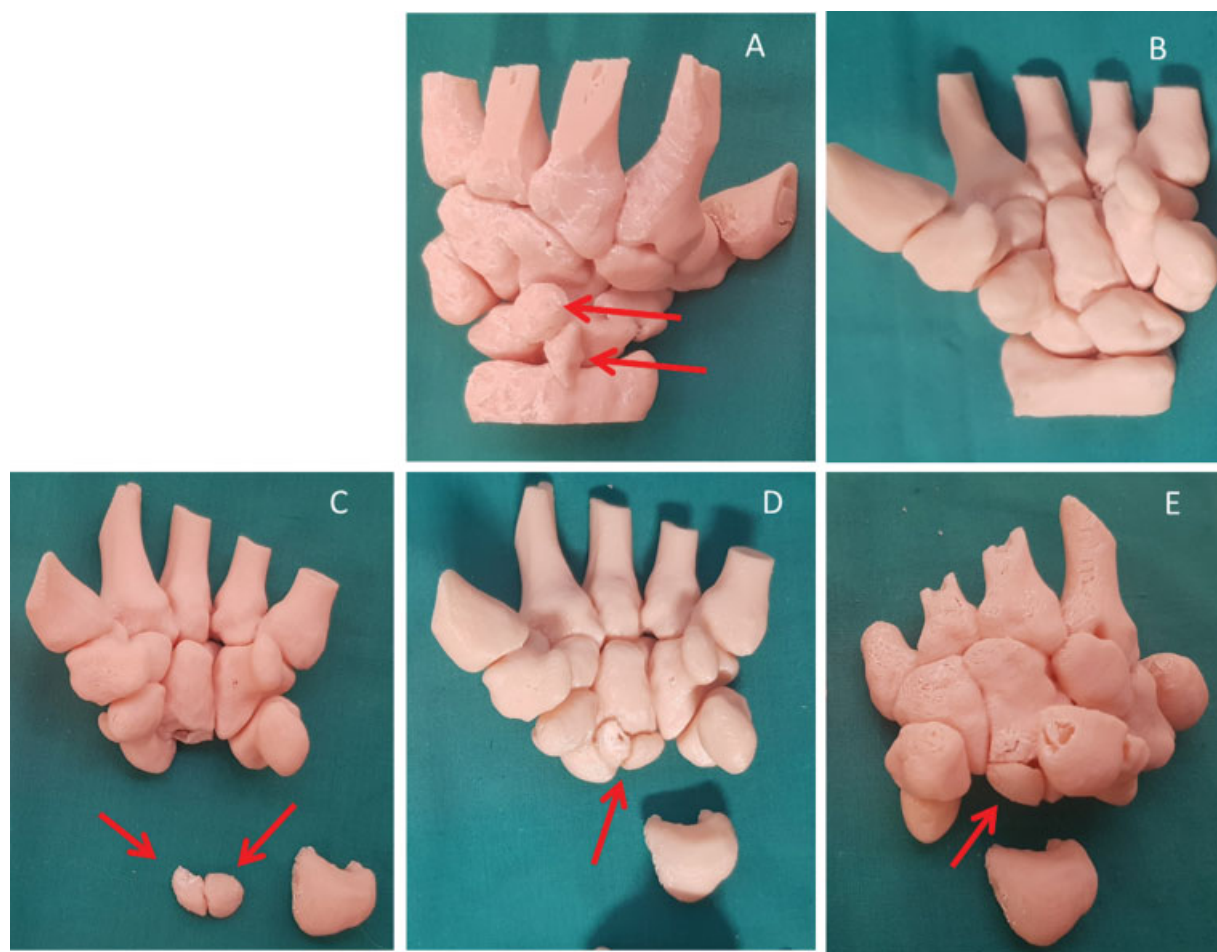
The process begins with the analysis of a Digital Imaging and Communications in Medicine (DICOM) study from a multi-slice helical CT scan performed after the evaluation of a plain radiograph. The study was imported into the OsiriX radiological software (Pixmeo Sàrl, Bernex, Switzerland) using a domestic equipment. Next, segmentation was applied to individualize carpal bones and fragments and 3D surface rendering. The 3D object was then exported in stereolithography (.stl) format. Using the UltimakerCura software (Ultimaker, Utrecht, Netherlands), the setting details on the impression tray were finalized. The printing was performed using a "fine" setup and acrylonitrile-butadiene-styrene (ABS) thermoplastic material with 1.75 mm in diameter. The printing lasted 9 hours, 15 minutes.

The 3D customized model was evaluated, and each bone was individualized to better understand the injury mechanism. This was a scaphoid fracture and dorsal capitate fracture-luxation with three fragments. Two of these fragments presented a 180° rotation and originated from the

proximal pole of the capitate bone. The fracture was classified as Fenton syndrome involving three capitate bone fragments (**→Figure 2**).

It is very difficult to assess such fractures using imaging techniques because the spatial assessment of the size, location, and orientation of each carpal bone and fragment is challenging. Surgery was planned on the 3D printed model, reconstructing the three capitate fragments as a puzzle, and measuring the length of the scaphoid and capitate bone to synthesize both of them with screws. The size of the two dislocated capitate fragments was also determined as 11 mm and 12 mm on its long axis; this measurement was performed due to the possibility of synthesis with screws. The approach route was evaluated with these data at hand, and we decided for a dorsal approach.

Surgical treatment was carried out four days after the production of the model. Using a dorsal approach, the scaphoid fracture was synthesized with a 2.5-mm AutoFix (Stryker Corporation, Kalamazoo, MI, US) headless compression cannulated screw, as we would do in any trans-scapholunate fracture-dislocation, because scaphoid stabilization, integrating two rows of carpal bones, facilitates capitate bone reduction. Next, the dislocation of the



**Fig. 2** Full-scale three-dimensional models. (A) Presurgical reconstruction, dorsal view, showing dislocated, dorsally rotated fragments (arrows). (B) Presurgical reconstruction, volar view. (C) Two anatomically reduced capitate bone fragments (arrows) (D) Capitate bone fragments assembled as a puzzle, volar view. (E) Reconstruction image, dorsal view.

capitate fragments was reduced and synthesized with a 2.0-mm AutoFix (Stryker) cannulated screw (►Figure 3). The patient was immobilized with a splint for 6 weeks, which was then replaced by a semi-rigid wrist brace with palmar-dorsal-thumb support to begin assisted rehabilitation.

## Results

Follow-up lasted for 12 months, with rehabilitation and physical therapy starting at the 6th week. The patient had no pain, and he was able to perform his usual activities. In addition, he had a non-painful dorsal scar, in addition to 85° of dorsal flexion, 50° of palmar flexion, 25° of radial deviation, 30° of ulnar deviation, and complete pronation-supination (►Figure 4). Wrist, claw, and grip functions are normal. Overall muscle balance was 4+/5 (according to the modified muscle strength scale from the Medical Research Council), with no sensitive disturbances. Radiological fracture consolidation was observed with no signs of pseudoarthrosis or necrosis of the scaphoid and capitate bones (►Figure 5). As final functional outcomes, the scores on the Disabilities of the Arm, Shoulder, and Hand (DASH) and the Mayo Wrist Score questionnaires were of 25 and 65 (satisfactory), respectively.

## Discussion

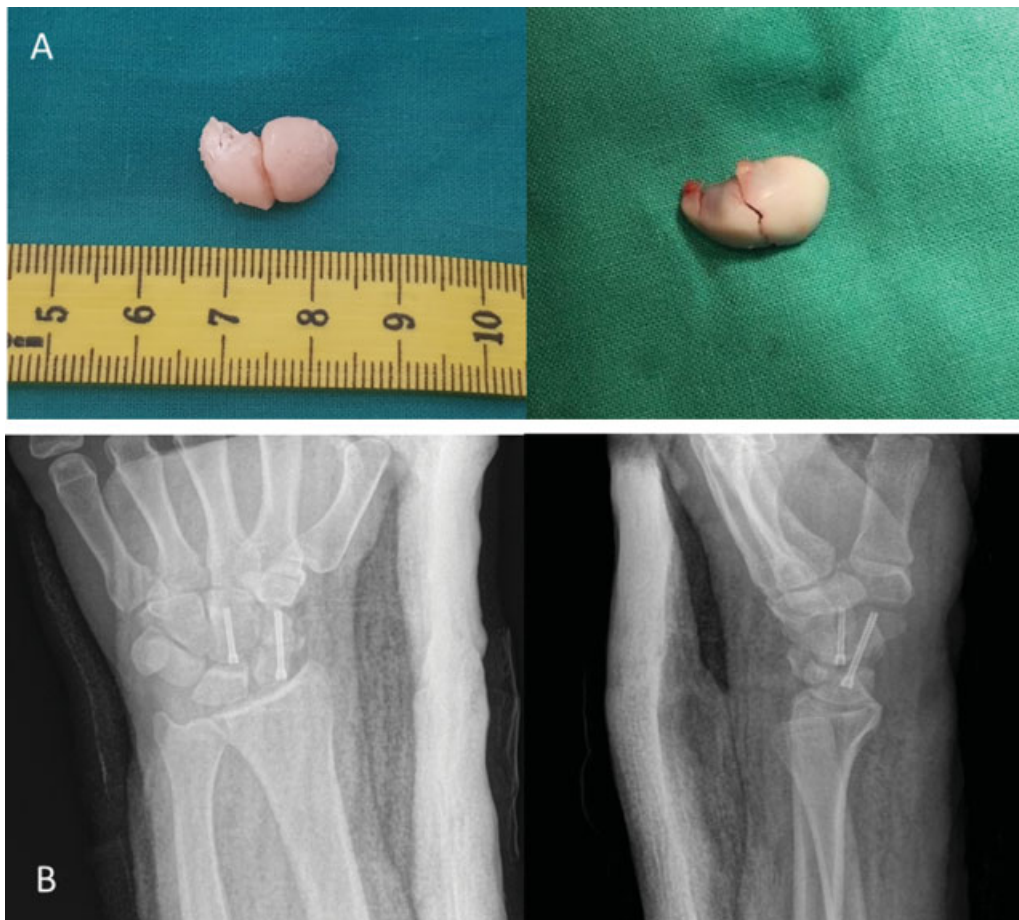Fenton syndrome is a rare, severe condition, mostly reported as single cases. Some authors believed scaphocapitate syndrome was a variety of transscaphoid-transcapitate perilunar fracture-dislocation, since it is spontaneously reduced by inversion of the proximal capitate fragment.

There are two common presentations; one is characterized by transverse scaphoid fracture and capitate fracture with no dislocation, whereas the other features a lunate dorsal dislocation.

The most frequently mentioned fracture pattern is indicated by Vance et al.,<sup>4</sup> who classified scaphoid and capitate fractures into six different patterns, depending on fragment geometry and displacement (►Figure 6).

## Lesion Mechanism

The lesion mechanism is a controversial matter; most authors agree that it would be trauma with the hand in forced hyperextension associated with axial compression. According to Jones,<sup>5</sup> the absence of lunate dislocation at the radiographic evaluation is due to the instantaneous, spontaneous reduction occurring in all cases. For Stein et al.,<sup>6</sup> the injury would go through three stages during trauma

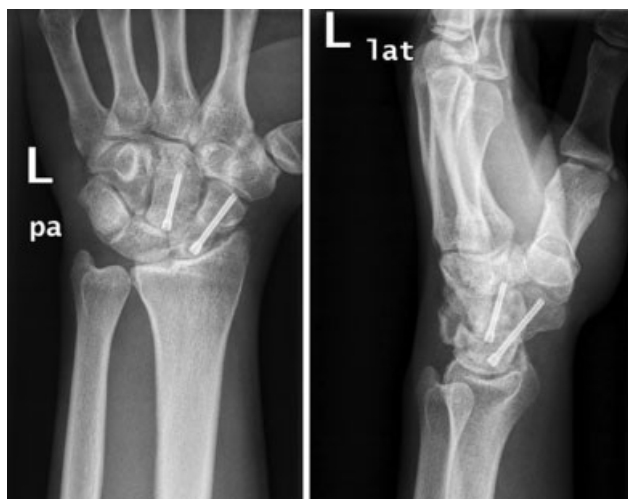

**Fig. 3** (A) Comparison between the two capitate bone fragments: the real and the three-dimensional printed bones (intraoperative image). (B) Postsurgical posteroanterior and lateral radiographs.





**Fig. 4** Final functional outcomes at 12 months.



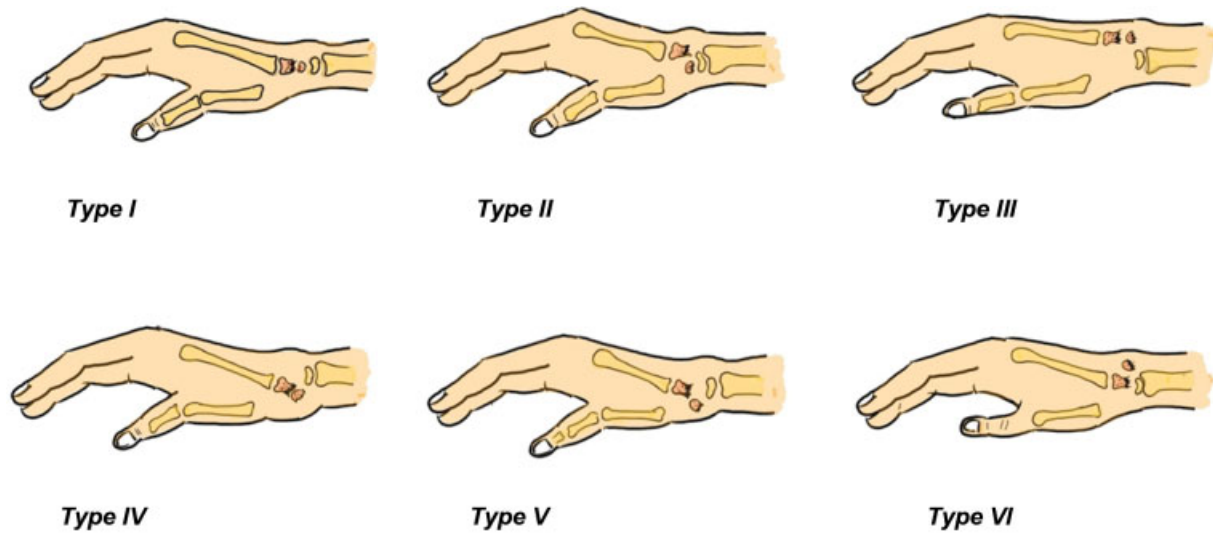
**Fig. 5** Posteroanterior and lateral radiographs at 12 months.

(→**Figure 7**). Fenton suggests that hyperextension and radial deviation of the wrist results in the radial styloid crashing the scaphoid and capitate bones. Stein and Siegel<sup>6</sup> suggest that direct compression of the radial styloid over the capitate bone during wrist hyperextension with no

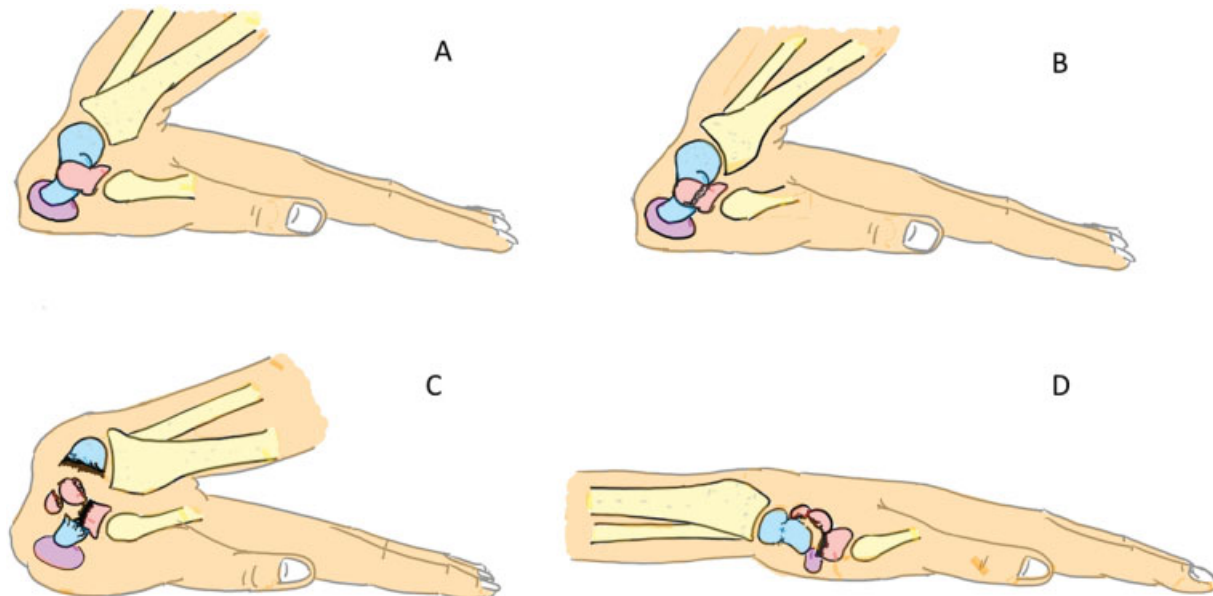
radial deviation results in a capitate fracture and a 90° rotation of the proximal fragment due to the forced extension; next, when the hand resumes its neutral position, the capitate fragment completes a 180° rotation. Vance et al.<sup>4</sup> suggest two mechanisms of injury: extreme dorsiflexion and volar wrist flexion (→**Figure 8**); a greater force would result in rotation of the proximal part of the capitate fragment.

## Diagnosis

Diagnosis is based on a high index of suspicion on physical examination and conventional radiographs. Even so, diagnosis is difficult, and we believe that CT scans have a critical role in assessing concomitant injuries and the degree of capitate bone rotation. Here, we used a 3D-printed model as an essential tool to plan a safe and successful surgery. However, 3D model building requires computer knowledge, and it is associated with printing costs and a variable time delay. Although sometimes not acceptable, this time delay is often enough for surgery planning and performance during the acute period. Our experience shows that 3D models change surgical planning and help solving cases.



**Fig. 6** Scaphocapitate syndrome fracture patterns. Type I, transverse scaphoid and capitate fracture with no dislocation. Type II, the inverted proximal fragment of the capitate remains at the joint with the lunate bone. Type III, lunate dorsal dislocation. Type IV, carpal and proximal capitate fragment volar perilunate dislocation. Type V, Isolated volar dislocation of the proximal capitate fragment. Type VI, isolated dorsal dislocation of the proximal capitate fragment. Designed by JL Muñoz based on Vance et al.<sup>6</sup>

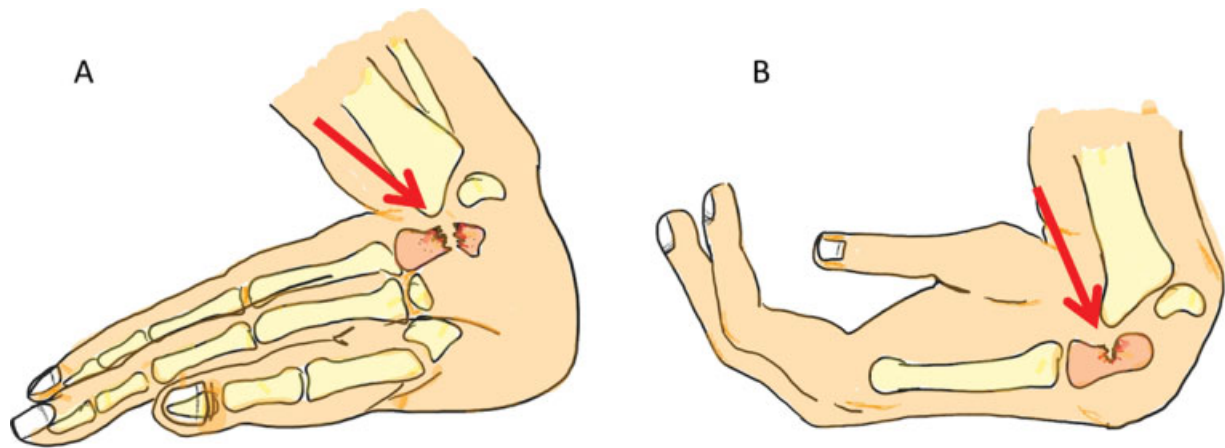


**Fig. 7** Injury mechanism on Fenton syndrome. (A) Scaphoid (blue), capitate (red) and pisiform bones (purple). (B) Stage 1: capitate fracture after impact with the dorsal edge of the radius. (C) Stage 2: scaphoid fracture and 90° rotation of the proximal capitate fragments (note two fragments, as in our case report). (D) Stage 3: Initial position of the hand with both proximal capitate fragments at an 180° rotation at the dorsal area of the wrist. Designed by JL Muñoz based on Vance et al.<sup>6</sup>

## Treatment

Historically, closed reduction and immobilization are the gold standard for perilunate lesion treatment. Conservative treatment can be considered in fractures with no displacement. Today, there is a consensus that carpal anatomical restoration is difficult to achieve and maintain using a conservative approach; numerous studies have shown poor outcomes when stabilizing such complex intercarpal relationships.

Several studies have shown better functional outcomes and an earlier return to work in patients with perilunate lesions submitted to open surgery compared to conservative treatment; inadequate carpal bones alignment has been associated with chronic carpal instability, posttraumatic arthritis with persistent pain, scapholunate collapse, and loss of range of motion.<sup>7</sup> Open reduction allows a direct visualization of the injury for carpal anatomy repair, so it is currently the treatment of choice in all acute perilunate fractures-dislocations,



**Fig. 8** Injury mechanism on Fenton syndrome. (A) Capitate fracture in extreme dorsiflexion; the dorsal distal part of the radius crashes the capitate bone. (B) Volar hyperflexion injury mechanism; the volar part of the radius causes capitate fracture. Designed by JL Muñoz based on Vance et al.<sup>6</sup>

with no significant differences compared to fixation with screws or Kirschner wires. However, recent publications showed that arthroscopy-assisted treatment provides outcomes comparable to open surgery, with stable carpal restoration, alignment, and fixation, in addition to satisfactory radiological and clinical results.<sup>8</sup>

Kumar et al.<sup>9</sup> reported pseudoarthrosis and avascular necrosis of the scaphoid-lunate bones and carpal collapse with osteoarthritis when performing open reduction and fixation with a Hebert screw; therefore, they recommended the addition of a bone graft in primary surgeries. Most authors agree that non-anatomical reduction of the scaphoid and capitate bones results in higher rates of avascular necrosis and nonunion; therefore, some suggested the excision of the proximal fragment of the capitate bone when synthesis is not an option due to the potential development of avascular necrosis; this recommendation does not apply to the head of the capitate bone, in which revascularization is more likely.<sup>3,6</sup>

## Prognosis

Prognosis is contingent on the type of injury and whether reduction has been optimal and stable. It is probable, however, that most patients will not present a full range of motion or excellent grip strength, but their wrists will be functional and with minimal pain. Sequela, including capitate bone necrosis or delayed union, radiocarpal and midcarpal osteoarthritis, scaphoid pseudoarthrosis, carpal instability, loss of strength, limitation of mobility or residual pain, must be reported.

In advanced cases, in which early treatment has not been carried out, carpal reconstructive surgery is complicated by scaphoid pseudoarthrosis, capitate degeneration, and arthritis of other carpal bones, including the distal lunate surface. In these cases, the surgical treatment options are total wrist arthrodesis; scaphoid resection with lunate-capitate bone arthrodesis, or “four corner” arthrodesis; proximal row

carpectomy; or capitate head replacement with a silastic prosthesis (resurfacing capitate pyrocarbon implant, RCPI).<sup>10</sup>

## Conclusions

Fenton syndrome is a rare condition with challenging diagnosis and treatment. Three-dimensional models facilitate the understanding, in full-scale, of anatomical relationships, concomitant fractures, comminution degrees, and fragment rotation. In addition, these models make preoperative planning simpler and more intuitive, providing the surgeon with clarity and security to face the procedure.

## Acknowledgments

We are grateful to Juan Antonio Muñoz Berenguer, a father and teacher, and to Carlos Morales and J. Tomás López Salinas, experts in hand surgery, for their help, dedication, and professional ethics; without them, this study would not have been possible.

## References

- 1 Muppavarapu RC, Capo JT. Perilunate Dislocations and Fracture Dislocations. *Hand Clin* 2015;31(03):399–408
- 2 Perves J, Rigaud A, Badelon L. Fracture par décapitation du grand os avec déplacement dorsal du corps de los stimulant une dislocation carpienne. *Chir Main* 1937;24:251–253
- 3 Fenton RL. The naviculo-capitate fracture syndrome. *J Bone Joint Surg Am* 1956;38-A(03):681–684
- 4 Vance RM, Gelberman RH, Evans EF. Scaphocapitate fractures. Patterns of dislocation, mechanisms of injury, and preliminary results of treatment. *J Bone Joint Surg Am* 1980;62(02):271–276
- 5 Jones GB. An unusual fracture-dislocation of the carpus. *J Bone Joint Surg Br* 1955;37-B(01):146–147
- 6 Stein F, Siegel MW. Naviculocapitate fracture syndrome. A case report: new thoughts on the mechsanim of injury. *J Bone Joint Surg Am* 1969;51(02):391–395
- 7 Green D, Hotchkiss R, Pederson W. Carpal instabilities and dislocations. In: *Green's Operative Hand Surgery*. Vol 1;4th ed. 1999:914

- 8 Kim JP, Lee JS, Park MJ. Arthroscopic treatment of perilunate dislocations and fracture dislocations. *J Wrist Surg* 2015;4(02):81–87
- 9 Kumar A, Thomas AP. Scapho-capitate fracture syndrome. A case report. *Acta Orthop Belg* 2001;67(02):185–189
- 10 Marcuzzi A, Ozben H, Russomando A, Petit A. Chronic transscaphoid, transcapitate perilunate fracture dislocation of the wrist: Fenton's syndrome. *Chir Main* 2013;32(02):100–103