



# Y Stenting in Wide-Necked Bifurcation Aneurysms: A Single-Center Experience

Apratim Chatterjee<sup>1,✉</sup> Anshu Mahajan<sup>1,✉</sup> Vinit Banga<sup>1</sup>  
Piyush Ojha<sup>1,✉</sup> Gaurav Goel<sup>1</sup>

<sup>1</sup>Department of Neurointervention, Medanta, The Medicity, Gurugram, Haryana, India

**Address for correspondence** Gaurav Goel, MD, DM, Department of Neurointervention, Room no 16, OPD 6th floor, Medanta, The Medicity, CH Baktawar Singh Rd, near Olympus, Medicity, Islampur Colony, Sector 38, Gurugram, Haryana 122001, India (e-mail: drgauravgoel1@gmail.com).

Indian J Neurosurg 2022;11:55–60

## Abstract

Stent-assisted coiling is an endovascular means of managing wide-necked bifurcation aneurysms. In spite of the wide availability of various newer devices in managing such difficult aneurysms, the Y stenting offers a safe and cost-effective alternative to treat such cases in resource poor settings. This article provides an insight of our initial six cases of Y stent-assisted coiling along with their follow-up over a period of 6 months with no recanalization in any case. It also highlights the various technical aspects involved in such cases. One case had recurrent subdural hematoma probably due to use of antiplatelets and another patient had sudden dip in level of consciousness probably due to hematoma expansion that might also have been due to antiplatelet usage. However, none of the cases had any issues regarding stent migration, malapposition, and dissection. In our experience, Neuroform Atlas stent used for Y stenting offers a safe and technically easy alternative to various newer bifurcation devices.

## Keywords

- ▶ Y stent
- ▶ wide
- ▶ aneurysm
- ▶ bifurcation

## Introduction

Endovascular therapy is an established means of treatment for ruptured wide-necked bifurcation aneurysms since the advent of International Subarachnoid Aneurysm Trial and Barroe Ruptured Aneurysm Trial trials. Newer techniques have been evolving in this field since then like balloon remodeling, stent-assisted coiling, bifurcation devices, flow diverters, and intrasaccular flow disrupters (WEB). However, aneurysms with wide necks are still challenging lesions for treatment by endovascular means and have technical limitations. Balloon-assisted coiling may be challenging in cases of very wide-necked aneurysms with complex anatomy.<sup>1</sup> Flow diversion is a revolution in endovascular treatment, but the destiny of the covered side branches in case of bifurcation aneurysms is concerning.<sup>2,3</sup> Intrasaccular flow

disrupters have evolved as the new modality of treatment in such wide-necked aneurysms of the bifurcation, but the technical expertise and mechanisms are still in evolution and long-term angiographic occlusion rates are still lower than stent-assisted coiling.<sup>4,5</sup> Last but not the least, PulseRider (Cerenovus, New Brunswick, New Jersey, United States) and pCONus aneurysm implant (phenox, Bochum, Germany) devices appear to be promising new strategies to treat wide-necked lesions, though further researches are required to confirm the efficacy of these devices. Newer devices such as eClips (Evasc Neurovascular Enterprise ULC), honeycomb microporous covered stent, and Comaneci (Rapid medical) devices have arrived for wide-necked bifurcation aneurysm but these are still under investigation and require further research to prove their efficacy.

published online  
January 13, 2022

**DOI** <https://doi.org/10.1055/s-0041-1730103>  
**ISSN** 2277-954X

© 2022. Neurological Surgeons' Society of India.

This is an open access article published by Thieme under the terms of the Creative Commons Attribution-NonDerivative-NonCommercial-License, permitting copying and reproduction so long as the original work is given appropriate credit. Contents may not be used for commercial purposes, or adapted, remixed, transformed or built upon. (<https://creativecommons.org/licenses/by-nc-nd/4.0/>).

Thieme Medical and Scientific Publishers Pvt. Ltd. A-12, 2nd Floor, Sector 2, Noida-201301 UP, India

The use of two stents in a Y configuration has been first described by Chow et al.<sup>5</sup> Its safety and efficacy have made it one of the safest alternatives to clip reconstruction. It is done by placing two stents in a Y configuration in the parent artery to create a new bifurcation point for the wide-necked bifurcation aneurysm and it prevents coil protrusion and provides a scaffold. There have been variations to this Y stenting in the form of T stenting in which the stents are placed in the form of a T in the parent artery that provides the same help that is prevention of coil protrusion and scaffolding.

There has been wide variation in the nature of implants taken for Y stenting. Studies have been with Enterprise (closed stent), Solitaire and usage of complaint balloon. The use of open cell stents (Neuroform) for Y stenting provides better scaffolding of parent vessels and is used in this study for Y stenting.

The current article tries to address our single-center experience of Y stenting in the treatment of ruptured wide-necked bifurcation aneurysms.

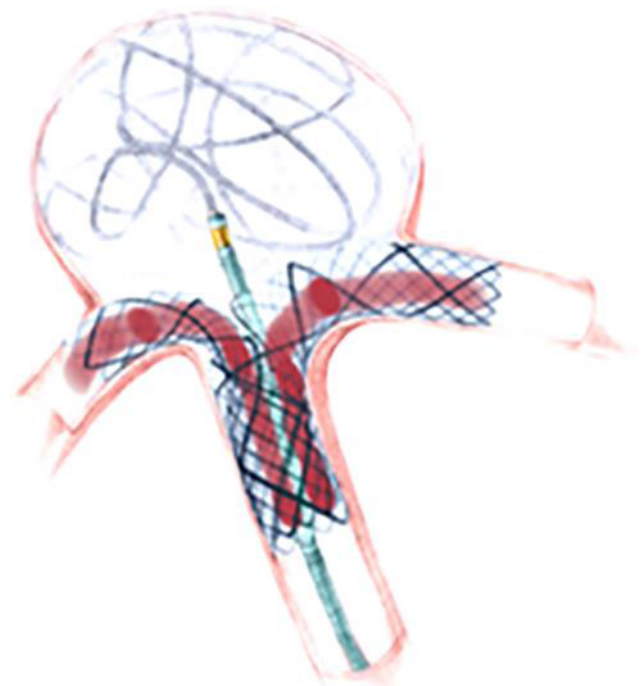
### Procedure Details

After inducing general anesthesia, a 6 FR Cook (750 Daniels Way Bloomington, Indiana, United States) long sheath was placed in common carotid artery through right femoral access over a 5 FR Piccard diagnostic catheter and then DAC 070 (Stryker Neurovascular 4870 West 2100 South Salt Lake City, Utah, United States) guiding catheter was parked in the cavernous segment of internal carotid artery (after giving 100 µg of intraarterial nitroglycerin). Following this first, the difficult daughter branch to navigate is cannulated with a Headway (Microvention Inc, 1311 Valencia Avenue, Tustin, California, United States) 017 microcatheter over a Traxcess (Microvention, Inc, 1311 Valencia Avenue, Tustin, California, United States) 014 microwire. Another coiling microcatheter (Excelsior SL 10 [Stryker Neurovascular, Business and Technology Park, Model Farm Road, Cork, Ireland]) in our case was navigated inside the aneurysm sac over a 014 microwire and few coil loops were placed in it without detaching. The 017 microcatheter in one daughter vessel was used to deploy a Neuroform Atlas stent so that a part remains in the daughter vessel and it lands in the parent vessel across the neck of the aneurysm sac. Now through the struts of this first stent 014 microwire (made in the form of J) was passed in to the other daughter vessel (easily accessible as per initial plan) and another Neuroform Atlas stent was deployed in a similar fashion so that the straight limbs of both the stents overlapped in the single limb of Y reconstruct one within the other. This step is considered the most difficult step in the process as deployment of the second stent through the struts of the first might lead to displacement of the first stent that may cause dissection or improper positioning leading to failed procedure. The coiling catheter jailed across the stents needs to be taken care of during this entire process as slight movement might lead to rupture of the aneurysm. It was now used to coil the rest of the aneurysm and the coiling microcatheter in the end was taken out to finish the process.

The whole process needs to be under loading dose of antiplatelets (which in our series were done with Tab Ecosprin 300 mg and Tab Prasugrel 50 mg) 2 hours prior to stent placement and Injection Heparin was used before starting and during the process with intraoperative activated clotting time (ACT) monitoring and target ACT was kept approximately double the baseline or roughly a value of 300.

### Case 1

A 45-year-old male, with known seizure disorder, came with sudden onset loss of consciousness with severe headache. Computed tomography (CT) showed right temporal bleed (►Fig. 1A,B) and CT angiography showed a right middle cerebral artery (RT MCA) bifurcation aneurysm. Digital subtraction angiography (DSA) showed a ruptured wide-necked bifurcation aneurysm of RT MCA measuring 7.8 × 6.6 mm with neck measuring 4.6 mm (►Fig. 1C). So, plan for Y stent-assisted coiling was taken in view of the wide neck and neck dome ratio >2. A SL 10 microcatheter was placed into the aneurysm over a 014 microwire and few coil loops were placed that were then jailed across a 3 × 24 mm size Neuroform Atlas stent placed via a 017 microcatheter into the difficult most branch first that in this case was the superior division through the struts of which subsequently 017 microcatheter was passed into the inferior division and a Neuroform Atlas stent 3 × 21 mm was placed. The coiling catheter was then used to place and fill the residual aneurysm with further coils. Post-procedure injection showed some residual space in the neck of the aneurysm as shown in ►Fig. 1D. Six months later, DSA showed thrombosis of residual filling that was present in the aneurysm neck with no residual filling in the aneurysm (R & R 1) (►Fig. 1E,F).



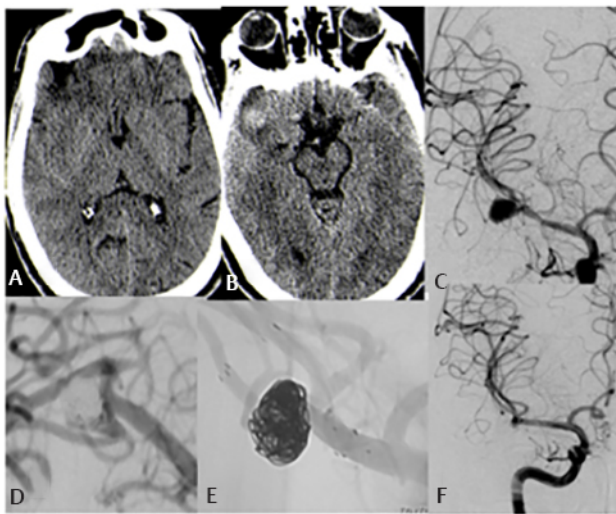
**Fig. 1** Schematic diagram of a Y stent reconstruct with the pattern of Y stenting marked in red ink resembling the letter "Y."

### Case 2

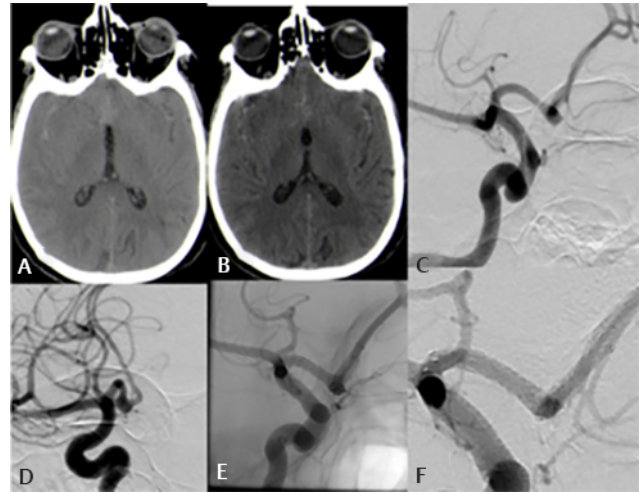
A 62-year-old female presented with severe headache and vomiting. CT showed a diffuse subarachnoid hemorrhage (SAH). DSA showed a ruptured wide-necked ACOM aneurysm measuring 1.6 × 1.8 mm with neck measuring 1.2 mm with neck dome ratio more than 2. With a 017 microcatheter Neuroform Atlas stents were placed in a Y fashion in the two anterior cerebral artery measuring 3 × 24 mm by 3 × 21 mm with the jailing technique for coiling of ACOM aneurysm. The packing was dense and post procedure there was no complications. The patient was discharged on double antiplatelets (Tab Ecosprin 150 mg and Tab Prasugrel 10 mg) and 6 months follow-up angiogram showed a well-coiled aneurysm without any residual filling (R & R 1) (► Fig. 2).

### Case 3

A 59-year-old female presented with sudden onset headache and vomiting following that she was admitted and CT brain showed a large hematoma in midbasifrontal region measuring 4.5 × 3.1 cm with perilesional edema with SAH. Magnetic resonance angiography revealed an ACOM aneurysm. DSA done confirmed a wide-necked ruptured ACOM aneurysm measuring 5.08 × 1.78 mm with neck 4.02 mm. Similarly Y stent with Neuroform Atlas stents were done with 3 × 24 mm by 3 × 21 mm with coiling done by jailing technique. However, post-procedure the patient had a deterioration in Glasgow Coma Scale (GCS) following which intubation was continued and conservative management was continued. CT showed expansion of the hematoma that was the reason for the deterioration of GCS; however, the relatives denied any further intervention and leave against medical advice was taken (► Fig. 3).



**Fig. 2** Case 1: (A and B) subarachnoid bleed with right temporal hematoma, (C) digital subtraction angiography (DSA) finding of right middle cerebral artery bifurcation aneurysm, (D) DSA image after Y stent-assisted coiling, (E and F) follow-up DSA image 6 months later showing progressive thrombosis of residual neck and no residual recanalization of aneurysm.



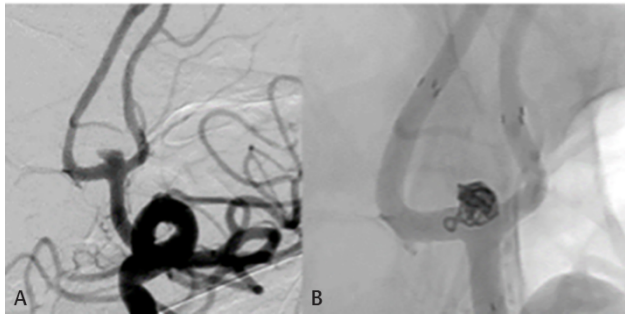
**Fig. 3** Case 2: (A and B) Diffuse subarachnoid hemorrhage, (C and D) digital subtraction angiography image of ACOM aneurysm, (E and F) DSA image of Y stent-assisted coiling.

### Case 4

A 59-year-old male presented with headache and vomiting. CT showed Right sylvian fissure bleed with subdural hematoma (SDH) in right side. DSA revealed a ruptured wide-necked RT MCA bifurcation aneurysm measuring 5.25 × 5.05 mm with neck measuring 5.01 mm. Thus, Y stent-assisted coiling was done with Neuroform Atlas stent measuring 3 × 24 mm by 4 × 24 mm with the coiling of aneurysm by jailing technique. The patient was discharged on double antiplatelets (Tab Ecosprin 150 mg and Tab Prasugrel 10 mg). After 2 months of discharge, the patient presented with slurred speech and altered sensorium. CT brain now revealed acute on chronic SDH in right frontotemporoparietal region that was subsequently managed by burr hole operation by the neurosurgical team. Antiplatelets were modified (ascribing as the cause of atraumatic SDH) and he was discharged on Tab Ecosprin 150 mg and Tab Plavix 75 mg. After 1 month of the same, he again presented similarly but this time to another hospital where CT brain showed a similar left frontoparietal SDH that was again managed surgically by burr hole and antiplatelets were stopped. One month following this he presented with left-sided weakness and aphasia suggestive of RT MCA syndrome; CT showed minor infarcts in RT MCA territory without any new SDH. DSA was immediately done to find no residual filling of MCA aneurysm but with minor clots in stents. Antiplatelets were renewed but this time with only Ecosprin 150 mg and he was discharged in a stable condition (► Fig. 4).

### Case 5

A 45-year-old female, hypertensive, diabetic, presented to us with headache, vomiting with minor SAH in CT in the anterior cerebral interhemispheric fissure. DSA revealed a ruptured wide-necked ACOM aneurysm measuring 1.98 × 2.78 mm with neck measuring 2.97 mm. Y stenting with Neuroform Atlas stent was done measuring 3 × 24 mm by 3 × 21 mm with coiling by jailing method. Post-procedure



**Fig. 4** Case 3: (A) ACOM aneurysm, (B) Y stent-assisted coiling.

no complications were encountered. DSA in follow-up after 6 months revealed no recanalization (R&R 0) with stent seen in situ (► Fig. 5).

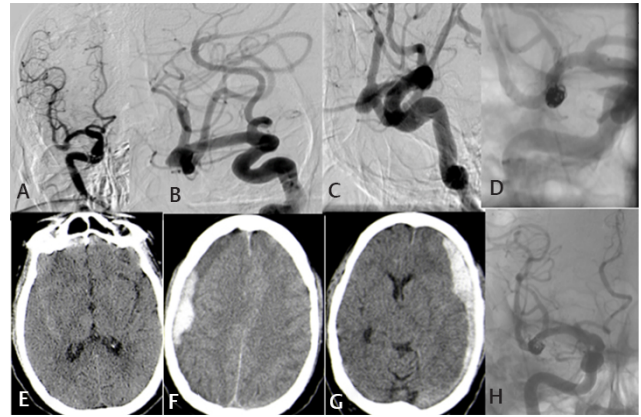
### Case 6

A 51-year-old male, hypertensive, bronchial asthma, h/o splenectomy and hemiarthroplasty, chronic smoker, presented with headache diagnosed as SAH and ACOM aneurysm treated 7 years back with coiling. He was lost to follow-up and presented 7 years later with mild headache. CT revealed no SAH. DSA was done to check for aneurysm coiling status and large recanalization was documented (R&R 2) (measuring  $5.23 \times 4.14$  mm) with neck measuring 3.23 mm. The large neck and the anatomy led to decision of Y stent-assisted coiling of recanalized ACOM aneurysm. Subsequently,  $3 \times 24$  and  $3 \times 21$  mm Neuroform Atlas stents were used for Y stenting. Subsequent follow-up DSA showed thrombosis of previously recanalized portion of ACOM aneurysm with stent in situ (► Fig. 6).

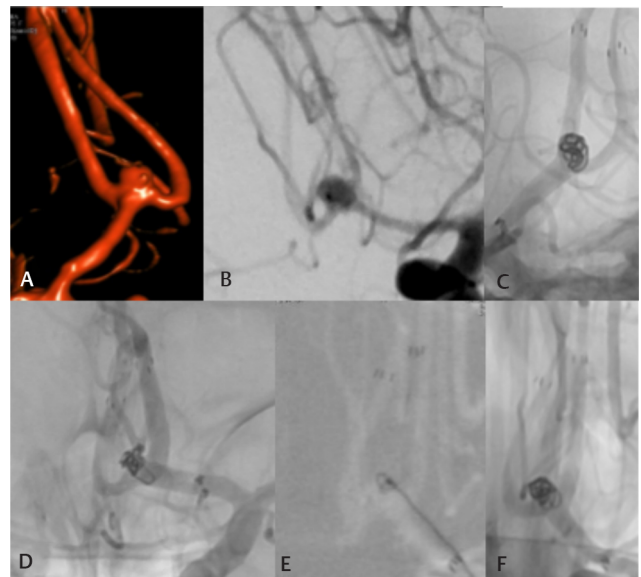
## Discussion

Stent-assisted coiling has been in effect since 1997. Stents in aneurysm coiling offer multiple advantages. It imparts an adjunct to potential mechanical, hemodynamic, and biologic properties to coil embolization alone. It provides support to coils and prevents its prolapse mechanically, serves as a conduit for passage of blood, and also acts as a scaffold for endothelial growth and healing. Stents after placement also alter the hemodynamics of blood flow into the aneurysm, thereby causing progressive thrombosis of incompletely occluded aneurysms.

Even with the advancements of endovascular therapy for aneurysm management, wide neck defined as neck diameter more than 4 mm with neck to dome ratio more than 2, at bifurcations, is a hard nut to crack. Apart from the coil mass protruding and occluding the daughter vessels that often are incorporated in the bifurcation aneurysms, these aneurysms are more often recanalized by simple coiling and chance of rerupture remains high in such cases. In the ATENA study, which was a morphologic study of 694 unruptured aneurysms treated endovascularly, in which the investigators found that a dome-to-neck aspect ratio of  $< 1.5$  was associated with a decreased rate of successful coil embolization. Various devices have come for such aneurysms like waffle-cone



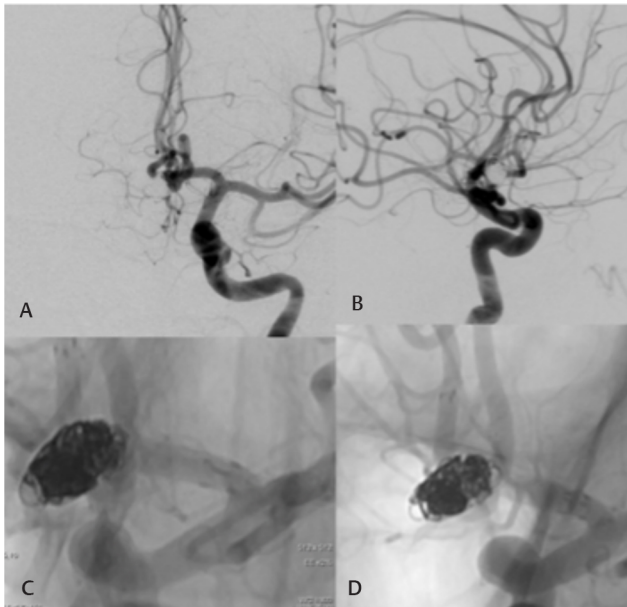
**Fig. 5** Case 4: (A–C) right middle cerebral artery (MCA) bifurcation aneurysm in digital subtraction angiography (DSA), (D) DSA image of Y stent-assisted coiling, computed tomography brain on initial presentation showing subarachnoid hemorrhage, (E–G) subdural bleed on either sides, (H) DSA of right MCA bifurcation aneurysm in follow-up.



**Fig. 6** Case 5: (A and B) digital subtraction angiography image showing ACOM aneurysm, (C–F) Y stent-assisted coiling.

technique, flow diverters, WEB, bifurcation devices like Pulse rider, pCONUS, pCANVAS, eCLIPS, honeycomb, Contour, and Comaneci device. The Y stenting (► Fig. 7) remains one of the most cost-effective and safe techniques for coiling of such cases; however, it has technical difficulties and in inexperienced hands might lead to increased morbidity.

A total of six cases (► Table 1) were obtained over 1 and ½ year from January 2019 to April 2020 with follow-up after 6 months for all the patients except one (as she deteriorated and has been taken leave against medical advice after procedure). Intraprocedural complications like rupture of aneurysm, dissection, and stent misplacement were not seen in our series in any patient; however, post-procedure a drop in GCS to E1M1 VT from E4V4M6 GCS status was seen in one patient that was ascribed to expansion of hematoma. No episode of thromboembolic events was noted in each of the



**Fig. 7** Case 6: (A) ACOM aneurysm digital subtraction angiography image, (B–D) Y stent-assisted coiling.

cases. Vasospasm was noted in two patients during the 7th to 9th day post ictus related to SAH-induced vasospasm as all were ruptured cases. Rates of technical difficulties such as stent migration (3.1%), stent prolapse (3.1%), and coil herniation (1.6%) remain low combining the two largest center experiences.<sup>6</sup> The periprocedural symptomatic ischemic stroke rate was found to be 4.7% in larger studies.<sup>6</sup> Thromboembolic rates range from 0 to 11.1%,<sup>6</sup> with the highest reported rates reported in the early experience. This difference may reflect a broader acceptance of more long-term dual antiplatelet therapy based on the preliminary data, specifically a reluctance to discontinue clopidogrel prior to 6 months. The incidence of delayed strokes (> 2 weeks after procedure) is low at 3.1%.<sup>1,2,6</sup> There have been no reports of in-stent stenosis (approximately 7.8% incidence) requiring treatment in studies by other groups.<sup>1,7-9</sup>

All the patients in our series were discharged on dual antiplatelets (Tab Ecosprin 150 mg and Tab Prasugrel 10 mg) till at least 6 months of follow-up with DSA and were continued

till 1 year after which plan was to continue on one antiplatelet lifelong.

After discharge, one patient developed subdural hematoma on double antiplatelets that was then evacuated by burr hole and antiplatelet regime was changed to single antiplatelet (clopidogrel only 75mg); however, he developed atraumatic subdural hematoma in the contralateral side. Following this antiplatelets were withdrawn from an outside hospital after burr hole of the opposite side, but he developed stent thrombosis and infarct in his stented side. After this, he was put on single antiplatelet (Ecosprin 150 mg only) and is continuing well till now.

Follow-up after 6 months of all the patients (5 patients) shows no recanalization of the aneurysm (R&R 1). There was no episode of rerupture in any of the cases.

Progressive thrombosis of the incompletely coiled part of the aneurysm has been documented in two cases. One of the cases was retreated with Y stenting after initial recanalization following simple Balloon-assisted coiling 7 years ago in which coiling was not done in the remnant neck of the aneurysm and just Y stenting was done. Follow-up angiogram at 6 months revealed thrombosis of the remnant portion of the neck of the aneurysm with R & R 1.

Despite inherent technical challenges, the centers reporting their experience with Y-stent reconstruction have demonstrated high technical success ranging from 88.9 to 100%, while the incidence of complications on the initial treatment remained low from 0 to 21%.<sup>1,6-10</sup>

All studies report a zero procedural mortality rate. Aneurysm recurrence rates range from 8.9 to 28.6% at from 3.5 to 36.7% months follow-up. Our 6 months follow-up has led to no recanalization so far in the five patients we have followed up. Retreatment rates range from 0 to 15%<sup>1,6,7,10</sup> in other groups, whereas none so far required in our study.

Technical success in using Neuroform Atlas stents for such cases has been easy in our experience. The placing of the first stent and crossing a 014 microwire in the form of a J through the struts of the first stent has been smooth in our experience with Neuroform Atlas stent and none of the case had stent migration, malapposition, dissection during the procedure as a complication. Follow-up in all the cases showed successful coiling without significant recanalization. Thus, Y

**Table 1** Patients with location of aneurysm, size of stents used, and outcome

Patients	Location of aneurysm	Size of aneurysm	Neck	Size of Neuroform Atlas	Follow-up at 6 months R&R	Complications
1	RT MCA bifurcation	7.8 × 6.5	4.6	3x24 & 3 × 21	1	
2	ACOM	1.6 × 1.8	1.2	3x24 & 3x 21	1	
3	ACOM	5.08 × 1.78	4.02	3x24 & 3x 21	NA	Hematoma expansion
4	RT MCA bifurcation	5.25 × 5.05	5.01	3x24 & 4x 24	1	SDH
5	ACOM	1.98 × 2.78	2.97	3x24 & 3x 21	1	
6	ACOM	5.23 × 4.14	3.23	3x24 & 3x 21	1	

Abbreviations: ACOM, anterior communicating; ACA, anterior cerebral artery; BAC, balloon-assisted coiling; NA, not available; RT MCA, right middle cerebral artery; SDH, subdural hematoma.

stenting in our experience has been successfully able to treat such wide-necked bifurcation aneurysms and is a very good alternative to newer devices keeping also the economic background in resource-poor settings.

Like in any other study, limitation in our study is the less number of sample size and increasing this number will give a better insight on such cases.

## Conclusion

Y stenting with or without coiling is an effective means of endovascular management in this group of wide-necked bifurcation aneurysm in the era of modern endovascular devices that obviously are with a price tag and often difficult in the middle-to-low socioeconomic countries. Experience varies with centers, but overall our experience as shared here offers significant benefit. Limitations remain like use of antiplatelet drugs in acute ruptured scenario but still it offers nice outcomes as shown in our series even with progressive thrombosis of incompletely occluded part of aneurysms after coiling. Further studies are needed in this regard possibly with more patients and larger period of study and follow-up.

### Conflict of Interest

None declared.

## References

- 1 Fargen KM, Mocco J, Neal D, et al. A multicenter study of stent-assisted coiling of cerebral aneurysms with a Y configuration. *Neurosurgery* 2013;73(3):466–472

- 2 Spiotta AM, Gupta R, Fiorella D, et al. Mid-term results of endovascular coiling of wide-necked aneurysms using double stents in a Y configuration. *Neurosurgery* 2011;69(2):421–429
- 3 Akgul E, Aksungur E, Balli T, et al. Y-stent-assisted coil embolization of wide-neck intracranial aneurysms. A single center experience. *Interv Neuroradiol* 2011;17(1):36–48
- 4 Chalouhi N, Jabbour P, Gonzalez LF, et al. Safety and efficacy of endovascular treatment of basilar tip aneurysms by 5 Stroke Research and Treatment coiling with and without stent assistance: a review of 235 cases. *Neurosurgery* 2012;71(4):785–794
- 5 Chow MM, Woo HH, Masaryk TJ, Rasmussen PA. A novel endovascular treatment of a wide-necked basilar apex aneurysm by using a Y-configuration, double-stent technique. *AJNR Am J Neuroradiol* 2004;25(3):509–512
- 6 Muda AS, Ralib ARM, Yaacob Y, Zakaria R, Bakar AA. Y-stent-assisted coil embolisation of wide-necked aneurysms using a new fully retrievable and detachable intracranial stent: report of two cases. *Malays J Med Sci* 2011;18(4):91–97
- 7 Cho YD, Park SW, Lee JY, et al. Nonoverlapping Y-configuration stenting technique with dual closed-cell stents in wide-neck basilar tip aneurysms. *Neurosurgery* 2012;70(2, Suppl Operative):244–249
- 8 Darkhabani ZM, Lazzaro MA, Zaidat OO. Pericallosal artery aneurysm treatment using Y-configuration stent-assisted coil embolization: a report of four cases. *J Neurointerv Surg* 2012;4(6):459–462
- 9 Martínez-Galdámez M, Saura P, Saura J, Martínez A, De Campos JM, Pérez A. Y-stent-assisted coil embolization of anterior circulation aneurysms using two Solitaire AB devices: a single center experience. *Interv Neuroradiol* 2012;18(2):158–163
- 10 Perez-Arjona E, Fessler RD. Basilar artery to bilateral posterior cerebral artery 'Y stenting' for endovascular reconstruction of wide-necked basilar apex aneurysms: report of three cases. *Neurol Res* 2004;26(3):276–281