



How I Treat Neuroendocrine Tumors

Aasems Jacob¹ Gaby Gabriel^{2,3} Robert A. Ramirez⁴ Yi-Zarn Wang⁵ Lowell Anthony^{1,3}
Aman Chauhan^{1,3}

¹Division of Medical Oncology, University of Kentucky, Lexington, Kentucky, United States

²Department of Radiology, Division of Interventional Radiology, University of Kentucky, Lexington, Kentucky, United States

³Division of Medical Oncology, Markey Cancer Center, University of Kentucky, Lexington, Kentucky, United States

⁴Department of Hematology and Oncology, Ochsner Health New Orleans, New Orleans, Louisiana, United States

⁵Department of Surgery, Louisiana State University Health Science Center, New Orleans, Louisiana, United States

Address for correspondence Aman Chauhan, MD, Department of Medical Oncology, University of Kentucky, 800 Rose Street, Lexington 40536, United States (e-mail: amanchauhan@uky.edu).

Ind J Med Paediatr Oncol 2021;42:470–478.

Introduction

Neuroendocrine tumors (NETs) originate from diffuse neuroendocrine cell system and can develop in many organs. Gastroenteropancreatic (GEP) NETs account for approximately 70%, followed by bronchopulmonary and thymic NETs.¹ The World Health Organization (WHO) classification divides GEP NETs into well-differentiated NETs and poorly differentiated neuroendocrine carcinoma (NEC). Well-differentiated NETs can be grade 1 (G1; mitotic count <2 per 10 HPF - high power field, K_i-67 < 3%), G2 (mitotic count: 2–20, K_i-67: 3–20%) tumors, and G3 (mitotic count >20, K_i-67 > 20%).² Poorly differentiated NECs are always G3 tumors with >20 mitotic count and K_i-67 index >20% and include small- and large-cell NECs.² A total of 10 to 13% of NETs do not have a primary site identified at the time of diagnosis and are called NETs of unknown primary.^{1,3} NETs can also be differentiated based on the secretion of vasoactive amines and hormones into functional (30%) and nonfunctional NETs (70%).¹ This article focuses on the management of well-differentiated NETs with attention to systemic therapy. Factors influencing initial medical decision-making in NET management include functional status, stage, and grade, burden of metastatic disease, and symptoms at presentation.

Case 1

A 61-year-old female presented with right hip pain, diarrhea, and weight loss over the past few months. Pelvic X-ray showed lytic lesions in right femoral acetabulum. Computerized tomography (CT) of abdomen showed multiple liver lesions and additional bony metastasis in ribs. Biopsy of a liver lesion showed a metastatic G2 well-differentiated NET with K_i-67 of 10%.

Diagnosis

CT and/or magnetic resonance (MR) scans are the commonly utilized imaging modalities for initial evaluation. Multiphasic CT/MRI is helpful in evaluating liver metastasis since NETs are highly vascular and can appear isodense on conventional scans. NETs with unknown primary site should be additionally evaluated with upper and lower endoscopy with attention to the terminal ileum or by CT enterography. Evaluation with somatostatin receptor (SSR)-based imaging, like 68-Ga-DOTATATE positron emission tomography (PET), or Cu-64-DOTATATE (preferred over Indium-111-pentetreotide SPECT), is utilized to assess receptor status for determining benefit of SSR-directed therapy and evaluate suspected metastasis if unclear on initial imaging.

DOI <https://doi.org/10.1055/s-0041-1732833>.
ISSN 0971-5851.

© 2021. Indian Society of Medical and Paediatric Oncology. All rights reserved.

This is an open access article published by Thieme under the terms of the Creative Commons Attribution-NonDerivative-NonCommercial-License, permitting copying and reproduction so long as the original work is given appropriate credit. Contents may not be used for commercial purposes, or adapted, remixed, transformed or built upon. (<https://creativecommons.org/licenses/by-nc-nd/4.0/>)

Thieme Medical and Scientific Publishers Pvt. Ltd., A-12, 2nd Floor, Sector 2, Noida-201301 UP, India

When symptoms are suggestive of carcinoid syndrome (unclear in this case), the initial biochemical evaluation of choice is 24-hour urinary excretion of 5-hydroxyindoleacetic acid (5-HIAA). The test has 90% sensitivity and 90% specificity to detect carcinoid syndrome.⁴ Urinary 5-HIAA level in carcinoid syndrome was found to range between 99 and 2,070 mg/day; however, lower levels may be present with foregut and hindgut tumors. Chromogranin and serotonin levels lack sensitivity and specificity; however, it is useful in foregut, rectal, and pancreatic NETs where 5-HIAA level is not usually elevated.⁵ Plasma 5-HIAA level has not been well validated. Serum VIP (VIPoma), glucagon (glucagonoma), gastrin (gastrinoma), and insulin/pro-insulin/C-peptide (insulinoma) levels are helpful in functional pancreatic NETs.

... 24-hour urine 5-HIAA level was 928 mg/day. While awaiting further workup, what treatment should be given for her symptomatic disease?

Management of Symptoms of Hormone Secretion

The most common symptoms from functional NETs are flushing and diarrhea and are associated with elevated urinary 5-HIAA. Since 80% of well-differentiated gastrointestinal (GI)-NETs express SSR, somatostatin analogs (SSA)-like octreotide and lanreotide are highly effective in controlling the symptoms. Initial therapy should be with octreotide of 50 to 750 µg/day, two to four times a day subcutaneously (typically started at 100–150 µg thrice a day with some patients requiring up to 1,500 µg/day, although data limited). This not only provides rapid symptomatic relief but also acts as test dose before initiating long-acting depot. After 1 to 2 weeks on short-acting SSA confirming symptomatic relief and absence of adverse reactions, we initiate long-acting depot injections starting with Octreotide intramuscular (IM) depot injection (octreotide long acting release - LAR) 20 to 30 mg at every 4 weeks. Although dose can be decreased to 10-mg IM at every 4 weeks depending on the response, in our practice, we start at 30-mg IM every 4 weekly dose and usually do not deescalate due to its benefit in tumor stabilization as seen in PROMID randomized clinical trial.⁶ Continue short-acting SSA for the first 2 weeks to maintain therapeutic levels. Temporary exacerbation of symptoms can be treated with additional subcutaneous injections. Lanreotide given 120-mg subcutaneous at every 4 weeks has similar efficacy and tolerability with additional progression-free survival (PFS) benefit and carcinoid syndrome control as noted in CLARINET and ELECT studies.⁷ Phase-II randomized trials have not shown benefit of adding pasireotide, a second-generation SSA along to everolimus.^{8,9}

Telotristat ethyl, a serotonin synthesis inhibitor is Food and Drug Administration (FDA)-approved for the management of carcinoid syndrome diarrhea refractory to SSA and is usually very well tolerated.¹⁰ Low-dose interferon alfa can improve symptoms in patients refractory to SSA.¹¹ However, the treatment is rarely used due to its high toxicity profile of fatigue, depression, and flu-like symptoms. Antidiarrheal therapy with loperamide and/or diphenoxylate-atropine should also be considered. Reducing the SSA intervals, and increasing the dose may offer some benefit.

Initial therapy for insulinomas is carbohydrates and diazoxide which inhibit hormone release. For gastrinomas, oral proton pump inhibitors should be considered. SSA can be used in all refractory disease.¹²

... CT chest showed no disease. Upper and lower GI endoscopic evaluation was unremarkable. What is the initial treatment for this patient?

Treatment

Surgery remains the mainstay for local or locoregional resectable NETs. With selective low surgical risk patients, early surgical exploration can be considered even in the setting of unknown primary.¹³ There is no clear role of adjuvant radiation or chemotherapy and observation is the preferred approach. Surgical resection can also be considered in metastatic disease with refractory symptoms from hormone secretion. Resection of an asymptomatic primary site in the setting of unresectable metastases is generally not recommended.¹⁴

For low-volume and asymptomatic unresectable disease, watchful waiting until symptomatic disease or radiological progression is reasonable and acceptable. Consider CT scan in 3 to 4 months to assess tumor growth rate. Low-grade well-differentiated NETs with very low burden of metastatic disease which is stable on the repeat scan can be watched closely without initiating further systemic therapy and extending the scanning interval to 6 months. However, in symptomatic, functional, moderate-to-high-volume tumors, or tumors with documented radiological growth, treatment initiation should be considered.

SSAs have also been found to provide disease stabilization and PFS benefit.^{6,7} These should be considered as first-line therapy due to their favorable side-effect profile and proven benefit in randomized controlled trials. GETNE-TRASGU nomograms could be used to estimate PFS in patient receiving SSA based on other factors, like tumor location, K_i -67 index, and symptoms; however, it is not widely used in the United States.¹⁵ Benefit of lanreotide and octreotide LAR in advanced well-differentiated nonfunctioning GEP NET was shown in randomized controlled trials (RCTs).¹⁶ ► **Table 1** summarizes some key clinical trials in NETs.

... Monthly octreotide LAR was initiated with symptomatic improvement. CT scan after 4 months showed disease progression in liver and new right upper quadrant abdominal pain and worsening right hip pain. What are the treatment options for this patient now?

Liver predominant metastatic disease can be managed with surgical resection, liver transplant, or nonsurgical liver-directed therapies like ablation and embolotherapies. If liver function is adequate and with the feature of a few dominated large liver metastasis in the absence of diffuse involvement of both liver lobes, surgical resection is an option with the goal of a 70% cytoreduction. This can offer symptom relief and lower rate of disease recurrence.¹⁷ Nonsurgical procedures like radiofrequency ablation, cryoablation, or microwave ablation can be utilized for oligometastatic liver disease or as an adjunct to surgery. Data for external beam radiation in well-differentiated NETs is limited and is often not used in

Table 1 Trials evaluating efficacy of treatments for NETs

Drug	Indication	Trial	Comparison	n	PFS	OS	Comments (reference)	MCBS score ^a
Octreotide (LAR 30-mg IM q28d)	Midgut or UPNF G1, G2 NET	PROMID, phase III	Placebo	85 (1:1)	14.3 vs. 6 mo (HR: 0.34, 95% CI: 0.20–0.59)	84.7 vs. 83.7 mo (p = NS, 107.6 mo if low tumor load)	Did not evaluate SSR positivity. No QoL benefit ⁶	2 (3–1)
Lanreotide (120-mg deep sc q28d)	Midgut, pancreatic or UP NF NET and K ₆₇ <10%, G1 or 2, SSTR+	CLARINET, phase III	Placebo	204 (1:1)	NR vs. 18 mo (HR: 0.47, 95% CI: 0.30–0.73)	No mature data	96% patients had stable disease for 3–6 mo prior to enrollment. PFS estimate 32.8 mo. No QoL benefit ⁷	3
¹⁷⁷ Lu-DOTATATE	Midgut NET with SSTR+, PD	NETTER-1, phase III	Octreotide LAR 60mg	229 (1:1)	NR vs. 8.4 mo (HR: 0.21, 95% CI: 0.13–0.33)	Interim analysis HR for death 0.40, p = 0.0004	Can be considered for any type of SSR+ disease, improved QoL ^{26,28}	4 (3 + 1)
Everolimus + octreotide LAR	Advanced G1, G2 NET	RADIANT-2, phase III	Placebo + octreotide LAR	429 (1:1)	16.4 vs. 11.3 m (HR: 0.77, 95% CI: 0.59–1.0)	Open-label extension (29.2 vs. 35.2 mo)	PFS one-sided log rank test p = 0.026. ^{24,25}	
Everolimus	Pancreatic NET, G1 or 2 PD	RADIANT-3, phase III	Placebo	407 (1:1)	11 versus 4.6 mo (HR 0.35, 95% CI 0.27–0.45)	44 vs. 37.7 mo (p = NS)	85% cross-over limits OS data. No QoL data ⁵³	3
Everolimus + BSC	Midgut and lung NF NET, PD	RADIANT-4, phase III	Placebo + BSC	302 (2:1)	11 vs. 3.9 mo (HR: 0.48, 95% CI: 0.35–0.67)	No mature data	Preserved QoL ²³	3
Sunitinib	Pancreatic NET, PD	Phase III	Placebo	171 (1:1)	11.4 vs. 5.5 mo (HR: 0.42, 95% CI: 0.26–0.66)	38.6 vs. 29.1 mo (p = NS)	69% cross-over limits OS data ³⁰	3
Pasireotide + everolimus	Lung and thymus carcinoids, PD	LUNA, phase II	Everolimus	124 (1:1:1)	11.8 mo PFS gain		No QoL data ⁸	2 (3–1)
Everolimus	Lung and thymus carcinoids, PD	LUNA, phase II	Pasireotide	124 (1:1:1)	12.5 mo PFS gain		No QoL data ⁸	3
Pasireotide	Lung and thymus carcinoids, PD	LUNA, phase II	Everolimus	124 (1:1:1)	8.5 mo PFS gain		No QoL data ⁸	3
Pasireotide+ everolimus	Well-differentiated pancreatic NET, PD	COOPERATE-2, phase II	Everolimus	160 (1:1)	16.8 vs. 16.6 mo (HR: 0.99, 95% CI: 0.64–1.54)	No difference at 22.6 mo	G 3/4 hyperglycemia 37% patients ⁹	
Octreotide + bevacizumab	Advanced G1, G2 NET	SWOG S0518, phase III	Octreotide + interferon	427 (1:1)	16.6 vs. 15.4 mo (HR: 0.90, 95% CI: 0.72–1.12)		Radiologic response rate higher in Bev arm 12 vs. 4% ³⁴	
Pazopanib	Well-differentiated non-pancreatic NET	ALLIANCE A021202, phase III	Placebo	97:74	11.6 vs. 8.5 mo (HR: 0.53, p = 0.0005)	41 vs. 42 mo (HR: 1.13, p = 0.70)	Only abstract available ³¹	

Abbreviations: BSC, best supportive care; CI, confidence interval; G, grade; HR, hazard ratio; IM, intramuscular; sc, subcutaneous; MCBS, magnitude of clinical benefit scale; NET, neuroendocrine tumors; NF, nonfunctioning; NR, not reached; NS, not significant; OS, overall survival; PD, progressive disease; PFS, progression-free survival; QoL, quality of life; SSTR, somatostatin receptor; TTF, time to treatment failure; UP, unknown primary.

^aESMO–MCBC is a tool assessing clinical benefit of treatment based on trial outcomes with positive points for improved QoL and negative points for poor tolerability.

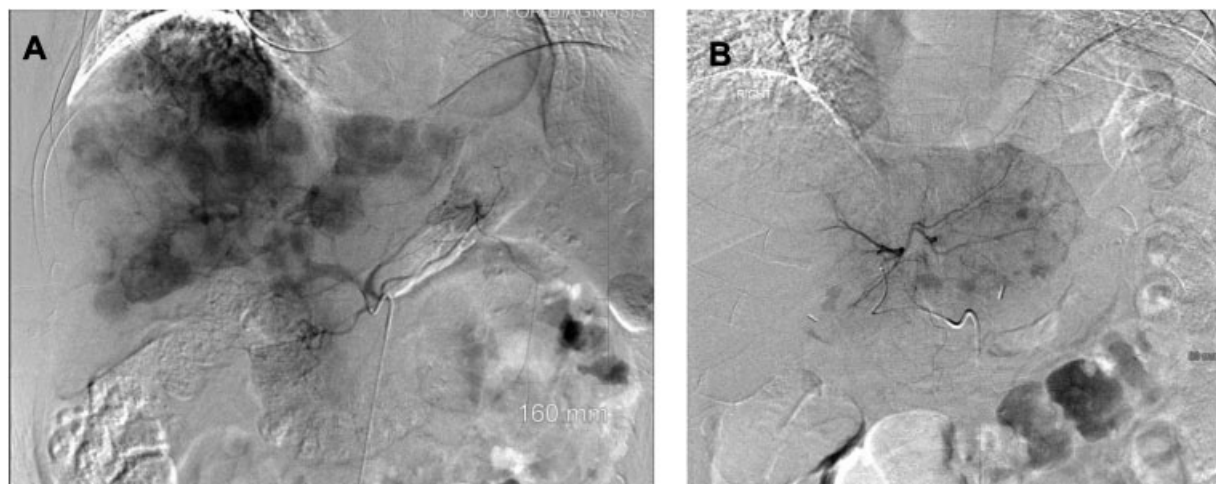


Fig. 1 (A) Celiac artery angiogram demonstrating multiple enhancing metastatic NET throughout the liver. (B) Left hepatic artery angiogram demonstrating enhancing metastatic NET in the left lobe of the liver (representative images; source: Department of Radiology, University of Kentucky). NET, neuroendocrine tumors.

clinical practice. Percutaneous ablative techniques are limited to lesions typically less than 3 cm in size and generally up to four lesions. However, evidence regarding this is supported only by small case studies.^{18,19} Symptomatic or progressive hepatic predominant unresectable disease can also be treated with bland hepatic arterial embolization, chemoembolization or radioembolization or may be considered as a palliative measure. Transarterial bland embolization (our preferred method) is most commonly performed using bland microspheres (►Fig. 1). Transarterial chemoembolization follows the same principles as bland embolization with the addition of a chemotherapeutic agent.²⁰ Radioembolization involves injection of microspheres incorporating the radioisotope Yttrium-90 intra-arterially into the liver.²¹ Although liver transplantation may provide long-term recurrence-free survival in some patients, the majority ultimately develop recurrent disease.²²

... She underwent right and left lobe liver bland embolization without complication. Also received palliative radiation therapy to the right hip. What systemic therapy is ideal now?

Progression

In functional NETs, SSAs may be continued for symptom management. Systemic therapy options on progression include everolimus, sunitinib, or Lu-DOTATATE radionuclide therapy (►Table 1).

Everolimus improves PFS without overall survival (OS) benefit in advanced nonfunctional GI and lung NETs. Grade 1/2 skin, GI side effects, and fatigue were mainly reported.²³ In advanced G1/2 NETs, treatment with octreotide plus everolimus showed clinically meaningful prolongation of PFS but only trended toward statistical significance.²⁴ An open-label extension of the study failed to show any OS benefit as many patients received everolimus off-study.²⁵ In our experience, everolimus is active in NETs and is able to stabilize disease in most patients for several months. Oral mucositis can be prevented with prophylactic steroid mouth

wash, especially during first 4 to 6 weeks of therapy and dose adjustments are often required.

Peptide receptor radionuclide therapy: The evidence of PFS benefit from radiolabeled SSA, Lu-DOTATATE was demonstrated in NETTER-1 trial with an interim analysis, also demonstrating OS benefit.²⁶ Objective response rate was higher among patients on peptide receptor radionuclide therapy PRRT (18 vs. 3%). The most common side effect was nausea (59%) from the amino acid infusions administered during treatment for renal protection. Mild cytopenias were also common with nadir counts expected around 4 to 6 weeks after infusion and resolved by 8 weeks.²⁷ Later studies also showed improved quality of life.²⁸ Patients with G1/2 inoperable and metastatic SSR + NET, with expected survival of >3 months, Karnofsky's performance status >50, sufficient bone marrow reserve, and creatinine clearance >50 mL/min were included in the clinical trial and should be the ideal candidates for this treatment. The Lu-DOTATATE is acceptable as second- or third-line treatment option for metastatic progressive midgut and pancreatic NET with SSR expression, although pancreatic NETs were not studied in NETTER-1 phase-III clinical trial.²⁸ In our practice, we often consider ¹⁷⁷Lu-DOTATATE as second line if patient has symptomatic disease, bone metastasis, or need for cytoreduction. Lu-DOTATATE has the most superior PFS and overall recurrence rate (ORR) data among the approved therapies for NETs. It can be potentially deferred to third- or fourth-line treatment option in patients with mesenteric disease, as PRRT often does not work well for peritoneal metastasis and in young patients due to concern for long-term myelotoxicity and less than 5% long-term risk of myelodysplasias or leukemia.²⁹

The presence of SSR can be determined by diagnostic imaging using a radiolabeled SSA Indium-111 pentetreotide (OctreoScan) or PET scan using Gallium-68 DOTATATE. The higher sensitivity of the later one makes it the preferred option, especially in patients with low tumor volume. Uptake of radiolabeled isotope is predictive of response to therapy.

Tyrosine kinase inhibitors: Although sunitinib, sorafenib, surufatinib, pazopanib, lenvatinib, and cabozantinib have been evaluated in advanced GI-NET in phase-2 and -3 trials, only sunitinib is currently FDA approved for metastatic progressive pancreatic NETs.³⁰⁻³² In lung and GI-NETs, pazopanib showed PFS improvement compared with placebo without OS benefit. Nintedanib, was evaluated in a phase-2 trial for G1/2 NET and was associated with disease stabilization and delayed deterioration of quality of life.³³

Bevacizumab had a PFS benefit when given with octreotide compared to interferon alfa in a phase-II trial.³⁴ However, the confirmatory larger randomized trial with 427 patients failed to show any PFS benefit.³⁵ We do not recommend use of bevacizumab in the management of NETs.

Interferon alfa (IFNa) is recommended only if other treatment options are unavailable due to the relatively low level of evidence of benefit and significant side-effect profile.^{36,37} Low-dose IFNa can reduce symptoms of hormonal hypersecretion and result in tumor stabilization in some patients, but tumor regression is rare.^{34,38,39} IFNa is dosed at 3 to 5 MU three times weekly and dose should be titrated to a leukocyte count of 3,000/ μ L. Pegylated IFN (80–150 μ g per week subcutaneous) has better tolerability compared with IFNa.

Cytotoxic chemotherapy (► **Table 2**) should be considered in patients with progressive metastatic disease with no standard approved treatment options. Regimens that have shown evidence of activity include capecitabine plus temozolomide (CAPTEM) and short-term infusional 5 FU with leucovorin plus oxaliplatin (FOLFOX); however, confirmatory studies are needed.^{40,41} Based on emerging data and toxicity profile, we consider CAPTEM as the initial chemotherapy regimen especially for G2/3 well-differentiated midgut and pancreatic NET after progression on other treatments. The poor PFS from Eastern Cooperative Oncology Group (ECOG) E1281 trial and toxicity of the drugs have questioned the use of 5 FU, streptozocin, and doxorubicin in the treatment of NET.⁴²

Immunotherapy: Data on use of immune checkpoint inhibitors are early but promising (► **Table 2**). Patients with microsatellite unstable tumors and tumor mutational burden ≥ 10 can now receive pembrolizumab based on available evidence.⁴³ DART SWOG 1609 phase-II trial was a basket trial evaluating dual anti-CTLA4 and anti-programmed death 1 (PD1) blockers in rare tumors which showed response mainly in high grade NET. Among the 14 patients with G1/2 NET, 2 had stable disease lasting >6

Table 2 Cytotoxic chemotherapy and immunotherapy regimens studied in NETs

Regimen	Trial (year)	n	CR (%)	PR (%)	SD (%)	mPFS (mo)	mOS (mo)	Comments (ref.)
Capecitabine	Phase II (2011)	19	–	–	68	9.9	36.5	⁵⁴
Capecitabine + oxaliplatin	Phase II (2007)	27	–	30	48	18	32	⁵⁵
Capecitabine + Bev	Phase II (2014)	49	–	18	70	23.4	NR	2-year OS: 85%; 82% ileal primary ⁵⁶
5 FU + streptozocin 5 FU + doxorubicin 9 PD: dacarbazine	Phase II/III ECOG E1281 (2005)	78 85	2.4	16 13.5 8	15.4 15.4	4.5 5.3	24.3 11.9	Grades 1, 2 renal toxicity 35% with STZ ⁴²
FOLFOX + Bev CAPEOX + Bev	Phase II (2016)	36 40	–	25 18	69.4 60	21 19.1	31 42.2	Included 6 NEC. Did not meet 1-degree endpoint. ⁴¹
TMZ	Retrospective (2007)	36	–	14	53	7	16	⁵⁷
TMZ	Retrospective (2013)	31	–	14	52	5.3	23.2	Only bronchial carcinoids ⁵⁸
Capecitabine + TMZ	Retrospective (2013)	18	5.5	55.5	22.2	14	83	Only patients with liver metastasis ⁵⁹
Capecitabine + TMZ	Phase II (2014)	28	11	32	54	>20	NR	Abstract only ⁶⁰
Capecitabine + TMZ	Retrospective (2011)	30	–	70	27	18	–	2-year OS: 92%. Only pancreatic NET ⁶¹
TMZ + Bev	Phase II (2012)	34	–	15	65	11	33.3	Most of the benefit seen in pancreatic NET ⁶²
Pembrolizumab	Phase I KEYNOTE-028 (2020)	41	–	9.7	70.7	5.6/4.5 ^a	–	PDL1 positive tumors only ⁶³
Pembrolizumab	Phase II KEYNOTE -158 (2020)	107	–	3.7	56.1	4.1	24.2	All PR in PDL1 negative tumors. ⁶⁴
Ipilimumab + Nivolumab	Phase II DART SWOG 1609 (2020)	32	3	22	41	4	11	Only nonpancreatic NET. 56% NEC ⁴⁴

Abbreviations: Bev, bevacizumab; CR, complete response; FOLFOX, FU with leucovorin plus oxaliplatin; CAPEOX, capecitabine plus oxaliplatin; NEC, neuroendocrine carcinoma; NET, neuroendocrine tumors; OS, overall survival; PDL1, programmed death ligand 1; PFS, progression-free survival; PR, partial response; SD, stable disease; STZ, streptozocin; TMZ, temozolomide.

^a5.6 months for carcinoids and 4.5 months for pancreatic NET.

months with no complete response (CR) or partial response (PR).⁴⁴

... She was then started on everolimus along with octreotide LAR and dose titrated to 10-mg daily. Two months later, she complained about worsening episodes of sweating, flushing, and dizziness, however, not associated with diarrhea or nausea. Blood work in clinic showed glucose levels of 43 which improved with oral glucose administration. Her abdominal pain and hip pain had improved and did not require any further opioid pain medications. Dietary education was given and continued having frequent laboratory checks.

It is important to understand the side-effect profile of each drug while choosing between two treatments. Although both everolimus and octreotide can inhibit insulin leading to hyperglycemia, especially in diabetic patients, both the drugs can cause paradoxical hypoglycemia by decreasing secretion of hormones for glycogenolysis and gluconeogenesis. SSAs are well tolerated with only one-third of patients developing mild symptoms of bloating, diarrhea, and nausea which improves with time.²⁵ Use of pancreatic enzyme supplementation help resolve some symptoms.⁴⁵ Also, 25% of patients may develop asymptomatic gallstones due to delayed gall bladder emptying. Equally important is to know the complications of SSA discontinuation, like carcinoid crisis, and long-term effects, like carcinoid heart syndrome, making it important to continue SSA beyond progression.

... 3 months later, Ga-68 DOTATATE scan demonstrated improvement in hepatic lesions but new areas of bone involvement including multiple vertebral bodies. She was started on PRRT. She tolerated the treatment well. Repeat Ga-68 DOTATATE scan after four doses of PRRT showed decreased avidity of skeletal lesions and no new lesions.

Case 2

A 52-year-old male initially presented with severe abdominal and back pain. CT showed multiple liver lesions. Fluorodeoxyglucose (FDG)-PET/CT confirmed hypermetabolic liver lesions, pancreatic cystic lesion, T11-L1 vertebral lesions, and portocaval lymphadenopathy. Biopsy of liver lesion showed G3 well-differentiated pancreatic NET with K_i-67 of 30%. He completed four cycles of cisplatin and etoposide with stabilization of disease. However, there was disease progression after 5 months of treatment completion. What is the ideal treatment for this patient?

The recent WHO classification for GEP NETs recognizes a new category of high-grade neuroendocrine neoplasm called G3 well-differentiated NETs.² By definition, G3 NETs will have K_i-67 >20%. However, K_i-67 typically ranges between 20 and 55% for this subset of tumors. G3 NETs often show SSR imaging positivity and are typically of pancreatic origin.⁴⁶ Thus, the clinical behavior is between poorly differentiated neuroendocrine carcinoma and G2 well-differentiated NET.⁴⁷ While 92% high-grade tumors are PET avid, SSR-based imaging may be more helpful in NET G3.^{48,49}

Patients with advanced, well-differentiated G3 NETs do not often respond to platinum-etoposide regimen as with high-grade poorly differentiated NEC.⁵⁰ Hence, treatment with carboplatin or cisplatin with etoposide is preferred only in very aggressive disease and on disease progression. Treatments used in low-to-intermediate grade NETs like capecitabine-temozolomide- or streptozocin-based chemotherapy or sunitinib is preferred as first-line therapy. Whenever possible, these patients should be encouraged to enroll in clinical trials as evidence is not clear due to exclusion of these patients from most of the clinical trials. ECOG-ACRIN EA2142 trial is currently evaluating capecitabine-temozolomide regimen versus cisplatin etoposide in NET G3 (ClinicalTrials.gov ID: NCT02595424). PRRT should be considered in NET G3 with high SSR uptake. Currently, no prospective data exist to support this, as this is extremely rare subset of NETs; however, presence of somatostatin receptor-2 (SSTR-2) makes PRRT a lucrative treatment option. Everolimus showed median progression free survival (mPFS) of 6 months and median overall survival (mOS) of 28 months after drug initiation in a series of 15 patients with NET G3.⁵¹ Most of the patients received it as second-line treatment and median K_i-67 was 30% in this study.

... Patient then received capecitabine plus temozolomide for 6 months. On disease progression, he was switched to everolimus. With SSR positivity on Ga-68 DOTATATE scan, patient was started on Lu-177 DOTATATE but progressed after four cycles. He was then initiated on sunitinib and due to intolerance, transitioned to off-label ipilimumab plus nivolumab.

Practical Recommendations

Following an evidence-based approach will provide maximum clinical benefit for patients without overt expenditure. Some of the practical recommendations are listed below:

- Indolent nature of the disease should be considered when choosing initial therapies. Observation and SSA analogs may be appropriate in asymptomatic stable disease.
- Blood-based biomarkers like chromogranin A have poor sensitivity and specificity.
- Baseline brain imaging is usually not required for staging. Multiphasic liver imaging and oral contrast for bowel evaluation can be done along with SSR-PET/CT in a single setting.
- Routine use of gallium-68-DOTATATE PET/CT for disease monitoring should be avoided. CT/MR are most reliable methods for radiological monitoring. FDG-PET should be used in NEC.
- There are indigenous SSR-directed PRRT therapeutics available in some low- to middle-income countries (LMICs) at a reduced cost, although no comparison on trials are available with standard product.⁵²
- Networking with NET specialist for a second opinion and referring to consensus North American Neuroendocrine Tumor Society (NANETS) and European Society of Neuroendocrine Tumors (ENETS) guidelines is encouraged.

Conclusion

NETs are heterogeneous and rare tumors often posing challenging management dilemmas. A multidisciplinary approach is endorsed for their initial management. The discussion focused on medical management and a detailed analysis of the surgical modalities and nonsurgical procedures are outside the purview of this review. Due to the wide range of clinical behavior and treatment responses with NETs, treatment should always be individualized. Being a rare tumor with limited randomized controlled data available, clinical trial participation is encouraged. We recommend referring to the National Comprehensive Cancer Network (NCCN), NANETS, and ENETS guidelines for updated management options that may change as results from ongoing trials are published.

Financial Disclosures

A.C. receives research support from BMS, Clovis Oncology, EMD Serono, Nanopharmaceuticals, Tersera, ECS Progastrin. Advisor: Novartis, Ipsen, TerSera, Lexicon, Seneca Therapeutics, and ECS Progastrin. R.A.R. serves as a speaker for Merck & Co., Inc., Advanced Accelerator Applications, Genentech, Inc., AstraZeneca, and Ipsen Biopharmaceuticals, Inc. Consultant for Curium Pharma, Advanced Accelerator Applications, AstraZeneca, Ipsen Biopharmaceuticals and Novartis Pharmaceuticals, Corp. Research funding from Aadi Biosciences, and Merck & Co., Inc. Other coauthors do not have relevant disclosures.

Conflict of Interest

L.A. reports grants from Lexicon Pharmaceuticals, Inc., Entrinsic Health, Inc., and personal fees from Sun Pharmaceuticals, Inc., during the conduct of the study. A.C. reports grants from BMS, EMD Serono, Nanopharmaceuticals, and Clovis; other from Ipsen, Novartis, Lexicon, TerSera; and nonfinancial support from ECS Progastrin, during the conduct of the study. R.A.R. reports personal fees from Ipsen Biopharmaceuticals, Novartis, Curium, Advanced Accelerator Applications, Genentech, AstraZeneca, grants and personal fees from Merck, and grants from Aadi Bioscience, outside the submitted work.

References

- 1 Yao JC, Hassan M, Phan A, et al. One hundred years after "carcinoid": epidemiology of and prognostic factors for neuroendocrine tumors in 35,825 cases in the United States. *J Clin Oncol* 2008;26(18):3063–3072
- 2 Nagtegaal ID, Odze RD, Klimstra D, et al. WHO Classification of Tumours Editorial Board. The 2019 WHO classification of tumours of the digestive system. *Histopathology* 2020;76(02):182–188
- 3 Catena L, Bichisao E, Milione M, et al. Neuroendocrine tumors of unknown primary site: gold dust or misdiagnosed neoplasms? *Tumori* 2011;97(05):564–567
- 4 Sjöblom SM. Clinical presentation and prognosis of gastrointestinal carcinoid tumours. *Scand J Gastroenterol* 1988;23(07):779–787
- 5 Seregni E, Ferrari L, Bajetta E, Martinetti A, Bombardieri E. Clinical significance of blood chromogranin A measurement in neuroendocrine tumours. *Ann Oncol* 2001;12(Suppl 2):S69–S72
- 6 Rinke A, Wittenberg M, Schade-Brittinger C, et al. PROMID Study Group. Placebo-controlled, double-blind, prospective, randomized study on the effect of octreotide LAR in the control of tumor growth in patients with metastatic neuroendocrine midgut tumors (PROMID): results of long-term survival. *Neuroendocrinology* 2017;104(01):26–32
- 7 Vinik AI, Wolin EM, Liyanage N, Gomez-Panzani E, Fisher GA ELECT Study Group. Evaluation of lanreotide depot/autogel efficacy and safety as a carcinoid syndrome treatment (elect): a randomized, double-blind, placebo-controlled trial. *Endocr Pract* 2016;22(09):1068–1080
- 8 Ferolla P, Brizzi MP, Meyer T, et al. Efficacy and safety of long-acting pasireotide or everolimus alone or in combination in patients with advanced carcinoids of the lung and thymus (LUNA): an open-label, multicentre, randomised, phase 2 trial. *Lancet Oncol* 2017;18(12):1652–1664
- 9 Kulke MH, Ruzsniwski P, Van Cutsem E, et al. A randomized, open-label, phase 2 study of everolimus in combination with pasireotide LAR or everolimus alone in advanced, well-differentiated, progressive pancreatic neuroendocrine tumors: COOPER-ATE-2 trial. *Ann Oncol* 2019;30(11):1846
- 10 Kulke MH, Hörsch D, Caplin ME, et al. Telotristat ethyl, a tryptophan hydroxylase inhibitor for the treatment of carcinoid syndrome. *J Clin Oncol* 2017;35(01):14–23
- 11 Frank M, Klose KJ, Wied M, Ishaque N, Schade-Brittinger C, Arnold R. Combination therapy with octreotide and alpha-interferon: effect on tumor growth in metastatic endocrine gastroenteropancreatic tumors. *Am J Gastroenterol* 1999;94(05):1381–1387
- 12 Frankton S, Bloom SR. Gastrointestinal endocrine tumours. *Glu-cagonomas*. *Baillieres Clin Gastroenterol* 1996;10(04):697–705
- 13 Wang YZ, Chauhan A, Rau J, et al. Neuroendocrine tumors (NETs) of unknown primary: is early surgical exploration and aggressive debulking justifiable? *Linchuang Zhongliuxue Zazhi* 2016;5(01):4
- 14 Lesurtel M, Nagorney DM, Mazzaferro V, Jensen RT, Poston GJ. When should a liver resection be performed in patients with liver metastases from neuroendocrine tumours? A systematic review with practice recommendations. *HPB (Oxford)* 2015;17(01):17–22
- 15 Carmona-Bayonas A, Jiménez-Fonseca P, Lamarca Á, et al. Prediction of progression-free survival in patients with advanced, well-differentiated, neuroendocrine tumors being treated with a somatostatin analog: the GETNE-TRASGU study. *J Clin Oncol* 2019;37(28):2571–2580
- 16 Caplin ME, Pavel M, Ćwikła JB, et al. CLARINET Investigators. Lanreotide in metastatic enteropancreatic neuroendocrine tumors. *N Engl J Med* 2014;371(03):224–233
- 17 Glazer ES, Tseng JF, Al-Refaie W, et al. Long-term survival after surgical management of neuroendocrine hepatic metastases. *HPB (Oxford)* 2010;12(06):427–433
- 18 Wessels FJ, Schell SR. Radiofrequency ablation treatment of refractory carcinoid hepatic metastases. *J Surg Res* 2001;95(01):8–12
- 19 Berber E, Flesher N, Siperstein AE. Laparoscopic radiofrequency ablation of neuroendocrine liver metastases. *World J Surg* 2002;26(08):985–990
- 20 Kennedy A, Bester L, Salem R, Sharma RA, Parks RW, Ruzsniwski P. NET-Liver-Metastases Consensus Conference. Role of hepatic intra-arterial therapies in metastatic neuroendocrine tumours (NET): guidelines from the NET-Liver-Metastases Consensus Conference. *HPB (Oxford)* 2015;17(01):29–37
- 21 Kennedy AS, Dezarn WA, McNeillie P, et al. Radioembolization for unresectable neuroendocrine hepatic metastases using resin 90Y-microspheres: early results in 148 patients. *Am J Clin Oncol* 2008;31(03):271–279
- 22 Moris D, Tsilimigras DI, Ntanasis-Stathopoulos I, et al. Liver transplantation in patients with liver metastases from

- neuroendocrine tumors: a systematic review. *Surgery* 2017;162(03):525–536
- 23 Yao JC, Fazio N, Singh S, et al. RAD001 in Advanced Neuroendocrine Tumours, Fourth Trial (RADIANT-4) Study Group. Everolimus for the treatment of advanced, non-functional neuroendocrine tumours of the lung or gastrointestinal tract (RADIANT-4): a randomised, placebo-controlled, phase 3 study. *Lancet* 2016;387(10022):968–977
 - 24 Pavel ME, Hainsworth JD, Baudin E, et al. RADIANT-2 Study Group. Everolimus plus octreotide long-acting repeatable for the treatment of advanced neuroendocrine tumours associated with carcinoid syndrome (RADIANT-2): a randomised, placebo-controlled, phase 3 study. *Lancet* 2011;378(9808):2005–2012
 - 25 Pavel ME, Baudin E, Öberg KE, et al. Efficacy of everolimus plus octreotide LAR in patients with advanced neuroendocrine tumor and carcinoid syndrome: final overall survival from the randomized, placebo-controlled phase 3 RADIANT-2 study. *Ann Oncol* 2017;28(07):1569–1575
 - 26 Strosberg J, El-Haddad G, Wolin E, et al. NETTER-1 Trial Investigators. Phase 3 trial of 177Lu-Dotatate for midgut neuroendocrine tumors. *N Engl J Med* 2017;376(02):125–135
 - 27 Brabander T, van der Zwan WA, Teunissen JJ, et al. Long-term efficacy, survival, and safety of [177Lu-DOTA0Tyr3]octreotate in patients with gastroenteropancreatic and bronchial neuroendocrine tumors. *Clin Cancer Res* 2017;23(16):4617–4624
 - 28 Strosberg J, Wolin E, Chasen B, et al. NETTER-1 Study Group. Health-related quality of life in patients with progressive midgut neuroendocrine tumors treated with 177Lu-Dotatate in the phase III NETTER-1 trial. *J Clin Oncol* 2018;36(25):2578–2584
 - 29 Sonbol MB, Halfdanarson TR, Hilal T. Assessment of therapy-related myeloid neoplasms in patients with neuroendocrine tumors after peptide receptor radionuclide therapy: a systematic review. *JAMA Oncol* 2020;6(07):1086–1092
 - 30 Kulke MH, Lenz HJ, Meropol NJ, et al. Activity of sunitinib in patients with advanced neuroendocrine tumors. *J Clin Oncol* 2008;26(20):3403–3410
 - 31 Grande E, Capdevila J, Castellano D, et al. Pazopanib in pretreated advanced neuroendocrine tumors: a phase II, open-label trial of the Spanish Task Force Group for Neuroendocrine Tumors (GETNE). *Ann Oncol* 2015;26(09):1987–1993
 - 32 Capdevila J, Fazio N, Lopez CL, et al. Final results of the TALENT trial (GETNE1509): a prospective multicohort phase II study of lenvatinib in patients (pts) with G1/G2 advanced pancreatic (panNETs) and gastrointestinal (giNETs) neuroendocrine tumors (NETs). *J Clin Oncol* 2019;37(15suppl):4106
 - 33 Iyer RV, Konda B, Fountzilias C, et al. Multicenter phase 2 trial of nintedanib in advanced nonpancreatic neuroendocrine tumors. *Cancer* 2020;126(16):3689–3697
 - 34 Yao JC, Phan A, Hoff PM, et al. Targeting vascular endothelial growth factor in advanced carcinoid tumor: a random assignment phase II study of depot octreotide with bevacizumab and pegylated interferon alpha-2b. *J Clin Oncol* 2008;26(08):1316–1323
 - 35 Yao JC, Guthrie KA, Moran C, et al. Phase III prospective randomized comparison trial of depot octreotide plus interferon Alfa-2b versus depot octreotide plus bevacizumab in patients with advanced carcinoid tumors: SWOG S0518. *J Clin Oncol* 2017;35(15):1695–1703
 - 36 Strosberg JR, Halfdanarson TR, Bellizzi AM, et al. The North American Neuroendocrine Tumor Society Consensus Guidelines for surveillance and medical management of midgut neuroendocrine tumors. *Pancreas* 2017;46(06):707–714
 - 37 Pavel M, O'Toole D, Costa F, et al. Vienna Consensus Conference participants. ENETS consensus guidelines update for the management of distant metastatic disease of intestinal, pancreatic, bronchial neuroendocrine neoplasms (NEN) and NEN of unknown primary site. *Neuroendocrinology* 2016;103(02):172–185
 - 38 Faiss S, Pape UF, Böhmig M, et al. International Lanreotide and Interferon Alfa Study Group. Prospective, randomized, multicenter trial on the antiproliferative effect of lanreotide, interferon alfa, and their combination for therapy of metastatic neuroendocrine gastroenteropancreatic tumors—the International Lanreotide and Interferon Alfa Study Group. *J Clin Oncol* 2003;21(14):2689–2696
 - 39 Arnold R, Rinke A, Klose KJ, et al. Octreotide versus octreotide plus interferon-alpha in endocrine gastroenteropancreatic tumors: a randomized trial. *Clin Gastroenterol Hepatol* 2005;3(08):761–771
 - 40 Al-Toubah T, Morse B, Strosberg J. Capecitabine and temozolomide in advanced lung neuroendocrine neoplasms. *Oncologist* 2020;25(01):e48–e52
 - 41 Kunz PL, Balise RR, Fehrenbacher L, et al. Oxaliplatin-fluoropyrimidine chemotherapy plus bevacizumab in advanced neuroendocrine tumors: an analysis of 2 phase II trials. *Pancreas* 2016;45(10):1394–1400
 - 42 Sun W, Lipsitz S, Catalano P, Mailliard JA, Haller DG Eastern Cooperative Oncology Group. Phase II/III study of doxorubicin with fluorouracil compared with streptozocin with fluorouracil or dacarbazine in the treatment of advanced carcinoid tumors: Eastern Cooperative Oncology Group Study E1281. *J Clin Oncol* 2005;23(22):4897–4904
 - 43 Marabelle A, Le DT, Ascierto PA, et al. Efficacy of pembrolizumab in patients with noncolorectal high microsatellite instability/mismatch repair-deficient cancer: results from the phase II KEYNOTE-158 study. *J Clin Oncol* 2020;38(01):1–10
 - 44 Patel SP, Othus M, Chae YK, et al. A phase II basket trial of dual anti-CTLA-4 and anti-PD-1 blockade in rare tumors (DART SWOG 1609) in patients with nonpancreatic neuroendocrine tumors. *Clin Cancer Res* 2020;26(10):2290–2296
 - 45 Newman CB, Melmed S, Snyder PJ, et al. Safety and efficacy of long-term octreotide therapy of acromegaly: results of a multicenter trial in 103 patients—a clinical research center study. *J Clin Endocrinol Metab* 1995;80(09):2768–2775
 - 46 Coriat R, Walter T, Terris B, Couvelard A, Ruszniewski P. Gastroenteropancreatic Well-differentiated grade 3 neuroendocrine tumors: review and position statement. *Oncologist* 2016;21(10):1191–1199
 - 47 Basturk O, Yang Z, Tang LH, et al. The high-grade (WHO G3) pancreatic neuroendocrine tumor category is morphologically and biologically heterogeneous and includes both well differentiated and poorly differentiated neoplasms. *Am J Surg Pathol* 2015;39(05):683–690
 - 48 Walter T, Tougeron D, Baudin E, et al. CEPD investigators. Poorly differentiated gastro-entéro-pancreatic neuroendocrine carcinomas: Are they really heterogeneous? Insights from the FFCD-GTE national cohort. *Eur J Cancer* 2017;79:158–165
 - 49 Heetfeld M, Chougnat CN, Olsen IH, et al. other Knowledge Network members. Characteristics and treatment of patients with G3 gastroenteropancreatic neuroendocrine neoplasms. *Endocr Relat Cancer* 2015;22(04):657–664
 - 50 Hijioka S, Hosoda W, Matsuo K, et al. Rb Loss and KRAS mutation are predictors of the response to platinum-based chemotherapy in pancreatic neuroendocrine neoplasm with grade 3: a Japanese multicenter pancreatic NEN-G3 study. *Clin Cancer Res* 2017;23(16):4625–4632
 - 51 Panzuto F, Merola E, Pavel ME, et al. Stage IV gastro-entéro-pancreatic neuroendocrine neoplasms: a risk score to predict clinical outcome. *Oncologist* 2017;22(04):409–415
 - 52 Basu SPR, Ranade R, Thapa P. Peptide receptor radionuclide therapy in the management of neuroendocrine tumors (Neoplasms)*: Fundamentals and salient clinical practice points for medical oncologists. *Indian J Med Paediatr Oncol* 2019;40:165–167
 - 53 Yao JC, Pavel M, Lombard-Bohas C, et al. Everolimus for the treatment of advanced pancreatic neuroendocrine tumors: overall survival and circulating biomarkers from the randomized, phase III RADIANT-3 study. *J Clin Oncol* 2016;34(32):3906–3913

- 54 Medley L, Morel AN, Farrugia D, et al. Phase II study of single agent capecitabine in the treatment of metastatic non-pancreatic neuroendocrine tumours. *Br J Cancer* 2011;104(07):1067–1070
- 55 Bajetta E, Catena L, Procopio G, et al. Are capecitabine and oxaliplatin (XELOX) suitable treatments for progressing low-grade and high-grade neuroendocrine tumours? *Cancer Chemother Pharmacol* 2007;59(05):637–642
- 56 Mitry E, Walter T, Baudin E, et al. Bevacizumab plus capecitabine in patients with progressive advanced well-differentiated neuroendocrine tumors of the gastro-intestinal (GI-NETs) tract (BETTER trial)—a phase II non-randomised trial. *Eur J Cancer* 2014;50(18):3107–3115
- 57 Ekeblad S, Sundin A, Janson ET, et al. Temozolomide as monotherapy is effective in treatment of advanced malignant neuroendocrine tumors. *Clin Cancer Res* 2007;13(10):2986–2991
- 58 Crona J, Fanola I, Lindholm DP, et al. Effect of temozolomide in patients with metastatic bronchial carcinoids. *Neuroendocrinology* 2013;98(02):151–155
- 59 Fine RL, Gulati AP, Krantz BA, et al. Capecitabine and temozolomide (CAPTEM) for metastatic, well-differentiated neuroendocrine cancers: The Pancreas Center at Columbia University experience. *Cancer Chemother Pharmacol* 2013;71(03):663–670
- 60 Fine RL, Gulati AP, Tsushima D, et al. Prospective phase II study of capecitabine and temozolomide (CAPTEM) for progressive, moderately, and well-differentiated metastatic neuroendocrine tumors. *J Clin Oncol* 2014;32(Suppl 3 179
- 61 Strosberg JR, Fine RL, Choi J, et al. First-line chemotherapy with capecitabine and temozolomide in patients with metastatic pancreatic endocrine carcinomas. *Cancer* 2011;117(02):268–275
- 62 Chan JA, Stuart K, Earle CC, et al. Prospective study of bevacizumab plus temozolomide in patients with advanced neuroendocrine tumors. *J Clin Oncol* 2012;30(24):2963–2968
- 63 Mehnert JM, Bergsland E, O'Neil BH, et al. Pembrolizumab for the treatment of programmed death-ligand 1-positive advanced carcinoid or pancreatic neuroendocrine tumors: results from the KEYNOTE-028 study. *Cancer* 2020;126(13):3021–3030
- 64 Strosberg J, Mizuno N, Doi T, et al. Efficacy and safety of pembrolizumab in previously treated advanced neuroendocrine tumors: results from the phase II KEYNOTE-158 study. *Clin Cancer Res* 2020;26(09):2124–2130