



Mesenteric Lengthening in Pouch Surgery: Review of Surgical Techniques

Melissa Kyriakos Saad^{1,3} Elias Fiani^{2,3} Elias Saikaly^{1,3}

¹General Surgery Department, Saint George Hospital University Medical Center, Beirut, Lebanon

²Gastroenterology Department, Saint George Hospital University Medical Center, Beirut, Lebanon

³Department of Surgery, University of Balamand, Beirut, Lebanon

Address for correspondence Elias Saikaly, MD, General Surgery Department, Saint George Hospital University Medical Center, Beirut, Lebanon; University of Balamand, Beirut, Lebanon (e-mail: dreliassaikaly@gmail.com).

J Coloproctol 2021;41(4):438–442.

Abstract

Described for the first time in the medical literature in 1978 by Parks and Nicholls, total proctocolectomy with ileal-pouch anal anastomosis (IPAA) is nowadays the procedure of choice for patients with ulcerative colitis in whom the medical therapy has, a selected group of patients with Crohn's disease, and for patients with familial adenomatous polyposis. Despite the advances in medical treatment regarding inflammatory bowel disease, up to 30% of patients still require surgery, and restorative proctocolectomy and IPAA are the mainstay of the surgical treatment. It is considered a demanding and technically-challenging procedure, with the main challenge being the performance of a tension-free IPAA; the main reason for failure of the tension-free anastomosis is a shortened mesentery. With particular attention to detail, sufficient length can be achieved to enable a safe anastomosis in most patients. Herein, we describe the available techniques to lengthen the mesentery of the ileal pouch to perform an easy-to-reach tension-free anastomosis.

Keywords

- ▶ pouch surgery
- ▶ mesenteric lengthening

Introduction

Described for the first time in the medical literature in 1978 by Parks and Nicholls,¹ total proctocolectomy with ileal-pouch anal anastomosis (IPAA) is nowadays the procedure of choice for patients with ulcerative colitis in whom the medical therapy has failed, a selected group of patients with Crohn's disease, with no evidence of anorectal disease, and those with familial adenomatous polyposis. Restorative proctocolectomy with IPAA removes the entire colon and the rectum, and creates an internal pelvic reservoir for intestinal content using the ileum. This is associated with the preservation of the anal sphincters; hence, normal bowel function and continence are expected. Although it is considered a

technically-challenging and morbid operation, its durability has been well documented;^{2,3} therefore, it is an attractive option for a certain subset of patients.

Total proctocolectomy with IPAA is considered a demanding and technically-challenging procedure with the best surgical outcome depending highly upon the surgical expertise and good patient selection. The most challenging part of the surgery is the performance of an easy-to-reach tension-free anastomosis with a good blood supply. Failure to do so will result in an increased risk of complications, starting with minor subclinical leaks to major anastomotic leak and anastomotic dehiscence, leading to pelvic sepsis, pouch ischemia and consequently loss of the ileal pouch.

received
February 19, 2021
accepted after revision
August 6, 2021

DOI <https://doi.org/10.1055/s-0041-1736466>.
ISSN 2237-9363.

© 2021. Sociedade Brasileira de Coloproctologia. All rights reserved.

This is an open access article published by Thieme under the terms of the Creative Commons Attribution-NonDerivative-NonCommercial-License, permitting copying and reproduction so long as the original work is given appropriate credit. Contents may not be used for commercial purposes, or adapted, remixed, transformed or built upon. (<https://creativecommons.org/licenses/by-nc-nd/4.0/>)

Thieme Revinter Publicações Ltda., Rua do Matoso 170, Rio de Janeiro, RJ, CEP 20270-135, Brazil

Pelvic sepsis and pouch ischemia are considered life-threatening complications,^{4,5} and the most feared complication in pouch surgery. In fact, it has been reported that the rates of ileoanal anastomotic complications, in particular those of leaks and stricture formation, range from 3% to 7% and from 5% to 15% respectively, depending on the anastomotic technique (hand-sewn versus stapled), and on the technique used for pouch construction.^{6,7} Studies^{8,9} have shown that up to 25% of patients are affected to some degree, and are at greater risk of developing pouch-related fistula. Furthermore, early postoperative pelvic sepsis is responsible for significant functional disturbances¹⁰ and impaired quality of life in the long term.^{8,11} Therefore, the performance of a tension-free anastomosis is of utmost importance, and the key for successful healing is a good blood supply. The absence of these factors is considered the major cause of anastomotic complications in pouch surgery.¹² These two conditions are more commonly associated with the presence of a short mesentery. In such cases, gaining more length in the ileal mesentery will translate directly into reduced tension on the IPAA. However, the performance of an easy-to-reach, tension-free anastomosis is not always possible due to a shortened and retracted mesentery in some patients, especially in obese patients, tall patients with a narrow pelvis, patients with previous abdominal surgeries and adhesions on the mesentery, patients with previous small-bowel resections, and those with familial adenomatous polyposis and mesenteric desmoid tumors. Therefore, completion of the IPAA is neither always possible nor always advisable. As noted by Chun et al.,¹³ the intraoperative abandonment of IPAA has never been reported in large series despite its universal occurrence. However, profound knowledge of different mesenteric lengthening techniques is vital, as this will result in lower rates of IPAA abandonment.

Assessing the Reach of the Ileal Pouch

In most patients, the reach of the ileal pouch will be close to adequate, with further simple measures taken to gain the extra length needed for tension-free, easy-to-reach IPAA. The initial landmark used to estimate if the ileal pouch will reach the anal canal in a tension-free fashion is the pubic bone. However, there is no consensus in the medical literature about which border of the pubic symphysis should be used to perform an easy-to-reach and tension-free anastomosis knowing that there is a 2-cm difference between the superior and inferior borders of the pubic symphysis. In fact, cadaveric studies have shown that if the apex of the ileal pouch can be pulled down 6 cm below the pubic symphysis, then the ileal pouch will reach the dentate line in 100% of the cases; if the pouch apex can be pulled down 4 cm below the pubic symphysis, then it will reach the dentate line in 55% of the cases; and finally, if it can be pulled down 2 cm below the pubic symphysis, there is a 33% chance that it will reach the dentate line.⁷ Furthermore, Chu et al.¹⁴ reported that, if the apex of the proposed ileal pouch can be pulled 3 cm to 4 cm below the inferior edge of the pubic symphysis, then the surgeon can feel confident that there will be an adequate

reach for a tension-free IPAA. Furthermore, Smith et al.⁷ found that the pouch could always be sutured to the dentate line without tension when the terminal ileum reached 6 cm over the inferior edge of the pubic symphysis. Additionally, in 2016, Ohira et al.¹⁵ showed that the distance between the ileocolic artery and the anal verge is a useful predictor of the difficulty in pulling the ileal pouch down to the anus during restorative proctocolectomy. In summary, the reach of the ileal pouch is considered adequate if the planned apex reaches the inferior border of the pubic symphysis; however, the trial descent of the pouch to the anus represents a better estimate for a tension-free anastomosis, and should be always performed. However, the challenge is how the adequate length can be obtained when the pouch does not reach the pubic symphysis.

Techniques for Pouch Lengthening

The key to success in total proctocolectomy with IPAA is to obtain a sufficient mesenteric length in the ileal pouch to enable the performance of an easy-to-reach, tension-free anastomosis. Knowing that only 23% of the patients admitted for total proctocolectomy and IPAA will not need additional mesenteric pouch lengthening,¹⁶ a multitude of techniques have been described in the medical literature^{14,17,18} to gain the required mesenteric length. In fact, the excessive tension on the anastomosis and a reduced blood supply to the pouch remain the major causes of anastomotic complications.¹² Hence, knowledge of all mesenteric-lengthening techniques available and used is crucial to surgeons dealing with pouch surgery.

Complete Mobilization of the Ileum

An easy-to-perform step, with no compromise of blood supply to the ileal pouch is the complete mobilization of the ileum all the way to the inferior edge of the pancreas, until the second and third portions of the duodenum are in complete view. This is performed by meticulously dividing the visceral peritoneum at the base of the ileal mesentery from the distal ileum to the level of the duodenum on the right and left sides of the mesentery. The peritoneum must be divided to the level of the superior mesenteric artery and vein.

The Mesenteric Stepladder Incision Technique

The mesenteric stepladder incision technique (► Fig. 1) is considered a simple and reliable method for mesenteric lengthening without compromising the blood supply to the ileal pouch. It is particularly useful in patients with adhesions and mesenteric fibrosis due to previous abdominal surgeries. It is performed with multiple perpendicular transverse incisions, measuring 3 cm in length at 2- to 4-cm intervals, on both sides of peritoneum covering the superior mesenteric artery. Baig et al.¹⁷ reported that this technique provides an additional mesenteric extension of ~ 4 cm to 8 cm. In many clinics, this technique has been performed routinely without any reported complications, such as pouch necrosis or mesenteric hemorrhage, for a long time.¹⁷

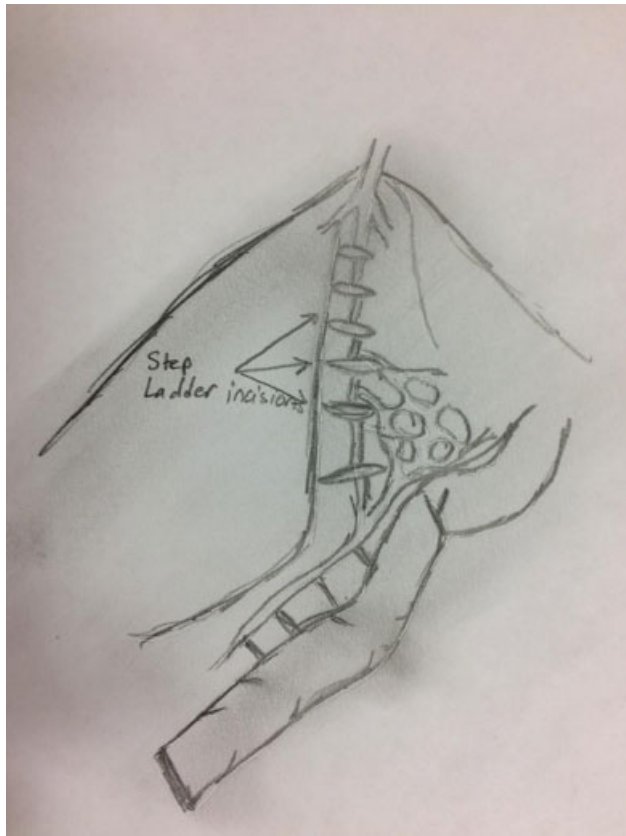


Fig. 1 Stepladder incisions.

Pouch Folding

In patients in whom the created ileal pouch reach is critical, pouch folding either pouch anterior with mesentery posterior or pouch posterior with mesentery anterior makes a difference. When the ileal pouch reach is not predicted to be a concern, folding the pouch posteriorly is attractive, as it fits the sacral hollow perfectly well. However, when the reach of the ileal pouch is of concern, the pouch should be folded anteriorly, as this will result in ~ 1 cm of extra length when compared with the pouch folded to lie posteriorly.¹⁸

Pouch Configuration

Pouch configurations include the J pouch, the S pouch and the W pouch (→Fig. 2). The double-stapled ileal J pouch is currently the standard.^{19,20} The J pouch is considered the preferred pouch configuration due to the ease of performance and the optimal functional outcomes, although the S pouch and the W pouch are larger and may have better early function.^{21,22} In patients in whom the reach of the ileal pouch is critical an S pouch is an attractive alternative. In fact, the performance of an S pouch may result in an additional gain of 2 cm to 3 cm.⁷

Vascular Pedicle Divisions

Vascular pedicle divisions involve meticulous dissection and a careful selective divisions of the mesenteric blood vessels. These include the division of the superior mesenteric pedicle (→Fig. 3) and the preservation of the ileocolic pedicle, the division of the ileocolic pedicle while preserving the superior

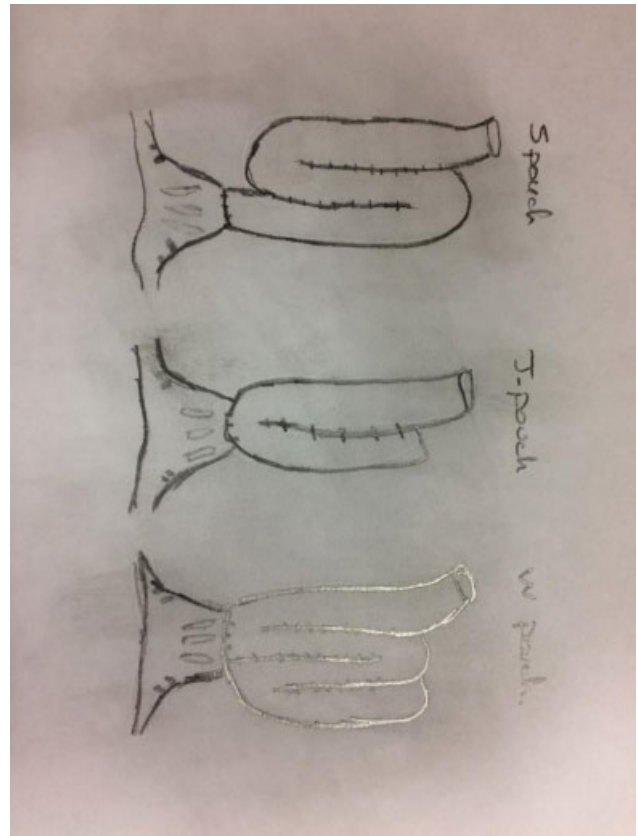


Fig. 2 Pouch configuration.

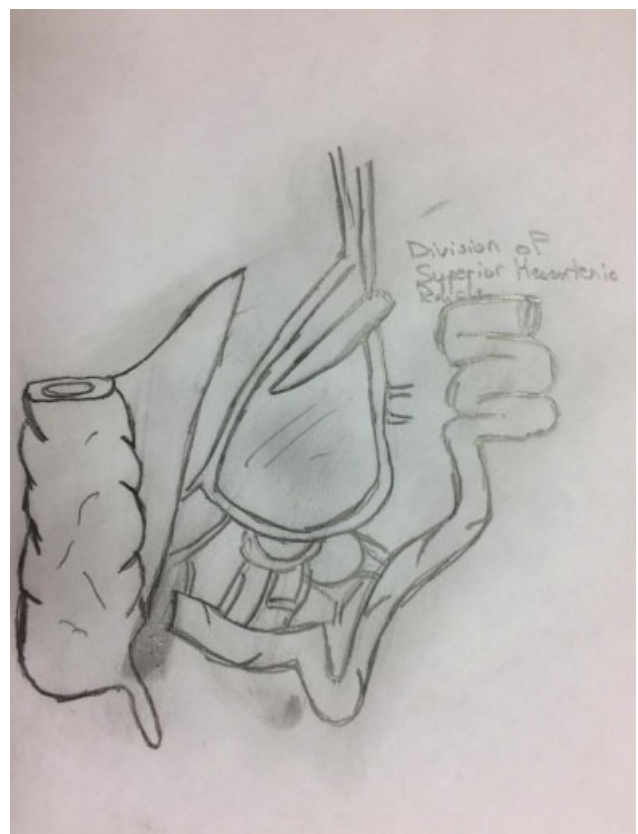


Fig. 3 Division of the superior mesenteric pedicle.

mesenteric pedicle, the division of the superior mesenteric and ileocolic pedicles, or the division of selected individual ileal mesenteric vessels. Before the division, identification of the point of tension hindering the reach of the ileal pouch will guide the surgeon as to whether the ileocolic pedicle, the superior mesenteric pedicle, both pedicles, or selective individual ileal mesenteric vessels need to be ligated. In most cases, the main reason hindering an easy to reach ileal pouch is either the ileocolic artery or the ileal branch of the superior mesenteric artery. Hence, dividing and ligating the shorter artery, be it the ileocolic artery or the ileal branch of the superior mesenteric artery, is sufficient. In fact, cadaveric studies^{4,23} have shown average gains of 3 cm and 6.5 cm in mesenteric length after ligation of the ileocolic artery or the distal superior mesenteric artery respectively. In an anatomical study, Martel et al.²⁴ confirmed that the division of the superior mesenteric pedicle significantly increased the length of the mesentery compared with the ligation of the ileocolic vessels (6.5 versus 3 cm). These studies strongly supported the results previously found by other authors^{16,23} regarding the supremacy of the division of the mesenteric pedicle. Furthermore, in a previous study, Martel et al.⁴ observed that high ligation of the superior mesenteric vessels was not associated with worse outcomes compared with ligation of the ileocolic pedicle.

On the other hand, Burnstein et al.⁵ concluded that division of the ileocolic or the superior mesenteric vessel is not a must nor always necessary, and that division and ligation of two or three smaller ileal mesenteric vessels between the primary and secondary arcades is usually sufficient, and will result in ~2 cm to 5 cm of extra length. Furthermore, Rottoli et al.²⁵ stated that it is the standard practice in their tertiary care center to perform ligation of the superior mesenteric vessel in every patient when a hand-sewn anastomosis is required after ensuring adequate blood supply to the terminal ileum. In contrast, opponents of this selective ligation and division argue that such a division carries a risk of segmental necrosis,^{23,24} and the best single maneuver to enhance mesenteric lengthening is division of the ileocolic or superior mesenteric arteries, which will result in extra length between 4 cm and 7 cm.^{16,23,24} Moreover, Goes et al.²⁶ reported a technique to preserve the middle colic vessels along with the marginal vascular arcade all the way to the ileal branch of the ileocolic artery. Thus, both the ileocolic vessels and the distal third of the superior mesenteric artery can be sacrificed. In a cadaveric dissection²⁴, this technique produced a mean addition of 3.6 cm (range: 2.5 cm to 5 cm) of mesenteric length over the conventional technique of taking only one vessel. This technique may prove to be very useful, pending further studies on live patients.

Conclusion

Total proctocolectomy with IPAA is a demanding and technically-challenging procedure, and it may be associated with perioperative morbidity, including pelvic sepsis and anastomotic leak, which will directly translate into

poorer long-term pouch function and, hence, poorer quality of life. Performance of an adequate IPAA is dependent on whether the ileal pouch can reach the anus without tension. Hence, obtaining an adequate length of the mesentery is essential for the success of the entire procedure. Surgeons dealing with pouch surgery should be familiar with all the techniques used to increase reach and decrease tension in IPAA.

Conflict of Interests

The authors have no conflict of interests to declare.

References

- 1 Parks AG, Nicholls RJ. Proctocolectomy without ileostomy for ulcerative colitis. *BMJ* 1978;2(6130):85–88
- 2 Kelly KA. Anal sphincter-saving operations for chronic ulcerative colitis. *Am J Surg* 1992;163(01):5–11
- 3 McIntyre PB, Pemberton JH, Wolff BG, Beart RW, Dozois RR. Comparing functional results one year and ten years after ileal pouch-anal anastomosis for chronic ulcerative colitis. *Dis Colon Rectum* 1994;37(04):303–307
- 4 Martel P, Majery N, Savigny B, Sezeur A, Gallot D, Malafosse M. Mesenteric lengthening in ileoanal pouch anastomosis for ulcerative colitis: Is high division of the superior mesenteric pedicle a safe procedure? *Dis Colon Rectum* 1998;41(07):862–866, discussion 866–867
- 5 Burnstein MJ, Schoetz DJ Jr, Collier JA, Veidenheimer MC. Technique of mesenteric lengthening in ileal reservoir-anal anastomosis. *Dis Colon Rectum* 1987;30(11):863–866
- 6 Lewis WG, Kuzu A, Sagar PM, Holdsworth PJ, Johnston D. Stricture at the pouch-anal anastomosis after restorative proctocolectomy. *Dis Colon Rectum* 1994;37(02):120–125
- 7 Smith L, Friend WG, Medwell SJ. The superior mesenteric artery. The critical factor in the pouch pull-through procedure. *Dis Colon Rectum* 1984;27(11):741–744
- 8 Ross H, Steele SR, Varma M, et al; Standards Practice Task Force of the American Society of Colon and Rectal Surgeons. Practice parameters for the surgical treatment of ulcerative colitis. *Dis Colon Rectum* 2014;57(01):5–22
- 9 Fazio VW, Kiran RP, Remzi FH, et al. Ileal pouch anal anastomosis: analysis of outcome and quality of life in 3707 patients. *Ann Surg* 2013;257(04):679–685
- 10 Selvaggi F, Sciaudone G, Limongelli P, et al. The effect of pelvic septic complications on function and quality of life after ileal pouch-anal anastomosis: a single center experience. *Am Surg* 2010;76(04):428–435
- 11 Papadopoulos VN, Michalopoulos A, Apostolidis S. Ileal pouch dysfunction. *Tech Coloproctol* 2010;14(Suppl 1):S83–S85
- 12 Ballantyne GH, Pemberton JH, Beart RW Jr, Wolff BG, Dozois RR. Ileal J pouch-anal anastomosis. Current technique. *Dis Colon Rectum* 1985;28(03):197–202
- 13 Chun HK, Smith LE, Orkin BA. Intraoperative reasons for abandoning ileal pouch-anal anastomosis procedures. *Dis Colon Rectum* 1995;38(03):273–275
- 14 Chu DI, Tognelli J, Kartheuser AH, Dozois EJ. Strategy for the difficult-to-reach ileal pouch-anal anastomosis: technical steps of an in vivo application of a mesenteric-lengthening technique. *Tech Coloproctol* 2015;19(11):705–709
- 15 Ohira G, Miyauchi H, Narushima K, et al. Predicting difficulty in extending the ileal pouch to the anus in restorative proctocolectomy: investigation of a simple predictive method using computed tomography. *Colorectal Dis* 2017;19(01):O34–O38
- 16 Thirlby RC. Optimizing results and techniques of mesenteric lengthening in ileal pouch-anal anastomosis. *Am J Surg* 1995; 169(05):499–502

- 17 Baig MK, Weiss EG, Nogueras JJ, Wexner SD. Lengthening of small bowel mesentery: stepladder incision technique. *Am J Surg* 2006; 191(05):715–717
- 18 Uraiqat AA, Byrne CM, Phillips RK. Gaining length in ileal-anal pouch reconstruction: a review. *Colorectal Dis* 2007;9(07):657–661
- 19 Kirat HT, Remzi FH, Kiran RP, Fazio VW. Comparison of outcomes after hand-sewn versus stapled ileal pouch-anal anastomosis in 3,109 patients. *Surgery* 2009;146(04):723–729, discussion 729–730
- 20 Remzi FH, Fazio VW, Delaney CP, et al. Dysplasia of the anal transitional zone after ileal pouch-anal anastomosis: results of prospective evaluation after a minimum of ten years. *Dis Colon Rectum* 2003;46(01):6–13
- 21 Michelassi F, Lee J, Rubin M, et al. Long-term functional results after ileal pouch anal restorative proctocolectomy for ulcerative colitis: a prospective observational study. *Ann Surg* 2003;238(03):433–441, discussion 442–445
- 22 McHugh SM, Diamant NE, McLeod R, Cohen Z. S-pouches vs. J-pouches. A comparison of functional outcomes. *Dis Colon Rectum* 1987;30(09):671–677
- 23 Cherqui D, Valleur P, Perniceni T, Hautefeuille P. Inferior reach of ileal reservoir in ileoanal anastomosis. Experimental anatomic and angiographic study. *Dis Colon Rectum* 1987;30(05):365–371
- 24 Martel P, Blanc P, Bothereau H, Malafosse M, Gallot D. Comparative anatomical study of division of the ileocolic pedicle or the superior mesenteric pedicle for mesenteric lengthening. *Br J Surg* 2002;89(06):775–778
- 25 Rottoli M, Tanzanu M, Lanci AL, Gentilini L, Boschi L, Poggioli G. Mesenteric lengthening during pouch surgery: technique and outcomes in a tertiary centre. *Updates Surg* 2021;73(02):581–586
- 26 Goes RN, Nguyen P, Huang D, Beart RW Jr. Lengthening of the mesentery using the marginal vascular arcade of the right colon as the blood supply to the ileal pouch. *Dis Colon Rectum* 1995;38(08):893–895