



Anatomic Reconstruction of the Triangular Fibrocartilage Complex for the Treatment of Chronic Instability of the Distal Radioulnar Joint. A Systematic Review

Reconstrucción anatómica del complejo fibrocartilago triangular para el tratamiento de la inestabilidad crónica de la articulación radiocubital distal. Una revisión sistemática

Ignacio Miranda¹ Francisco J. Lucas² Vicente Carratalá² Joan Ferràs-Tarragó¹
Francisco J. Miranda³

¹ Orthopedic Surgery and Traumatology Service, Hospital Arnau de Vilanova, Valencia, España

² Hand and Upper Limb Surgery Unit, Hospital Quirónsalud Valencia, Valencia, España

³ Department of Physiology, Universitat de València, Valencia, España

Address for correspondence Ignacio Miranda, MD, PhD, Servicio de Cirugía Ortopédica y Traumatología, Hospital Arnau de Vilanova, Calle Sant Climent 12, 46015 Valencia, España (e-mail: nachomigo@hotmail.com).

Rev Iberam Cir Mano 2021;49(2):e97–e104.

Abstract

Keywords

- ▶ chronic distal radioulnar joint instability
- ▶ triangular fibrocartilage complex
- ▶ tendon plasty
- ▶ reconstruction of distal radioulnar ligaments

Introduction Peripheral injuries of the triangular fibrocartilage complex (TFCC) can produce pain and instability of the distal radioulnar joint (DRUJ). There are several techniques for the reconstruction of the TFCC. The aim of the present paper was to summarize the tendon plasties of the DRUJ ligaments for the anatomic reconstruction of TFCC, to analyze the surgical techniques, and to evaluate their outcomes.

Methods In order to perform a systematic review, we searched in the literature the terms *DRUJ instability OR chronic distal radioulnar joint instability OR distal radioulnar tendon plasty*.

Results In total, 11 articles with level of evidence IV (case series) were retrieved. Most studies achieved good results, with recovery of wrist stability, improvement of the pain, and increase in grip strength in the functionality tests. In the historical evolution of the published series, wrist surgeons tried to perform a more anatomical plasty, with a more stable fixation and less invasive techniques.

received
October 26, 2020
accepted
March 31, 2021

DOI <https://doi.org/10.1055/s-0041-1736570>.
ISSN 1698-8396.

© 2021. SECMA Foundation. All rights reserved.

This is an open access article published by Thieme under the terms of the Creative Commons Attribution-NonDerivative-NonCommercial-License, permitting copying and reproduction so long as the original work is given appropriate credit. Contents may not be used for commercial purposes, or adapted, remixed, transformed or built upon. (<https://creativecommons.org/licenses/by-nc-nd/4.0/>)

Thieme Revinter Publicações Ltda., Rua do Matoso 170, Rio de Janeiro, RJ, CEP 20270-135, Brazil

Resumen

Palabras clave

- ▶ inestabilidad crónica de la articulación radiocubital distal
- ▶ complejo fibrocartilago triangular
- ▶ plastia tendinosa
- ▶ reconstrucción de los ligamentos radiocubitales distales

Conclusion The Adams procedure continues to be a valid and reproducible technique for the treatment of chronic DRUJ instability. If wrist arthroscopy and implants are available and surgeons have been technically trained, the authors recommend an arthroscopy-assisted technique, or, if possible, an all-arthroscopic TFCC reconstruction with implant fixation of the plasty in its anatomical points of insertion. Comparative studies between open and arthroscopic TFCC reconstruction techniques are needed.

Introducción Las lesiones periféricas del complejo fibrocartilago triangular (CFCT) pueden provocar dolor e inestabilidad de la articulación radiocubital distal (ARCD). El objetivo de este trabajo fue recoger todas las plastias tendinosas de los ligamentos de la ARCD para la reconstrucción anatómica del CFCT, analizar las técnicas quirúrgicas, y evaluar sus resultados.

Métodos Para hacer una revisión sistemática, se realizó una búsqueda en inglés en la literatura con los términos *DRUJ instability* o *chronic distal radioulnar joint instability* o *distal radioulnar tendon plasty*.

Resultados Se encontraron once artículos de nivel de evidencia IV (series de casos). La mayoría de los trabajos consiguieron buenos resultados, con recuperación de la estabilidad de la muñeca, mejoría del dolor, y aumento de la fuerza de prensa en las pruebas de funcionalidad. En la evolución histórica de las series publicadas, los cirujanos de muñeca intentan realizar plastias cada vez más anatómicas, con una fijación más estable y con técnicas cada vez menos invasivas.

Conclusión El procedimiento de Adams continúa siendo una técnica válida y reproducible para el tratamiento de la inestabilidad crónica de la ARCD. Si la artroscopia de muñeca y los implantes están disponibles y los cirujanos están técnicamente capacitados, los autores recomiendan una técnica asistida por artroscopia o, si es posible, una técnica íntegramente artroscópica para la reconstrucción del CFCT, con una fijación con implantes de la plastia en sus puntos de inserción anatómicos. Son necesarios estudios comparativos entre la reconstrucción anatómica del CFCT mediante técnica abierta y artroscópica.

Introduction

The triangular fibrocartilage complex (TFCC) has two functional components, the distal component (dc) and the proximal component (pc). The dc-TFCC is formed by the ulnocarpal ligaments and the articular fibrocartilage, and its function is to support and contain the ulnar margin of the carpus (like a hammock).¹ The pc-TFCC is composed of the volar and dorsal distal radioulnar ligaments, and it is the primary stabilizer of the distal radioulnar joint (DRUJ) during pronosupination of the forearm. The origin of the pc-TFCC is in the ulnar fovea rather than in the ulnar styloid, and it is attached to the most dorsal and volar limits of the sigmoid notch of the radius.^{1,2} The isometric area of the pc-TFCC is considered to be located in the ulnar fovea.¹

In 1989, Palmer³ published a classification of TFCC injuries, and described 2 basic categories: class 1, or traumatic injuries; and class 2, or degenerative injuries. These categories were subdivided into types, depending on the location of the tear and the presence or absence of cartilage injury.³ Type 1-B injuries are traumatic tears of the ulnar periphery of the TFCC. When there is an isolated rupture of the dc-TFCC, DRUJ

stability is preserved. However, when a type 1-B TFCC tear involves disruption of the pc-TFCC, the DRUJ becomes unstable. If the cartilage is well preserved, these type 1-B injuries with DRUJ instability are then classified as "Class 4: Non-repairable peripheral TFCC tear",^{4,5} in the 5-class treatment-oriented classification proposed by Atzei and Luchetti.⁵ Injury to the TFCC is a frequent cause of pain on the ulnar side and disability in the wrist; and if it is misdiagnosed or unsuccessfully treated, it may cause DRUJ chronic instability.⁵

Reconstruction of the TFCC is indicated if the TFCC injury is not repairable, if there are no degenerative changes in the DRUJ (healthy articular cartilage), and if the interosseous membrane is functional (to rule out Essex-Lopresti injury).^{4,6} Numerous procedures have been described to restore the stability of the DRUJ through nonanatomic reconstructions. These techniques include extra-articular plasty,^{7,8} direct radioulnar fixation plasty to the joint,⁹⁻¹¹ or dynamic muscular transfers using the pronator quadratus.^{12,13} These techniques are less effective than the anatomic reconstruction of the DRUJ ligaments using a tendon graft, which tries

to reproduce the anatomy and biomechanics of the native TFCC. There are several tendon plasties for anatomic reconstruction of TFCC, which are difficult to be understood, differentiated, reproduced and compared.

The aim of this paper was to summarize the different tendon plasties of the DRUJ ligaments for the anatomic reconstruction of the TFCC, to analyze the surgical techniques, and to evaluate their outcomes.

Methods

A systematic literature review was performed in accordance with the Preferred Reporting Items for Systematic Reviews and Meta-Analyses (PRISMA)¹⁴ and the guidelines of the Quality of Reporting of Meta-analyses (QUOROM) group.¹⁵ On May 25th, 2020, a search in the PubMed and Cochrane Library databases was made with the terms *distal radioulnar tendon plasty* OR *DRUJ instability* OR *chronic distal radioulnar joint instability*. The database search resulted in a total of 356 articles, which were reviewed by 2 senior orthopedic surgeons. the references of the selected articles were also cross-checked (►Fig. 1).

Eligibility criteria: 1) articles which presented results of the treatment of DRUJ chronic instability with some kind of tendon plasty for TFCC anatomic reconstruction; and 2) full text available in English or Spanish.

Exclusion criteria: 1) review articles; 2) single-case-report articles; 3) letters to the editor or editorial comments; 4)

book chapters; 5) Conference papers or posters; and 6) cadaveric studies.

The surgical techniques and outcomes described in the articles which fulfilled those criteria were analyzed.

Results

In total, 11 articles with level of evidence IV were retrieved. All of them presented case series (with 9 to 95 patients) of chronic DRUJ instability treated by an anatomic reconstruction using a tendon plasty. The previous papers¹⁶⁻¹⁸ described different types of open surgery reconstruction of the TFCC. In the last few years, case series of open surgery have been published,^{19,20} as well as arthroscopic reconstruction series of assisted open surgery.^{21,22} The surgical techniques are schematized in ►Fig. 2 and summarized in ►Table 1. The technique developed by Carratalá Baixauli et al.⁶ was excluded from this systematic review because, although it has already been published, only partial and preliminary results have been presented for 4 patients at 6 months. In this study,⁶ the score on the Visual Analog Scale (VAS) was of 1.75 (range: 0 to 4) after 6 months; the VAS score before the surgery was of 6.75 (range: 4 to 8). The score on the Quick Disabilities of the Arm, Shoulder and Hand (DASH) questionnaire before the surgery was of 44.70 (range: 36.25 to 54); after 6 months, it was of 11.18 (range: 6.75 to 18); the results on the Mayo Wrist Score after 6 months of follow-up were: excellent (95) in 1 case; good (90 and 85) in 2 cases; and fair (70) in 1 case.

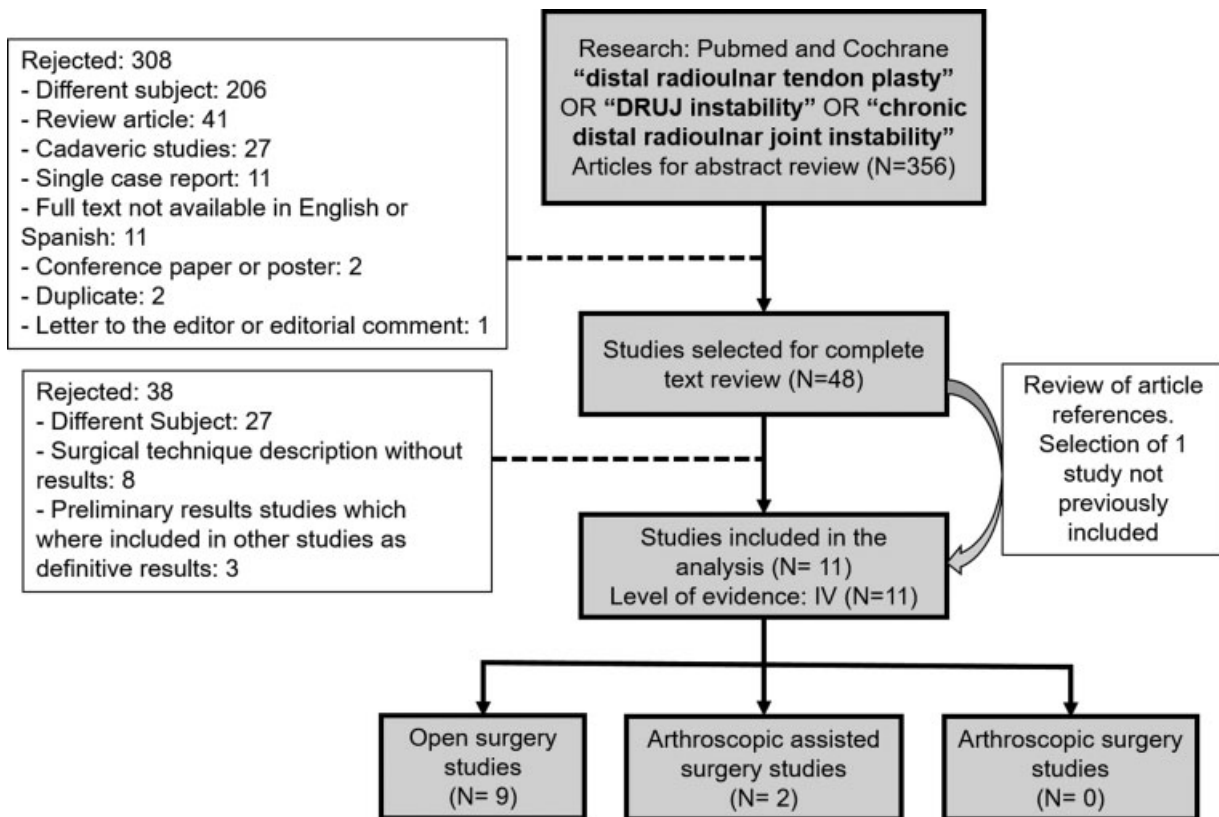


Fig. 1 Flowchart of the process of search and inclusion of studies.

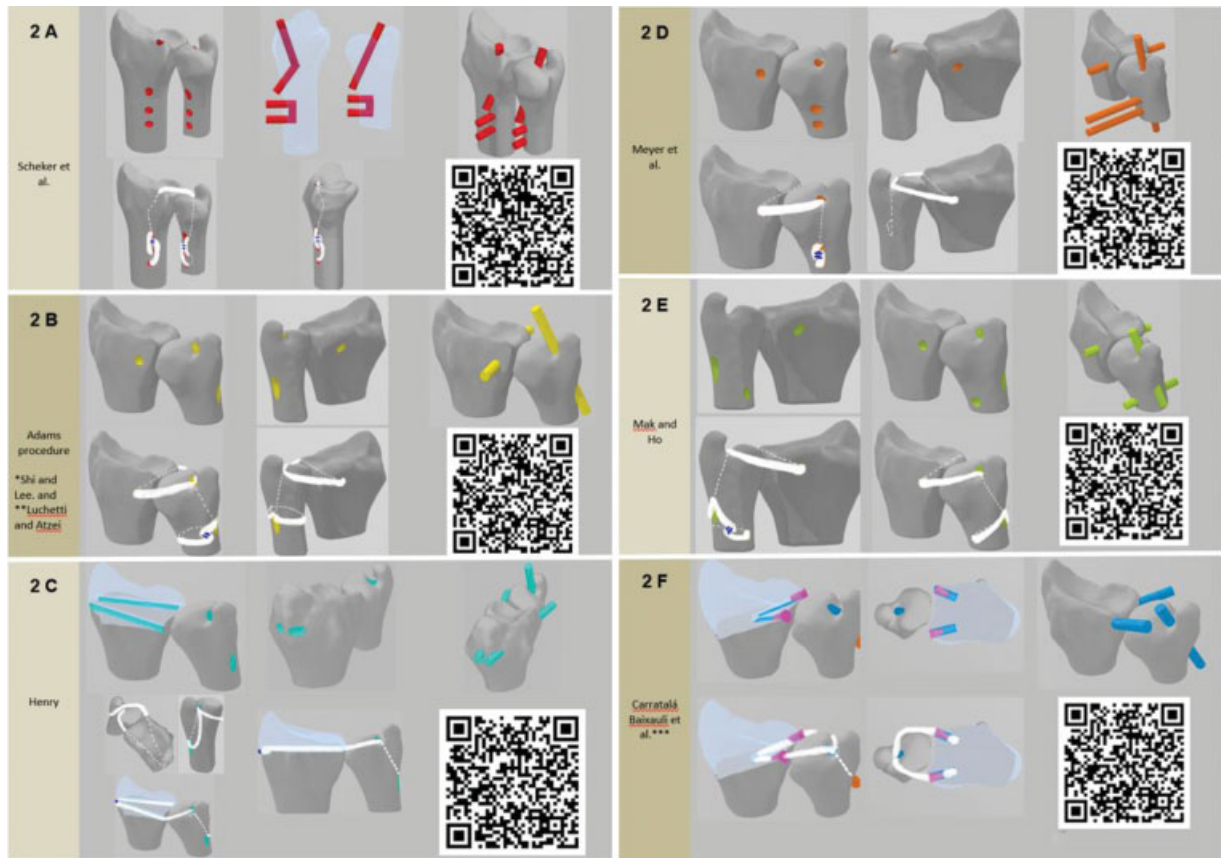


Fig. 2 Schemes of the TFCC reconstructions. The QR codes show the placement of the tunnels in 3D. (A). Scheker et al.¹⁶ technique. (B). Adams procedure.^{17–20,24} *The Shih and Lee²⁵ technique modifies the Adams procedure regarding the fixation of the plasty, which was sutured with polydioxanone suture (PDS) without an ulnar bundle. **The Luchetti and Atzei²² technique modifies the Adams procedure regarding the fixation of the plasty, which is fixed in the ulna tunnel with an interference screw. (C) Henry²⁷ technique. (D). Meyer et al.²⁶ technique. (E) Chu-Kay Mak and Ho²¹ technique. (F). Carratalá Baixauli et al.⁶ technique. ***The Carratalá Baixauli et al.⁶ technique was excluded from the present systematic review because, although it has already been published, only partial and preliminary results have been presented for four patients at six months.

The outcomes were compiled: the pre- and postoperative ranges of motion (ROMs) are shown in ►Table 2; the pain and grip strength, in ►Table 3; and stability, functional scores and complications, in ►Table 4.

Discussion

In total, 11 case series were retrieved, 9 with open surgery techniques (2 of them with previous diagnostic wrist arthroscopy), and 2 with arthroscopically-assisted procedures (►Table 1). In 1994, Scheker et al.¹⁶ published their series of 15 patients treated with a distal radioulnar plasty of the palmaris longus performed by open surgery; the authors reconstructed the dorsal distal radioulnar ligament (►Fig. 2A), obtaining a disappearance of the pain in 80% of the patients, with increased strength and without losing mobility compared with the preoperative ROM. In 2000, Adams²³ described his technique for anatomic reconstruction of the dorsal and volar radioulnar ligaments with a palmaris longus autograft (►Fig. 2B), and he published the results together with Berger in 2002.¹⁷ After that, four teams of surgeons performed the Adams procedure in their series,^{18–20,24} and most of the later-designed techniques retrieved in the present systematic review are modifications of

this procedure,^{21,22,25,26} which is currently the gold-standard treatment for chronic DRUJ instability.

The 5 case series with reconstruction using the Adams technique (with 9, 14, 16, 74 and 95 patients) achieved good results in 86% to 100% of the patients, with recovery of wrist stability (78% to 100%), disappearance of the pain or mild pain (76% to 89%) and increase in grip strength in the functionality tests.^{17–20,24} With this technique, most authors described a decrease in pronosupination compared with the preoperative ROM.^{17,19,20} Meyer et al.²⁶ described a method of anatomic TFCC reconstruction which only differs from the Adams technique regarding the fixation of the ends of the tendon graft; it may enable a higher tension on the tendon graft and a more resistant fixation, thus enabling a less strict and shorter immobilization. They drilled two oblique tunnels in the ulna instead of the unique oblique tunnel in the Adams technique, and tied and secured the ends of the tendon graft over the bone bridge between the two drill holes²⁶ (►Fig. 2D); the outcomes were similar to those described with the Adams procedure.

In the series by Shih and Lee,²⁵ all patients underwent wrist arthroscopic examination, and the lesions of the TFCC tears were identified, classified and, if indicated, a TFCC reconstruction was performed a week after with an extensor

Table 1 Case series of tendon plasties of the DRUJ

Authors	Year	N	Kind of Surgery	Graft	Tunnels and fixation
Scheker et al. ¹⁶	1994	15	Open surgery	Palmaris longus, plantaris, or extensor digitorum communis autograft	3 in the radius; 3 in the ulna; fixation of the graft with 2 sutures over the bone bridge (radius, ulna)
Adams and Berger ¹⁷	2002	14	Open surgery	Palmaris longus autograft	Posteroanterior in the radius; oblique in the ulna; fixation of the graft around the ulnar neck
Teoh & Yam ¹⁸	2005	9	Open surgery	Palmaris longus autograft	Posteroanterior in the radius; oblique in the ulna; fixation of the graft around the ulnar neck
Shih and Lee ²⁵	2005	37	Diagnostic arthroscopy + open surgery (1 week after)	Extensor carpi ulnaris autograft	Posteroanterior in the radius; oblique in the ulna
Seo et al. ²⁴	2009	16	Open surgery	Palmaris longus autograft	Posteroanterior in the radius; oblique in the ulna; fixation of the graft around the ulnar neck
Henry ²⁷	2012	25	Diagnostic arthroscopy + open surgery	Palmaris longus autograft	2 in the sigmoid notch in the radius; oblique in the ulna; suture over the bone bridge (radius)
Luchetti and Atzei ²²	2017	11	Arthroscopy-assisted surgery	Palmaris longus	Posteroanterior in the radius; oblique in the ulna; linterference screw in the ulna
Meyer et al. ²⁶	2017	48	Open surgery	Palmaris longus, flexor carpi ulnaris, or long toe extensor autograft	Posteroanterior in the radius; oblique in the ulna; fixation of the graft with suture over the bone bridge (ulna)
Chu-Kay Mak and Ho ²¹	2017	28	Arthroscopy-assisted surgery	Palmaris longus autograft	Posteroanterior in the radius, oblique in the ulna; + posteroanterior in the ulna; suture over the bone bridge (ulna)
Kootstra et al. ²⁰	2018	22	Open surgery	Palmaris longus, toe extensor, or plantaris autograft	Posteroanterior in the radius; oblique in the ulna; Fixation of the graft around the ulnar neck.
Gillis et al. ¹⁹	2019	95	Open surgery	Autograft (44%); allograft (56%). Palmaris longus, plantaris, triceps surae, gracilis, or semitendinosus	Posteroanterior in the radius; oblique in the ulna; fixation of the graft around the ulnar neck, or fixation with anchors or with interference screw

carpi ulnaris (ECU) tendon graft with tunnels similar to those of the Adams procedure; despite the inconvenience of performing two surgeries, the outcomes were not better than those obtained with the Adams technique. Henry²⁷ proposed a wrist arthroscopy, and, once the injury is confirmed, to proceed with open incisions and free tendon graft reconstruction with the palmaris longus; he replicated the true anatomic points of insertion both at the ulnar fovea and at the volar and dorsal margins of the sigmoid notch; the ends of the graft were tied to each other over the bone bridge of the radius (–Fig. 2C). He reported restoration of the DRUJ stability in 100% of the cases, an improvement in the DASH score, and no decrease in ROM.

In the last few years, two series using arthroscopically-assisted techniques were published.^{21,22} When compared with the open techniques for tendon-graft reconstruction,

these techniques have some potential benefits: 1) visualization of the TFCC tear and assessment of reparability; 2) preservation of the capsule of the ulnar wrist and soft tissues; and 3) exposition of the fovea, which enables the surgeon to open the tunnel under direct view at the isometric insertion point of the fovea. Additionally, these techniques enable the surgeon to make smaller incisions to perform the reconstruction, thus minimizing soft-tissue scarring, fibrosis and stiffness. Luchetti and Atzei²² performed the same tunnels as those of the Adams procedure, but fixed the graft in the ulna tunnel with an interference screw. Chu-Kay Mak and Ho²¹ (part of this series was previously published by Tse et al.²⁸) performed the Adams technique, but made a second tunnel at the distal ulna, which is used to tie the ends of the graft to each other over the bone bridge of the ulna (–Fig. 2E). The authors²¹ reported results comparable to those of the conventional open technique

Table 2 Range of motion (ROM) outcomes

Authors	Preoperative ROM (degrees)						Postoperative ROM (degrees)						Pre- vs. postoperative
	F	E	P	S	RD	UD	F	E	P	S	RD	UD	
Scheker et al. ¹⁶	64	62	81	92	20	31	61	62	82	80	24	31	↓ S
Adams and Berger ¹⁷			80	80.5					72	70			↓ S and P; F, E and UD unchanged
Teoh and Yam ¹⁸	Nearly all patients with full S and P ROMs						P-S (in % of contralateral): 92%						
Shih and Lee ²⁵													
Seo et al. ²⁴	69.7	76.9	76.6	83.9	15	29.1	70.9	72.8	76.3	82.5	13.4	30.3	No difference
Henry ²⁷	53	53	66	65			61	62	71	74			No difference
Luchetti and Atzei ²²	64	70	85	81			60	67	80	81			No difference
Meyer et al. ²⁶	70.2	71.5	76.4	78.5	18.8	35.7	67.1	70.1	67.9	66.1	19.6	32.9	↓ S and P
Chu-Kay Mak and Ho ²¹	In % of contralateral: P-S: 84.7%; E-F: 77.1%; RD-UD: 71.4%						In % of contralateral: P-S: 91.1%; E-F: 83.7%; RD-UD: 83.5%						Improved ROM
Kootstra et al. ²⁰							67	71,8	73	71	17,7	30,9	↓ S and P vs. healthy wrist
Gillis et al. ¹⁹	53.9	57	76.9	69.7	18.3	27.2	52.1	58.6	71.3	62.7	19.8	28.6	↓ S and P

Abbreviations: E, extension; F, flexion; P, pronation; RD, radial deviation; S, supination; UD, ulnar deviation; ↓, decrease.

Table 3 Pain and grip strength outcomes

Authors	Preoperative			Postoperative			Pre- vs. postoperative
	Pain	Grip strength (Kg)	Grip strength (% contralateral or healthy wrist)	Pain	Grip strength (Kg)	Grip Strength (%) contralateral or healthy wrist)	
Scheker et al. ¹⁶	100% chief complaint	17	53.2	86% none; 14% minor discomfort	29.6	80.5	↓ pain; ↑ grip strength
Adams and Berger ¹⁷				64% none; 36% mild pain	Improved 11 kg	85	↑ grip strength
Teoh and Yam ¹⁸			55	66% mild pain		86	↑ grip strength
Shih and Lee ²⁵			35 to 40	No patients with pain in the daily activities		65 to 90	↑ grip strength
Seo et al. ²⁴	PRWE (pain): 23.1/50	31.6		PRWE (pain): 9.1/50	36.7		↓ pain; ↑ grip strength
Henry ²⁷			57			79	No differences
Luchetti and Atzei ²²	VAS (rest): 4; VAS (stress): 9	13	54	VAS (rest) 2; VAS (stress) 4	20	96	↓ pain; ↑ grip strength
Meyer et al. ²⁶	VAS: 2.6	24.6	63.9	VAS: 1.3	31	80.3	↓ pain; ↑ grip strength
Chu-Kay Mak and Ho ²¹	VAS: 5.9		58.6	VAS: 3		71.6	↓ pain; ↑ grip strength
Kootstra et al. ²⁰					38.6	89.7	
Gillis et al. ¹⁹	33.7% severe pain; 65.3% moderate pain; 1.1% mild pain	21.7	68.5	27.5% no pain; 48,4% mild pain; 22% moderate pain	24.2	77.4	↓ pain; ↑ grip strength

Abbreviations: PRWE, Patient-Rated Wrist Evaluation; VAS, Visual Analogue Scale; ↓, decrease; ↑, increase.

(stability, grip strength, and functionality); however, in addition to the cosmetic advantage, they achieved better ROM, through the preservation of soft-tissue and capsular integrity, and accelerated rehabilitation.

A new all-arthroscopic TFCC reconstruction technique has been described;⁶ however, it has been excluded from the present systematic review because the results have not been published yet. Carratalá Baixauli et al.⁶ performed a free

Table 4 Stability, functional scores, complications and satisfaction outcomes

Authors	Stability (% of patients)	Functional scores			Complications and satisfaction
		Preoperative	Postoperative	Pre- vs. postoperative	
Scheker et al. ¹⁶					1 postblock brachial plexus neuritis; 1 mild reflex sympathetic dystrophy; 1 recurrence of instability
Adams and Berger ¹⁷	86				2 recurrence of instability; 2 paraesthesia (healed)
Teoh and Yam ¹⁸	78	MMWS: 66	MMWS: 87	Improvement	1 paraesthesia (healed); 1 stiffness
Shih and Lee ²⁵			MMWS: 29.7% excellent; 59.5% good; 10.8% fair		3 superficial wound infections
Seo et al. ²⁴	75	MMWS: 72.5; DASH: 34.5; PRWE: 39.2	MMWS: 92.8; DASH: 10.5; PRWE: 11.2	Improvement	3 laxity; 1 subluxation
Henry ²⁷	100	DASH: 62	DASH: 7	Improvement	
Luchetti and Atzei ²²	91	MWS: 52; DASH: 48; PRWE: 70	MWS: 82; DASH: 25; PRWE: 33	Improvement	1 fracture of the ulnar styloid (healed); 3 ulnar paraesthesia (healed); 1 graft rupture; 1 instability recurrence
Meyer et al. ²⁶	91				2 subluxation persisted; 2 recurrent instability
Chu-Kay Mak and Ho ²¹		MWS: 58	MWS: 79	Improvement	35,7%: 4 graft rupture; 3 nerve injuries (healed); 3 discomfort over scar; 1 breakage KW
Kootstra et al. ²⁰	100		DASH: 13.1; PRWHE: 20.3		4% recurrent instability
Gillis et al. ¹⁹	90.8	MMWS 59.6	MMWS 68.9	Improvement	31.6%: neuroapraxia, neuroma, recurrent instability, degenerative disease; satisfaction: VAS: 8.1 (86.3%)

Abbreviations: DASH, Disabilities of the Arm, Shoulder, Hand questionnaire; MMWS, Modified Mayo Wrist Score; MWS, Mayo Wrist Score; PRWE, Patient-Rated Wrist and Hand Evaluation Score; KW, kirschnir wire.

tendon graft reconstruction, with the palmaris longus replicating the true anatomic points of insertion both at the ulnar fovea and at the volar and dorsal margins of the sigmoid notch, with two blind tunnels in the radius and an oblique ulnar tunnel; they fixed the graft with tree interference screws, two in the radius and one in the ulna⁶ (► Fig. 2F).

As shown in the historical evolution of the series herein presented, wrist surgeons tried to perform a more anatomical plasty, with a more stable fixation. With the introduction of arthroscopic techniques, smaller (and therefore more cosmetic) incisions, a more anatomical location of the tunnels, and lower soft-tissue damage have been achieved, thus enabling an improvement in ROM without worsening the results in terms of pain, stability, grip strength or functional scores.

The present review has some limitations, the main one being that all the studies retrieved have level IV of evidence (case series), but, to the best of our knowledge, no comparative studies or clinical trials have been published to date. In addition, in the case series analyzed, the authors used different items to measure the outcomes, and there was a lack of objective assessment of DRUJ instability.

In conclusion, the Adams procedure continues to be a valid and reproducible technique for the treatment of chronic DRUJ instability. If wrist arthroscopy and implants are available and surgeons are technically-trained, the authors recommend an arthroscopy-assisted technique, or, if possible, an all-arthroscopic TFCC reconstruction, with implant fixation of the plasty in its anatomical points of insertion. Comparative studies between open and arthroscopic TFCC reconstruction techniques are needed.

Source of Funding

The authors have no source of funding to declare.

Conflict of Interests

The authors have no conflict of interests to declare.

References

- 1 Nakamura T, Makita A. The proximal ligamentous component of the triangular fibrocartilage complex. *J Hand Surg [Br]* 2000;25 (05):479–486

- 2 Nakamura T, Takayama S, Horiuchi Y, Yabe Y. Origins and insertions of the triangular fibrocartilage complex: a histological study. *J Hand Surg [Br]* 2001;26(05):446–454
- 3 Palmer AK. Triangular fibrocartilage complex lesions: a classification. *J Hand Surg Am* 1989;14(04):594–606. Doi: 10.1016/0363-5023(89)90174-3
- 4 Atzei A. New trends in arthroscopic management of type 1-B TFCC injuries with DRUJ instability. *J Hand Surg Eur Vol* 2009;34(05):582–591
- 5 Atzei A, Luchetti R. Foveal TFCC tear classification and treatment. *Hand Clin* 2011;27(03):263–272. Doi: 10.1016/j.hcl.2011.05.014
- 6 Carratalá Baixauli V, Lucas García FJ, Martínez Andrade C, Carratalá Baixauli R, Guisasola Lerma E, Corella Montoya F. All-arthroscopic triangular fibrocartilage complex ligamentoplasty for chronic DRUJ instability. *Tech Hand Up Extrem Surg* 2019;23(01):44–51. Doi: 10.1097/BTH.0000000000000222
- 7 Pürisa H, Sezer İ, Kabakaş F, Tunçer S, Ertürer E, Yazar M. Ligament reconstruction using the Fulkerson-Watson method to treat chronic isolated distal radioulnar joint instability: short-term results. *Acta Orthop Traumatol Turc* 2011;45(03):168–174. Doi: 10.3944/AOTT.2011.2380
- 8 Eliason EL. An operation for recurrent inferior radioulnar dislocation. *Ann Surg* 1932;96(01):27–35
- 9 Breen TF, Jupiter JB. Extensor carpi ulnaris and flexor carpi ulnaris tenodesis of the unstable distal ulna. *J Hand Surg Am* 1989;14(04):612–617
- 10 Hui FC, Linscheid RL. Ulnotriquetral augmentation tenodesis: a reconstructive procedure for dorsal subluxation of the distal radioulnar joint. *J Hand Surg Am* 1982;7(03):230–236
- 11 El-Haj M, Baughman C, Thirkannad SM. A Technique for Treating Dorsal Instability of the Distal Radioulnar Joint. *Tech Hand Up Extrem Surg* 2017;21(02):67–70. Doi: 10.1097/BTH.0000000000000157
- 12 Johnson RK, Shrewsbury MM. The pronator quadratus in motions and in stabilization of the radius and ulna at the distal radioulnar joint. *J Hand Surg Am* 1976;1(03):205–209
- 13 Lee SK, Lee JW, Choy WS. Volar Stabilization of the Distal Radioulnar Joint for Chronic Instability Using the Pronator Quadratus. *Ann Plast Surg* 2016;76(04):394–398. Doi: 10.1097/SAP.0000000000000354
- 14 Liberati A, Altman DG, Tetzlaff J, et al. The PRISMA statement for reporting systematic reviews and meta-analyses of studies that evaluate health care interventions: explanation and elaboration. *PLoS Med* 2009;6(07):e1000100. Doi: 10.1371/journal.pmed.1000100
- 15 Moher D, Cook DJ, Eastwood S, Olkin I, Rennie D, Stroup DFQUOROM Group. Improving the quality of reports of meta-analyses of randomised controlled trials: the QUOROM statement. *Br J Surg* 2000;87(11):1448–1454. Doi: 10.1046/j.1365-2168.2000.01610.x
- 16 Scheker LR, Belliappa PP, Acosta R, German DS. Reconstruction of the dorsal ligament of the triangular fibrocartilage complex. *J Hand Surg [Br]* 1994;19(03):310–318. Doi: 10.1016/0266-7681(94)90079-5
- 17 Adams BD, Berger RA. An anatomic reconstruction of the distal radioulnar ligaments for posttraumatic distal radioulnar joint instability. *J Hand Surg Am* 2002;27(02):243–251. Doi: 10.1053/jhsu.2002.31731
- 18 Teoh LC, Yam AKT. Anatomic reconstruction of the distal radioulnar ligaments: long-term results. *J Hand Surg [Br]* 2005;30(02):185–193. Doi: 10.1016/j.jhsb.2004.10.017
- 19 Gillis JA, Soreide E, Khouri JS, Kadar A, Berger RA, Moran SL. Outcomes of the Adams-Berger Ligament Reconstruction for the Distal Radioulnar Joint Instability in 95 Consecutive Cases. *J Wrist Surg* 2019;8(04):268–275
- 20 Kootstra TJM, van Doesburg MH, Schuurman AH. Functional Effects of the Adams Procedure: A Retrospective Intervention Study. *J Wrist Surg* 2018;7(04):331–335. Doi: 10.1055/s-0038-1660812
- 21 Chu-Kay Mak M, Ho PC. Arthroscopic-Assisted Triangular Fibrocartilage Complex Reconstruction. *Hand Clin* 2017;33(04):625–637. Doi: 10.1016/j.hcl.2017.07.014
- 22 Luchetti R, Atzei A. Arthroscopic assisted tendon reconstruction for triangular fibrocartilage complex irreparable tears. *J Hand Surg Eur Vol* 2017;42(04):346–351. Doi: 10.1177/1753193417690669
- 23 Adams BD. Anatomic Reconstruction of the Distal Radioulnar Ligaments for DRUJ Instability. *Tech Hand Up Extrem Surg* 2000;4(03):154–160
- 24 Seo KN, Park MJ, Kang HJ. Anatomic reconstruction of the distal radioulnar ligament for posttraumatic distal radioulnar joint instability. *Clin Orthop Surg* 2009;1(03):138–145. Doi: 10.4055/cios.2009.1.3.138
- 25 Shih JT, Lee HM. Functional results post-triangular fibrocartilage complex reconstruction with extensor carpi ulnaris with or without ulnar shortening in chronic distal radioulnar joint instability. *Hand Surg* 2005;10(2-3):169–176. Doi: 10.1142/S0218810405002759
- 26 Meyer D, Schweizer A, Nagy L. Anatomic Reconstruction of Distal Radioulnar Ligaments With Tendon Graft for Treating Distal Radioulnar Joint Instability: Surgical Technique and Outcome. *Tech Hand Up Extrem Surg* 2017;21(03):107–113. Doi: 10.1097/BTH.0000000000000163
- 27 Henry M. Anatomic reconstruction of the radioulnar ligament. *Hand (N Y)* 2012;7(04):413–419. Doi: 10.1007/s11552-012-9456-7
- 28 Tse WL, Lau SW, Wong WY, et al. Arthroscopic reconstruction of triangular fibrocartilage complex (TFCC) with tendon graft for chronic DRUJ instability. *Injury* 2013;44(03):386–390. Doi: 10.1016/j.injury.2013.01.009