



Tissue Factor Expression in Colorectal Adenocarcinoma: Association with Angiogenesis and Clinical and Pathological Aspects

Lúcio Sarubbi Fillmann¹ Laura Pinho Fillmann² Leonardo Zarpelon de Oliveira²
Henrique Sarubbi Fillmann³ Gustavo Franco Carvalhal⁴

¹ PhD in Medicine and Health Sciences from PUCRS and Professor in the Department of Surgery at PUC-RS School of Medicine, Porto Alegre, RS, Brazil

² Student of the Undergraduate Course in Medicine at PUC-RS, Porto Alegre, RS, Brazil

³ PhD from UFRGS and Professor at the School of Medicine at PUC-RS, Professor at the Department of Surgery at the School of Medicine at PUC-RS, Porto Alegre, RS, Brazil

⁴ PhD in Urology from USP and Professor in the Department of Surgery at the PUC-RS School of Medicine, Porto Alegre, RS, Brazil

Address for correspondence Lúcio Sarubbi Fillmann, PhD, Avenida Ipiranga, 6690, sala 307, Centro Clínico PUC-RS, Porto Alegre, RS, 90610-000, Brazil (e-mail: lsfillmann@yahoo.com.br).

J Coloproctol 2022;42(1):54–58.

Abstract

Introduction Tissue factor (TF) expression has been described in various neoplasms and was correlated with angiogenesis and metastases.

Objectives To describe TF expression in colorectal cancers, correlating it with microvessel density and clinical and pathological variables.

Methods Immunohistochemistry was used to determine TF expression and microvessel density. The Student *t*-test was used to compare high and low TF expression with microvessel density and with age. The chi-squared test was used for other comparisons, and Kaplan-Meier curves were used for survival analyses.

Results Forty-three patients were operated with curative intent. Their mean age was 58.1 ± 12.6 years old, and 62.8% were male. The rectum was the most common location (60.4%), and most tumors reached the serosa and peri-intestinal fat (72.1%). Lymph nodes were positive in 46.5%, and 72.1% of the tumors were moderately differentiated adenocarcinomas. Death occurred in 27.6 ± 12.8 months in 51.1% of the patients who had recurrence. Tissue factor expression was intense in 88.4%. There was a positive correlation between TF expression and microvessel density ($p = 0.02$), and

Keywords

- ▶ tissue factor
- ▶ angiogenesis
- ▶ colorectal adenocarcinoma

The present study was performed at Colproctology Service of the Hospital São Lucas, Pontifícia Universidade Católica do Rio Grande do Sul, Porto Alegre, RS, Brazil.

received
June 7, 2021
accepted after revision
September 6, 2021
published online
January 31, 2022

DOI <https://doi.org/10.1055/s-0041-1739453>.
ISSN 2237-9363.

© 2022. Sociedade Brasileira de Coloproctologia. All rights reserved.

This is an open access article published by Thieme under the terms of the Creative Commons Attribution-NonDerivative-NonCommercial-License, permitting copying and reproduction so long as the original work is given appropriate credit. Contents may not be used for commercial purposes, or adapted, remixed, transformed or built upon. (<https://creativecommons.org/licenses/by-nc-nd/4.0/>)

Thieme Revinter Publicações Ltda., Rua do Matoso 170, Rio de Janeiro, RJ, CEP 20270-135, Brazil

between TF and older age ($p < 0.01$). There was no correlation between TF expression and other variables (gender, histological type, penetration into the intestinal wall, and lymphatic and systemic metastases). Tissue factor expression did not correlate with survival.

Conclusion Tissue factor expression correlated with increased microvessel density and older age. Further studies are necessary to ascertain the clinical relevance of TF in colorectal cancer.

Introduction

Pivotal studies published by the end of the 19th century have shown that blood coagulation results from the interaction among prothrombin, calcium, fibrinogen, and a fourth factor known as thromboplastin or, more commonly, tissue factor (TF).¹ Tissue factor acts in the coagulation cascade by combining with factor VII, a complex that has a proteolytic role, resulting in the activation of factors IX and X, and ultimately leading to the conversion of fibrinogen into fibrin, resulting in the final clot formation.¹⁻³ The expression of TF was identified in various cell types from embryonal tissues, especially during developmental phases in which the coagulation factors are not present or are unable to cross the placental barrier.¹ In addition, triggers to the induction of TF expression include inflammatory cytokines (such as tumor necrosis factor [TNF]), mitogens (such as vascular endothelial growth factor [VEGF], insulin, and fibroblast growth factor [FGF]), hormones, endotoxins, viral infections, hypoxia, and trauma.¹

In addition to being associated with many hypercoagulability states,^{4,5} TF is related to cancer physiopathology due to its ability to enhance VEGF expression and to promote abnormal proliferation of blood vessels, which is fundamental to tumor development and to the metastatic process.^{4,6-8} Tissue factor expression is increased in many neoplasms, such as small cell lung cancers,⁹ gliomas,¹⁰ breast cancers,¹¹ pancreatic cancers,¹² colonic cancers,⁶ prostate cancers,¹³ and gastric cancers,¹⁴ being also related to more advanced stages of these tumors.

Objective

The goal of our study is to describe TF expression in colorectal adenocarcinomas, correlating the intensity of the expression with microvessel density. Additionally, we aim to correlate TF expression with variables such as age, gender, depth of tumor penetration into the intestinal wall, lymphatic metastases, location of the tumors in the intestine, sites of metastatic recurrence, histologic grade, and survival.

Methods

Our sample consisted of patients diagnosed with colorectal adenocarcinoma treated at the Department of Coloproctology of the Hospital São Lucas, Pontifícia Universidade Católica do Rio Grande do Sul, Porto Alegre, state of Rio Grande do

Sul, Brazil, with at least 5 years of follow-up since surgery. The 43 selected patients were submitted to exclusive intestinal resections according to therapeutic curative (nonpalliative) oncological criteria. We compared TF expression and microvessel density in paraffin-embedded tissues of the colorectal tumors. Clinical and pathological data collected were age and gender, location of the tumors in the rectum or colon, histological differentiation grade, depth of penetration into the intestinal wall, presence of lymph node metastases, and survival in months after surgery.

Immunohistochemistry

The tumors were fixed and embedded in paraffin, and subsequently submitted to 3 μm cuts with antigen retrieval in 99% water bath for 30 minutes at 99°C using Tris/ethylenediamine tetraacetic acid (EDTA), pH 9 (20 mM Tris/0,65 mM EDTA). The blockage of endogenous peroxidase was performed with a 3% peridrol solution (H₂O₂ in methylic alcohol) for 30 minutes. The tissue was then immersed in a 5% PBS buffered saline solution to control the background and incubated with mouse monoclonal antibody anti-TF 1 (1:30 dilution) and anti-human monoclonal mouse antibody for CD34 (1:400 dilution). Detection was performed with the Kit Dako LSAB + peroxidase, and sections were revealed with the chromogen 3,3' - diaminobenzidine in a solution with PBS and 0.002% hydrogen peroxide, contracolored with hematoxylin. Finally, the samples were dehydrated, clarified, and mounted in slides and covers.

Tissue Factor Expression

Cut sections of the tumors were prepared according to immunohistochemistry methods, using an anti-TF monoclonal antibody. The samples were analyzed under 100x magnification by 2 trained observers to determine the percentage of malignant cells positive to the antigen. The tumors were divided into 4 groups according to TF expression: 1 (0-25% of the cancer cells stained), 2 (26-50% of the cancer cells stained), 3 (51-75% of the cancer cells stained), and 4 (76-100% of the cancer cells stained) (-Fig. 1).

Microvessel density

We used immunohistochemistry techniques with an anti-endothelial CD34 antibody, which stained micro vessels with a brownish color, contrasting with the light blue background (hematoxylin). After identifying areas of greater vascularization (hot spots) in 100x magnification, images were captured in 20 different fields to proceed to microvessel

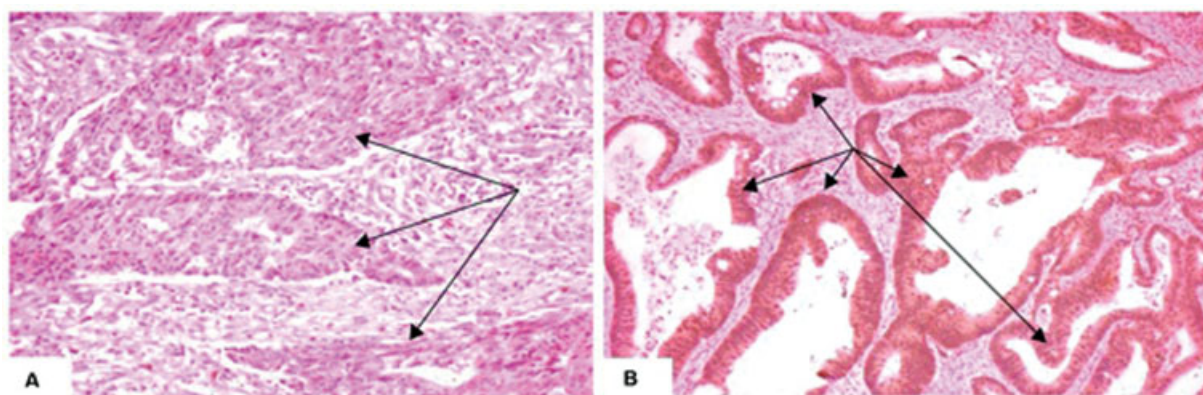


Fig. 1 Examples of tissue factor expression in two of our samples. (A) absence of tissue factor expression in cells of adenocarcinoma glands (indicated by arrows). (B) Tissue factor expression in 100% of the cells of glands from a colorectal adenocarcinoma (arrows point to neoplastic cells intensely expressing tissue factor).

counting in 400x magnification. We included in the counting isolated blood vessel cells as well as larger blood vessels without muscle layers and adventitia, without necessarily including the visualization of the vessel lumen or the presence of red blood cells to consider it a vessel. Counting was made after inserting a correction grid following an ordinal scale. An arithmetic mean of the 20 selected fields was then produced for each tumor.

Statistical Analysis and Ethics

Categorical data were described through frequency and percentage, whereas quantitative data were described through mean and standard deviation (SD). The Student *t*-test was used to compare age and microvessel density between groups of low and high TF expression. The remaining variables were compared for low and high TF expression with the chi-squared test. For survival analysis, Kaplan-Meier curves were produced. The present study was authorized by the Ethics and Research Committee of our institution (documents 174/04-PG and 606/04-CEP).

Results

Patients and Samples Characteristics

The mean age of the patients was 58.1 ± 12.6 years old, with a predominance of the male gender (62.8%). The rectum was the most common location of the tumors (60.4%), with most tumors extending to the serosa and to peritumoral fat (72.1%). Regional lymph nodes were positive for tumors in 46.5% of the patients, and 72.1% of the tumors were classified as moderately differentiated adenocarcinomas. Tumor recurrence occurred in 51.1% of the patients, with an overall survival of 27.6 ± 12.8 months after surgery with the liver being the most common metastatic site (50%). Patients who did not have recurrence were followed-up for 103.8 ± 34.5 months.

Tissue Factor Expression

Tumors that expressed TF intensely (76–100% of tumor cells positive for TF, group 4) were present in 88.4% of the patients; 7% of the patients presented with group 1 tumors (0–25% of

tumor cells expressing TF), and 4.6% of the patients presented with group 2 tumors (26–50% of tumor cells expressing TF). There were no patients with group 3 tumors (51–75% of cells positive for TF). For the statistical analysis, we considered two groups: high expression of TF (group 4) and low expression of TF (groups 1 and 2, encompassing lesions with 0–50% of tumor cells stained for TF).

Correlation between Tissue Factor Expression and Microvessel Density

Tumors with high expression of TF (group 4) revealed an average of 28.4 ± 10.1 microvessels by 400x microscopy field, whereas lesions with low TF expression (groups 1 and 2) showed an average of 17.1 ± 7.9 microvessels per 400x microscopy field. High TF expression correlated positively with an increased microvessel density in our sample ($p = 0.022$) (→ Fig. 2).

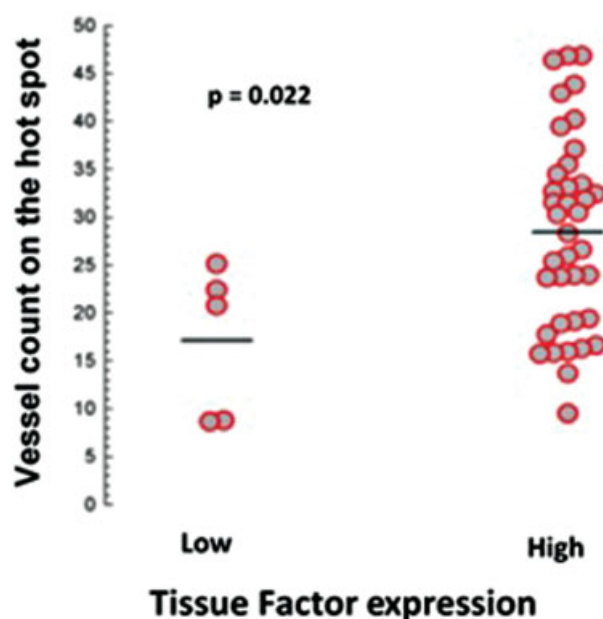


Fig. 2 Graphic representation of microvessel density according to tissue factor expression.

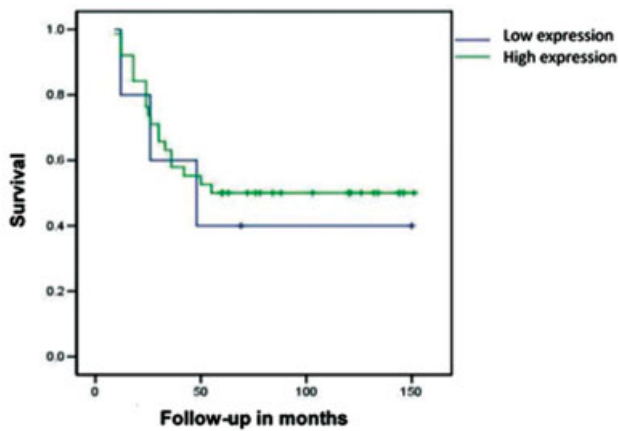


Fig. 3 Kaplan-Meier survival curves of patients with low and high tissue factor expression ($p = \text{NS}$).

Correlation between TF expression and clinical and pathological variables

The mean age of the patients in the high TF expression group was 60.2 ± 11.5 years old, whereas the mean age of the patients in the low TF expression group was 42.6 ± 10.2 years old. The difference was statistically significant ($p < 0.01$). There were no statistically significant differences between TF expression and gender, histologic grade, depth of tumor penetration into the intestinal wall, regional lymph node involvement, and survival (→ Fig. 3).

→ Table 1 summarizes the correlation between low or high TF expression and other clinical and pathological variables evaluated.

Discussion

Interactions between coagulation and cancer have been studied for a long time. Possible mechanisms may include¹⁵: direct activation of the coagulation cascade by circulating tumor cells in the blood stream, possibly related to the hypercoagulable states observed in patients with cancer

(Trousseau syndrome), extravascular activation of coagulation factors in malignant tumors, and the induction of coagulation-related factors by inflammatory cells recruited by the host in response to the tumor.

Our findings of an elevated TF expression in colorectal cancers suggest its importance in the study of these tumors. In our sample, 88.3% of the cases revealed a high TF expression in cancer cells. Therefore, TF could also interact with other significant elements associated with colorectal cancer progression. We have also shown that, in colorectal cancer, TF is associated with tumor angiogenesis, since lesions with high TF expression revealed an increased microvessel density. In colorectal cancer, Seto et al.¹⁶ acknowledged an important prognostic role for TF but could not find a statistically significant association between TF and the expression of VEGF. These authors suggested that other agents associated with the presence of TF might be responsible for the metastatic spread of colorectal cancer.

The statistically significant association between TF expression and microvessel density observed in our study suggests a proangiogenic stimulus associated with the presence of TF in colorectal cancer. However, despite finding a positive correlation between TF and angiogenesis, we did not find any effect on prognosis and survival. In the literature, there is much controversy regarding the prognostic importance of microvessel density.^{17–24} However, tumor angiogenesis and the resulting metastatic process are multifactorial events that depend upon a strict balance between pro and antiangiogenic factors.²⁵ These mechanisms need to be studied in larger patient cohorts to enhance our comprehension of the actual interactions between coagulation, tumor angiogenesis, and disease progression in colorectal cancer.

Finally, excluding microvessel density, age was the only clinical or pathological variable statistically associated with TF expression in our cohort. The group of patients with low TF expression was significantly younger than the group of patients with high TF expression. Seto et al.¹⁶ also observed

Table 1 Characteristics of colorectal cancer patients according to tissue factor expression

	Tissue factor expression		<i>p</i> -value
	Low	High	
Features	<i>n</i> = 5	<i>n</i> = 8	
Male gender, <i>n</i> (%)	3 (60.0)	24 (63.2)	1.00
Age, years old	42.6 ± 10.2	60.2 ± 11.5	< 0.01
Histological type, <i>n</i> (%)			
Well-differentiated	0 (0.0)	2 (5.3)	
Moderately differentiated	3 (60.0)	28 (73.7)	
Poorly differentiated	2 (40.0)	8 (21.0)	
Extensive wall penetration, <i>n</i> (%)	4 (80.0)	30 (78.9)	1.00
Lymph nodes metastases, <i>n</i> (%)	3 (60.0)	17 (44.7)	0.65
Systemic metastasis, <i>n</i> (%)	3 (60.0)	19 (50.0)	1.00
Microvascular density, vessels/field	17.1 ± 7.9	28.4 ± 10.1	0.02

that, in their series, patients with low TF expression were younger, although the difference was not statistically significant. We believe that this association should be further explored in other series.

Regarding future studies, as suggested by others,¹⁶ analyzing the interactions between VEGF, increased angiogenesis, and TF/FVIIa, we could better understand the disease progression mechanisms in colorectal cancer.²⁶ In tumors with increased TF expression and activity, the prevention of thromboembolic events could impact mortality.⁶ It is also known that infection in the postoperative setting may result in an increase in TF production and in greater risks of thrombosis and thromboembolism,²⁷ a considerable problem in colorectal cancer. Tissue factor could also be of use in cancer diagnosis and follow-up. Increased urinary levels of TF have been identified in patients with breast and colon cancer, also correlating with tumor grade in these tumors.²⁸ Lastly, we should consider the potential therapeutic role of blockers of the coagulation cascade such as tinzaparin, a low-molecular weight heparin that activates intracellularly an inhibitor of the TF pathway.²⁹

Conclusion

Tissue factor is highly expressed in the membrane and cytoplasm of cells in most colorectal adenocarcinomas, and its expression positively correlates with increased microvessel density and older age. Further studies are needed to ascertain the role of TF as a prognostic factor or therapeutic target in colorectal cancer.

Conflict of Interests

The authors have no conflict of interests to declare.

References

- Carmeliet P, Collen D. Tissue factor. *Int J Biochem Cell Biol* 1998;30(06):661–667
- Banner DW. The factor VIIa/tissue factor complex. *Thromb Haemost* 1997;78(01):512–515
- Higashi S, Iwanaga S. Molecular interaction between factor VII and tissue factor. *Int J Hematol* 1998;67(03):229–241
- Rickles FR, Patierno S, Fernandez PM. Tissue factor, thrombin, and cancer. *Chest* 2003;124(03):58S–68S
- Goad KE, Gralnick HR. Coagulation disorders in cancer. *Hematol Oncol Clin North Am* 1996;10(02):457–484
- Lykke J, Nielsen HJ. The role of tissue factor in colorectal cancer. *Eur J Surg Oncol* 2003;29(05):417–422
- Folkman J. Tumor angiogenesis and tissue factor. *Nat Med* 1996;2(02):167–168
- Zhang J, Ding J, Zhang X, Shao X, Hao Z. Regulation of vascular endothelial growth factor (VEGF) production and angiogenesis by tissue factor (TF) in SGC-7901 gastric cancer cells. *Cancer Biol Ther* 2005;4(07):769–772
- Sawada M, Miyake S, Ohdama S, et al. Expression of tissue factor in non-small-cell lung cancers and its relationship to metastasis. *Br J Cancer* 1999;79(3-4):472–477
- Guan M, Jin J, Su B, Liu WW, Lu Y. Tissue factor expression and angiogenesis in human glioma. *Clin Biochem* 2002;35(04):321–325
- Ueno T, Toi M, Koike M, Nakamura S, Tominaga T. Tissue factor expression in breast cancer tissues: its correlation with prognosis and plasma concentration. *Br J Cancer* 2000;83(02):164–170
- Ueda C, Hirohata Y, Kihara Y, et al. Pancreatic cancer complicated by disseminated intravascular coagulation associated with production of tissue factor. *J Gastroenterol* 2001;36(12):848–850
- Abdulkadir SA, Carvalhal GF, Kaleem Z, et al. Tissue factor expression and angiogenesis in human prostate carcinoma. *Hum Pathol* 2000;31(04):443–447
- Toneto MG, Depaula PL, Debon L, et al. Immunohistochemical analysis of tissue factor expression in gastric carcinoma: correlations with prognosis and survival. *Análise da expressão imunohistoquímica do fator tecidual no carcinoma gástrico: correlações com prognóstico e sobrevida. Rev Col Bras Cir.* 2018;45(06):e2030. Published 2018 Nov 29. Doi: 10.1590/0100-6991e-20182030
- Shoji M, Hancock WW, Abe K, et al. Activation of coagulation and angiogenesis in cancer: immunohistochemical localization in situ of clotting proteins and vascular endothelial growth factor in human cancer. *Am J Pathol* 1998;152(02):399–411
- Seto S, Onodera H, Kaido T, et al. Tissue factor expression in human colorectal carcinoma: correlation with hepatic metastasis and impact on prognosis. *Cancer* 2000;88(02):295–301
- Frank RE, Saclarides TJ, Leurgans S, Speziale NJ, Drab EA, Rubin DB. Tumor angiogenesis as a predictor of recurrence and survival in patients with node-negative colon cancer. *Ann Surg* 1995;222(06):695–699
- Tanigawa N, Amaya H, Matsumura M, et al. Tumor angiogenesis and mode of metastasis in patients with colorectal cancer. *Cancer Res* 1997;57(06):1043–1046
- Kaio E, Tanaka S, Kitadai Y, et al. Clinical significance of angiogenic factor expression at the deepest invasive site of advanced colorectal carcinoma. *Oncology* 2003;64(01):61–73
- Tarta C. *Análise digital de imagem e estereologia da angiogênese em adenomas e no carcinoma colorretal invasivo de submucosa (tese).* Porto Alegre: Faculdade de Medicina da Universidade Federal do Rio Grande do Sul; 2003
- Banner BF, Whitehouse R, Baker SP, Swanson RS. Tumor angiogenesis in stage II colorectal carcinoma: association with survival. *Am J Clin Pathol* 1998;109(06):733–737
- Lindmark G, Gerdin B, Sundberg C, Pählman L, Bergström R, Glimelius B. Prognostic significance of the microvascular count in colorectal cancer. *J Clin Oncol* 1996;14(02):461–466
- Cianchi F, Palomba A, Messerini L, et al. Tumor angiogenesis in lymph node-negative rectal cancer: correlation with clinicopathological parameters and prognosis. *Ann Surg Oncol* 2002;9(01):20–26
- Abdalla SA, Behzad F, Bsharah S, et al. Prognostic relevance of microvessel density in colorectal tumours. *Oncol Rep* 1999;6(04):839–842
- Chung YS, Maeda K, Sowa M. Prognostic value of angiogenesis in gastro-intestinal tumours. *Eur J Cancer* 1996;32A(14):2501–2505
- Siegbahn A. Cellular consequences upon factor VIIa binding to tissue factor. *Haemostasis* 2000;30(Suppl 2):41–47
- Lwaleed BA, Bass PS, Cooper AJ. The biology and tumour-related properties of monocyte tissue factor. *J Pathol* 2001;193(01):3–12
- Lwaleed BA, Chisholm M, Francis JL. Urinary tissue factor levels in patients with breast and colorectal cancer. *J Pathol* 1999;187(03):291–294
- Mousa SA, Mohamed S. Anti-angiogenic mechanisms and efficacy of the low molecular weight heparin, tinzaparin: anti-cancer efficacy. *Oncol Rep* 2004;12(04):683–688