



Endoscopy in Pregnancy: A Systematic Review

Partha Pal¹ D. Nageshwar Reddy¹ Manu Tandan¹

¹Medical Gastroenterology, Asian Institute of Gastroenterology, Hyderabad, Telangana, India

Address for correspondence Partha Pal, MD, DNB, MRCP (UK), Medical Gastroenterology, Asian Institute of Gastroenterology, 6-3-661, Somajiguda, Hyderabad, Telangana 500082, India (e-mail: partha1986@yahoo.com).

J Digest Endosc 2021;12:138–150.

Abstract

Background Fetomaternal outcomes are of primary concern for gastrointestinal (GI) endoscopy in pregnancy. We aimed to systematically review the safety and utility of endoscopic procedures in pregnancy.

Methods A systematic literature search was performed using PubMed. All original research articles with sample size > 10 involving endoscopy in pregnancy were included for the review along with case report/series describing novel/rare techniques from 1948 to July 2021.

Results After screening 12,197 references, 216 citations were found and finally 66 references were included. Esophagogastroduodenoscopy had favorable fetal outcome (>95%) based on two large retrospective studies and a review of case reports. Sclerotherapy and band ligation of varices were safe according to case series. A large nationwide cohort study established safety of endotherapy for nonvariceal bleed. Botulinum toxin and pneumatic dilation in achalasia are only supported by case reports. Percutaneous endoscopic gastrostomy can be useful to support nutrition based on case reports. A retrospective case–control and cohort study with systemic review justified flexible sigmoidoscopy if strongly indicated. Low birth weight was more common when sigmoidoscopy was done in inflammatory bowel disease based on a prospective study. Colonoscopy was considered safe in second trimester based on a case–control study whereas it can be performed otherwise only in presence of strong indication like malignancy. Capsule endoscopy is promising and can be useful in acute small bowel bleeding although risk of capsule retention is unknown. There are no reports of enteroscopy in pregnancy. Twelve retrospective studies and one prospective study showed high success rate of therapeutic endoscopic retrograde cholangiopancreatography (ERCP) (> 90%) in all trimesters and can be performed if strongly indicated. Pregnancy was an independent risk factor for post-ERCP pancreatitis in a large nationwide case–control study. Radiation-free ERCP with wire-guided bile observation, stent-guided or precut sphincterotomy, endoscopic ultrasound (EUS) guidance, and spyscopy have been described. Safety of EUS is limited to case series and can be used in intermediate probability of choledocholithiasis to guide ERCP and endoscopic cystogastrostomy.

Conclusion This review concludes that GI endoscopy during pregnancy can be done effectively if strongly indicated with good fetomaternal outcomes. Precautions are advocated during procedures where radiation exposure is expected.

Keywords

- ▶ pregnancy
- ▶ esophagogastroduodenoscopy
- ▶ flexible sigmoidoscopy
- ▶ colonoscopy
- ▶ endoscopic retrograde cholangiopancreatography
- ▶ endoscopic ultrasound

DOI <https://doi.org/10.1055s-0041-1739567>
ISSN 0976-5042

© 2021. Society of Gastrointestinal Endoscopy of India.

This is an open access article published by Thieme under the terms of the Creative Commons Attribution-NonDerivative-NonCommercial-License, permitting copying and reproduction so long as the original work is given appropriate credit. Contents may not be used for commercial purposes, or adapted, remixed, transformed or built upon. (<https://creativecommons.org/licenses/by-nc-nd/4.0/>).

Thieme Medical and Scientific Publishers Pvt. Ltd. A-12, 2nd Floor, Sector 2, Noida-201301 UP, India

Introduction

Endoscopy plays a crucial role in managing gastrointestinal (GI) disorders in general population and is considered safe. However, this could not be extrapolated to pregnant women requiring GI endoscopy due to scarcity of robust clinical data and concern regarding fetomaternal complications. Risk factors unique to endoscopy in pregnancy include risk of teratogenicity/premature labor with anesthetic medications, placental abruption or fetal injury with deep intestinal intubation, radiation during endoscopic retrograde cholangiopancreatography (ERCP), and maternal intraprocedure complications like hypotension/hypertension, hypoxia, and arrhythmia.¹

The literature regarding endoscopy in pregnancy is limited to various small isolated case reports/series, and few retrospective studies although recently few prospective studies and nationwide cohort studies with population control have been reported.²⁻⁵ Guidelines are limited and outdated.⁵ It is difficult for the busy practicing gastroenterologist to find and judge clinical data for endoscopy in pregnancy in the absence of prospective, controlled studies which are scarce due to difficulty and reluctance in research due to concern for fetal safety and medico-legal implications.¹ Moreover, the implications of various endoscopic procedures (esophagogastroduodenoscopy [EGD], sigmoidoscopy, colonoscopy, ERCP, endoscopic ultrasound [EUS], etc.) may vary according to various trimesters of pregnancy. For this reason, our review attempts to address the clinical need of the practicing gastroenterologists contemplating endoscopy in pregnancy. It would be a ready reckoner for all endoscopic procedures including sedation in pregnancy based on latest available

data so that endoscopists can take informed decisions, modify procedural techniques, and counsel their patients regarding possible risk and benefits. This will also stimulate clinical research in this unattended area by identifying loopholes of currently available data.¹

Search Strategy

References for this review were identified through searches of PubMed from 1948 until July 2021 using search terms “(Pregnancy) and (endoscopy).” A total of 12,197 citations were screened by one reviewer. A total of 216 relevant citations were identified. Separate searches were done with keywords like (sedation), (esophagogastroduodenoscopy: EGD), (sclerotherapy), (endoscopic variceal banding), (flexible sigmoidoscopy), (colonoscopy), (endoscopic retrograde cholangiopancreatography: ERCP), (enteroscopy), (capsule endoscopy), (endoscopic ultrasound: EUS), (endoscopic cystogastrostomy), (radiation-free ERCP), (endoscopic spyscopy), and (pregnancy). Important cross-references from selected citations were included. Papers describing endoscopy postpartum or with small sample size ($n < 10$) were excluded unless describing novel/rare techniques. A total of 66 references are included in the review (► Fig. 1).

Anesthesia during Endoscopy in Pregnancy

Anesthetic agents during pregnancy can be subdivided into narcotics (meperidine, fentanyl, propofol), sedatives (diazepam and midazolam), general anesthetics (ketamine), and reversal agents (naloxone, flumazenil) or according to the Food and Drug Administration (FDA) pregnancy category

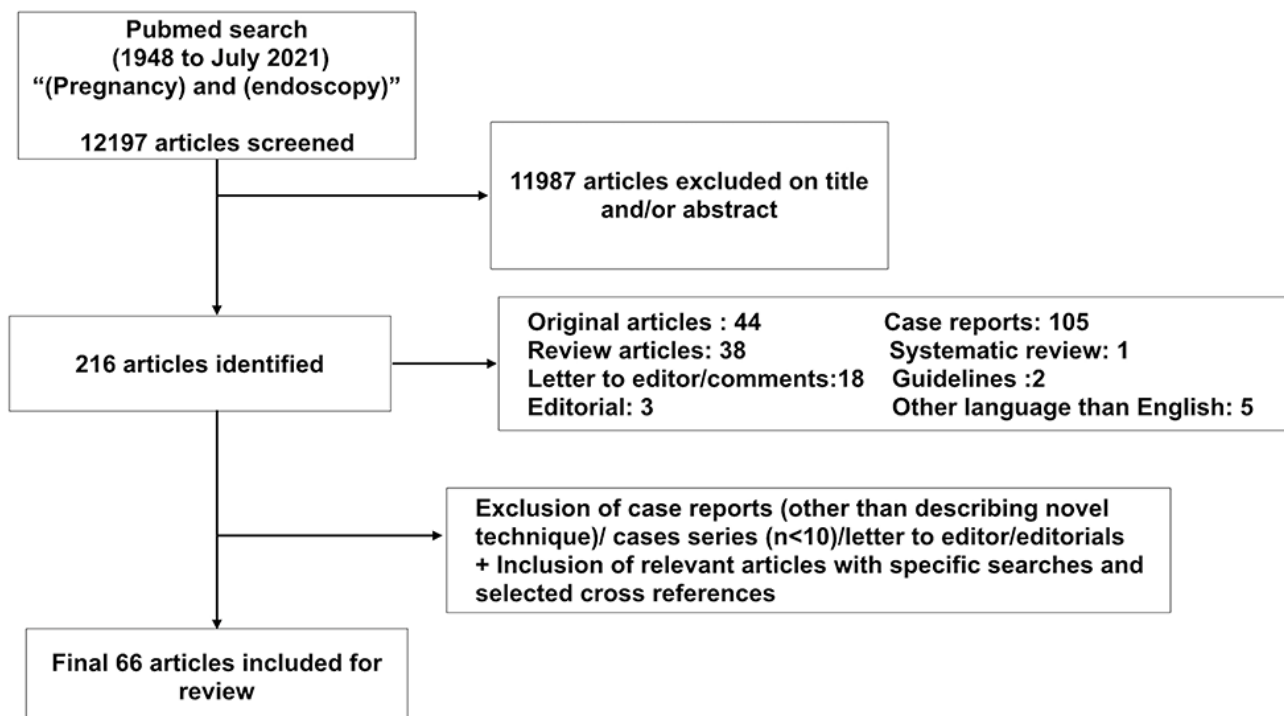


Fig. 1 Search strategy for systematic review on endoscopy in pregnancy.

(category A: none; category B: propofol, ketamine, naloxone; category C: fentanyl, flumazenil; category D: diazepam, midazolam, high dose, prolonged meperidine at term; category X: none).¹

Prolonged administration (> 36 hours) of meperidine can cause respiratory depression and seizures. Hence, other safer opioid alternatives like fentanyl (FDA C) with faster onset and offset of action is used more frequently.

Propofol is increasingly being used in general population for sedation during endoscopy. Ketamine is an alternative in cases where propofol is expected to be inadequate. Both agents are short acting with rapid recovery although the safety has not been studied in first trimester. Propofol has narrow therapeutic index and can cause respiratory depression, arrest, and even death if improperly monitored. Prolonged, high dose of ketamine is unsafe in pregnancy.^{1,6}

Among sedatives, diazepam is a category D drug due to possible association with cleft lip, mental retardation, cardiac anomalies, and neurological defect (e.g., Mobius syndrome). Midazolam is preferred over diazepam as it is not associated with cleft lip. However, its use should be restricted specially in first trimester.^{1,6}

Naloxone is indicated for narcotic toxicity but can precipitate opioid withdrawal in dependent patients. Due to a report of fetal death, its use should be restricted in pregnancy. Flumazenil for benzodiazepine overdose has limited safety data in pregnancy and hence benzodiazepines should be used in lowest dose with gradual titration.⁶

Informed consent, review of medical history, routine blood investigations, obstetric consultation, patient stabilization, deferring if possible to second trimester, secure intravenous line, and referral to expert endoscopist for high-risk procedures are prerequisites of endoscopy with anesthetics during pregnancy.⁶ Use of smallest effective dose of anesthetics, preferential use of category B drugs over C, minimization of procedure time (e.g., sigmoidoscopy instead of colonoscopy), oxygen supplementation, vitals, and electrocardiography monitoring with optional fetal cardiac monitoring are intraprocedural considerations. Fetal heart sounds should be documented before and after the procedure. At our institute, propofol under supervision of anesthesiologist is the drug of choice in all trimesters of pregnancy.¹

Esophagogastroduodenoscopy

Diagnostic EGD in pregnancy should be performed if strongly indicated and going to change the therapy. Upper GI bleed causing hemodynamic instability, ongoing bleed, recent onset progressive dysphagia with weight loss, and suspected upper GI malignancy are strong indications for EGD with high diagnostic yield.

Studies on diagnostic EGD in pregnancy have been summarized in ►Table 1.1^{3,7,8} These studies indicate that the highest diagnostic yield of EGD is for upper GI bleeding (95%) and lower for other indications (50–82%). Reflux esophagitis was most common finding in diagnostic EGD whereas peptic ulcer disease (PUD) was less common as compared to

the general population. The symptoms of PUD decrease with pregnancy and reflux symptoms increase. The frequency of Mallory–Weiss tear as a cause of upper GI bleed was similar to that of PUD (14%).⁷ Intractable vomiting and hyperemesis gravidarum (HG) are other frequent indications for EGD in pregnant female. However, the diagnostic yield of EGD in intractable vomiting (69%) was lower than upper GI bleeding (82%) according to a study from Israel on 60 pregnant patients.⁸ More importantly, EGD in case of intractable vomiting does not lead to major change in management as empirical use of proton pump inhibitors and H₂ blockers can provide symptomatic relief. Bagis et al have found that *Helicobacter pylori* infection was more common in pregnant females ($n = 20$) with HG (90%) compared to 50% in controls ($n = 10$). Although *H. pylori* therapy is generally deferred until postpartum period due to teratogenicity of antibiotics, validation of such association can warrant *H. pylori* therapy for HG.³

Maternal Outcomes (►Table 1)

Data from several studies suggest that EGD is safe in pregnancy and no serious adverse events were reported.^{1,3,7,8} The risk of EGD in pregnancy is similar to that of general population. Pregnant women are generally young to early middle age and likely to have lower complication rates compared to elderly. Hemodynamic instability should be corrected prior to EGD.

Fetal Outcomes

Most of the reported fetal adverse outcomes (preterm delivery, still births, spontaneous abortion) occurred in high-risk pregnancies and not temporally related to EGD (►Table 1).^{1,3,7,8} Apgar scores in infants after birth were similar in patients who underwent EGD versus controls.¹ On fetal cardiac monitoring, fetal heart rate remained normal during EGD.¹

Therapeutic EGD

Variceal Bleed

Extrahepatic portal vein obstruction and noncirrhotic portal fibrosis are the important causes of variceal bleed in pregnancy as fertility is compromised in cirrhosis due to altered estrogen metabolism. The risk of bleeding increases in pregnancy due to increased blood volume and increased peripheral vascular resistance due to compression of inferior vena cava by gravid uterus. The risk of bleeding is highest in second trimester as portal hypertension peaks and during labor due to increased vascular resistance due to performance of Valsalva man oeuvre. De novo variceal hemorrhage and bleeding from preexisting varices occur in 30 and 75% cases, respectively, in pregnancy. Beta-blockers are useful in reducing portal pressure and should be continued. There is risk of decompensation of preexisting liver disease during variceal bleed in pregnancy leading to poor fetomaternal outcomes

Table 1 Summary of studies on esophagogastroduodenoscopy (EGD; both diagnostic and therapeutic) and flexible sigmoidoscopy/colonoscopy in pregnancy

Author	Type of study	N	Maternal outcome	Fetal outcome
Diagnostic EGD				
Cappell et al (1996) ⁷	Retrospective case-control	83	One case of transient pyrexia resolving spontaneously, adverse pregnancy outcomes related to high-risk pregnancy rather than EGD	Health infants in 95% compared to 94% in controls; EGD did not induce abnormal fetal heart rate during EGD
Debby et al (2008) ⁸	Retrospective clinical series	60	No maternal mortality, other complications not described	Fetal death and induced abortion in 2 and 5%, respectively. Eight had preterm delivery. No fetal malformations reported
Bagis et al (2002) ³	Prospective	30	All 30 mothers had hyperemesis gravidarum. High prevalence of <i>H. pylori</i> infection (95%) compared to 50% in controls	Not available
Cappell (2003) ⁵¹	Literature review of case reports	27	Single maternal mortality due to metastatic malignancy	3 cases of stillbirth, 1 abortion, 1 preterm labor
Therapeutic EGD				
Sclerotherapy for esophageal varices				
Author	Type of study	N	Maternal outcome	Fetal outcome
Aggarwal et al (2001) ¹¹	Case series	17	All patients had acute variceal bleed. 10 patients with EHPVO and 7 patients with NCPF underwent EST with absolute alcohol or sodium tetradecyl sulfate 1.5%; 12 patients required repeat EST and 2 required EVL due to failed EST	8 healthy infants (2 preterm), 3 stillbirths, 1 neonatal death, and 5 voluntary abortions
Kochhar et al (1990 and 1999) ^{9,10}	Two cases series	10	For active variceal bleed in 5 and for prophylaxis in 5. Mean number of sessions required were 3. Esophageal stricture dilated with Savary-Gilliard dilator	All delivered at term as healthy infants by normal vaginal delivery
Cappell (2003) ⁵¹	Review of case reports	7	Successful EST for all	All infants were healthy
Mandal et al (2012) ¹²	Retrospective	2	Successful EST, better if diagnosed and treated prior to pregnancy	Better if diagnosed prenatally
Endoscopic variceal ligation for esophageal varices				
Mandal (2012) ¹²	Retrospective	8	Successful EVL, better if diagnosed and treated prior to pregnancy	Better if diagnosed prenatally
Keepanasseril et al (2020) ¹³	Retrospective	9	Maternal complications similar in NCPF and EHPVO. DIC, sepsis and AKI may complicate pregnancy	Perinatal outcomes similar with NCPF and EHPVO. Preterm birth most common fetal complication
Dhiman et al (2000) ¹⁴	Case series	3	2 had uncomplicated delivery, one patient was better until 20th week of gestation (no further data), successful variceal eradication with EVL after failed EST	Uneventful delivery
Nonvariceal upper GI bleed (NVUGIB)				
Nguyen et al (2010) ⁴	Retrospective cohort study	1,210	Mortality was lower in pregnant women compared to nonpregnant, age-matched controls ($n = 6,050$)	The incidence of perinatal complications and prematurity was similar between the groups who underwent endoscopy compared to them who did not
Flexible sigmoidoscopy/colonoscopy				
Ko et al (2020) ²⁰	Retrospective cohort study	48	No adverse obstetric events temporally associated with sigmoidoscopy, management changed in 78% following pregnancy	Fetal outcomes like prematurity and low birth weight was more common in IBD population compared to non-IBD pregnant women
Cappell et al (1996) ¹⁹	Case-control study	56	No complications (48 sigmoidoscopies, 8 colonoscopies)	Among sigmoidoscopy group, after excluding voluntary abortions, rest all have delivered healthy babies (27 at term). 1 stillbirth, 1 death due to prematurity, and 1 cleft palate was reported. Complications were not higher compared to control pregnant female who did not undergo sigmoidoscopy. Adverse outcomes were unrelated to colonoscopy

(continued)

Table 1 (continued)

Author	Type of study	N	Maternal outcome	Fetal outcome
Cappell et al (2010) ²¹	Case-control study	20	16 colonoscopies in second trimester, 2 each in first and third trimester. Colonoscopy led to change in management in 35% cases. 2 cases with mild transient hypotension	No abnormal fetal heart rate during procedure. 1 involuntary abortion and 1 with congenital abnormality. Trend of better fetal outcomes (lower prematurity, abortion, higher birth weight, similar APGAR score, and congenital anomaly) in cases compared to controls
De Lima et al (2015) ²³	Systematic review	164	Above two studies plus 92 cases in case reports. 100 lower GI endoscopies in case reports (1 spontaneous abortion in first trimester, 1 induced abortion in second trimester, induction of labor and emergency caesarean section in 1 each)	Two fetal deaths, both in second trimester among 100 lower GI endoscopies in case reports
de Lima et al (2015) ²	Prospective study (IBD)	42	2 spontaneous abortions were related to procedure, but abortion rate not higher compared to controls (47 procedures, 12 colonoscopy, 35 sigmoidoscopy)	Median birth weight was lower compared to controls, however, prematurity, congenital malformations, and APGAR scores were not different compared to controls

Abbreviations: AKI, acute kidney injury; APGAR, Appearance, Pulse, Grimace, Activity, and Respiration; DIC, disseminated intravascular coagulation; EHPVO, extrahepatic portal vein obstruction; EST, endoscopic sclerotherapy; EVL, endoscopic variceal ligation; GI, gastrointestinal; IBD, inflammatory bowel disease; NCPF, noncirrhotic portal fibrosis.

and hence prophylactic treatment should be considered whenever pregnancy is contemplated.

Fetal outcomes are favorable (100%) in a study by Kochhar et al compared to that by Aggarwal et al (67%) with regard to endoscopic sclerotherapy (EST) which is mainly due to lower incidence of acute variceal bleed in the former (50 vs. 100% in the later) (► **Table 1**).⁹⁻¹¹ The data regarding safety of endoscopic variceal ligation (EVL) is also limited to case series (► **Table 1**).¹²⁻¹⁴ EVL is preferred over EST in pregnancy due to lower incidence of complications, higher efficacy, and conflicting reports on fetal outcomes with EST.

Nonvariceal Upper GI Bleed

The most common cause of nonvariceal upper GI bleed (NVUGIB) in pregnant women is Mallory-Weiss tear (25%) followed by gastritis (12%), PUD (6.8%), esophagitis (2.5%), anastomotic ulcer (0.2%), and Dieulafoy's lesion/arteriovenous malformation (0.1%) according to a nationwide study ($n = 1,210$).⁴ A conservative, nonendoscopic management of NVUGIB in pregnant women is not associated with increased fetomaternal complications according to the study. Fetal outcomes were not different compared to controls. Hence, therapeutic EGD is safe in actively bleeding pregnant patients.⁴ Rest of the studies are limited to case reports.

The data regarding NVUGIB in pregnancy is difficult to extrapolate given the variety of procedures performed for NVUGIB (epinephrine/glue/thrombin/saline injection, electro/photo/thermo/argon plasma coagulation, or mechanical therapy with hemoclips) and various causes with different stigmata of bleed (active spurt/ooze, nonbleeding visible vessel, and adherent clot).¹

Special considerations should be made during electrocoagulation and epinephrine injection. During electrocoagulation, the grounding pad should be kept in such a way from the interventional catheter that the current does not traverse

the uterus/fetus. Epinephrine (pregnancy category C) exposure during first trimester has been associated with congenital malformation, although it could be due to high-risk pregnancy.¹

Endoscopic Therapy for Achalasia

Achalasia during pregnancy can be confused with reflux and hyperemesis. The goal of treatment during pregnancy is to avoid maternal malnutrition and consequent fetal growth retardation and death. Nutrition can be managed initially with nasogastric feeding or parenteral nutrition. In case of intolerance or refusal, botulinum toxin (BT) injection at lower esophageal sphincter or pneumatic balloon dilation (PBD) can be performed.¹⁵ There are five case reports of BT injection for achalasia during pregnancy mainly in the second and third trimester. There are seven case reports of PBD in achalasia with pregnancy.¹⁵ These modalities can have transient effect with recurrence but can be helpful to tide over the crisis. Currently, there are no case reports of peroral endoscopic myotomy (POEM) for achalasia in pregnancy although it could be an effective treatment. There is only one case report of laparoscopic Heller's myotomy (LHM) in second trimester. POEM or LHM can only be considered in resistant cases where PBD and BT fails.¹⁵

Endoscopy to Improve Maternal Nutrition

Percutaneous Endoscopic Gastrostomy and Percutaneous Endoscopic Gastrojejunostomy

Enteral nutrition with percutaneous endoscopic gastrostomy (PEG) or percutaneous endoscopic gastrojejunostomy (PEG-J) may be indicated in pregnancy if maternal nutrition is compromised due to dysphagia, severe odynophagia, obstruction at gastroesophageal junction, intractable HG,

eating disorders like anorexia nervosa, chronic intestinal pseudo-obstruction, and neurologic disorders precluding deglutition like motor neurone disease, myotonic dystrophy, or massive stroke. PEG can be beneficial in maintaining maternal nutrition thus improving fetal outcomes as seen in five out of six case reports. Fetal adverse outcome is mainly related to maternal high-risk condition rather than PEG.¹

Precautions like ultrasound-guided marking of upper border of uterus should be done prior to PEG to avoid inadvertent uterine puncture. Gravid uterus can cause gastric compression leading to pain and leak around stoma. Feeding tube can be placed via the gastrostomy into the jejunum (PEG-J) in case of refractory nausea, vomiting, and aspiration (five cases reports).¹

Flexible Sigmoidoscopy and Colonoscopy

Preparations

Sigmoidoscopy preparation with tap water, saline, or sodium phosphate enema can lead to fluid shifts and volume overload/dehydration along with dyselectrolytemia. Chronic use may cause dyselectrolytemia and fetal bone demineralization/growth failure. However, risks are negligible in pregnant female without heart failure, chronic renal insufficiency, or dehydration.¹

Among orally administered preparations, polyethylene glycol (isotonic, pregnancy category C) is preferred over sodium phosphate preparations as the later can lead to dyselectrolytemia and even renal insufficiency in at-risk or dehydrated patients with consequent effects on fetus.¹⁶ In a prospective study of pregnant patients with constipation, polyethylene glycol relieved constipation in three-fourths without any complications.¹⁷

Indications

Acute lower GI bleeding (except in suspected hemorrhoids), sigmoid/rectal mass, or stricture are strong indications of flexible sigmoidoscopy in pregnancy. Severe, persistent diarrhea and severe flare of inflammatory bowel disease are moderate indications and investigation of lower abdominal pain/altered bowel habits are weak indications. Volvulus is an indication of emergency surgery as it can lead to worse fetomaternal outcomes. Reports have described successful decompression of sigmoid volvulus by sigmoidoscopy.¹⁸ The diagnostic value of sigmoidoscopy is highest for hematochezia (76%) compared to other indications (29%).¹⁹ Reported change in management after sigmoidoscopy/colonoscopy ranges from 35 to 78%.¹⁹⁻²¹

Therapeutic sigmoidoscopy to release uterine incarceration have been reported in five patients by Seubert et al.²²

Maternal and Fetal Outcomes

The maternal and fetal outcomes from retrospective and prospective studies and systematic review including various case reports indicate highly favorable fetomaternal outcomes (►Table 1).¹⁹⁻²³ Maternal complications were

transient, self-limited, or unrelated to procedure. Poor fetal outcomes correlated with high-risk pregnancy. Congenital anomalies were not higher compared to controls. These data suggest safety of sigmoidoscopy when performed for strong indications.

The data for colonoscopy in pregnancy is, however, relatively scanty with strongest evidence in second trimester with lowest risk for fetus. Colonoscopy in first trimester can induce premature labor/neonatal depression. Colonoscopy should generally be deferred in all the trimesters of pregnancy for elective indications. Despite the fact that colonoscopy can be technically difficult due to distortion of normal landmarks in pregnancy, cecal intubation rates are high.

Endoscopic Retrograde Cholangiopancreatography

Risks of ERCP

Pregnancy increases gallstone formation as estrogen promotes cholesterol synthesis leading to supersaturation of bile and progesterone inhibits gallbladder contractility. Choledocholithiasis complicated by jaundice, pancreatitis, or cholangitis can be treated safely by therapeutic ERCP in pregnant women as compared to complex biliary surgery which increases risk of fetal loss. As compared to EGD, unique risk of ERCP in pregnancy includes radiation exposure. The teratogenic dose of radiation in first trimester is above 50 mGy.²⁴ Small studies have shown that fetal radiation exposure up to 3.1 mGy can occur during ERCP which is significantly lower than the acceptable threshold.²⁵ However, more recent studies have shown that fetal radiation dose may not be trivial and exceed 10 mGy when total dose area product was calculated.²⁶ Prolonged procedure and duodenal intubation time, requirement of higher anesthetic doses, and risk of postsphincterotomy bleeding/perforation are the other unique risks with ERCP.

Clinical Evidence

Until recently, the data regarding safety of ERCP in pregnancy was based on several retrospective small series of total 350 patients.²⁷ A nationwide cohort study published in 2015 consisting of 907 pregnant women undergoing ERCP represents the highest study population until now. This matched control study by Inamdar et al have shown that complications of ERCP were similar in pregnant as compared to nonpregnant women although risk of post-ERCP pancreatitis (PEP) was considerably higher in pregnant (adjusted odds ratio [aOR]: 2.8), more so in nonteaching hospitals (aOR: 3.5).²⁸ Fetomaternal outcomes were noninferior to national rates.²⁸ Pregnancy was an independent risk factor for PEP. This data emphasizes the fact that although ERCP is safe in pregnancy, it should be done in carefully selected cases with due precautions in specialized centers.

There are several retrospective studies, case series, and reports of ERCP in pregnancy. We have summarized the results of these studies with sample size ($n \geq 10$) in ►Table 2.^{25,28-41} The limitations of existing studies are retrospective in nature (only one prospective), missing fetal

Table 2 Summary of studies (sample size: n ≥10) on endoscopic retrograde cholangiopancreatography (ERCP) in pregnancy

Author	Year	Number	Study type	Gestation (trimester)	Intervention	Imaging modality	Complication	Fetal outcomes
Jamidar et al ²⁹	1995	29	Retrospective	1st 15 2nd 8 3rd 6	BES-14 Biliary stent-1 Minor papilla ES-1 PD stent-1	Fluoroscopy time not reported	Post-ERCP Pancreatitis : PEP-1	Spontaneous abortion-1 Neonatal death -1 Preterm-1
Farca et al ³⁰	1997	10	Prospective	Not known	BES+ stent -10	Fluoroscopy	Impacted stone requiring repeat ERCP-1	None
Tham et al ²⁵	2003	15	Retrospective	1st 1 2nd 5 3rd 9	ES-6 Biliary stent-1	Median fluoroscopy time 3.2 min	Mild PEP -1	None
Kahaleh et al ³¹	2004	17	Retrospective	No information	BES-17	Median fluoroscopy time -14 s	Post ES bleed-1 PEP-1 Pre-eclampsia-1	None
Gupta et al ³²	2005	18	Retrospective	1st 4 2nd 6 3rd 8	CBD clearance -14 Stents-4	Fluoroscopy -11 USG-5 Bile aspiration-2	Mild PEP-1 Post-ES Bleed-1	Preterm-1
Sharma and Maharshi ³³	2008	11	Retrospective	No information	ES = 11 Stent = 11 Mechanical lithotripsy = 1	Not used	None, 1 required surgery postpartum for large stones	No adverse outcomes
Shelton et al ³⁴	2008	21	Retrospective	1st 7 2nd 9 3rd 5	ES- 21 EUS-6 Choledochoscopy-5	Not used EUS/MRCP Wire-guided bile observation	Mild PEP-1 (4.8%)	1-IUGR
Tang et al ³⁵	2009	65	Retrospective	1st 17 2nd 20 3rd 31	ES-64 Biliary stent-16 Mechanical lithotripsy-1.5% Precut and Prophylactic PD stent-2.9%	Median fluoroscopy time: 1.45 min	Mild PEP-16% Minor bleeding 7.4%	First trimester ERCP: Preterm-20% LBW-21.4%
Bani Hani et al ³⁶	2009	10	Retrospective	1st 2 2nd 5 3rd 3	ES-10	Fluoroscopy all- duration Unknown	PEP-1 (10%)	None
Daas et al ³⁷	2009	17	Retrospective	1st 2 2nd 3 3rd 17	ES-10 Biliary stent-4	Mean fluoroscopy time 8 s	Nil	None
García-Cano et al ³⁸	2012	11	Retrospective	1st 1 2nd 4 3rd 6	ES-9 Stent -2	Fluoroscopy 5 cases (median time 30 s)	Hyperamylasemia-1	None
Zhou et al ³⁹	2013	17	Retrospective	All 3rd	NBD-7 Biliary stent-10	Fluoroscopy time not reported	Post ES bleed-1 PEP-1	6 preterm
Ersoz et al ⁴⁰	2016	22	Retrospective	1st 2 2nd 3 3rd 17	ES=22 EPBD-22	Not used	Mild PEP-2/22	None
Inamdar et al ²⁸	2016	907	National data base review	No information	No information	No information	PEP-12.13% vs. 5% in matched controls	Preterm-1.87% Fetal distress-0.33% Fetal loss-0.67%
Konduk and Bayraktar ⁴¹	2019	25	Retrospective	1st 2 2nd 3 3rd 17	ES-25 Stone extraction-18	Fluoroscopy-18 (6 s) Nonradiation-7	None	None

Abbreviations: BES, biliary endoscopic sphincterotomy; CBD, common bile duct; EPBD, endoscopic papillary balloon dilation; ES, endoscopic sphincterotomy; EUS, endoscopic ultrasound; IUGR, intrauterine growth retardation; NBD, nasobiliary drain; PEP, post-ERCP pancreatitis; USG, ultrasound.

outcomes (10–40%), limited follow-up after birth, and lack of control.¹ A large study with control group is required to investigate whether ERCP increases the background risk of teratogenicity (1.8%).

ERCP Interventions in Pregnancy

Interventions described during ERCP in pregnancy include endoscopic biliary sphincterotomy with or without biliary stenting, biliary stenting alone, balloon sweep without sphincterotomy, endoscopic papillary balloon dilation, mechanical lithotripsy, precut sphincterotomy, pancreatic stent placement, nasobiliary tube placement, and choledochoscopy (–Table 1).

Repeat or Failed ERCP

Technical success is generally high (> 90%). A repeat ERCP/surgery is required due to recurrent biliary disease in < 10% patients (24/296). Failed ERCP was reported in < 5% (14/296) patients.¹

Maternal Considerations

The risk of post-ERCP complications (bleeding, perforation) are similar in pregnancy compared to nonpregnant (bleeding risk 2%) except for higher risk of PEP.²⁸ This is contrary to earlier data describing similar risk of PEP in pregnancy compared to nonpregnant. However, the risk is small and clinically acceptable. Lack of liberal use of intravenous hydration, teratogenic rectal nonsteroidal anti-inflammatory drugs, or an inherent physiological mechanism could explain this.²⁸ PEP in pregnancy is mostly mild-moderately severe.

Rates of postsphincterotomy bleeding in pregnancy (1%) are lower than general population (2%) and similar to age-matched nonpregnant females (0.96%).²⁸ Most of the bleeding can be tackled endoscopically. Pregnancy being a mild hypercoagulable state, does not lead to increased bleeding tendency.

Rate of perforation was comparable in pregnant versus nonpregnant age-matched female during ERCP.²⁸ Postsphincterotomy bilioenteric fistula were reported to be successfully treated with biliary stenting.⁴²

Maternal outcomes in those undergoing ERCP is similar to other pregnant women with no increase in maternal mortality.²⁸

Fetal Considerations

Based on an earlier review of literature, among 296 pregnancies fatal outcomes were not reported in 42 cases. Majority had normal term delivery ($n = 237$) and rest had premature birth ($n = 11$), spontaneous abortion ($n = 3$), sudden death after birth ($n = 2$), and induced abortion

($n = 1$). Overall, perinatal mortality was less than 1% with no congenital anomalies.¹ However, most of the studies did not look specifically for congenital anomalies and follow-up after birth was limited. Data from national database study showed that the rate of prematurity (1.87%) was lower compared to national average (11.5%). Fetal distress/loss was seen in 1% cases similar to population rates.²⁸ The data is reassuring and suggests that the fetal risk is small and acceptable although comparatively higher than maternal risk. Overall benefits of ERCP in complicated choledocholithiasis seem to outweigh the risks.

Technical Modifications and Considerations for Radiation-Free ERCP or Reduction in Radiation Exposure during Therapeutic ERCP in Pregnancy

Various technical modifications and procedural strategies like (1) wire-guided bile observation, (2) stent-guided/precut sphincterotomy for biliary access, (3) EUS guidance, (4) spy cholangioscopy, (5) expert endoscopist (reduce radiation exposure by shorter procedure time), (6) two-staged ERCP, (7) contrast-enhanced ultrasound-guided ERCP, and (8) technical modifications in X-ray technique have been described to minimize fetal radiation exposure during ERCP which are listed in –Table 3.^{29,33,34,43-55}

Earlier reports focused on wire-guided bile aspiration, precut sphincterotomy, and lead shielding to reduce radiation exposure.^{53,55} Later on, modification in fluoroscopy techniques have been described.^{51,52} Two-staged procedures with nasobiliary drain and stent placement has also been described.^{33,39,40} The recent trend is toward radiation-free, single-session ERCP in pregnancy with either EUS guidance or by digital single-operator cholangioscopy (DSOC).^{43,46-48}

Endoscopic Spycopy

Spyscope/baby scope introduced through the biopsy channel of ERCP scope can be used to confirm common bile duct (CBD) stone clearance postsphincterotomy and evaluate intracholedochal tumor or stricture. Five such cases have been described in the literature without any adverse maternal outcomes.³⁴ Spycopy has been described along with EUS guidance for management of CBD stone in pregnancy.⁵⁶

Cholangioscopy has been revolutionized with the use of DSOC (SpyGlass DS, Boston Scientific) with disposable cholangioscope and digital image capture. This results in better image quality and maneuverability with advantages like feasibility of radiation-free ERCP, direct visualization of the biliary system, ability for tissue acquisition, and cholangioscopy-directed therapy. ERCP guided by DSOC can help avoid radiation in 50% cases as shown in a recent study.⁴³ Fetal outcomes have not been described in these reports. Larger studies reporting fetomaternal outcomes are required to establish this attractive radiation-free

Table 3 Summary of studies describing technical modifications to reduce radiation exposure during therapeutic endoscopic retrograde cholangiopancreatography (ERCP) in pregnancy

Author	Modified ERCP techniques	Rationale
Brewer et al (2021) ⁴³	Digital single operator cholangioscopy (DSOC)-guided ERCP (n = 10)	Fluoroscopy-less ERCP in 50% cases, safe and feasible alternative to standard ERCP, acceptable maternal and fetal safety profile
Sharma and Maharshi (2008) ³³	Two-stage technique: ES + stenting without fluoroscopy in pregnancy followed by definitive ERCP postpartum	Avoidance of radiation exposure
Ersoz et al (2016) ⁴⁰	ES followed by endoscopic papillary balloon dilation (EPBD) and balloon sweep	Nonradiation technique to facilitate complete stone removal
Shelton et al (2008) ³⁴	Catheter bile aspiration followed by wire-guided bile observation or stent-guided biliary sphincterotomy or precut sphincterotomy and finally spy cholangioscopy	Nontraditional techniques for ERCP with increase in efficacy with wire-guided observation and spy cholangioscopy
Zhou et al (2013) ³⁹	Nasobiliary drain or stent followed by definite ERCP postpartum for third trimester pregnancy presenting with cholangitis	Modified ERCP protocol in 3rd trimester acute cholangitis by initial temporizing measure and later definitive therapy
Polydorou et al (2012) ⁴⁴	Magnetic resonance cholangiopancreatography (MRCP) and nonradiation ERCP followed by immediate laparoscopic cholecystectomy in biliary pancreatitis	MRCP to clarify the number of stones to guide nonradiation ERCP
Huang et al (2013) ⁴⁵	Comparison of ultrasound guidance for ERCP versus nonradiographic ERCP	Higher success rate of complete stone removal, shorter hospital stay, and lower complication rates with ultrasound guidance for ERCP; confirm biliary cannulation by ultrasound
Sethi et al (2015) ⁴⁶	EUS guidance followed by same session ERCP with or without spy cholangioscopy	Safe and effective radiation-free ERCP in pregnant patients
Götzberger et al (2012) ⁴⁷	EUS followed by contrast-enhanced ultrasound-guided ERCP by injecting ultrasound contrast agent via ERCP catheter	Intraductal application of ultrasound contrast clearly delineates biliary pathology
Vohra et al (2014) ⁴⁸	Single session EUS followed by scheduled ERCP: If endoscopic ultrasound (EUS) confirms no stone, ERCP can be avoided; if EUS shows stones, it helps to give idea about location, size and number of stones, guide therapy, and confirm stone clearance	Confirm CBD stone and guide therapy and guide nonradiation intervention
Bar-Meir and Rotmensch (1984) ⁴⁹	Use of ultrathin caliber baby cholangioscope through biopsy channel of side view endoscope	Investigation of obstructive jaundice without radiation exposure
Baillie et al (1990) ⁵⁰	Place lead shielding over mother's abdomen and radiation dosimetry badge to monitor radiation. Reduction in fluoroscopy time and avoiding spot radiographs for documentation	Methods to reduce radiation exposure during ERCP
Cappell (2003) ⁵¹	Modern X-ray machine, consulting tradition physicist, attending anesthesiologist, avoiding fellow participation, deferring to second trimester if possible, minimize procedure time, referral to tertiary center, prior obstetric consultation, and informed consent	Reduction in radiation scatter and overall reduction in radiation exposure
Baron and Schueler (2009) ⁵²	Avoid magnification fluoroscopy image, adjust maternal position in fluoroscopy table, digital image acquisition instead of film-screen radiography, variable rate pulsed fluoroscopy rather than continuous fluoroscopy, beam collimation to smallest field, placing image receptor close to patient, and X-ray tube as far as possible	Technical modifications to reduce fetal radiation exposure
Jamidar et al (1995) ²⁹	Performing pregnancy test prior to ERCP in right clinical setting (missed period in menstruating female), direct sphincterotome cannulation	Avoid ERCP in unrecognized pregnancy, reduce procedure time
Binmoeller and Katon (1990) ⁵³	Needle knife precut sphincterotomy	Reduction in fluoroscopy time
Nesbitt et al (1996) ⁵⁴	Magnesium administration for tocolysis	Decrease biliary tract spasm
Rahmin et al (1994) ⁵⁵	Bile aspiration to confirm CBD cannulation	Avoid radiation exposure

Abbreviations: CBD, common bile duct; ES, endoscopic sphincterotomy; EUS, endoscopic ultrasound.

technology as an alternative to therapeutic ERCP for CBD stones in pregnancy.

Endoscopic Ultrasound

EUS is safe in pregnancy as it involves EGD followed by ultrasound examination of pancreaticobiliary tract.⁵⁷ However, EUS may require prolonged procedure time exposing the mother to higher anesthetic doses and the indicated patients could be sicker (e.g., biliary pancreatitis) compared to those undergoing EGD. Clinical data in EUS safety in pregnancy is limited to small case series. In the largest series, Shelton et al used EUS in suspected CBD stone.³⁴ Adverse fetal outcomes like death due to recurrent cholangitis and HELLP syndrome are mostly unrelated to EUS and due to severe maternal illness and conservative management of biliary pancreatitis.⁵⁸ Hence, in the absence of strong clinical data, EUS should be used if there is intermediate probability of CBD stone and magnetic resonance cholangiopancreatography is not desirable. EUS can be done in the same session prior to ERCP.^{48,59} Performing ERCP through linear echo-endoscope ultrasound guidance has been described.⁶⁰

Small Bowel Endoscopy

Enteroscopy

Enteroscopy in pregnancy is technically difficult due to compression of small bowel loops by gravid uterus precluding deep intubation. The challenges of performing enteroscopy in pregnancy are prolonged procedure time, higher requirement of anesthetic doses, and possibility of placental abruption due to pressure from enteroscope. There is currently no published clinical data on enteroscopy in pregnant females. Only indication of balloon-assisted enteroscopy could be small bowel tumor presumed to be malignant and life-threatening small bowel bleeding not reachable by push enteroscopy. Push enteroscopy could be technically easier given no need for deep small bowel intubation and shorter procedure time than balloon-assisted enteroscopy. Spiral enteroscopy is contraindicated in pregnancy.¹

Video Capsule Endoscopy

Video capsule endoscopy (VCE) is an attractive option in pregnancy for small bowel imaging due to absence of radiologic exposure and need for deep enteroscopy although there is concern regarding microwave emission from active capsule. Prolonged small bowel transit in pregnancy due to inhibitory effect of progesterin on small bowel smooth muscle contractility can theoretically increase the risk of capsule retention in pregnancy and can lead to incomplete small bowel examination. However, two cases of VCE have been described in the literature. In a case of esophageal varices postsclerotherapy, esophageal VCE ruled out active bleeding from esophageal varices resulting in normal delivery.⁶¹ In the another case with active small bowel bleed, jejunal ulcerated lesion was

identified which turned out to be carcinoid.⁶² In one case of Crohn's disease with missed retained capsule became pregnant which led to ileal resection.⁶³ Hence, VCE can be beneficial in pregnancy if strongly indicated unless other risk factors of retention are present.

Endoscopic Cystogastrostomy

Two cases of endoscopic cystogastrostomy have been described in the literature under abdominal ultrasound guidance (not EUS) at 17th and 21st week of gestation.^{64,65} Postprocedure pain and leucocytes have been described which was successfully treated with antibiotics and placement of additional cyst-gastric stents. Hence, endoscopic cystogastrostomy in the current era with EUS guidance is a useful option in pregnant female with symptomatic pancreatic fluid collections as an alternative to surgical cystogastrostomy. Proper informed consent and explanation of alternative modalities of treatment are essential in these settings.

Conclusion

This review highlights the fact that endoscopy should be done in pregnancy only if strongly indicated. Whenever possible it is wise to defer endoscopy in first trimester and peripartum period unless an emergency like significant GI bleed or suspected malignancy is present. Minimally invasive, short-duration procedures should be substituted for long invasive procedures (e.g., flexible sigmoidoscopy rather than colonoscopy). Stabilizing patient prior to procedure is vital and it should be performed by expert endoscopist in a hospital-based settings. Informed consent with clear explanation of limited clinical data on fetomaternal safety is a prerequisite. Documentation of fetal heart sound pre- and postprocedure is mandatory with optional intraprocedure fetal heart rate monitoring. Pulse oximetry, oxygen supplementation, and electrocardiography monitoring is needed during procedure. It is important to perform EGD in left lateral position to avoid reflux and to avoid abdominal compression (during colonoscopy) and prone or supine position (to avoid compression of inferior vena cava by gravid uterus).

More prospective or case-control studies are required to establish safety of various endoscopic procedures during pregnancy. Most of the current evidence and recommendations are based on retrospective data (► **Fig. 2**). Randomized controlled studies are unlikely due to medico-legal issues. Ultrathin scopes and EUS guidance can help avoid radiation during ERCP with minimal anesthesia and pressure on gravid uterus. Smaller, steerable video capsule endoscopes in future can help evaluate entire intestine noninvasively in a pregnant female as an alternative to invasive endoscopy.

Authors' Contribution

Conceptualization: P.P., MT; Literature review and writing original draft: P.P.; Illustrations: P.P.; Images: P.P.; Proof reading and critical review: M.T., D.N.R.; approving final manuscript: M.T., P.P., D.N.R.

Procedure	Clinical evidence	Fetomaternal outcomes	Recommendations
Diagnostic EGD	2 large retrospective study and 1 literature review of case reports. 1 prospective study (H. Pylori and Hyperemesis)	Highly favourable fetal outcomes (>95%), yield highest for GI bleed	Perform EGD if strongly indicated with informed consent and after stabilization
EST and EVL	Case series (3: EST, 4: EVL)	Conflicting results (EST): good fetal outcome: 67-100%, EVL scarcity of data but appears safe	EVL>EST for actively bleeding varices
NVUGIB	Retrospective large nationwide cohort study (n=1210), controls (n=6050)	Maternal mortality lower and prenatal complications similar to controls	Therapeutic endoscopy safe for NVUGIB, safety of various techniques of hemostasis unknown
Sigmoidoscopy/ colonoscopy	A retrospective case control and cohort study, 1 systemic review, 1 prospective study (IBD), case control study (Colonoscopy)	LBW commoner when sigmoidoscopy done in IBD	Sigmoidoscopy if strongly indicated, colonoscopy can be considered in 2nd trimester else only if malignancy suspected
ERCP	12 retrospective studies, 1 prospective study, A large nationwide case control study, technical modifications: 17 studies	High success rate (>90%), pregnancy risk factor for PEP, various modalities can minimize/avoid radiation	ERCP should only be performed when strongly indicated, non-radiation modalities to be considered
EUS	Case series	Adverse fetal outcomes related to maternal conditions and conservative approach in biliary pancreatitis	For intermediate probability of choledocholithiasis and to guide ERCP and cystogastrostomy
Enteroscopy /VCE	VCE two case reports, enteroscopy: no data	Risk of capsule retention is unknown, enteroscopy can lead to placental abruption	VCE can be done in acute small bowel bleeding, enteroscopy experimental
BT and PBD	Case reports (5: BT, 7: PBD)	Fetal outcomes not reported, maternal outcomes favourable	BT and PBD are useful options for pregnant female with Achalasia
PEG and PEG J	Case reports (6: PEG, 5: PEG-J)	Adverse fetal outcome related to maternal condition than procedure	PEG or PEG- J may be indicated if maternal nutrition is compromised

Fig. 2 Recommendations for various endoscopic procedures in pregnancy with available clinical evidence and data on fetomaternal outcomes. BT, botulinum toxin; EGD, esophagogastroduodenoscopy; EST, endoscopic sclerotherapy; ERCP, endoscopic retrograde cholangiopancreatography; EUS, endoscopic ultrasound; EVL, endoscopic variceal ligation; *H. pylori*, *Helicobacter pylori*; IBD, inflammatory bowel disease; LBW, low birth weight; NVUGIB, nonvariceal upper gastrointestinal bleed; PBD, pneumatic balloon dilation; PEG, percutaneous endoscopic gastrostomy; PEG-J, percutaneous endoscopic gastrojejunostomy; PEP, post-ERCP pancreatitis; VCE, video capsule endoscopy.

Funding

None.

Conflict of Interest

None declared.

Acknowledgment

None.

References

- Cappell MS. Risks versus benefits of gastrointestinal endoscopy during pregnancy. *Nat Rev Gastroenterol Hepatol* 2011;8(11):610-634
- de Lima A, Zelinkova Z, van der Woude CJ. A prospective study of the safety of lower gastrointestinal endoscopy during pregnancy in patients with inflammatory bowel disease. *J Crohn's Colitis* 2015;9(7):519-524
- Bagis T, Gumurdulu Y, Kayaselcuk F, Yilmaz ES, Kilitcadag E, Tarim E. Endoscopy in hyperemesis gravidarum and *Helicobacter pylori* infection. *Int J Gynaecol Obstet* 2002;79(2):105-109
- Nguyen GC, Dinani AM, Pivovarov K. Endoscopic management and outcomes of pregnant women hospitalized for nonvariceal upper GI bleeding: a nationwide analysis. *Gastrointest Endosc* 2010;72(5):954-959
- Shergill AK, Ben-Menachem T, Chandrasekhara V; ASGE Standard of Practice Committee, et al; Guidelines for endoscopy in pregnant and lactating women. *Gastrointest Endosc* 2012;76(1):18-24 [Erratum in: *Gastrointest Endosc*. 2013 May;77(5):833. PMID: 22579258
- Cappell MS. Sedation and analgesia for gastrointestinal endoscopy during pregnancy. *Gastrointest Endosc Clin N Am* 2006;16(1):1-31
- Cappell MS, Colon VJ, Sidhom OA. A study of eight medical centers of the safety and clinical efficacy of esophagogastroduodenoscopy in 83 pregnant females with follow-up of fetal outcome with comparison control groups. *Am J Gastroenterol* 1996;91(2):348-354
- Debby A, Golan A, Sadan O, Glezerman M, Shirin H. Clinical utility of esophagogastroduodenoscopy in the management of recurrent and intractable vomiting in pregnancy. *J Reprod Med* 2008;53(5):347-351
- Kochhar R, Kumar S, Goel RC, Sriram PV, Goenka MK, Singh K. Pregnancy and its outcome in patients with noncirrhotic portal hypertension. *Dig Dis Sci* 1999;44(7):1356-1361
- Kochhar R, Goenka MK, Mehta SK. Endoscopic sclerotherapy during pregnancy. *Am J Gastroenterol* 1990;85(9):1132-1135
- Aggarwal N, Sawhney H, Vasishta K, Dhiman RK, Chawla Y. Non-cirrhotic portal hypertension in pregnancy. *Int J Gynaecol Obstet* 2001;72(1):1-7
- Mandal D, Dattaray C, Sarkar R, Mandal S, Choudhary A, Maity TK. Is pregnancy safe with extrahepatic portal vein obstruction? An analysis. *Singapore Med J* 2012;53(10):676-680
- Keepanasseril A, Gupta A, Ramesh D, Kothandaraman K, Jeganathan YS, Maurya DK. Maternal-fetal outcome in pregnancies complicated with non-cirrhotic portal hypertension: experience from a tertiary centre in South India. *Hepatol Int* 2020;14(5):842-849
- Dhiman RK, Biswas R, Aggarwal N, Sawhney H, Chawla Y. Management of variceal bleeding in pregnancy with endoscopic variceal ligation and N-butyl-2-cyanoacrylate: report of three cases. *Gastrointest Endosc* 2000;51(1):91-93

- 15 Vosko S, Cohen DL, Neeman O, Matalon S, Broide E, Shirin H. Achalasia during pregnancy: proposed management algorithm based on a thorough literature review. *J Neurogastroenterol Motil* 2021;27(1):8–18
- 16 Patel V, Nicar M, Emmett M, et al. Intestinal and renal effects of low-volume phosphate and sulfate cathartic solutions designed for cleansing the colon: pathophysiological studies in five normal subjects. *Am J Gastroenterol* 2009;104(4):953–965
- 17 Neri I, Blasi I, Castro P, Grandinetti G, Ricchi A, Facchinetti F. Polyethylene glycol electrolyte solution (Isocolan) for constipation during pregnancy: an observational open-label study. *J Midwifery Womens Health* 2004;49(4):355–358
- 18 Rottenstreich M, Mosmar K, Ehrlich Z, Kitroser E, Grisaru-Granovsky S. Flexible endoscopic decompression for treatment of sigmoid volvulus in pregnancy. *Eur J Obstet Gynecol Reprod Biol* 2019;242:184–185
- 19 Cappell MS, Colon VJ, Sidhom OA. A study at 10 medical centers of the safety and efficacy of 48 flexible sigmoidoscopies and 8 colonoscopies during pregnancy with follow-up of fetal outcome and with comparison to control groups. *Dig Dis Sci* 1996;41(12):2353–2361
- 20 Ko MS, Rudrapatna VA, Avila P, Mahadevan U. Safety of flexible sigmoidoscopy in pregnant patients with known or suspected inflammatory bowel disease. *Dig Dis Sci* 2020;65(10):2979–2985
- 21 Cappell MS, Fox SR, Gorrepati N. Safety and efficacy of colonoscopy during pregnancy: an analysis of pregnancy outcome in 20 patients. *J Reprod Med* 2010;55(3-4):115–123
- 22 Seubert DE, Puder KS, Goldmeier P, Gonik B. Colonoscopic release of the incarcerated gravid uterus. *Obstet Gynecol* 1999;94(5 Pt 1):792–794
- 23 De Lima A, Galjart B, Wisse PH, Bramer WM, van der Woude CJ. Does lower gastrointestinal endoscopy during pregnancy pose a risk for mother and child? - a systematic review. *BMC Gastroenterol* 2015;15:15
- 24 Brent RL. The effect of embryonic and fetal exposure to x-ray, microwaves, and ultrasound: counseling the pregnant and nonpregnant patient about these risks. *Semin Oncol* 1989;16(5):347–368
- 25 Tham TC, Vandervoort J, Wong RC, et al. Safety of ERCP during pregnancy. *Am J Gastroenterol* 2003;98(2):308–311
- 26 Samara ET, Stratakis J, Enele Melono JM, Mouzas IA, Perisinakis K, Damilakis J. Therapeutic ERCP and pregnancy: is the radiation risk for the conceptus trivial? *Gastrointest Endosc* 2009;69(4):824–831
- 27 Friedel D, Stavropoulos S, Iqbal S, Cappell MS. Gastrointestinal endoscopy in the pregnant woman. *World J Gastrointest Endosc* 2014;6(5):156–167
- 28 Inamdar S, Berzin TM, Sejjal DV, et al. Pregnancy is a risk factor for pancreatitis after endoscopic retrograde cholangiopancreatography in a national cohort study. *Clin Gastroenterol Hepatol* 2016;14(1):107–114
- 29 Jamidar PA, Beck GJ, Hoffman BJ, et al. Endoscopic retrograde cholangiopancreatography in pregnancy. *Am J Gastroenterol* 1995;90(8):1263–1267
- 30 Farca A, Aguilar ME, Rodriguez G, de la Mora G, Arango L. Biliary stents as temporary treatment for choledocholithiasis in pregnant patients. *Gastrointest Endosc* 1997;46(1):99–101
- 31 Kahaleh M, Hartwell GD, Arseneau KO, et al. Safety and efficacy of ERCP in pregnancy. *Gastrointest Endosc* 2004;60(2):287–292
- 32 Gupta R, Tandan M, Lakhtakia S, Santosh D, Rao GV, Reddy DN. Safety of therapeutic ERCP in pregnancy - an Indian experience. *Indian J Gastroenterol* 2005;24(4):161–163
- 33 Sharma SS, Maharshi S. Two stage endoscopic approach for management of choledocholithiasis during pregnancy. *J Gastrointest Liver Dis* 2008;17(2):183–185
- 34 Shelton J, Linder JD, Rivera-Alsina ME, Tarnasky PR. Commitment, confirmation, and clearance: new techniques for nonradiation ERCP during pregnancy (with videos). *Gastrointest Endosc* 2008;67(2):364–368
- 35 Tang SJ, Mayo MJ, Rodriguez-Frias E, et al. Safety and utility of ERCP during pregnancy. *Gastrointest Endosc* 2009;69(3 Pt 1):453–461
- 36 Bani Hani MN, Bani-Hani KE, Rashdan A, AlWaqfi NR, Heis HA, Al-Manasra AR. Safety of endoscopic retrograde cholangiopancreatography during pregnancy. *ANZ J Surg* 2009;79(1-2):23–26
- 37 Daas AY, Agha A, Pinkas H, Mamel J, Brady PG. ERCP in pregnancy: is it safe? *Gastroenterol Hepatol (N Y)* 2009;5(12):851–855
- 38 García-Cano J, Pérez-Miranda M, Pérez-Roldán F, et al. ERCP during pregnancy. *Rev Esp Enferm Dig* 2012;104(2):53–58
- 39 Zhou Y, Zhang X, Zhang X, et al. ERCP in acute cholangitis during third trimester of pregnancy. *Hepatogastroenterology* 2013;60(125):981–984
- 40 Ersoz G, Turan I, Tekin F, Ozutemiz O, Tekesin O. Nonradiation ERCP with endoscopic biliary sphincterotomy plus papillary balloon dilation for the treatment of choledocholithiasis during pregnancy. *Surg Endosc* 2016;30(1):222–228
- 41 Konduk BT, Bayraktar O. Efficacy and safety of endoscopic retrograde cholangiopancreatography in pregnancy: a high-volume study with long-term follow-up. *Turk J Gastroenterol* 2019;30(9):811–816
- 42 Akcakaya A, Ozkan OV, Okan I, Kocaman O, Sahin M. Endoscopic retrograde cholangiopancreatography during pregnancy without radiation. *World J Gastroenterol* 2009;15(29):3649–3652
- 43 Brewer Gutierrez OI, Godoy Brewer G, Zulli C, et al. Multicenter experience with digital single-operator cholangioscopy in pregnant patients. *Endosc Int Open* 2021;9(2):E116–E121
- 44 Polydorou A, Karapanos K, Vezakis A, et al. A multimodal approach to acute biliary pancreatitis during pregnancy: a case series. *Surg Laparosc Endosc Percutan Tech* 2012;22(5):429–432
- 45 Huang P, Zhang H, Zhang XF, Zhang X, Lü W, Fan Z. Comparison of endoscopic retrograde cholangiopancreatography performed without radiography and with ultrasound-guidance in the management of acute pancreaticobiliary disease in pregnant patients. *Chin Med J (Engl)* 2013;126(1):46–50
- 46 Sethi S, Thosani N, Banerjee S. Radiation-free ERCP in pregnancy: a “Sound” approach to leaving no stone unturned. *Dig Dis Sci* 2015;60(9):2604–2607
- 47 Götzberger M, Pichler M, Gülberg V. Contrast-enhanced US-guided ERCP for treatment of common bile duct stones in pregnancy. *Gastrointest Endosc* 2012;76(5):1069–1070
- 48 Vohra S, Holt EW, Bhat YM, Kane S, Shah JN, Binmoeller KF. Successful single-session endosonography-based endoscopic retrograde cholangiopancreatography without fluoroscopy in pregnant patients with suspected choledocholithiasis: a case series. *J Hepatobiliary Pancreat Sci* 2014;21(2):93–97
- 49 Bar-Meir S, Rotmensch S. Investigation of obstructive jaundice by an ultra-thin-caliber endoscope: a new technique for potential use in pregnancy. *Am J Obstet Gynecol* 1984;150(8):1003–1004
- 50 Baillie J, Cairns SR, Putman WS, Cotton PB. Endoscopic management of choledocholithiasis during pregnancy. *Surg Gynecol Obstet* 1990;171(1):1–4
- 51 Cappell MS. The fetal safety and clinical efficacy of gastrointestinal endoscopy during pregnancy. *Gastroenterol Clin North Am* 2003;32(1):123–179
- 52 Baron TH, Schueler BA. Pregnancy and radiation exposure during therapeutic ERCP: time to put the baby to bed? *Gastrointest Endosc* 2009;69(4):832–834

- 53 Binmoeller KF, Katon RM. Needle knife papillotomy for an impacted common bile duct stone during pregnancy. *Gastrointest Endosc* 1990;36(6):607–609
- 54 Nesbitt TH, Kay HH, McCoy MC, Herbert WN. Endoscopic management of biliary disease during pregnancy. *Obstet Gynecol* 1996;87(5 Pt 2):806–809
- 55 Rahmin MG, Hitscherich R, Jacobson IM. ERCP for symptomatic choledocholithiasis in pregnancy. *Am J Gastroenterol* 1994;89(9):1601–1602
- 56 Girotra M, Jani N. Role of endoscopic ultrasound/SpyScope in diagnosis and treatment of choledocholithiasis in pregnancy. *World J Gastroenterol* 2010;16(28):3601–3602
- 57 Lee JJ, Lee SK, Kim SH, et al. Efficacy and safety of pancreatobiliary endoscopic procedures during pregnancy. *Gut Liver* 2015;9(5):672–678
- 58 Roumieu F, Ponchon T, Audra P, Gaucherand P. Acute pancreatitis in pregnancy: place of the different explorations (magnetic resonance cholangiopancreatography, endoscopic ultrasonography) and their therapeutic consequences. *Eur J Obstet Gynecol Reprod Biol* 2008;140(1):141–142
- 59 Chong VH. EUS complements ERCP during pregnancy. *Gastrointest Endosc* 2009;70(6):1285–1286, author reply 1286–1287
- 60 Magno-Pereira V, Moutinho-Ribeiro P, Macedo G. Demystifying endoscopic retrograde cholangiopancreatography (ERCP) during pregnancy. *Eur J Obstet Gynecol Reprod Biol* 2017;219:35–39
- 61 Hogan RB, Ahmad N, Hogan RB II, et al. Video capsule endoscopy detection of jejunal carcinoid in life-threatening hemorrhage, first trimester pregnancy. *Gastrointest Endosc* 2007;66(1):205–207
- 62 Van Bodegraven AA, Böhmer CJ, Manoliu RA, et al. Gallbladder contents and fasting gallbladder volumes during and after pregnancy. *Scand J Gastroenterol* 1998;33(9):993–997
- 63 Aicart Ramos M, Volpato N, López San Román A. Retained capsule in Crohn's disease: what happens if i get pregnant? *J Crohn's Colitis* 2015;9(6):516
- 64 Ryan ME. Endoscopic management of a pancreatic pseudocyst during pregnancy. *Gastrointest Endosc* 1992;38(5):605–608
- 65 Gyokeres T, Topa L, Marton I, Pap A. Endoscopic cystogastrostomy during pregnancy. *Gastrointest Endosc* 2001;53(4):516–518