



CT-Based Definition and Structured Reporting of Abdominal Lymph Node Stations

Ishan Kumar¹  Srishti Sharma¹ Aditya Prakash¹ Priyanka Aggarwal² Ram C. Shukla¹ Ashish Verma¹

¹Department of Radiodiagnosis and Imaging, Institute of Medical Sciences, Banaras Hindu University, Varanasi, Uttar Pradesh, India

²Division of Pediatric hematology and Oncology, Department of Pediatrics, Institute of Medical Sciences, Banaras Hindu University, Varanasi, Uttar Pradesh, India

Address for correspondence Ashish Verma, MBBS, DNB, PhD, Department of Radiodiagnosis and Imaging, Institute of Medical Sciences, Banaras Hindu University, Varanasi 221005, Uttar Pradesh, India (e-mail: drdnv5@gmail.com).

Indian J Radiol Imaging 2022;32:62–70.

Abstract

Background Meticulous evaluation of abdominal lymph nodes on computed tomography (CT) is a fundamental task in radiological practice especially in oncological reporting. Although various reporting systems exist to define abdominal nodal stations for malignancies of individual abdominal organs, a complete and uniform framework for radiological reporting of abdominal lymph nodes does not exist in the literature.

Purpose The goal of this review was to provide a step-wise reporting template and precise definitions of the radiological anatomy of abdominal lymph nodes and to generate a CT-based illustration of the lymph node stations of the abdomen.

Conclusion This CT-based illustration and reporting template will help the radiologists to aptly describe the extent of the lymph nodal diseases and will help in comparison with posttherapy scans.

Keywords

- ▶ lymph node
- ▶ anatomy
- ▶ CT

Introduction

Lymph node (LN) metastasis is frequently seen in most primary abdominal malignant tumors. An accurate description of lymph nodal location is essential for appropriate staging and treatment of the disease. The Japanese Gastric Cancer Association (JGCA) classifies the regional LNs draining the stomach into 33 regional lymphatic stations to assess the extent of lymphatic spread in gastric carcinoma. Similar classification schemes of lymph nodal disease have been proposed for pancreatic and pelvic cancers. However, a complete template for reporting of entire abdominal lymph nodal stations does not exist in the literature. Although a structured reporting template may lead to an increase in reporting time, such detailed and pedantic evaluation of all the nodal stations of the abdomen may have several advantages. First, when the site of the primary tumor is

known, it allows step-by-step evaluation of nodal spread of the disease especially for inexperienced and trainee radiologists so that no clinically and surgically relevant LN is missed.^{1–3} Second, identification of unexpected or distant adenopathy that is not routinely resected can be more readily achieved. Third, it also allows a more meticulous comparison of the post- and pretreatment scans to identify residual or recurrent disease or disease progression after treatment by looking at the nodal station beyond the treated site. Lastly, the past few years have witnessed a considerable rise in interest toward machine learning applications and artificial intelligence (AI) in radiology. Large, standardized data of adequate quality is required to train the AI algorithms. The information extracted from template-based structured reports can be more efficiently used for training of AI algorithms and thus we emphasize the usage of template-based reporting to gather data that can be utilized

published online
April 6, 2022

DOI <https://doi.org/10.1055/s-0041-1741089>.
ISSN 0971-3026.

© 2022. Indian Radiological Association. All rights reserved.

This is an open access article published by Thieme under the terms of the Creative Commons Attribution-NonDerivative-NonCommercial-License, permitting copying and reproduction so long as the original work is given appropriate credit. Contents may not be used for commercial purposes, or adapted, remixed, transformed or built upon. (<https://creativecommons.org/licenses/by-nc-nd/4.0/>)

Thieme Medical and Scientific Publishers Pvt. Ltd., A-12, 2nd Floor, Sector 2, Noida-201301 UP, India

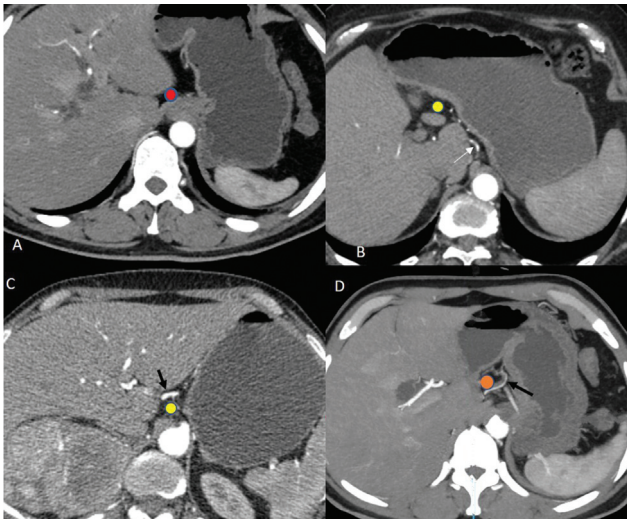


Fig. 1 Perigastric lymph nodes (LNs) along lesser curvature. Locations of (A) right paracardial LN (red). (B) Lesser curvature LN (yellow) along branches of the left gastric artery (white arrow). (C) Lesser curvature LN (yellow) along right distal gastric artery (black arrow). (D) Suprapyloric LN (orange) along proximal right gastric artery (black arrow).

to facilitate research. This pictorial review article aimed to provide a step-wise reporting template and precise definitions of the computed tomography (CT) anatomy of abdominal LNs.

Perigastric Lymph Nodes

The regional LNs of the stomach are classified into stations numbered from 1 to 20 as per the JGCA classification.^{4,5}

At Lesser Curvature (– Fig. 1)

- Right paracardial LN: at the right side of cardia along the first ramification of the ascending branch of the left gastric artery.
- Lesser curvature LN: at the lesser curvature of the stomach along branches of the left gastric artery and along the right gastric artery distal to the first gastric branch.

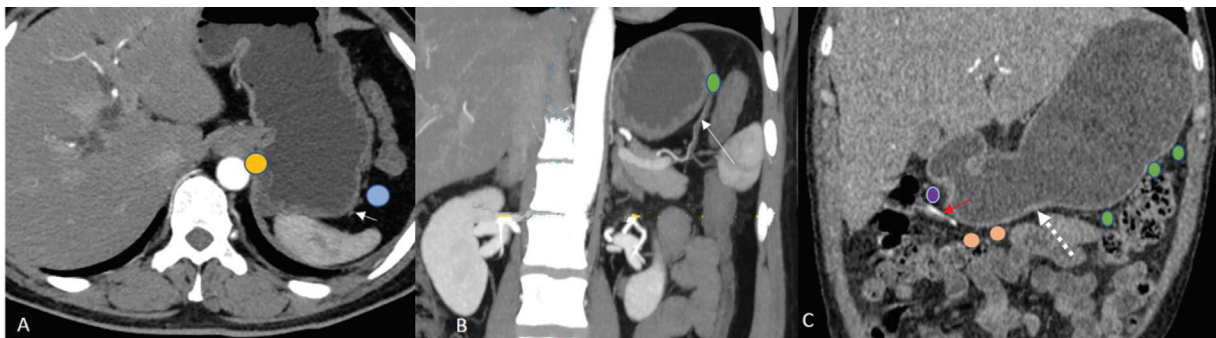


Fig. 2 Perigastric lymph nodes (LNs) along greater curvature. Locations of (A) left paracardial LN (yellow) seen on left side of cardia and proximal left greater curvature LN (blue) along short gastric artery (white arrow). (B) Distal left greater curvature LN (green) along the left gastroepiploic artery (white long arrow). (C) Right greater curvature LN (orange) along distal part of the right gastroepiploic artery (red arrow) and infrapyloric LN (purple) is seen along proximal right gastroepiploic artery. White dashed line shows the approximate position of Von Ghoe point superior to which is distal left greater curvature LN (green).

- Suprapyloric nodes: at the lower aspect of lesser curvature above pylorus along the proximal right gastric artery.

At Greater Curvature (– Fig. 2)

- Left paracardial LN: on the left side of the cardia.
- Greater curvature LN: divided into two groups into right and left greater curvature LN separated by the Von Ghoe point, where right and left gastroepiploic arteries meet each other.
 - Proximal left greater curvature LN: around the short gastric artery.
 - Distal left greater curvature LN or left gastrointestinal LN: around the left gastroepiploic artery.
 - Right greater curvature LN or right gastrointestinal LN: along the second branch and distal part of the right gastroepiploic artery.
- Infrapyloric LN: at the greater curvature immediately below the pylorus near the confluence of the right gastroepiploic vein with the anterior inferior pancreaticoduodenal vein.

Second-Tier Perigastric LN (– Fig. 3)

- Left gastric artery nodes: at the lesser curvature along the left gastric artery between its roots from the celiac trunk till the origin of its ascending branch.
- Common hepatic artery nodes: near lesser curvature along common hepatic artery.
- Celiac trunk nodes immediately near the celiac trunk at its trifurcation.
- Hepatoduodenal ligament LN: located in hepatoduodenal ligament between upper pancreatic margin and the confluence of the right and left biliary duct
- Left hepatoduodenal ligament LN: along the hepatic artery
- Posterior hepatoduodenal ligament LN: along common hepatic duct and common bile duct and posterior to the portal vein.
- Omental foramen (foramen of Winslow) LN: LN present at foramen situated between the two great veins of the abdomen (portal vein and inferior vena cava [IVC]).

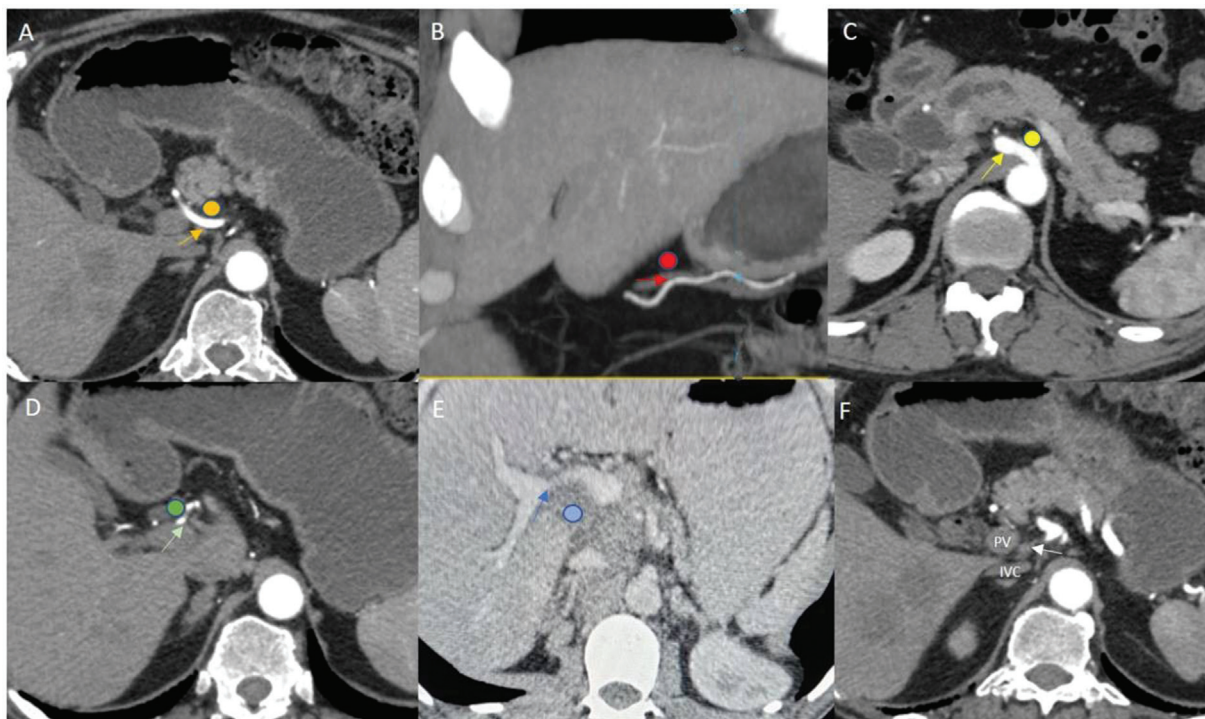


Fig. 3 Second-tier perigastric lymph nodes (LNs). Locations of (A) common hepatic artery nodes (yellow) along common hepatic artery (yellow arrow). (B) Left gastric artery node (red) is seen along proximal left gastric artery (red arrow). (C) Celiac trunk nodes (yellow) are seen near the celiac trunk (yellow arrow). (D) Left hepatoduodenal ligament LN (green) along hepatic artery (green arrow). (E) Posterior hepatoduodenal ligament nodal mass (blue) posterior to portal vein (blue arrow) along common hepatic duct and common bile duct. (F) Location of Omental foramen LN (white arrow) between portal vein (PV) and Inferior vena cava (IVC).

Gastric cancers located at greater curvature spread to the greater curvature, gastroduodenal, gastroepiploic, pyloric, and pancreaticoduodenal LNs. Gastric cancers arising from lesser curvature spreads to lesser curvature, left gastric, common hepatic, and hepatoduodenal LN. Subsequently, the celiac nodes can also get involved.^{4,5}

Peripancreatic LN (→ Fig. 4)

- Anterior pancreaticoduodenal LN: along the anterior surface of the pancreas.
- Posterior pancreaticoduodenal LN/retropancreatic LN: follow the CBD along the posterior pancreaticoduodenal vessels.

- The inferior pancreaticoduodenal LN: along the inferior pancreaticoduodenal artery drain to nodes along superior mesentery artery (SMA) or proximal jejunal mesentery.
- Dorsal pathway:
 - LN along the posterior aspect of the superior portion of the head of the pancreas.
 - LN along the posterior aspect of the inferior portion of the head of the pancreas.
- Body and tail: LN along dorsal pancreatic artery or splenic artery draining to celiac LN.
- LNs along the proximal splenic artery.
- LNs along the distal splenic artery.
- Splenic hilar LN.

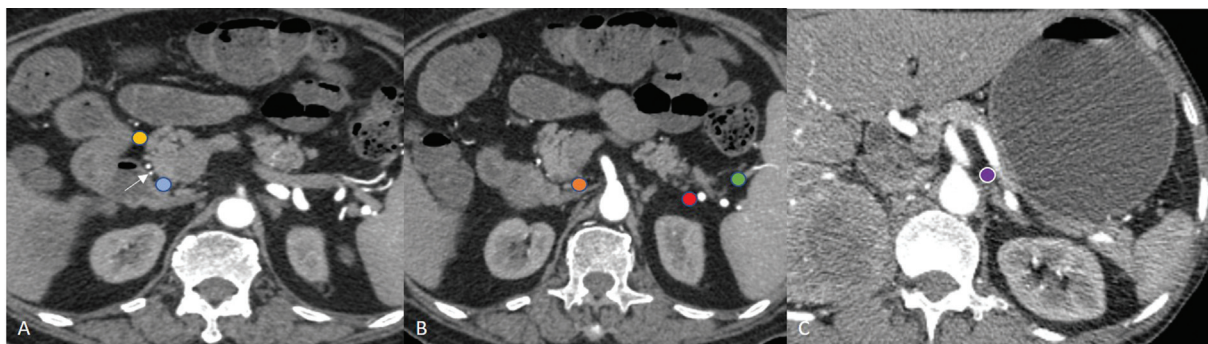


Fig. 4 Peripancreatic lymph nodes (LNs). Locations of (A) anterior pancreaticoduodenal LN (yellow) at anterior surface of the pancreas and posterior pancreaticoduodenal LN (blue) along posterior pancreaticoduodenal artery (arrow). (B) Inferior pancreaticoduodenal LN (orange) near inferior pancreaticoduodenal artery; LN along distal splenic artery (red) and splenic hilar (green) LN are seen. (C) Location of proximal splenic artery LN (purple).

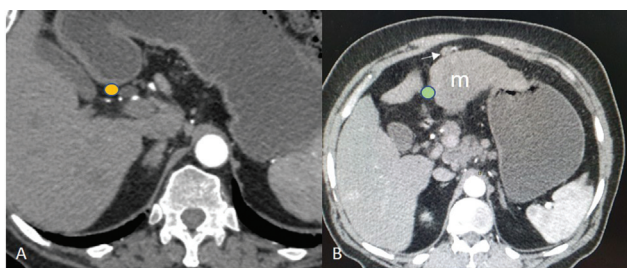


Fig. 5 Hepatic lymphatic drainage. (A) Location of cystic lymph node (LN) (yellow) near cystic duct and gall bladder neck. (B) Deep superior epigastric LN (arrow) in subxiphoid area and falciform ligament LN (green).

Cancers involving head of pancreas spread to anterior and posterior pancreaticoduodenal LNs, whereas those involving the body and tail spread to LNs along splenic artery and splenic hilar LNs. Thereafter, the tumor can extend to celiac and superior mesenteric LNs. It should be noted that nodes along gastroduodenal and pancreaticoduodenal arteries are routinely resected. However, nodes at an abnormal location such as proximal jejunal mesentery and transverse mesocolon should be reported separately, as they may lead to recurrence.

Liver (→ Fig. 5)

Superficial lymphatic drainage

- Gastrohepatic and hepatoduodenal ligament LN.
- Diaphragmatic LN plexus through the bare area, coronary or triangular ligament.
- Falciform ligament to deep superior epigastric LN in subxiphoid area.

Deep lymphatic drainage from the liver is through cystic LN near the gall bladder neck or through hepatoduodenal ligament lymph nodes (explained earlier) of which, the hepatic artery chain drains to cisterna chili and posterior periportal chain drains to retropancreatic and subsequently aortocaval LN. Hepatocellular carcinoma involves the hepatoduodenal and caval LNs and LNs along the hepatic artery. Subsequently the celiac LNs get involved.

Small and Large Bowel LNs

Small Bowel (→ Fig. 6)

The path of regional nodal metastasis follows the vessels of the involved segment to the root of the SMA near the head of the pancreas and the extra peritoneum.⁶ LN metastasis is rare in the tumors of the appendix. Generally, nodal metastasis follows the ileocolic vessels along the root of the mesentery to the origin of the SMA and the paraaortic region.⁶

- Juxtaintestinal LN: along peripheral arterial arcades.
- Intermediate mesenteric nodes: along the jejunal and ileal arteries.
- Central superior mesenteric nodes: along the length of the SMA.

Colon (→ Fig. 7)

Lymphatic drainage from the ascending colon and proximal two-thirds of the transverse colon is to the colic LNs and the superior mesenteric LNs.

The lymph from the distal one-third of the transverse colon, the descending colon, the sigmoid colon, and the upper rectum drains into the inferior mesenteric and colic LNs.⁷ The lower rectum to the anal canal above the pectinate line drains to the internal iliac nodes. The anal canal below the pectinate line drains into the superficial inguinal nodes.⁸

- Appendix drain to periappendiceal LN that drains into SMA.
- Cecum: anterior cecal and posterior cecal LN.
- Epicolic LN: near the wall of gut accompanying vasa recta.
- Paracolic: along the marginal vessels at the medial side of ascending and descending colon and along the mesocolic border of the transverse and sigmoid colon.
- Intermediate mesocolic LN includes LN along with ileocolic, right colic, middle colic, left ascending and descending colic, left colic, or sigmoidal arteries.
- Principal/terminal LN at the origin of IMA, SMA, middle colic origin artery, gastrocolic trunk.
- Perirectal LN:
 - Along superior hemorrhoidal artery toward mesorectum.

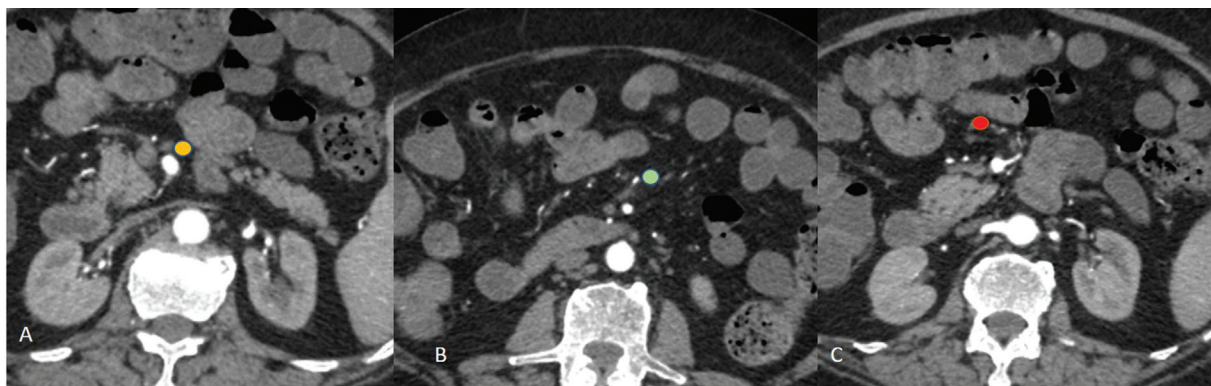


Fig. 6 Lymph nodes (LNs) of small bowel. Locations of (A) central superior mesenteric nodes (yellow) along superior mesentery artery. (B) Intermediate mesenteric nodes (green) along the jejunal and ileal arteries and (C) juxtaintestinal LN (red) along peripheral arterial arcades.

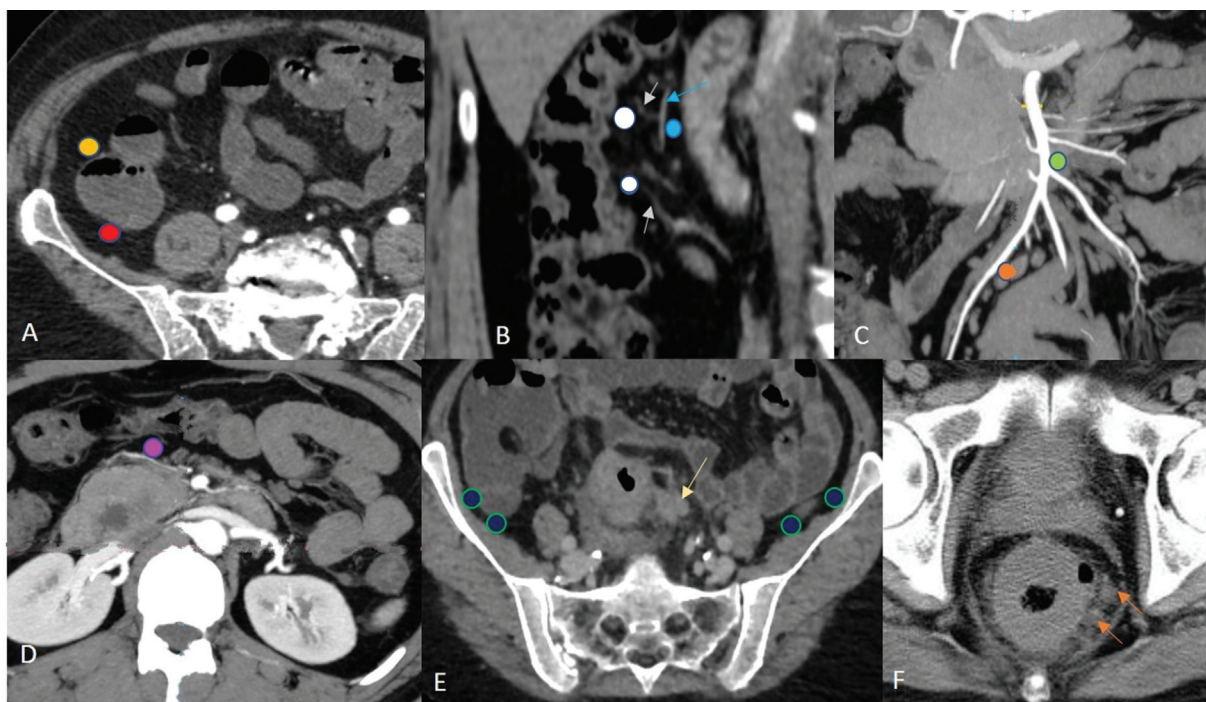


Fig. 7 Lymph nodes (LNs) of colon. Locations of (A) anterior (yellow) and posterior pericecal LN (red) near cecum. (B) Epicolic LN (white) accompanying vasa recta (white arrow) and paracolic LN (blue) along the marginal vessels (blue arrow). (C) Intermediate mesocolic LN (orange) along ileocolic artery and terminal LN (green) along superior mesentery artery. (D) Middle colic LN (pink) along middle colic artery. (E) Mesosigmoid colon LN (yellow arrow) near malignant thickening of sigmoid colon. Also shown is the location of posterior iliac crest LN (navy blue). (F) Mesorectal LN (orange arrow) within the mesorectal fascia in a case of carcinoma rectum.

- Along middle and inferior hemorrhoidal artery toward hypogastric and obturator LN.
- Anal canal:
 - Above the pectinate line: internal iliac LNs.
 - Below the pectinate line: superficial inguinal LNs.

The pericolic LNs are the first to get involved in colorectal carcinoma. Tumors of ascending colon spread to right colic nodes, whereas tumors up to two-thirds of transverse colon spread to middle colic nodes. Tumors to descending colon spread to left colic nodes. Thereafter, tumors arising up to two-thirds of transverse colon involve the superior mesen-

teric nodes and tumors of descending colon, sigmoid, and rectum involve the inferior mesenteric nodes.

Retroperitoneal and Pelvic LNs

Retroperitoneal LNs (→ Fig. 8)

The retroperitoneal and pelvic LNs can be divided into five main groups namely paraaortic, common iliac, internal iliac, external iliac, and inguinal.⁶ Paraaortic LNs can be divided into seven groups based on their relation with aorta and IVC: retrocaval, precaval, laterocaval, aortocaval, preaortic, retroaortic, and lateral aortic groups. Of these, the first four are sometimes called right lateroaortic LNs. Some authors divide

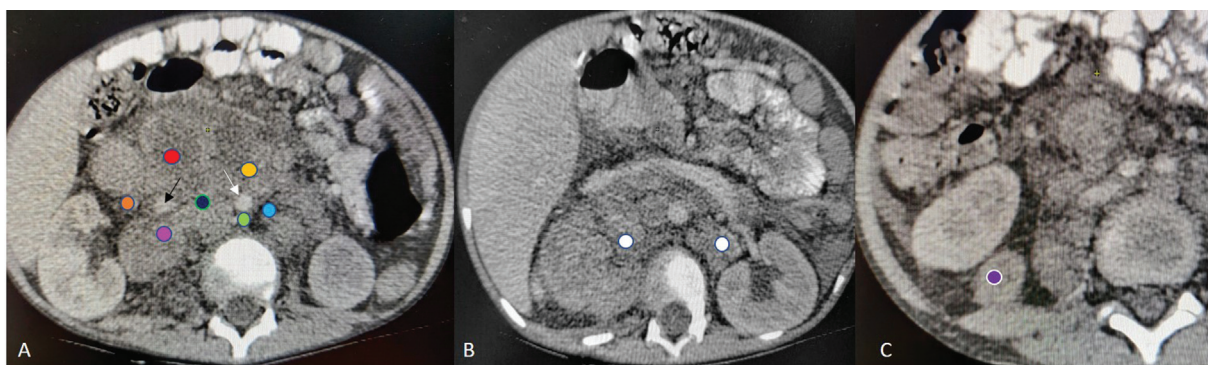


Fig. 8 Retroperitoneal lymph nodes (LNs). (A) Enlarged LNs in the laterocaval (orange), precaval (red), retrocaval (pink), aortocaval (navy blue), preaortic (yellow), retroaortic (green), and lateral aortic regions (sky blue). White and black arrows mark the aorta and inferior vena cava. (B) Enlarged bilateral renal hilar LN (white) (C) Enlarged right posteroinferior pararenal LN (purple).

retroperitoneal LN into left lumbar (paraaortic), right lumbar (paracaval), and intermediate lumbar (aortocaval) LN. In the JGCA classification, these LN are divided into aortic hiatus LN, middle paraaortic, and caudal paraaortic based on their location in relation to the origin of the celiac trunk, left renal vein, inferior mesenteric artery, and aortic bifurcation.

- Aortic hiatus LNs are seen around the diaphragmatic aortic hiatus up to the upper border of the celiac artery.
- Middle paraaortic LNs extend from the celiac artery to the lower border of the left renal vein;
- Middle paraaortic LNs are located from the lower border of the left renal vein to the upper border of the origin of the inferior mesenteric artery; right and left borders are defined by the right border of the IVC and by the left gonadic vessels.
- Caudal paraaortic LNs are located between the upper border of the origin of the inferior mesenteric artery and the aortic bifurcation.

Laterally, the retroperitoneal LN also includes those in relation to both kidneys (perirenal LN).

- Renal hilar LNs: along the main renal vessels.
- Suprahilar LN: area between the upper pole of the kidney and the ipsilateral great vessel.
- Posterosuperior perirenal LN: perirenal space posterior to the upper pole of the kidney
- Posteroinferior perirenal LN: posterior to the lower pole of kidneys.

Pelvic LNs

The common iliac LNs are seen in the vicinity of common iliac arteries and can be divided into three main groups⁹⁻¹¹ (► Fig. 9).

- The lateral common iliac node chain, an extension of the lateral chain of the external iliac LN group, is situated lateral to the common iliac artery.¹⁰
- The medial chain occupies a triangular area bordered by the common iliac arteries and includes LNs at the sacral promontory.¹⁰
- The middle chain consists of LNs of the lumbosacral fossa, the area bordered posteromedially by the lower lumbar or upper sacral vertebral bodies, anterolaterally by the psoas

muscle, and anteromedially by the common iliac artery and common iliac vein.⁶

Similarly, the external iliac nodal group (► Fig. 9) is divided into lateral, medial, and middle chain. The lateral chain is situated along and lateral to the external iliac artery. The middle chain is seen between the external iliac artery and the external iliac vein. The medial chain (obturator LNs) consists of LNs medial and posterior to the external iliac vein and obturator internus muscle and anterior to the obturator nerve.

Internal iliac (hypogastric) LNs (► Fig. 10) are seen along the internal iliac artery and their branches. They can be subcategorized into:

- Anterior internal iliac LN: seen anterior to hypogastric vessels at the origin of umbilical and obturator artery.
- Iliac circumflex LN: along the course of the deep iliac circumflex vessels.
- Lateral sacral LNs: along lateral sacral arteries anterior to the first and second sacral foramina.
- Junctional LNs: located at the junction between the internal and external iliac nodal groups.
- LN along visceral branches of the internal iliac artery and internal iliac vein such as those along uterine arteries, the prostatic branch of inferior vesical and middle hemorrhoidal artery, superior and inferior gluteal arteries, and internal pudendal artery.

Perivisceral LNs (► Fig. 10)

These nodes are seen adjacent to the pelvic organs and are regional nodes for the respective organ adjacent to which they lie¹²:

- Perirectal LN (mesorectal LN): these nodes are present within the mesorectal fat along the superior hemorrhoidal vessels into the inferior mesenteric vessel nodal group.
- Perivesical LN: located near the urinary bladder.
- Prevesicular (anterior vesical) LN: anterior to urinary bladder (UB).
- Postvesicular LN: posterior to UB.
- Lateral vesicular (lateral vesical) LN: to the right and left of UB along lateral umbilical ligaments.
- Periprostatic LN and periseminal vesical LN: adjacent to prostate and seminal vesicles.

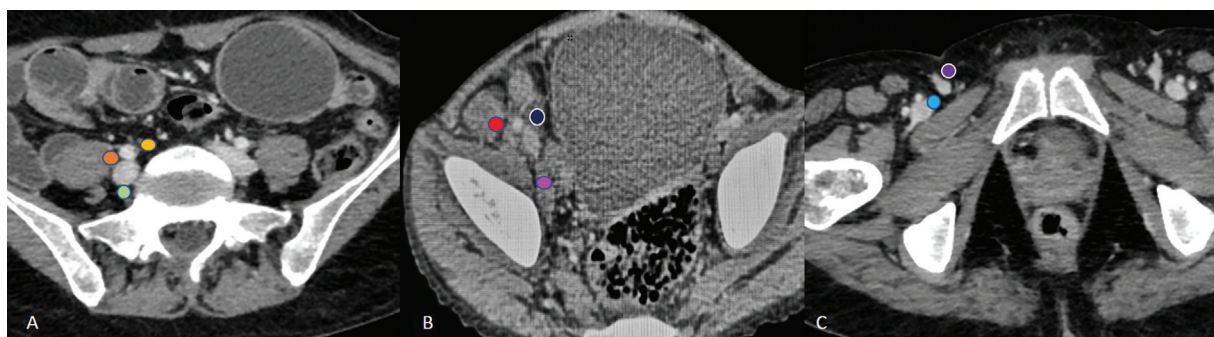


Fig. 9 (A) Locations of lateral (orange), medial (yellow), and middle chain (green) of right common iliac lymph nodes (LNs). (B) Lateral (red), middle (navy blue), and medial/ obturator (pink) chains of right external iliac LN. (C) Superficial (purple) and deep (blue) inguinal LNs.

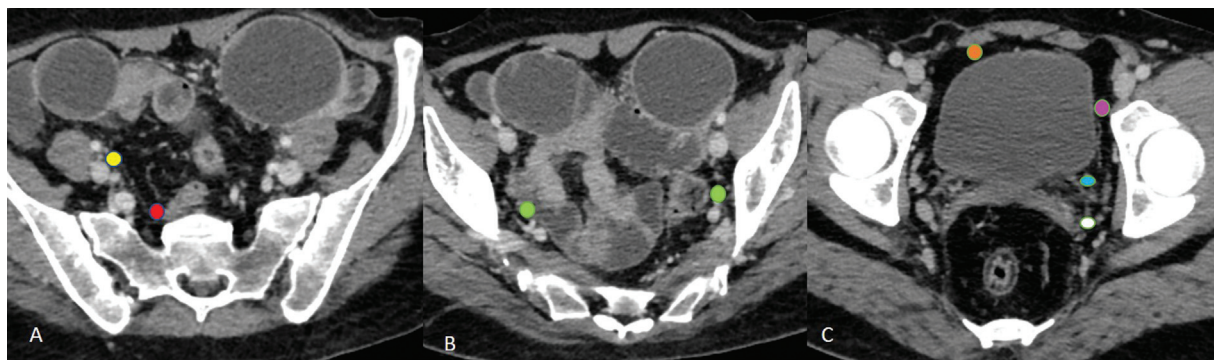


Fig. 10 Hypogastric lymph nodes (LNs). (A) Locations of junctional (yellow), lateral sacral (red), and (B) anterior (green) internal iliac LN. (C) Prevesicular (orange), postvesicular (blue), lateral vesicular (pink), and periseminal vesical (white) LN.

There are four routes of tumoral lymphatic spread in the pelvis.^{9–11} The anterior route extends along the obliterated umbilical artery remnant to the hypogastric nodes and drains to the anterior wall of the bladder. The lateral group drains various pelvic organs to the medial chain of external iliac LN. The organs include upper vagina, cervix, uterus, ovaries, UB, prostate, and rectum. The hypogastric route includes LN along the visceral branches of the hypogastric vessels to the junctional nodes and the common iliac nodes. The presacral route consists of LN in the presacral space or along the uterosacral ligament and can be involved by tumors of the prostate, cervix, and rectum. These nodes can drain into LN at lumbosacral fossa (middle chain) or LN at sacral promontory (medial chain) of Common iliac LNs.

Uncommon lymph nodal pathways for pelvic tumors includes:

- Posterior iliac crest LN: situated at iliac fossa lateral to psoas muscle near iliac wing.
- Mesenteric/mesorectal/sigmoid mesocolon LN.
- Inferior phrenic LN: lateral and anterior to diaphragmatic crura.
- Gonadal vessels LN: for ovarian or testicular tumors.

Inguinal LNs (– Fig. 9)

Inguinal LNs can be divided into superficial and deep groups.

- The superficial inguinal nodes are located in the subcutaneous tissue anterior to the inguinal ligament and accompany the superficial femoral vein and the saphenous vein. These are divided into four zones delineated by imaginary vertical and horizontal lines passing through the saphenofemoral junction.
- Deep inguinal LNs are seen posterior to the inguinal ligament and inferior to the origins of the inferior epigastric and iliac circumflex arteries. The origins of the inferior epigastric and iliac circumflex vessels are the landmarks that allow differentiation between the deep inguinal LNs and the medial chain of the external iliac LNs.

Abdominal Wall LN

- Abdominal wall lymphatic drainage can be divided into anterior abdominal wall and posterior abdominal wall

LNs both of which can be further categorized into superficial and deep LNs.¹³ For anterior abdominal wall, the superficial system is constituted by supraumbilical LN (draining into axillary LN/parasternal LN) or infraumbilical LN that extends along superficial epigastric vessels and drains into the superficial inguinal LNs. Deep system includes:

- The superior epigastric LN: along the superior epigastric artery and drains into the parasternal nodes.
- The inferior epigastric pathway: along the inferior epigastric artery and drains into the external iliac nodes.
- The intercostal pathway: follows in the inferior intercostal and subcostal arteries to the posterior mediastinal nodes.

Posterior abdominal wall LN includes superficial LN along superficial circumflex vessels. Deep lymphatic drainage can be through LN along lumbar arteries (draining into para-aortic LN) or into the deep circumflex iliac artery (draining into external iliac LN) or through intercostal nodes near the heads of the ribs.

Diaphragmatic LNs (– Fig. 11)

Anterior diaphragmatic LN: behind the base of the xiphoid process or near with seventh costal cartilage.

Middle (lateral) diaphragmatic LN: either side close to where the phrenic nerves enter the diaphragm related to the pericardium and lateral aspect of IVC.

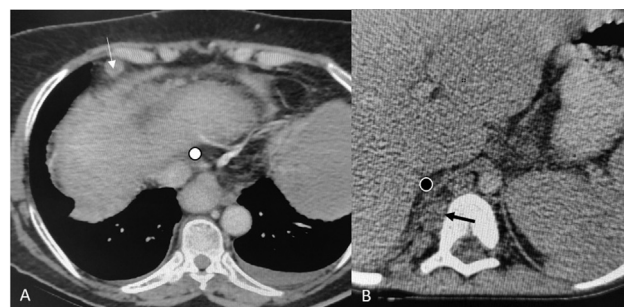


Fig. 11 Diaphragmatic lymph nodes (LNs). (A) Anterior diaphragmatic (white arrow), and location of middle diaphragmatic LN (white circle). (B) Inferior diaphragmatic LN location (black arrow) and retrocrural LN (black circle).

Table 1 Suggested template for reporting of abdominal LNs on CT scan

Region	LN stations
Abdominal wall LN	<i>Anterior</i> Superficial: supraumbilical LN/infraumbilical LN Deep: superior epigastric pathway/inferior epigastric pathway/intercostal pathway <i>Posterior</i> Superficial: LN along superficial circumflex vessels Deep: LN along lumbar arteries/LN along deep circumflex iliac artery
Diaphragmatic LN	Anterior diaphragmatic LN/middle diaphragmatic LN/retrocrural LN/inferior diaphragmatic LN
Liver	Cystic duct LN/gastrohepatic/hepaticoduodenal LN/falciform ligament LN/falciform ligament/deep superior epigastric LN (subxiphoid)
Stomach	At lesser curvature: right paracardial LN/lesser curvature LN/suprapyloric nodes At greater curvature: left paracardial/proximal left greater curvature LN/distal left greater curvature LN/right greater curvature LN/infrapyloric LN Near lesser curvature: left gastric artery LN/common hepatic artery LN/cealic trunk LN/left hepatoduodenal ligament LN/posterior hepatoduodenal ligament LN/foramen of Winslow LN
Pancreas	Pancreaticoduodenal LN: anterior/posterior/inferior Dorsal pathway posterior to pancreatic head: superior/ inferior Body/tail: along proximal splenic artery/along distal splenic artery/splenic hilar LN
Mesenteric LN (small bowel)	Juxtaintestinal LN/intermediate mesenteric nodes/central mesenteric LN
Colon	Cecum: periappendiceal/ anterior cecal/ posterior cecal Colon: epicolic LN/ paracolic LN/intermediate mesocolic/terminal colic LN • Intermediate mesocolic LN: ileocolic LN/right colic LN/middle colic LN/left ascending and descending colic LN/ left colic LN/LN along sigmoidal artery • Terminal colic LN: SMA/IMA/middle colic Perirectal LN: sigmoid mesocolon LN/mesorectal LN Perianal LN: above pectinate line/below pectinate line
Retroperitoneal	Retrocausal LN/ precaval LN/laterocaval LN/aortocaval LN/preaortic LN/retroaortic LN/lateral aortic LN • Level: aortic hiatus LN/ middle paraaortic/ caudal paraaortic Perirenal: renal hilar/suprahilar/posterosuperior perirenal LN/posteroinferior perirenal LN
Pelvic	Common iliac LN: lateral/medial/middle External iliac LN: lateral/middle/obturator Internal iliac LN: Junctional/ anterior/iliac circumflex/lateral circumflex Perivisceral: • perivesical: prevesical/postvesical/lateral vesical • periuterine/parametrial/pericervical LN • periprostatic/ periseminal vesicle LN Others: posterior iliac crest LN/ gonadal vessels LN Inguinal LN: superficial/ deep inguinal LN

Abbreviations: IMA, inferior mesenteric artery; SMA, superior mesenteric artery.

Retrocrural LN (posterior diaphragmatic LN): LN present in the retrocrural space (small triangular region within the most inferior posterior mediastinum and upper abdomen bordered by the two diaphragmatic crura and arcuate ligaments).

Inferior diaphragmatic LN: lateral and anterior to diaphragmatic crura.

Conclusion

Nodal staging is an integral part of determining therapy and prognosis in most primary tumors and the evaluation of LNs involves accurate anatomical localization followed by characterization. The current pictorial review attempts to highlight nodal anatomy of the abdomen with a suggested template for its radiological reporting

(**Table 1**). We hope the content will be useful and informative to a wide range of readers filling in the void about nodal anatomy. We further envisage that the suggested reporting system can evolve after the widespread application of this template and gathering feedback from oncologists. Subsequently, the gathered data can be utilized to facilitate research in AI and machine learning applications.

Compliance with Ethical Standards

*Disclosure of potential conflicts of interest: The authors declare that there is no conflict of interest regarding this manuscript.

*Research involving human participants and/or animals: This was not a study involving human participants/ animals.

Informed Consent

Written informed consent has been taken from the patients whose images have been used in this article.

Conflict of Interest

None.

References

- 1 McDaniel KP, Charnsangavej C, DuBrow RA, Varma DG, Granfield CA, Curley SA. Pathways of nodal metastasis in carcinomas of the cecum, ascending colon, and transverse colon: CT demonstration. *AJR Am J Roentgenol* 1993;161(01):61–64
- 2 Granfield CA, Charnsangavej C, Dubrow RA, et al. Regional lymph node metastases in carcinoma of the left side of the colon and rectum: CT demonstration. *AJR Am J Roentgenol* 1992;159(04):757–761
- 3 Dorfman RE, Alpern MB, Gross BH, Sandler MA. Upper abdominal lymph nodes: criteria for normal size determined with CT. *Radiology* 1991;180(02):319–322
- 4 Japanese Gastric Cancer Association. Japanese classification of gastric carcinoma: 3rd English edition. *Gastric Cancer* 2011;14(02):101–112
- 5 Rosa F, Costamagna G, Doglietto GB, Alfieri S. Classification of nodal stations in gastric cancer. *Transl Gastroenterol Hepatol* 2017;2:2
- 6 Meyers MA, Charnsangavej C, Oliphant M. *Meyers' Dynamic Radiology of the Abdomen: Normal and Pathologic Anatomy*. New York: Springer; 2010
- 7 Snell, Richard S. *Clinical Anatomy for Medical Students*. 4th edition Boston: Little, Brown, and Company; 1992:53–54
- 8 Rouviere H, Tobias MJ, Eds. *Anatomy of the Human Lymphatic System*. Ann Arbor, MI: Edward Brothers; 1938:209–210
- 9 Park JM, Charnsangavej C, Yoshimitsu K, Herron DH, Robinson TJ, Wallace S. Pathways of nodal metastasis from pelvic tumors: CT demonstration. *Radiographics* 1994;14(06):1309–1321
- 10 Paño B, Sebastià C, Buñesch L, et al. Pathways of lymphatic spread in male urogenital pelvic malignancies. *Radiographics* 2011;31(01):135–160
- 11 Paño B, Sebastià C, Ripoll E, et al. Pathways of lymphatic spread in gynecologic malignancies. *Radiographics* 2015;35(03):916–945
- 12 Harisinghani MG, Ed. *Atlas of Lymph Node Anatomy*. New York: Springer Publishing; 2013
- 13 Morón FE, Szklaruk J. Learning the nodal stations in the abdomen. *Br J Radiol* 2007;80(958):841–848