

Clinical Applications of Contrast-Enhanced Ultrasound in the Pediatric Work-Up of Focal Liver Lesions and Blunt Abdominal Trauma: A Systematic Review



Authors

Nicolaj Grønbaek Laugesen¹, Christian Pallson Nolsoe²,
Jacob Rosenberg³

Affiliations

- 1 Neurological, Herlev Hospital, Herlev, Denmark
- 2 Ultrasound Section, Department of Gastroenterology,
Department of Surgery, Herlev Hospital, Herlev, Denmark
- 3 Department of Surgery, Herlev Hospital, University of Copenhagen,
Copenhagen, Denmark

Key words

paediatrics, ultrasound, contrast-enhanced ultrasound, contrast
agents, microbubbles

received 20.06.2016

revised 05.12.2016

accepted 11.12.2016

Bibliography

DOI <http://dx.doi.org/10.1055/s-0042-124502>

Ultrasound Int Open 2017; 3: E2–E7

© Georg Thieme Verlag KG Stuttgart · New York

ISSN 2199-7152

Correspondence

Nicolaj Laugesen, MD
Herlev Hospital, Neurological
Herlev Ringvej 75
2730 Herlev
Denmark
Tel.: +45/224/61 469
n.laugesen@gmail.com

ABSTRACT

In pediatrics ultrasound has long been viewed more favorably than imaging that exposes patients to radiation and iodinated contrast or requires sedation. It is child-friendly and diagnostic capabilities have been improved with the advent of contrast-enhanced ultrasound (CEUS). The application of CEUS is indeed promising. However, no ultrasound contrast agent manufactured today is registered for pediatric use in Europe. The contrast agent SonoVue® has recently been approved by the FDA under the name of Lumason® to be used in hepatic investigations in adults and children. This article reviews the literature with respect to 2 specific applications of CEUS in children: 1) identification of parenchymal injuries following blunt abdominal trauma, and 2) classification of focal liver lesions. Applications were chosen through the CEUS guidelines published by the European Federation of Societies for Ultrasound in Medicine and Biology and World Federation for Ultrasound in Medicine and Biology. Literature was obtained by searching Medline and Pubmed Central (using Pubmed), Scopus database and Embase. CEUS proved to be an effective investigation in the hemodynamically stable child for identifying parenchymal injuries and for the characterization of focal liver lesions. CEUS showed comparable performance to CT and MRI with a specificity of 98 % for identifying benign lesions and a negative predictive value of 100 %. For the applications reviewed here, CEUS holds promising perspectives and can help reduce radiation exposure and use of iodinated contrast agents in pediatrics, thereby potentially reducing complications in routine imaging.

Introduction

The first studies on the clinical use of ultrasound contrast agents were published in the 1990s [1, 2]. Levovist® (Bayer Schering, Berlin, Germany) was the first licensed ultrasound contrast agent, but this product is no longer available. However, SonoVue® (Bracco Imaging, Milan, Italy) was approved by the European Medicines Agency in 2001 and has been marketed since then in Europe. Simultaneous development of new contrast-specific software for high-end ultrasound scanners has enabled the introduction of many novel applications of ultrasound contrast agents. International guidelines for contrast-enhanced ultrasound (CEUS) were

updated in 2011 for non-hepatic use by the European Federation of Societies for Ultrasound in Medicine and Biology [3] and for hepatic applications in collaboration with the World Federation for Ultrasound in Medicine and Biology in 2012 [4].

The advantages of B-mode ultrasound (US) in children are apparent. Besides providing an imaging modality free from ionizing radiation compared to X-ray based imaging, there is no need for sedation, which is necessary in infants and neonates in the case of magnetic resonance imaging (MRI). In addition, CEUS can be performed in a variety of settings, at bedside or in the operating room. The advent of ultrasound contrast media has increased the diagnostic possibilities of ultrasound investigation at little

extra cost. The contrast agents are neither nephro-, hepato- or cardio-toxic and do not require testing of renal function prior to examination as is necessary with other contrast media [5]. Ultrasound contrast agents consist of microbubbles of inert gas with low solubility in blood stabilized by a shell molecule, i. e., phospholipids or albumin. Injected intravenously the contrast medium is strictly intravascular and is cleared through gas exchange in ventilation and the shell molecules are metabolized hepatically. Ultrasound contrast media have been used in diagnosing vesicourethral reflux using intravesical administration [6].

The aim of this review was to evaluate the application of CEUS in children. Existing guidelines were used to identify possible applications. By focusing on work-up where conventional investigations involve exposure to ionizing radiation or the requirement of sedation, 2 applications were chosen as the subject of review: 1) the identification of parenchymal injuries following blunt abdominal trauma and 2) the classification of focal liver lesions.

Off-label use

The European Medicines Agency registered SonoVue® in 2001 for use in adults in echocardiography and for the assessment of arteries and portal vein assessment as well as for the evaluation of the vascularity of lesions in the liver and breast. The identical product is registered by the US Food and Drug Administration under the name of Lumason® and is licensed for use in echocardiography in adults as well as in the characterization of focal liver lesions in adults and children. The license was expanded recently and could possibly mean a breakthrough in research. Until now the majority of CEUS research has been performed in Europe. However, this seems likely to change [7]. According to the manufacturer, the dosage of Lumason® is weight-dependent at 0.03 mL per kg with a maximum of 2.4 mL per injection and may be repeated once [8].

Applications other than those licensed are termed off-label.

There is no legal or regulatory hindrance to the use of off-label drugs [9]. The General Medical Council of the United Kingdom advise off-label prescription only if the physician deems it necessary for the individual patient and under the informed consent from the patient or guardian under the following conditions: a) if there is sufficient experience or data demonstrating safety and efficacy, b) with the physician taking full responsibility for overseeing the patient's care and c) taking proper recordings of the use [10]. Off-label use is generally widespread especially in the area of pediatrics, as many drugs are not tested separately in children. One survey found that 40.2% of children taking medicines in a German outpatient setting had been administered at least one off-label drug [11]. Similar numbers have been reported in the USA [12]. However, off-label use in children is not entirely unproblematic as the number of adverse events may be higher and more serious when using drugs off-label [13]. With this in mind, ultrasound contrast media have safety data in adults showing fewer adverse events compared to other contrast media, i. e., iodinated contrast media used in computed tomography (CT), which is not registered for use in children, but is considered essential in clinical practice [14–17].

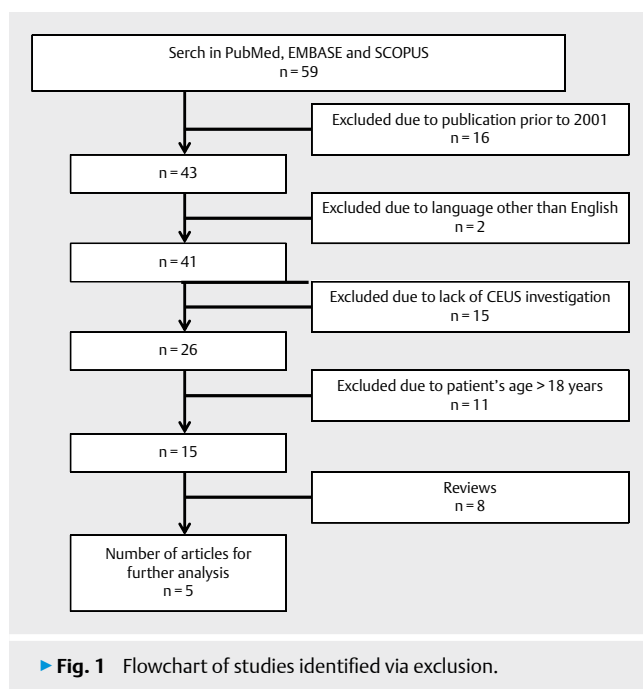
Methods

To obtain literature, a search was carried out using Medline and Pubmed Central (by Pubmed), Scopus database and Embase for relevant papers. Search terms were separated in 2 categories, each representing an important concept, and were combined using the AND operator. Terms in each individual group were combined by OR. No filters or limits were applied to the search. No additional papers were found when searching Scopus and Embase (when excluding abstracts for poster presentations), than already found through Pubmed.

The following search string was used: ("Ultrasonography"[Mesh] OR "ultrasonography" OR "ultrasound" OR "US") AND ("Contrast Media"[Mesh] OR "contrast") AND ("Pediatrics"[Mesh] OR "paediatrics" OR "paediatrics" OR child *) AND (blunt abdominal trauma OR "focal liver lesions"). Data was collected until January 1, 2016. Exclusion criteria were: Publication date prior to 2001, published in language other than English, lack of CEUS investigation, patient population not including only children (age 0–18).

Results

The search identified 59 papers. 16 papers were excluded due to publication earlier than 2001 (► Fig. 1). 2001 was selected due to the release of second-generation ultrasound contrast agents such as SonoVue®. 2 papers were published in a language other than English and were excluded. The full text of the remaining papers was reviewed and 26 papers were excluded because they either investigated an adult population or did not include a CEUS investigation (► Table 1). In 2 papers, patients were assessed for organ injury and CEUS was compared with US, with contrast-enhanced CT as the reference, and these were chosen for review [18, 19]. In one paper, the authors compared the diagnoses of indeterminate focal liver lesions in CEUS with MRI or CT and this was chosen for review [20]. 2 published single-patient cases concerning CEUS in children are not reviewed here [21, 22].



► **Table 1** Studies included for review with study design and patients.

No.	Author	Title	Study design	Number and age of patients	Range of doses	Ref.
1	Valentino et al., 2008	Blunt abdominal trauma: diagnostic performance of contrast-enhanced US in children—initial experience	Prospective, consecutive case series	27 children; 19M and 8F; mean age 8.9 ± 2.8 (SD)	2 × 2.4 mL injections of SonoVue®	[17]
2	Menichini et al., 2015	Accuracy of contrast-enhanced ultrasound (CEUS) in the identification and characterization of traumatic solid organ lesions in children: a retrospective comparison with baseline US and CE-MDCT	Retrospective case series	73 children; 51M and 22F; mean age 8.7 ± 2.8 (SD)	2 × 1.2 mL injections of SonoVue®	[18]
3	Jacob et al., 2013	Contrast-enhanced ultrasound (CEUS) characterization of grey-scale sonographic indeterminate focal liver lesions in pediatric practice	Retrospective consecutive case series	44 children; F 21 and M 23, median age 11.5 years, range 4–18	1.2–2.4 mL injections. Number of injections in investigation not specified	[19]

Blunt abdominal trauma

One study evaluated US and CEUS in abdominal injuries with contrast-enhanced CT as the reference [18]. Patients were included prospectively and were all hemodynamically stable and had a trauma of moderate-severe degree according to the Abbreviated Injury Scale. A total of 108 consecutive patients were evaluated for eligibility and examined with laboratory tests and for abdominal free fluid with a standardized US examination. Positive findings in either modality meant inclusion and investigation with both contrast-enhanced CT and CEUS. CEUS was performed with two 2.4 mL bolus contrast agent injections of SonoVue® with no adjustment to bodyweight. Each imaging modality was performed and interpreted by the same individual blinded to other imaging results. 27 children (19 M and 8 F, mean age 8.9 years, range 4–13 years) were included. Contrast-enhanced CT showed 14 parenchymal injuries in 12 children. CEUS performed better than B-mode US, where CEUS visualized 13 injuries in 12 children (7 splenic lesions, 4 hepatic, 1 renal, and 1 pancreatic). The single lesion that CEUS failed to demonstrate was a right adrenal gland contusion in a patient with a concurrent splenic injury. Nevertheless, CEUS achieved high sensitivity (92.2 %), specificity (100 %), negative predictive value (100 %) and positive predictive value (93.8 %). In comparison, US performed less well with sensitivity (57.1 %), specificity (86.7 %), negative predictive value (86.4 %) and positive predictive value (80 %). B-mode US found 8 of the 14 organ injuries verified on contrast-enhanced CT and showed abdominal free fluid in 2 patients that reference CT could not reproduce, thus interpreted as false positive. A priori sample size estimation of patients needed to enroll was not calculated.

Another paper recently evaluated CEUS compared to US for assessing parenchymal injuries and prognostic factors following blunt abdominal trauma with contrast-enhanced CT as the reference in a retrospective consecutive case series study [19]. 73 patients (51 M and 22 F, mean (SD) age 8.7 (2.8) years) were recruited from a regional trauma center. All included patients were hemodynamically stable, had a preceding trauma not meeting the Advanced Trauma Life Support criteria for major trauma and at least one positive

finding at baseline B-mode US. Inclusion triggered CEUS and contrast-enhanced CT. CEUS was performed with two 1.2 mL bolus injections of SonoVue® with no adjustment in dose to bodyweight. 6 patients were considered positive for free abdominal fluid on US, but failed to show abdominal organ injury in the following imaging. These were considered to have free fluid of gynecological cause, gastroenteritis and miscellaneous. CEUS identified 67/67 parenchymal injuries: 21 hepatic, 26 splenic and 20 renal injuries. US depicted 26/67 (39 %) parenchymal injuries. In identifying parenchymal injuries, CEUS was superior to US with a sensitivity, specificity, positive predictive value, negative predictive value and accuracy of 100, 100, 100, 100 and 100 % for CEUS and 38.8, 100, 100, 12.8 and 44 % for US. Furthermore, the aim of this study was to identify prognostic indicators so far only visible on contrast-enhanced CT, such as active parenchymal bleeding, partial devascularization, vascular bleeding, and urinomas. Of these, CEUS showed 8/16 cases of active parenchymal bleeding, 1/1 cases of partial devascularization, no active vascular bleeding out of 2 cases, and none of the 2 cases of urinoma. None of the prognostic indicators were shown using US.

Focal liver lesions

One retrospective study enrolled all children examined at a tertiary referral center with indeterminate focal liver lesions on B-mode US in a 5-year period [20]. 44 children (F 21; M 23, median age 11.5 years, range 4–18) were examined using CEUS to determine the origin of the lesion. CEUS was performed with 1.2–2.4 mL bolus injections of the contrast agent SonoVue®. Investigators did not specify the number of bolus injections or provide the arguments for varying doses of contrast agent. Patients were referred if initial B-mode US in another facility failed to characterize the lesion. Patients were either with known chronic liver disease (n = 30), had a history of non-hepatic malignancy with new liver lesions (n = 3) or with no known hepatic disease or malignancies of any kind (n = 11). All underwent standard investigations with contrast-enhanced CT (n = 14), MRI (n = 30) or both (n = 10) and eventually some underwent biopsy (n = 8). In 29 of 34 cases (85.4 %), there was agreement between

CEUS and reference imaging. 4 cases with discordance were seen where CEUS assessed lesions as fatty changes and one case was thought to be a regenerating nodule. None of the 5 pathologies visualized exclusively on contrast-enhanced CT or MRI appeared on follow-up. In the single case of a false-positive outcome in this study, all 3 imaging modalities determined the lesion to be malignant. However, biopsy showed a hepatic adenoma. In this small study, CEUS showed a specificity of 98 % for identifying benign lesions and a negative predictive value of 100 % suggesting that CEUS is comparable in performance to contrast-enhanced CT and MRI.

Discussion

In trauma management of the hemodynamically stable child as well as in the identification of focal liver lesions, CEUS has proven to be an effective investigation. Compared to contrast-enhanced CT, CEUS could confidently identify parenchymal injuries following blunt abdominal trauma of moderate or severe degree not visible using B-mode US. In identifying benign liver lesions, CEUS showed comparable performance to contrast-enhanced CT and MRI. Patients referred for CEUS of the liver had either a history of known chronic hepatic disease and were referred after follow-up had shown a new lesion or they had no known hepatic disease and were referred with an incidental focal liver lesion.

Parenchymal injuries in blunt abdominal trauma

B-mode US is an established modality in traumatology as the Focused Assessment with Sonography in Trauma (FAST) and is advantageous in giving a rapid diagnosis in the hemodynamically unstable patient. However, B-mode US has limitations for the pediatric trauma surgeon in the management of the stable trauma patient due to the shortcomings in identifying injuries without the presence of free fluid in the abdomen [23]. Indeed, 2 studies reported 34–37 % of pediatric patients with CT-verified abdominal parenchymal injuries failing to show free abdominal fluid using B-mode US [24, 25]. Abdominal free fluid from causes other than traumatic injury was found in one reviewed study and questions the reliability of abdominal free fluid as an indirect specific sign of traumatic organ injuries [19].

In the trauma suite, following blunt abdominal trauma, the hemodynamically unstable patient with signs of free fluid in the B-mode US investigation will be taken directly to the operating room, without having a CT performed, so as not to delay operation unnecessarily [26]. CEUS could be promising in identifying the patients first presenting as hemodynamically stable in need of active rather than conservative treatment. It has been argued that CEUS can be considered in the triage of hemodynamically stable children with blunt abdominal trauma [18]. Several studies applying CEUS in blunt abdominal trauma in adults have shown similar results with CEUS outperforming conventional US and comparable to the performance of contrast-enhanced CT [27–30]. It is in agreement with these findings that CEUS could supersede contrast-enhanced CT in the follow-up of trauma and become the main imaging modality in traumas of minor or moderate severity. CEUS represents an option to expedite patient discharge after dismissing abdominal traumatic injuries without unnecessary investigations or admission for observation [31].

Focal liver lesions

Primary liver lesions in children are uncommon and the majority of these lesions are benign. However, benign conditions can undergo malignant transformation, as in cirrhosis with increased risk of developing hepatocellular carcinoma, which makes up 39 % of pediatric hepatic malignancies [32]. An estimated one-third of primary liver masses in children are benign and their characterization using CEUS is well documented [33]. Follow-up of the lesions can be necessary to exclude malignant transformation [34]. For adults, the examination of focal liver lesions is an established application of CEUS and is a candidate to be the primary investigation [4, 35]. The CEUS findings showing a specificity of 98 % for identifying a benign lesion are in correlation with a multicenter study with 1 349 adult patients [35]. CEUS is suggested for potential use as follow-up in children with known hepatic disease, thus minimizing exposure to radiation. As imaging is becoming more readily available, the number of incidentally found focal liver lesions could rise. Consequently, CEUS is a promising tool to minimize radiation exposure and any possible complications hereof following investigations in asymptomatic patients with incidentally identified lesions. Besides the clinical advantages for the individual patient, the economic consequences of using SonoVue® in the characterization of focal liver lesions in adults has been found to be cost-effective [36]. A systematic review published by the National Institute for Health Research of the United Kingdom concluded that CEUS could be of equal importance to contrast-enhanced CT or MRI in the diagnostic work-up of focal liver lesions [37].

Safety data

The safety of ultrasound contrast agents administered intravenously has been assessed in several studies. In one prospective study, a total of 161 investigations with SonoVue® administered intravenously were performed on 137 children (M 83, F 54; mean (SD) age 10.2 (6.0), range 0–18) in a single institution over a period of 2 years [15]. The children were admitted to an observation ward for 24 h following the administration of SonoVue®. One adverse event (anaphylactic shock in an 11-year-old) occurred. It was managed with epinephrine and saline infusions and all symptoms had resolved within 2 h. Although this represents a severe reaction, the overall complication rate is considered low. A low complication rate for SonoVue® has also been shown in a prospective multicenter study comprising 23 188 abdominal investigations in adult patients performed over a period of 4 years. The rate of adverse events was 0.125 % and for serious adverse events it was 0.0086 % [14]. Other ultrasound contrast agents, such as Optison® (GE Healthcare, Princeton, NY, USA), and Definity® (Lantheus Medical Imaging, Billerica, MA, USA), have also been assessed for safety in children with a low complication rate and no serious adverse events [17]. None of the other reviewed papers reported any adverse events.

Outlook

The imaging modality of CEUS was introduced in clinical practice in the 1990s and has since earned a place in the treatment of adults in various settings. Despite the obvious benefits of reducing the exposure of children to radiation and sedation, CEUS has not been readily implemented in pediatric work-up algorithms, as it is off-label. This is a medicolegal challenge, which is preventing physicians

from using this technology [38]. The legislation today is impeding the routine use of ultrasound contrast agents in children, even though interest in the clinical application of CEUS is increasing.

As long as ultrasound contrast agents are not licensed for use in children, we must inform parents or legal guardians of the potential risks and benefits and acquire their informed consent before our examinations. In order to support the future implementation of CEUS in pediatrics and solve some of the current problems with off-label use, the European Federation of Societies for Ultrasound in Medicine and Biology has opened a pediatric registry online and is calling for physicians to take part and register records of clinical experience along with adverse events [39].

CT works best with a certain amount of body fat surrounding the abdominal organ, which most children lack. US excels in the absence of fat and B-mode US has always been of interest when examining children. There are still a number of disadvantages and aspects of CEUS that need to be understood. If the target organ is difficult to visualize on B-mode US, CEUS is likely to add little if any additional information. Training in the use of CEUS and interpreting is instrumental for utilizing the potential of CEUS.

Conclusion

The use of CEUS in pediatric trauma management and in the classification of focal liver lesions is promising. The current licensing of ultrasound contrast agents in Europe makes all uses in pediatric work-up off-label. The present legislation is a hindrance in the routine use of CEUS in children in many countries. Recent expansion of the license of Lumason® in the USA to include pediatric application is a giant leap forward in the replacement of imaging modalities that involve exposure to ionizing radiation and nephrotoxic contrast media in the patients we have the greatest interest in protecting. We hope to see further research and increased awareness of CEUS with the new license.

Conflict of Interest

No conflict of interest has been declared by the author(s).

References

- [1] Bauer A, Hauff P, Lazenby J, von Behren P, Zomack M, Reinhardt M et al. Wideband harmonic imaging: a novel contrast ultrasound imaging technique. *Eur Radiol* 1999; 9 (Suppl 3): S364–S367
- [2] Schroepe BA, Newhouse VL. Second harmonic ultrasonic blood perfusion measurement. *Ultrasound Med Biol* 1993; 19: 567–579
- [3] Piscaglia F, Nolsoe C, Dietrich CF, Cosgrove DO, Gilja OH, Bachmann Nielsen M et al. The EFSUMB Guidelines and Recommendations on the Clinical Practice of Contrast Enhanced Ultrasound (CEUS): update 2011 on non-hepatic applications. *Ultraschall Med* 2012; 33: 33–59
- [4] Claudon M, Dietrich CF, Choi BI, Cosgrove DO, Kudo M, Nolsoe CP et al. Guidelines and good clinical practice recommendations for contrast enhanced ultrasound (CEUS) in the liver – update 2012: a WFUMB-EFSUMB initiative in cooperation with representatives of AFSUMB, AIUM, ASUM, FLAUS and ICUS. *Ultraschall Med* 2013; 34: 11–29
- [5] Jakobsen JA, Oyen R, Thomsen HS, Morcos SK. Safety of ultrasound contrast agents. *Eur Radiol* 2005; 15: 941–945
- [6] Darge K. Voiding urosonography with US contrast agent for the diagnosis of vesicoureteric reflux in children: an update. *Pediatric radiology* 2010; 40: 956–962
- [7] Seitz K, Strobel D. A Milestone: Approval of CEUS for diagnostic liver imaging in adults and children in the USA. *Ultraschall Med* 2016; 37: 229–232
- [8] Bracco. Prescribing information of Lumason 2016 [cited 2016 10/11]. Available from: http://imaging.bracco.com/sites/braccoimaging.com/files/technica_sheet_pdf/us-en-2016-08-26-pi-Lumason_1.pdf
- [9] Barr RG. Off-label use of ultrasound contrast agents for abdominal imaging in the United States. *J Ultrasound Med* 2013; 32: 7–12
- [10] GMC. General Medical Council of the United Kingdom: Good practice in prescribing and managing medicines and devices. <http://www.gmc-uk.org/2016> [updated 02/25/13; cited 2016 09/27]. Available from: http://www.gmc-uk.org/guidance/ethical_guidance/14327.asp
- [11] Knopf H, Wolf IK, Sarganas G, Zhuang W, Rascher W, Neubert A. Off-label medicine use in children and adolescents: results of a population-based study in Germany. *BMC public health* 2013; 13: 631
- [12] Bazzano AT, Mangione-Smith R, Schonlau M, Suttrop MJ, Brook RH. Off-label prescribing to children in the United States outpatient setting. *Academic pediatrics* 2009; 9: 81–88
- [13] EMA. Report on the survey of all paediatric uses of medicinal products in Europe. http://www.ema.europa.eu/ema/index.jsp?curl=pages/regulation/document_listing/document_listing_000096.jsp [cited 2015 1st of November]. Available from: http://www.ema.europa.eu/ema/index.jsp?curl=pages/regulation/document_listing/document_listing_000096.jsp
- [14] Piscaglia F, Bolondi L. The safety of Sonovue in abdominal applications: retrospective analysis of 23188 investigations. *Ultrasound Med Biol* 2006; 32: 1369–1375
- [15] Piskunowicz M, Kosiak W, Batko T, Piankowski A, Polczynska K, Adamkiewicz-Drozynska E. Safety of intravenous application of second-generation ultrasound contrast agent in children: prospective analysis. *Ultrasound Med Biol* 2015; 41: 1095–1099
- [16] Riccabona M. Application of a second-generation US contrast agent in infants and children – a European questionnaire-based survey. *Pediatric radiology* 2012; 42: 1471–1480
- [17] Coleman JL, Navid F, Furman WL, McCarville MB. Safety of ultrasound contrast agents in the pediatric oncologic population: a single-institution experience. *AJR Am J Roentgenol* 2014; 202: 966–970
- [18] Valentino M, Serra C, Pavlica P, Labate AM, Lima M, Baroncini S et al. Blunt abdominal trauma: diagnostic performance of contrast-enhanced US in children – initial experience. *Radiology* 2008; 246: 903–909
- [19] Menichini G, Sessa B, Trinci M, Galluzzo M, Miele V. Accuracy of contrast-enhanced ultrasound (CEUS) in the identification and characterization of traumatic solid organ lesions in children: a retrospective comparison with baseline US and CE-MDCT. *Radiol Med* 2015; 120: 989–1001
- [20] Jacob J, Deganella A, Sellars ME, Hadzic N, Sidhu PS. Contrast enhanced ultrasound (CEUS) characterization of grey-scale sonographic indeterminate focal liver lesions in pediatric practice. *Ultraschall Med* 2013; 34: 529–540
- [21] Yusuf GT, Sellars ME, Huang DY, Deganella A, Sidhu PS. Cortical necrosis secondary to trauma in a child: contrast-enhanced ultrasound comparable to magnetic resonance imaging. *Pediatric radiology* 2014; 44: 484–487
- [22] Wetli SC, Gralla ES, Schibli S, Stranzinger E. Hepatocellular carcinoma and regenerating nodule in a 3-year-old child with Alagille syndrome. *Pediatric radiology* 2010; 40: 1696–1698

- [23] Benya EC, Lim-Dunham JE, Landrum O, Statter M. Abdominal sonography in examination of children with blunt abdominal trauma. *AJR Am J Roentgenol* 2000; 174: 1613–1616
- [24] Taylor GA, Sivit CJ. Posttraumatic peritoneal fluid: is it a reliable indicator of intraabdominal injury in children? *J Pediatr Surg* 1995; 30: 1644–1648
- [25] Emery KH, McAneney CM, Racadio JM, Johnson ND, Evora DK, Garcia VF. Absent peritoneal fluid on screening trauma ultrasonography in children: a prospective comparison with computed tomography. *J Pediatr Surg* 2001; 36: 565–569
- [26] Lee BC, Ormsby EL, McGahan JP, Melendres GM, Richards JR. The utility of sonography for the triage of blunt abdominal trauma patients to exploratory laparotomy. *AJR Am J Roentgenol* 2007; 188: 415–421
- [27] Valentino M, De Luca C, Galloni SS, Branchini M, Modolon C, Pavlica P et al. Contrast-enhanced US evaluation in patients with blunt abdominal trauma(). *J Ultrasound* 2010; 13: 22–27
- [28] Catalano O, Aiani L, Barozzi L, Bokor D, De Marchi A, Faletti C et al. CEUS in abdominal trauma: multi-center study. *Abdominal imaging* 2009; 34: 225–234
- [29] Valentino M, Ansaloni L, Catena F, Pavlica P, Pinna AD, Barozzi L. Contrast-enhanced ultrasonography in blunt abdominal trauma: considerations after 5 years of experience. *Radiol Med* 2009; 114: 1080–1093
- [30] Valentino M, Serra C, Zironi G, De Luca C, Pavlica P, Barozzi L. Blunt abdominal trauma: emergency contrast-enhanced sonography for detection of solid organ injuries. *AJR Am J Roentgenol* 2006; 186: 1361–1367
- [31] Pinto F, Valentino M, Romanini L, Basilico R, Miele V. The role of CEUS in the assessment of haemodynamically stable patients with blunt abdominal trauma. *Radiol Med* 2015; 120: 3–11
- [32] Meyers RL. Tumors of the liver in children. *Surgical oncology* 2007; 16: 195–203
- [33] Chiorean L, Cui XW, Tannapfel A, Franke D, Stenzel M, Kosiak W et al. Benign liver tumors in pediatric patients – Review with emphasis on imaging features. *World J Gastroenterol* 2015; 21: 8541–8561
- [34] Harkanyi Z. Potential applications of contrast-enhanced ultrasound in pediatric patients. *Ultrasound Clinics* 8: 403–422
- [35] Strobel D, Seitz K, Blank W, Schuler A, Dietrich C, von Herbay A et al. Contrast-enhanced ultrasound for the characterization of focal liver lesions – diagnostic accuracy in clinical practice (DEGUM multicenter trial). *Ultraschall Med* 2008; 29 (5): 499–505
- [36] Romanini L, Passamonti M, Aiani L, Cabassa P, Raieli G, Montermini I et al. Economic assessment of contrast-enhanced ultrasonography for evaluation of focal liver lesions: a multicentre Italian experience. *Eur Radiol* 2007; 17 (Suppl 6): F99–F106
- [37] Westwood M, Joore M, Grutters J, Redekop K, Armstrong N, Lee K et al. Contrast-enhanced ultrasound using SonoVue(R) (sulphur hexafluoride microbubbles) compared with contrast-enhanced computed tomography and contrast-enhanced magnetic resonance imaging for the characterisation of focal liver lesions and detection of liver metastases: a systematic review and cost-effectiveness analysis. *Health technology assessment (Winchester, England)* 2013; 17: 1–243
- [38] Nolsoe CP, Lorentzen T. International guidelines for contrast-enhanced ultrasonography: ultrasound imaging in the new millennium. *Ultrasonography (Seoul, Korea)* 2016; 35: 89–103
- [39] EfsUMB. EFSUMB Pediatric Registry [cited 2016 10/8/2016]. Available from: <http://www.efsumb.org/education/scientific-corner01.asp>