



Managing the Lesion and Counseling Patient Post–Breast Biopsy

Bagyam Raghavan¹ M. V. Gautham¹ R. Monushree¹ Ann Kurian¹ Sivaramalingam Geethapriya¹
V. Sathyashree¹

¹Department of Radiodiagnosis, Apollo Speciality Hospital, Chennai, Tamil Nadu, India

Address for correspondence Bagyam Raghavan, MBBS, DMRD, DNB, Department of Radiology, 320, Apollo Speciality Hospital, Padma Complex, Anna Salai, Teynampet, Chennai 600035 (e-mail: drbagyam@gmail.com).

Indographics 2022;1:91–100.

Abstract

Breast cancer is the leading cause of cancer deaths worldwide among women. Early diagnosis and prompt treatment offers a chance for cure and long-term survival among afflicted women. Triple assessment which includes clinical examination, radiological imaging and histopathological evaluation has become a standard of care in the evaluation of breast cancer. Radiological imaging involves mammography, ultrasound, and magnetic resonance imaging while pathological evaluation can be done on fine needle, core-needle, and surgical excision biopsy specimens with core needle biopsy being the workhorse for diagnosis. While triple assessment has increased the diagnostic yield and helps in the identification of early lesions, an increasing subset of patients present with a situation where the imaging and pathological characteristics of a lesion do not correlate with each other thereby causing diagnostic and therapeutic dilemma. Imaging and pathology concordance and discordance present distinctly under differing circumstances in the care of the patient. While those with concordant findings proceed to treatment or follow up directly and hence benefit from the early treatment, those with discordant findings are beset with a delay in the diagnosis and should be subjected to further evaluations for confirming or refuting a diagnosis. This article reviews the salient features of image-guided breast biopsy and the outcomes and management options in imaging and pathology concordance and discordance. We also discuss the role of a radiologist in the counselling of the patient before and after receiving the pathological report after biopsy.

Keywords

- ▶ breast biopsy
- ▶ core-needle biopsy
- ▶ postbiopsy management

Introduction

Breast biopsy is a very important arm of triple testing and is performed in the “one-stop” breast clinic. But the clinical activity needs to have review clinic wherein the results of the biopsy are reviewed, and the patient is counseled postbiopsy before and after the pathology results.

The goal for successful image-guided core-needle breast biopsy is to avoid delay in diagnosing cancer. It depends on the good imaging and pathological correlation, necessitating proper postbiopsy management by auditing the performance of the biopsy procedure, thereby detecting immediately false-negative results, so that discordant

DOI <https://doi.org/10.1055/s-0042-1742573>.

© 2022, Indographics. All rights reserved.

This is an open access article published by Thieme under the terms of the Creative Commons Attribution-NonDerivative-NonCommercial-License, permitting copying and reproduction so long as the original work is given appropriate credit. Contents may not be used for commercial purposes, or adapted, remixed, transformed or built upon. (<https://creativecommons.org/licenses/by-nc-nd/4.0/>)

Thieme Medical and Scientific Publishers Pvt. Ltd., A-12, 2nd Floor, Sector 2, Noida-201301 UP, India

lesions can be prospectively identified and communicated appropriately.

Image-guided percutaneous core-needle biopsy (CNB) has become the backbone and preferred initial minimally invasive diagnostic procedure for nonpalpable or palpable breast masses with high diagnostic accuracy.¹ With advanced technology in both imaging techniques and larger CNB devices, image-guided biopsy is now widely applicable to a majority of the breast lesions, including microcalcifications and nonmass lesions.²⁻⁴

Determining the imaging-pathology concordance after image-guided breast biopsy is essential in validating the biopsy result and to provide appropriate management. In this article, we describe the possible outcomes of image-guided breast biopsy when establishing imaging-pathological concordance and briefly discuss postbiopsy management for each.⁵

Concordance and Discordance

For determining imaging-pathological concordance appropriately, it is important to be familiar with the Breast Imaging Reporting and Data System (BI-RADS) classification for all available imaging modalities.⁵

The imaging and pathologic findings are considered to be concordant when the pathological result provides an acceptable explanation for the imaging features.⁶ Concordance

assessment of the histology, imaging, and clinical findings determines further management and surveillance.

Discordance refers to the situation when a breast CNB demonstrates benign histology while the clinical or imaging findings are suggestive of a possible malignancy or vice versa. This situation requires further evaluation and reviewing the imaging findings and the pathological slides and repeating the biopsy if needed. It might be necessary to repeat the CNB with the larger gauge needle or vacuum-assisted techniques and even surgical excision.⁷⁻¹³

Although there are methods, such as specimen radiography or postbiopsy check mammography to confirm tissue retrieval after performing a core biopsy, they often provide incomplete information, especially in lesions that are visualized by sonography only. Correlation of the pathologic result with the imaging findings after a biopsy is found to be useful to validate the biopsy result and to offer subsequent management.¹⁴⁻¹⁸

Assessment for Concordance

A strong working relationship between the radiologist and pathologist is important for an appropriate imaging-pathology correlation. The pathologist is critical in assessing and communicating the quantitative and qualitative aspects of the biopsy results.^{16,19}

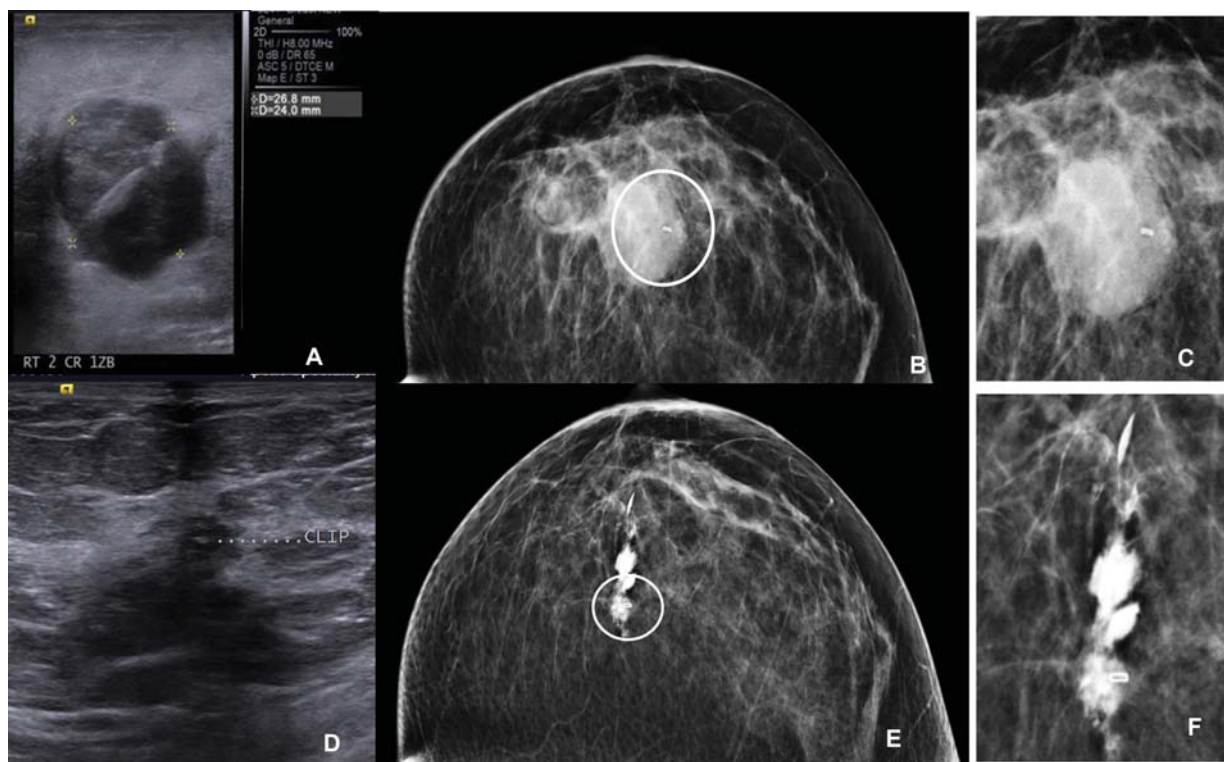


Fig. 1 A 29-year-old female patient came with history of triple negative mass lesion in right breast wanted breast conservation. (A) Ultrasound image before clip insertion. (B) The check mammogram after insertion of a marker clip. (C) Ultrasound of the same lesion postchemotherapy, the lesion has shrunk considerably thereby illustrating the need for clip placement prior to biopsy, so that the area can be correctly identified during surgery. (D) Mammogram after instillation of nonionic contrast to reconfirm the location of the clip prior to wire localization. (E, F) Zoomed up images of (B and D).

Before beginning the biopsy procedure, all imaging features of a targeted lesion like mammography, sonography, and magnetic resonance imaging (MRI) should be carefully reviewed. Then, the core tissue from the targeted lesion should be retrieved and sent for histopathological assessment. When the pathology result has arrived, the radiologist can compare the pathologic diagnosis with the expected result from the imaging finding.

Images documented during the biopsy procedure should also be carefully reviewed to verify whether the lesion was accurately targeted to avoid sampling the wrong lesion and suboptimal sampling (i.e., patient movement or insufficient needle penetration), besides assessing postprocedural complications (bleeding or hematoma formation).^{16,19,20}

This concordance is achieved by adequate targeting, adequate sampling, proper lesion approach, placing biopsy marker (→ Fig. 1), postbiopsy check mammogram, and specimen radiograph (→ Fig. 2).

Accurate Targeting

Microcalcifications are usually targeted using stereotactic guidance by vacuum-assisted devices and specimen mammogram is mandatory.

Sometimes microcalcifications though seen in specimen mammogram can be lost in the histopathological specimen during processing. This is because, the microtome shavings of the first few slices are discarded until a contiguous piece of tissue can be cut and floated onto the slide, this can result in “knocking out” of microcalcifications in which case, it is necessary to X-ray the histopathological blocks. Calcium oxalate crystals can be seen under polarized light and hence the pathologist can then try to see the sample under polarized light.

The advantage of ultrasound-guided breast biopsy over stereotactic biopsy is that targeting the lesion can be monitored by real-time needle visualization and confirmation of adequate tissue sampling.⁵ Placing a metallic marker on the skin over the target lesion and performing mammography before biopsy ensure a good correlation between the lesion

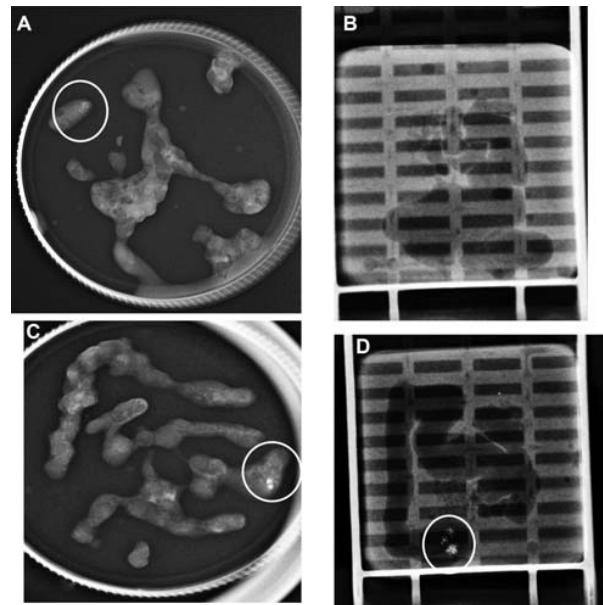


Fig. 2 (A) Postbiopsy specimen mammogram shows the calcification which have been sampled. (B) X-ray of the histopathological blocks of the same patient with the missing calcification. (C) Postbiopsy specimen mammogram in another patient shows the calcification which have been sampled. (D) X-ray of the histopathological blocks of the same patient with the presence of calcification.

seen on mammography and the planned approach for the ultrasound targeting of the lesion.⁵

The radiologist should be aware of any technical difficulties that can cause targeting errors secondary to a poor needle or lesion visualization, deep-seated lesions, mobile lesions, or dense tissue which is difficult to traverse.¹⁴ During the procedure, obtaining postfire needle position verification that shows the entire length of the needle passing through the target lesion by saving ultrasound images is important in assuring that adequate targeting has achieved (→ Fig. 3C).

Occasionally, the ultrasound images during the procedure may appear as if the needle is within a lesion (especially in

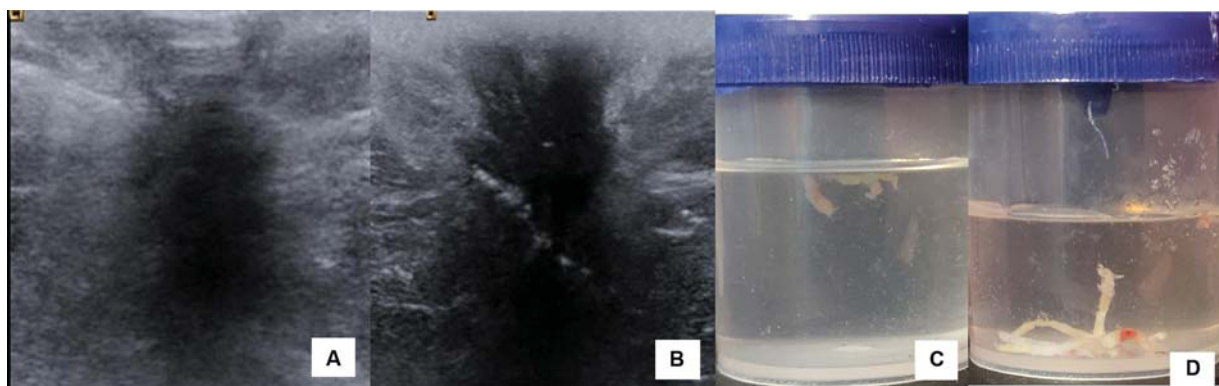


Fig. 3 (A) Biopsy from a spiculated lesion is taken and needle track is seen skimming the top of the resulting in an inadequate sample floating while placed in saline (C) i.e. Image (B) shows repositioning of the needle resulting in a predominantly white sample which sinks to the bottom of the formalin bottle (D) representing an adequate sample.

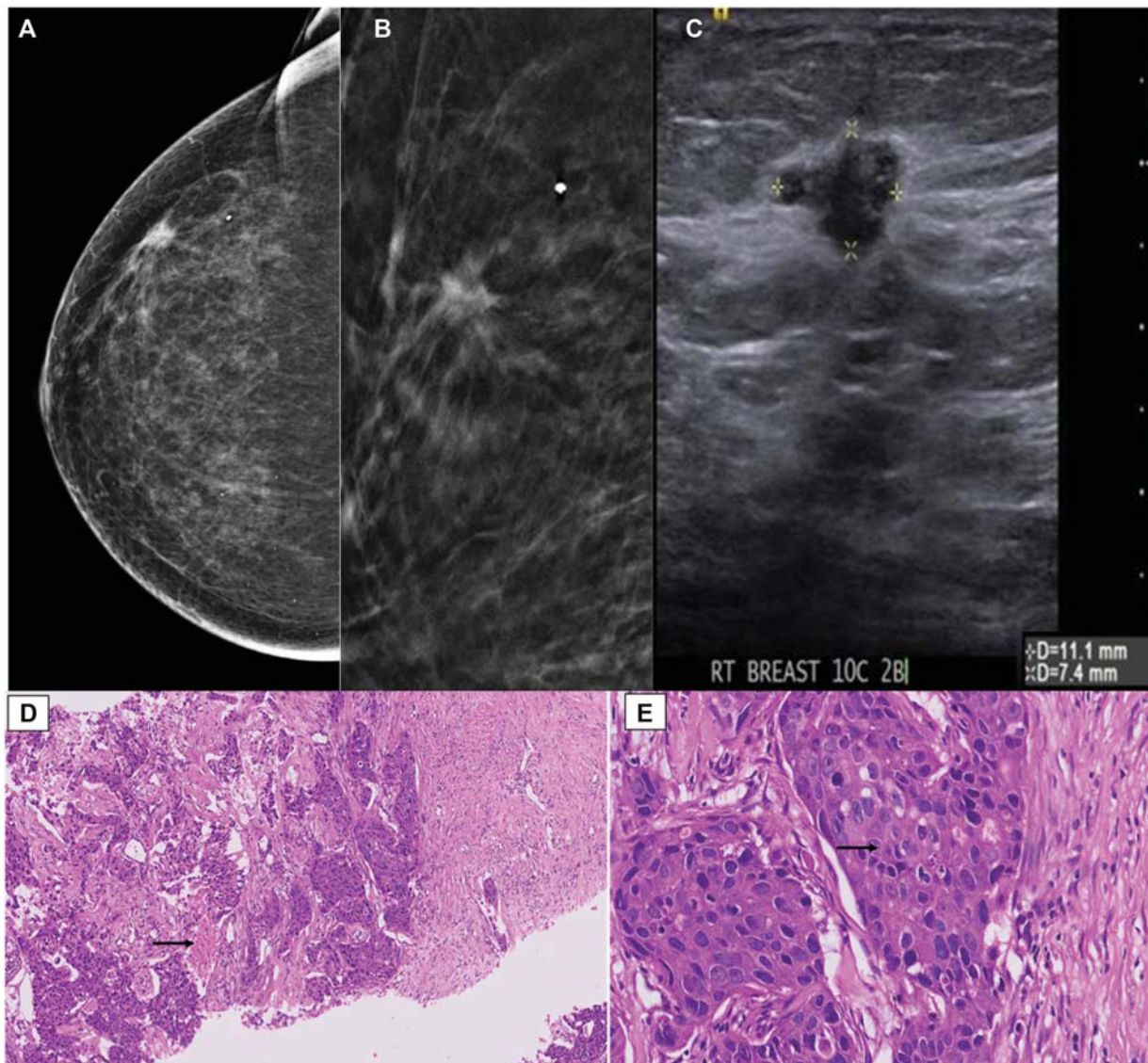


Fig. 4 A 78-year-old female came for routine screening with a family history of carcinoma breast. Mammogram (A, B) showing an irregular spiculated high-density lesion in the upper outer quadrant of the left breast. The Sonogram (C) showed an irregular microlobulated hypoechoic lesion. A Core needle biopsy was taken and corresponding pathological image (D) shows nests of invasive breast carcinoma, grade 3 with intermixed areas of necrosis (arrow), and image (E) shows cells showing marked nuclear atypia and prominent nucleoli (arrow).

the case of small and hard lesions) when it skirts along the top of the lesion. Hence, obtaining postfire images in the orthogonal plane can help in more precisely evaluating needle position.²¹

Adequate Sampling

Though image-guided percutaneous breast biopsy is used as an alternative to an excisional biopsy, sampling error is a possibility and a major limitation resulting in a false negative diagnosis or histologic underestimation.

The number and quality of specimens also play an important role in reliable histological diagnosis.⁵ Studies have shown that a minimum of 4 to 5 cores of tissue are necessary to obtain a definitive diagnosis with a CNB, but lesions with

calcification may require additional samples.²¹⁻²⁵ An intact specimen predominantly white with >1 cm of uninterrupted length and which sinks to the bottom when putting into saline suggests adequate sampling and is correlated with diagnostic yield²¹ (► Fig. 3).

Once the biopsy procedure is over, hand compression should be given for 10 minutes followed by which crepe bandage is applied and can be removed after 2 days. Ice packs and analgesics can be given if needed.

Categories of Imaging Pathologic Concordance

Parikh and Tickman¹⁶ first described five possible outcomes of imaging-pathology correlation and they are listed below:

1. Category 1: concordant malignancy.
2. Category 2: discordant malignancy.
3. Category 3: concordant benign.
4. Category 4: discordant benign.
5. Category 5: borderline or high risk.

Category 1: Concordant Malignancy

In this category, the lesions with imaging features suspicious for malignancy (i.e., BI-RADS category 4 or 5) are diagnosed to be malignancy on percutaneous biopsy. For example, a spiculated mass seen on ultrasound is diagnosed histologically as invasive ductal carcinoma after tissue biopsy (►Fig. 4). The radiologist should communicate the results to the referring physician, and the patient should be informed of the results and referred to a surgeon or oncologist for prompt treatment without any delay.⁵

Category 2: Discordant Malignancy

In this category, the lesions with benign imaging features (i.e., BI-RADS category 2 or 3) are diagnosed to be malignant on percutaneous biopsy. Malignant breast lesions that ap-

pear as well-circumscribed masses are triple-negative or high-grade invasive ductal carcinomas and not otherwise specified, metastatic lesions, lymphoma, and special type tumors, such as papillary carcinoma, mucinous carcinoma, medullary carcinoma, and metaplastic carcinoma, belong in this category.^{26,27}

The radiologist should inform the pathologist to review and confirm the diagnosis to ensure that there is no interpretative (►Fig. 5) or clerical errors accounting for the discrepancy and should be discussed clearly. The images of the lesion should be reviewed thoroughly for image quality, imaging characteristics, and any missed features that might have caused underestimation in assessment.⁵ Management is identical to concordant malignancy and surgery must be advised without any delay. The surgical excision should be combined with the frozen section.

Category 3: Concordant Benign

In this category, the lesions with imaging features of benign or likely benign (i.e., BI-RADS category 2, 3, or 4a) are pathologically benign at percutaneous biopsy (►Fig. 6).²⁸ Benign concordant results make up the majority of

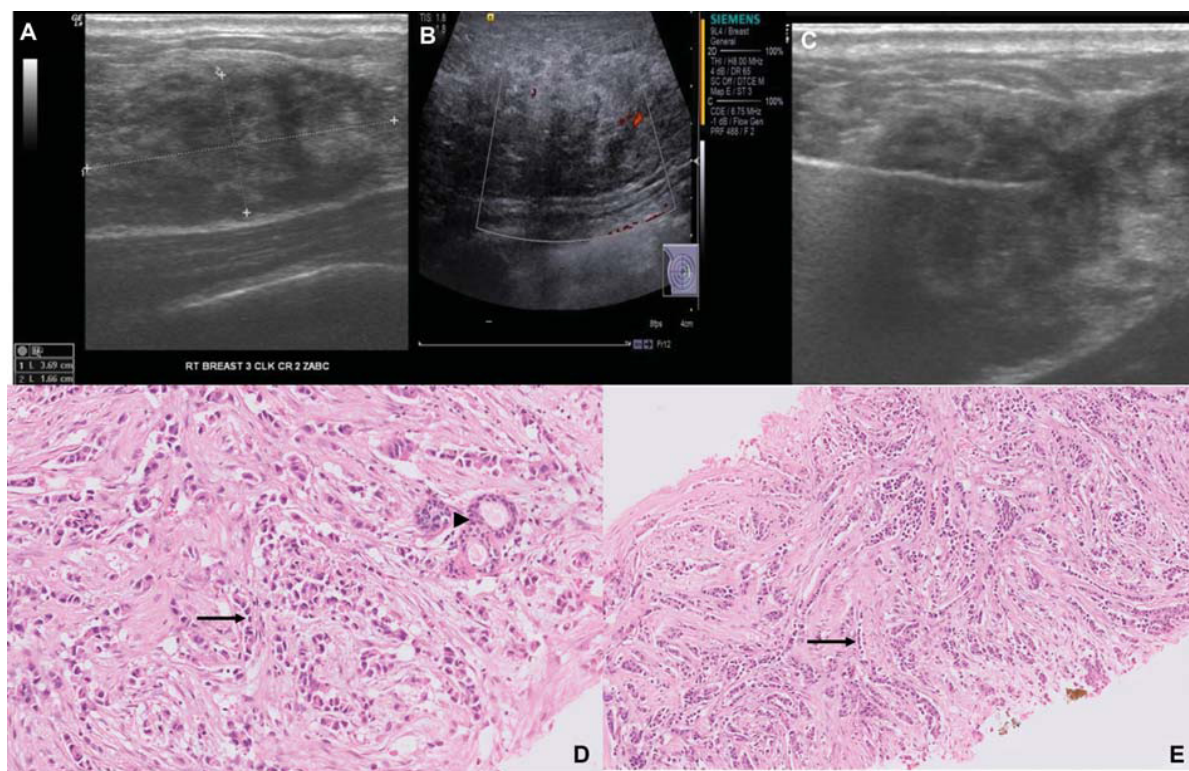


Fig. 5 A 41-year-old lactating patient came with a history of a lump and pain in the right breast for 1 month which did not resolve despite a course of antibiotics. Her last child birth was 1 and half years back. Ultrasound shows an ill-defined oval hypoechoic lesion with minimal internal vascularity and an indistinct margin. Based on the history, a diagnosis of mastitis was made BIRADS III (A–C). The Biopsy was taken and the corresponding pathological image (D, E) an infiltrating malignant neoplasm composed of cells arranged in a typical Indian file pattern (arrow) with entrapped normal ductules (arrowhead). The invasive tumor cells have mild nuclear atypia with scant cytoplasm consistent with invasive lobular carcinoma, grade 2. The Biopsy was taken and the corresponding pathological image (D, E) an infiltrating malignant neoplasm composed of cells arranged in a typical Indian file pattern (arrow) with entrapped normal ductules (arrowhead). The invasive tumor cells have mild nuclear atypia with scant cytoplasm consistent with invasive lobular carcinoma, grade 2. This is an example of an interpretative error of the Imaging findings. The Pregnancy associated breast cancer must always be kept in mind and it would have been appropriate to categorize this lesion as BIRADS IVa.

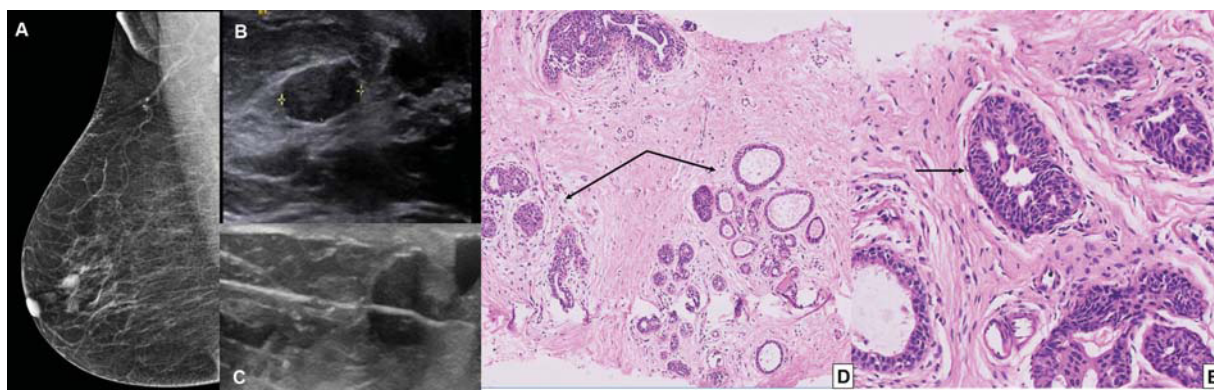


Fig. 6 A 65-year-old female with a history of carcinoma colon, on follow up, for screening mammogram. The Mammogram showed an oval circumscribed equal density lesion noted in the subareolar region of the right breast. Ultrasound shows oval circumscribed hypoechoic lesion which appears soft on elastography—BIRADS III lesion but the patient was anxious and wanted a biopsy. Corresponding pathological image (A) shows breast parenchyma with dilated ductal lobular units with areas of fibrosis and adenosis (arrow) and image (B, C) shows the glandular elements show evidence of usual ductal hyperplasia (D, E; arrow). BIRADS, Breast Imaging Reporting and Data System.

percutaneous breast biopsies.^{29,30} This result can offer reassurance to both the physician and patient and follow-up imaging is used to confirm stability and early detection of possible missed cancers. Although there is no standard follow-up guideline, a common follow-up imaging at 6 months after biopsy and then annually for at least 2 years is recommended.⁶

Category 4: Discordant Benign

In this category, the lesions with imaging features suspicious for malignancy (i.e., BI-RADS category 4 or 5), demonstrate benign pathology at percutaneous breast biopsy (→Fig. 7). Benign lesions that present as spiculated margins mimicking malignancy on ultrasound, like granular cell tumor, sclerosing adenosis, postsurgical scar, fat necrosis, mastitis, diabetic mastopathy, and sarcoidosis, belong to this category.^{28,31,32}

Special attention should be given by the radiologist to discordant benign lesions because many missed cancers can be detected without any delay in diagnosis at CNB from these lesions⁶ (→Fig. 7.) In published reports, up to 64% of discordant benign lesions after a percutaneous biopsy were confirmed as cancer by subsequent surgical excision.¹⁷ For an image-guided 14-gauge CNB, discordant benign lesions had cancer rates of up to 50%.¹⁸

If there is concern regarding a discordant benign core biopsy, it is important for the radiologist to immediately contact the pathologist who interpreted the biopsy and communicate about the discrepancy. Also, the radiologist should communicate with the referring physician or patient and discuss the need for a repeat biopsy.⁵

Surgical biopsy rather than a CNB is recommended in case of repeat biopsy because of the inconclusive outcome from the first core biopsy. Recently, vacuum-assisted CNB has been

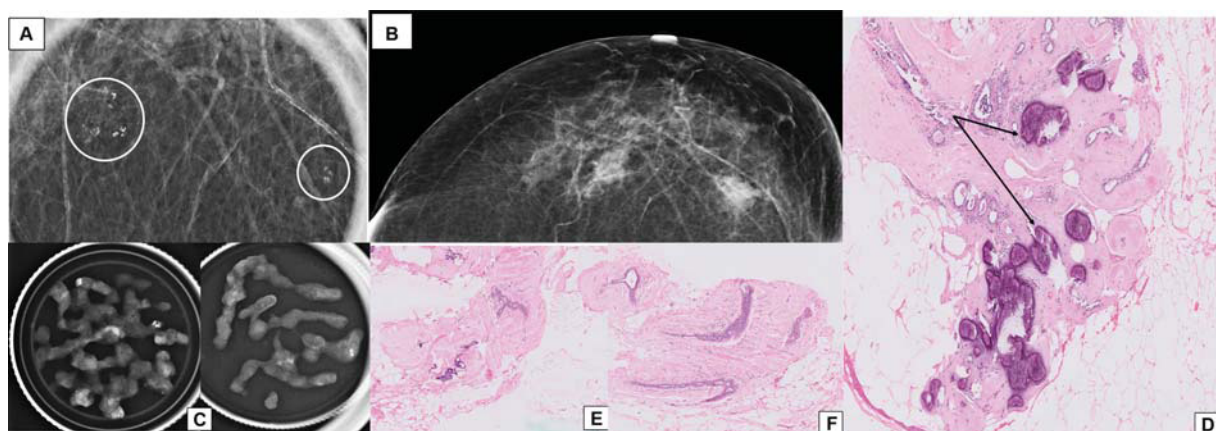


Fig. 7 The Patient came for a routine mammogram (A) which showed two clusters of coarse heterogeneous grouped suspicious calcification in the left breast. The Stereotactic biopsy was taken from both the lesions. (B) Postbiopsy hematoma corresponding to the original area of calcification. (C) Specimen mammogram from the two regions post-VAB. The corresponding pathological image (D; calcified areas) shows breast parenchyma with a nodular biphasic lesion. The stroma is fibrohyalinized and shows areas of calcification (arrow), consistent with fibroadenoma. Image (E; noncalcified areas) shows breast parenchyma with hyalinized nodular biphasic lesion with ducts lined by two-layered epithelium, consistent with hyalinized fibroadenoma, and image (F; from another focus) shows breast parenchyma with fibrosis and adenosis only. There is no evidence of calcification. VAB, Vacuum Assisted Biopsy.

reported to be an alternative to surgical excision to obtain a definitive histological diagnosis for discordant benign lesions.³³

Therefore, both surgical biopsy and image-guided vacuum-assisted biopsy can be recommended for repeat biopsy

for discordant benign lesions and the best biopsy method should be chosen for each case through proper communication between the radiologist, pathologist, referring physician, and patient.⁵

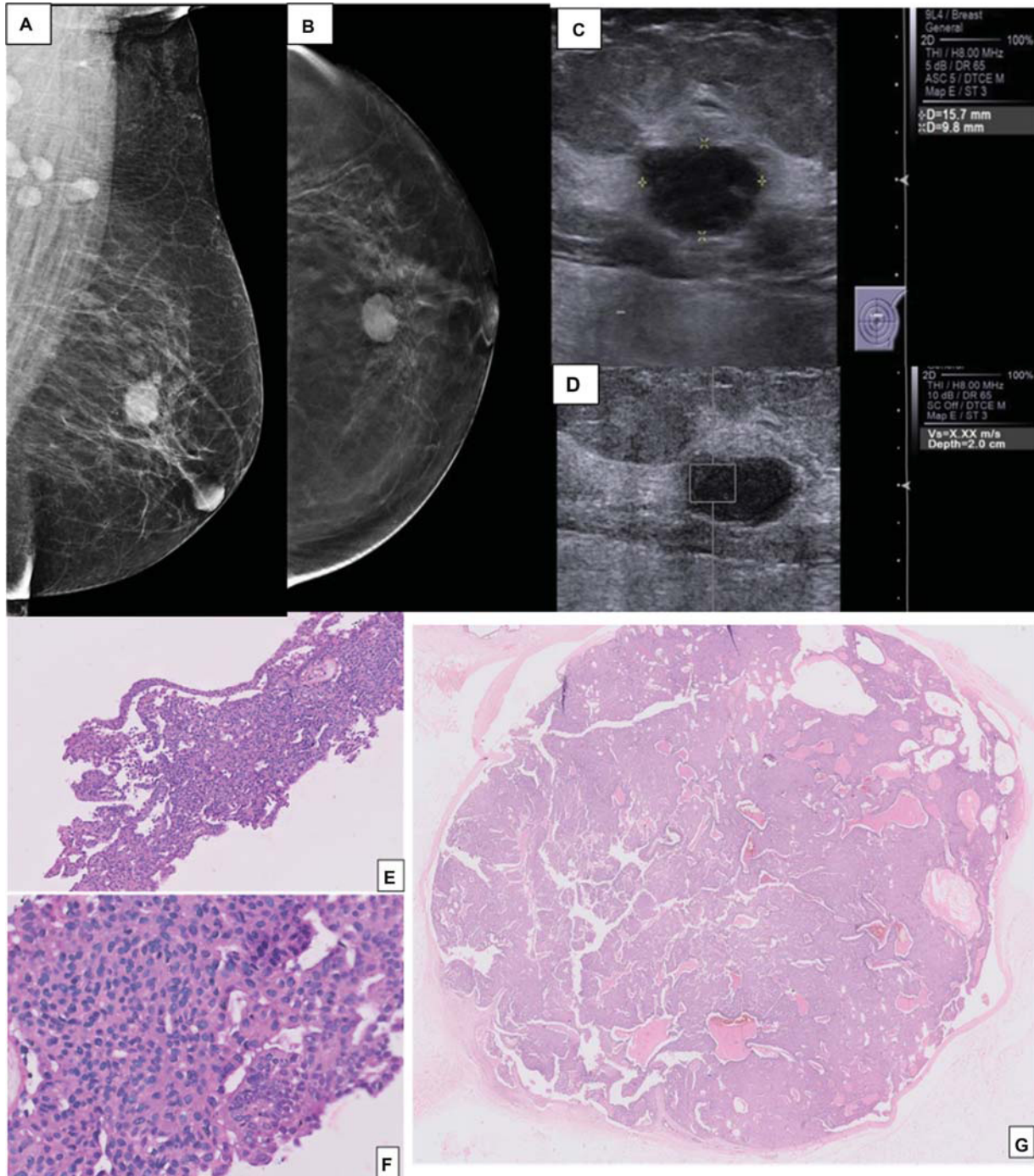


Fig. 8 A 64-year-old female patient came for routine screening. (A, B) The Mammogram and the tomogram (cc) showed a round circumscribed high-density lesion along the plane of the nipple in the left breast. (C) The ultrasound showed an oval circumscribed hypoechoic lesion which appears hard on elastography (D). The Biopsy was taken and a corresponding pathological image (E) shows a detached portion of a complex papillary lesion composed of cells arranged as fused papillae, rarely forming cribriform spaces. Image (F) High power view showing nuclei with mild nuclear atypia, suggestive of a complex papillary lesion with atypia. (Comment: Papilloma with ductal carcinoma in situ is a possibility). Image (G) Excised specimen showing a lesion bound by a fibrous capsule with the proliferation of cells around papillary cores, which are occasionally fused. The cells showed moderate nuclear atypia in multiple foci. There is no evidence of invasion. Histopathological features are consistent with encapsulated papillary carcinoma, low grade.

Category 5: Borderline or High Risk

In this category, the lesions that are not malignant but are considered to have an increased lifetime risk of developing breast cancer, including atypical ductal hyperplasia (ADH), lobular neoplasia, radial scar, papillary lesions, and possible phyllodes tumors are included ¹⁶(→Fig. 8). Controversy still exists regarding the appropriate surgical and oncological management for these lesions.⁵ A case-by-case approach and active collaboration between multidisciplinary groups are making a significant difference in the management of biopsy-proven high-risk lesions.^{34,35} However, a surgical biopsy is usually recommended in these lesions because of the relatively high upgrade rate to malignancy.⁶

Postbiopsy Counseling of the Patient

Image-guided breast interventions are essentially outpatient surgical procedures and must be dealt as such. It is important that we follow-up our patient's postbiopsy and apprise them of possible complications and ask them to see us in the emergency department in case of any complications. It is important to have a postbiopsy clinic to review patients with the pathology reports. In our hospital, the turn-around time for histopathology reports is 5 days and all patients, postbiopsy, are reviewed by the radiologists to look at the site of biopsy and also to review the pathology reports for Rad-path correlation.

An algorithmic is needed and is given below to illustrate the work-flow of the postbiopsy clinic (→Figs. 9 and 10).

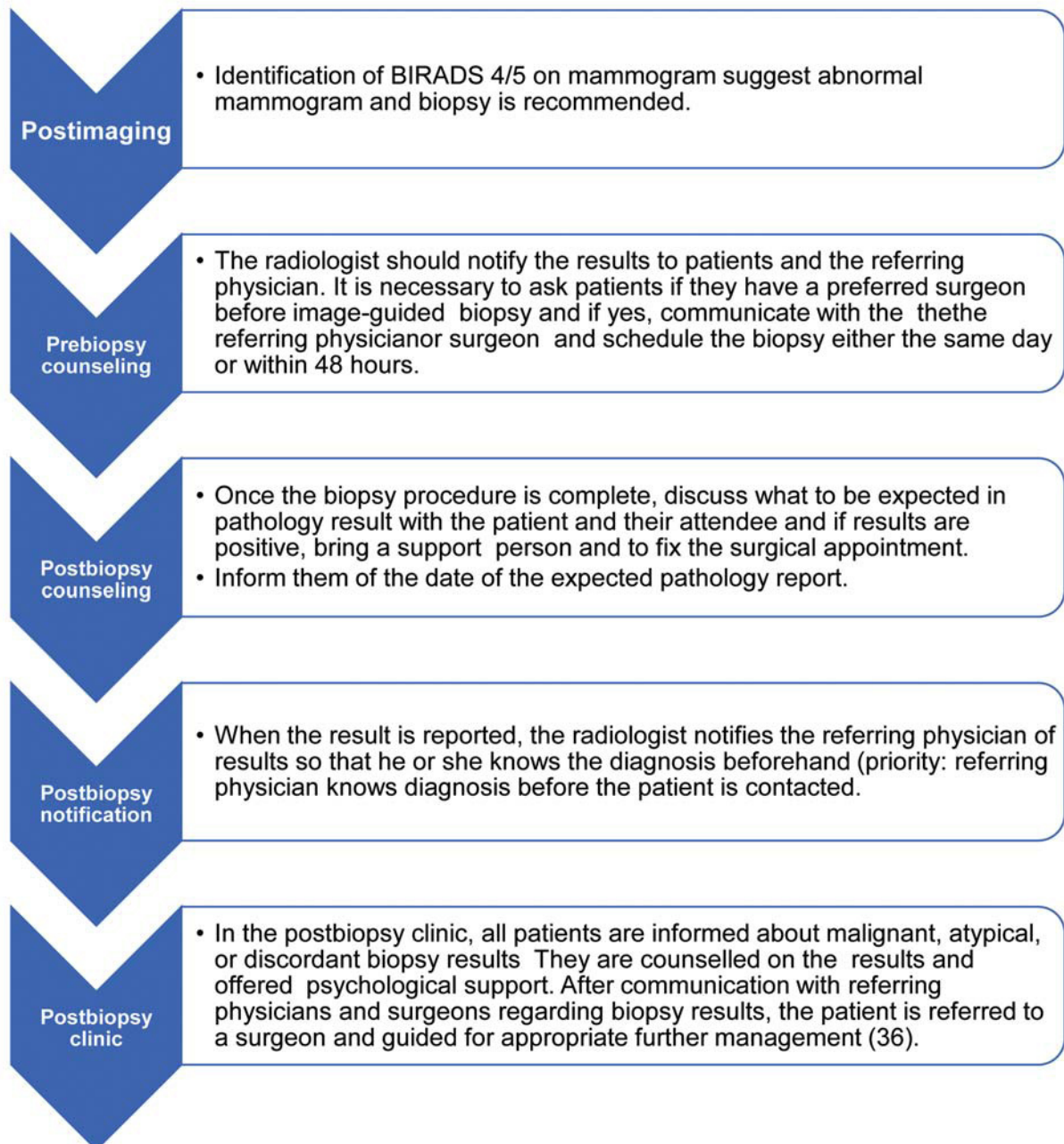


Fig. 9 Navigation workflow.

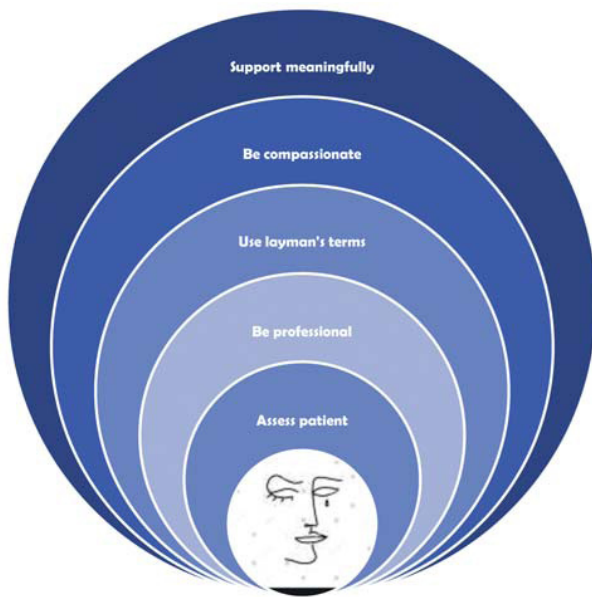


Fig. 10 A five-step approach for disclosing the results.

Counseling

Radiologists usually do not consult face to face with patients, they work in front of monitors and computers. Hence, it is important for us to develop appropriate aspects of psychological counseling and soft skills in to provide emotional support professionally to our patients. Radiologist's communication of cancer diagnoses can have a lifetime impact on patients; hence, we must break the bad news in a proper method. In case of a benign pathological diagnosis, patients should be advised regarding the importance of follow-up routine or short-term imaging follow-up as the case might be.

The traits of effective communication are sensitivity, courtesy, appropriateness, honesty, and openness. Studies recommend a five-step approach for disclosing the results.

Step 1 Assess the Patient

We must make sure that the patient understands what we want to communicate. We must take in to consideration the patient's education, intelligence, and emotional quotient. And always advise the patient to come with a close relative or friend. Look at the patient in the eye and the patient should get the feeling that she/he is being given full attention.

Step 2 Be Professional in Counseling

We must plan for the meeting in a professional manner. Communication of results to the patient should be done in a private consultation room, with the patient's spouse/family members. A professional appearance with a white coat instills confidence in the patient. Be prepared for patient's and attender's sorrow by having tissues at hand. It might be

necessary to have a follow-up appointment available after the person has assimilated the results of the test.

Step 2 Convey the Results in Layman's Terms

Bad news of diagnosis of cancer should be conveyed by the radiologists in layman's language and should instill hope without false assurance while explaining the relative risk in benign discordant lesions. Some of our patients might not be familiar with the language and it is better to use local language with a translator.

Step 3 Be Compassionate

Empathy involves evaluating patient's response and this can be done only when we put ourselves in their shoes. Patients can exhibit shock, disbelief, denial, fear, anger, or guilt. We need to be compassionate and give them time to assimilate and vent their feelings.

Step 4 Be Proactive

Organize an appointment to the surgeon if they do not have their own. Prepare them for a repeat biopsy in case there is a discordance in the results with vacuum or surgical excision, the possibility of which should be discussed during the preprocedural consent. Encourage to have an active listener in case the patient is not in a position to make the decision for the next appointment.

Step 5 Support Meaningfully

Support should be meaningful in the form of professional information, reliable resources, and professional support groups. The availability and commitment of the radiologist to the patient for her care should be conveyed with sharing of business cards and phone numbers.³⁶

Good communication is essential to help our patients empower themselves and make informed choices thereby enriching their lives and our own.³⁷

Conclusion

An Image-guided breast biopsy is an accurate method for diagnosing breast cancer, with a false negative rate ranging from 0.1 to 2.5%. Careful imaging-pathology correlation is essential, as most false-negative cases are identified because of imaging-pathology discordance. Although the communication between the radiologist and pathologist is the basis of imaging-pathology correlation, establishing concordance is subject to the experience of the radiologist and pathologist. Appropriate postbiopsy management, including active communication with the pathologist, referring physician, and the patient, is the cornerstone for a successful core biopsy procedure.

Conflict of Interest

None declared.

References

- 1 Silverstein MJ, Recht A, Lagios MD, et al. Special report: consensus conference III. Image-detected breast cancer: state-of-the-art diagnosis and treatment. *J Am Coll Surg* 2009;209(04):504–520
- 2 Bae S, Yoon JH, Moon HJ, Kim MJ, Kim EK. Breast microcalcifications: diagnostic outcomes according to image-guided biopsy method. *Korean J Radiol* 2015;16(05):996–1005
- 3 Uematsu T. How to choose needles and probes for ultrasonographically guided percutaneous breast biopsy: a systematic approach. *Breast Cancer* 2012;19(03):238–241
- 4 Keranen AK, Haapea M, Rissanen T. Ultrasonography as a guiding method in breast micro-calcification vacuum-assisted biopsies. *Ultraschall Med* 2016;37:497–502
- 5 Park VY, Kim EK, Moon HJ, Yoon JH, Kim MJ. Evaluating imaging-pathology concordance and discordance after ultrasound-guided breast biopsy. *Ultrasonography* 2018;37(02):107–120
- 6 Youk JH, Kim EK, Kim MJ, et al. Concordant or discordant? Imaging-pathology correlation in a sonography-guided core needle biopsy of a breast lesion. *Korean J Radiol* 2011;12(02):232–240
- 7 Johnson NB, Collins LC. Update on percutaneous needle biopsy of nonmalignant breast lesions. *Adv Anat Pathol* 2009;16(04):183–195
- 8 The American Society of Breast Surgeons. Performance and practice guidelines for stereotactic breast procedures. Accessed November 5, 2010 at: <https://www.breastsurgeons.org/docs/statements/Performance-and-Practice-Guidelines-for-Stereotactic-Breast-Procedures.pdf>
- 9 American College of Radiology. ACR practice parameter for the performance of stereotactic/tomosynthesis-guided breast interventional procedures. Accessed June 25, 2011 at: <https://www.acr.org/-/media/ACR/Files/Practice-Parameters/stereo-breast.pdf>
- 10 Landercasper J, Linebarger JH. Contemporary breast imaging and concordance assessment: a surgical perspective. *Surg Clin North Am* 2011;91(01):33–58
- 11 Neal L, Tortorelli CL, Nassar A. Clinician's guide to imaging and pathologic findings in benign breast disease. *Mayo Clin Proc* 2010;85(03):274–279
- 12 Masood S, Rosa M. Borderline breast lesions: diagnostic challenges and clinical implications. *Adv Anat Pathol* 2011;18(03):190–198
- 13 Corben AD, Edelweiss M, Brogi E. Challenges in the interpretation of breast core biopsies. *Breast J* 2010;16(Suppl 1):S5–S9
- 14 Youk JH, Kim EK, Kim MJ, Lee JY, Oh KK. Missed breast cancers at US-guided core needle biopsy: how to reduce them. *Radiographics* 2007;27(01):79–94
- 15 Liberman L, Drotman M, Morris EA, et al. Imaging-histologic discordance at percutaneous breast biopsy. *Cancer* 2000;89(12):2538–2546
- 16 Parikh J, Tickman R. Image-guided tissue sampling: where radiology meets pathology. *Breast J* 2005;11(06):403–409
- 17 Liberman L. Percutaneous image-guided core breast biopsy. *Radiol Clin North Am* 2002;40(03):483–500
- 18 Comstock CE. US-guided interventional procedures. In: Feig SA, ed. 2005 Syllabus: A Categorical Course in Diagnostic Radiology Breast Imaging. Oak Brook, IL: Radiological Society of North America; 2005:155–168
- 19 Bassett LW, Mahoney MC, Apple SK. Interventional breast imaging: current procedures and assessing for concordance with pathology. *Radiol Clin North Am* 2007;45(05):881–894
- 20 Whitman GJ, Erguvan-Dogan B, Yang WT, Wilson J, Patel P, Krishnamurthy S. Ultrasound-guided breast biopsies. *Ultrasound Clin* 2006;1:603–615
- 21 Fishman JE, Milikowski C, Ramsinghani R, Velasquez MV, Aviram G. US-guided core-needle biopsy of the breast: how many specimens are necessary? *Radiology* 2003;226(03):779–782
- 22 Dillon MF, Hill AD, Quinn CM, O'Doherty A, McDermott EW, O'Higgins N. The accuracy of ultrasound, stereotactic, and clinical core biopsies in the diagnosis of breast cancer, with an analysis of false-negative cases. *Ann Surg* 2005;242(05):701–707
- 23 Schueller G, Jaromi S, Ponhold L, et al. US-guided 14-gauge core-needle breast biopsy: results of a validation study in 1352 cases. *Radiology* 2008;248(02):406–413
- 24 Philpotts LE, Hooley RJ, Lee CH. Comparison of automated versus vacuum-assisted biopsy methods for sonographically guided core biopsy of the breast. *AJR Am J Roentgenol* 2003;180(02):347–351
- 25 Wu YC, Chen DR, Kuo SJ. Personal experience of ultrasound-guided 14-gauge core biopsy of breast tumor. *Eur J Surg Oncol* 2006;32(07):715–718
- 26 Yoo JL, Woo OH, Kim YK, et al. Can MR Imaging contribute in characterizing well-circumscribed breast carcinomas? *Radiographics* 2010;30(06):1689–1702
- 27 Song SE, Cho N, Chu A, et al. Undiagnosed breast cancer: features at supplemental screening US. *Radiology* 2015;277(02):372–380
- 28 Youk JH, Kim EK, Kim MJ, et al. Concordant or discordant? Imaging-pathology correlation in a sonography-guided core needle biopsy of a breast lesion. *Korean J Radiol* 2011;12(02):232–240
- 29 Moon HJ, Jung I, Youk JH, Kim MJ, Kim EK. Short-term follow-up in 6 months is unnecessary for asymptomatic breast lesions with benign concordant results obtained at ultrasonography-guided 14-gauge core needle biopsy. *Am J Surg* 2016;211(01):152–158
- 30 Sickles EA, Ominsky SH, Sollitto RA, Galvin HB, Monticciolo DL. Medical audit of a rapid-throughput mammography screening practice: methodology and results of 27,114 examinations. *Radiology* 1990;175(02):323–327
- 31 Cho SH, Park SH. Mimickers of breast malignancy on breast sonography. *J Ultrasound Med* 2013;32(11):2029–2036
- 32 Kim MJ, Kim D, Jung W, Koo JS. Histological analysis of benign breast imaging reporting and data system categories 4c and 5 breast lesions in imaging study. *Yonsei Med J* 2012;53(06):1203–1210
- 33 Kim MJ, Kim EK, Lee JY, et al. Breast lesions with imaging-histologic discordance during US-guided 14G automated core biopsy: can the directional vacuum-assisted removal replace the surgical excision? Initial findings. *Eur Radiol* 2007;17(09):2376–2383
- 34 Krishnamurthy S, Bevers T, Kuerer H, Yang WT. Multidisciplinary considerations in the management of high-risk breast lesions. *AJR Am J Roentgenol* 2012;198(02):W132–40
- 35 Middleton LP, Sneige N, Coyne R, et al. Most lobular carcinoma in situ and atypical lobular hyperplasia diagnosed on core needle biopsy can be managed clinically with radiologic follow-up in a multidisciplinary setting. *Cancer Med* 2014;3(03):492–499
- 36 Hutcherson KC, Ferrara M, Gillis J, Roberson S, Robinson C. Closing the loop with a post-biopsy breast clinic. Accessed January 11, 2022 at: https://www.accc-cancer.org/docs/documents/oncology-issues/articles/nd15/nd15-closing-the-loop-with-a-post-biopsy-breast-clinic.pdf?sfvrsn=d4b9974b_7
- 37 Soo MC. Optimizing the patient experience in breast imaging: improving radiologist – patient communication. Accessed January 11, 2022 at: <https://www.sbi-online.org/Portals/0/Breast%20Imaging%20Symposium%202016/Final%20Presentations/325C%20Soo%20-%20How%20to%20Talk%20to%20Patients.pdf>