



Neonatal Meningitis with Septicemia by *Elizabethkingia meningoseptica*: A Case Report

Neetha S. Murthy¹ Sowmya G. Shivappa¹ A. Tejashree¹ Krishna M.V.S. Karthik¹ R. Deepashree¹

¹Department of Microbiology, JSS Medical College, Mysuru, Karnataka, India

Address for correspondence Sowmya G. Shivappa, MBBS, MD, Department of Microbiology, JSS Medical College, JSS AHER, Sri Shivarathreeswaranagar, Mysuru, 570015, Karnataka, India (e-mail: sowmyashivappa@gmail.com).

J Lab Physicians 2022;14:362–364.

Abstract

Elizabethkingia is ubiquitous aerobic bacillus abundantly found in the community as well as hospital environments. *Elizabethkingia meningoseptica* is an emerging nosocomial pathogen with an elemental ability to acclimate and survive in diversified environmental circumstances. Prompt diagnosis and an early therapeutic intervention are preponderant in the management of these infections. We report a case of meningitis with septicemia caused by *E. meningoseptica* in a 1-day-old outborn neonate. The child was stabilized with anticonvulsants and, based on laboratory findings, the neonate was started on ciprofloxacin in addition to symptomatic management. The child responded well to the treatment and was discharged on day 7 after treatment initiation. Perceptive treatment protocols backed with accurate laboratory evidence remain instrumental to avert unpropitious outcomes while combatting rare multidrug-resistant opportunistic infections.

Keywords

- ▶ septicemia
- ▶ *Elizabethkingia meningoseptica*
- ▶ meningitis
- ▶ multidrug resistant
- ▶ neonate

Introduction

Elizabethkingia meningoseptica is an emerging cause of life-threatening nosocomial infections among neonates.¹ This opportunistic pathogen was primarily placed under genus *Flavobacterium* (1959) and later moved to genus *Chryseobacterium* (1994). Eventually in the year 2005 based on 16S rRNA phylogenetic studies, this aerobic bacillus was classified in the genus *Elizabethkingia* (an eponym from its discoverer Elizabeth O. King).² *E. meningoseptica* is a gram-negative bacillus that is nonmotile, nonfermentative bacteria capable of splitting tryptophan to produce indole and is oxidase positive. Whole genome sequence analysis has established the intrinsic ability of this microbe to form biofilms and serve as a potential stockpile of novel- β -lactamase genes.^{3,4}

Literature documents sparse case reports of *E. meningoseptica* from India and around the world. Few cases of wound infections, keratitis, nosocomial septicemia, nosocomial pneumonia, endocarditis, and meningitis in immunocompromised adults and preterm neonates have been reported globally.^{5,6} Several culpable sources of this opportunistic pathogen such as contaminated water supply, equipment tubing, infant formulas, and saline solutions have been documented apart from the environmental niches.⁷ Yet another remonstrance with respect to this bacillus is its habitual multidrug resistance with no established Clinical and Laboratory Standards Institute drug breakpoints.⁸ Given the above circumstances, empirical therapy and treatment standardization with respect to *E. meningoseptica* is a farfetched dream. We report a case of neonatal meningitis with septicemia caused by *E. meningoseptica* in an outborn term neonate.

published online
February 9, 2022

DOI <https://doi.org/10.1055/s-0042-1742635>.
ISSN 0974-2727.

© 2022. The Indian Association of Laboratory Physicians. All rights reserved.

This is an open access article published by Thieme under the terms of the Creative Commons Attribution-NonDerivative-NonCommercial-License, permitting copying and reproduction so long as the original work is given appropriate credit. Contents may not be used for commercial purposes, or adapted, remixed, transformed or built upon. (<https://creativecommons.org/licenses/by-nc-nd/4.0/>)

Thieme Medical and Scientific Publishers Pvt. Ltd., A-12, 2nd Floor, Sector 2, Noida-201301 UP, India

Case Report

We present a case of 1-day-old term outborn infant with *E. meningoseptica* attributed meningitis and septicemia presenting with convulsions. A single live, full-term, male baby delivered by normal vaginal delivery at a peripheral district hospital presented with birth asphyxia. The APGAR (appearance, pulse, grimace, activity, and respiration) score at birth unknown, the baby presented to our tertiary care center with two to three episodes of convulsions, sepsis screen positive, and respiratory distress. The neonate was stabilized with a loading dose of phenobarbitone 20 mg/kg followed by a maintenance dose of 10 mg/kg. Injection calcium was given 2 mL/kg and the child was shifted to the neonatal intensive care for further management.

At admission, the child was moderately active with a heart rate of 146/minute and respiratory rate of 93/minute. Weight of the neonate was 2.88 kg. The ultrasound brain yielded a normal study with no intracranial bleed, brain parenchymal lesions, or ventricular enlargement. The cerebral hemispheres, basal ganglia, corpus callosum, and posterior fossa structures appeared normal. Magnetic resonance imaging brain showed mild hypoxic ischemic encephalopathy.

The blood investigations showed a raised total cell count (128,900) and reduced platelet count (67,000). C-reactive protein was raised with a value of 27.91. Creatinine was found to be 1.32 mg/dL. Liver function parameters were within normal limits. Arterial blood gas analysis at admission showed metabolic acidosis with compensatory respiratory alkalosis. Cerebrospinal fluid (CSF) analysis at admission showed predominant neutrophils with normal protein and sugar levels.

Blood sample (4 mL) from the neonate⁸ was inoculated into a culture bottle and incubated in BacT/ALERT Microbial Colorimetric Detection System. Sample flagged positive in 23 hours. Flagged sample was subjected to direct gram staining and subsequently plated on MacConkey along with 5% sheep blood agar. Gram smear showed gram-negative bacilli and culture yielded aerobic, pale pink (► Fig. 1) oxidase positive colonies on MacConkey agar and nonhemolytic colonies on blood agar. Culture isolate smear showed gram-negative bacillus in concordance with the direct smear findings (► Fig. 2). VITEK-2 (bioMérieux) identification yielded *E. meningoseptica* with 99% probable confidence of identification. CSF sample from the child was subjected to automated culture (BacT/ALERT System). CSF culture also yielded *E. meningoseptica* by the VITEK 2 system with a 99% identification confidence. Both the blood and CSF isolate showed resistance to β -lactams, carbapenems, and aminoglycosides. Second- and third-generation quinolones were effective with an in vitro minimal inhibitory concentration of 0.5 μ g/mL. The child was started on parenteral ciprofloxacin along with symptomatic management. In vivo response to therapy was clinically admirable and the child was discharged on day 7 post treatment initiation with absolutely no residual morbidity.

Discussion

Genus *Elizabethkingia* houses a notorious bunch of rare opportunistic pathogens responsible for multidrug resistant

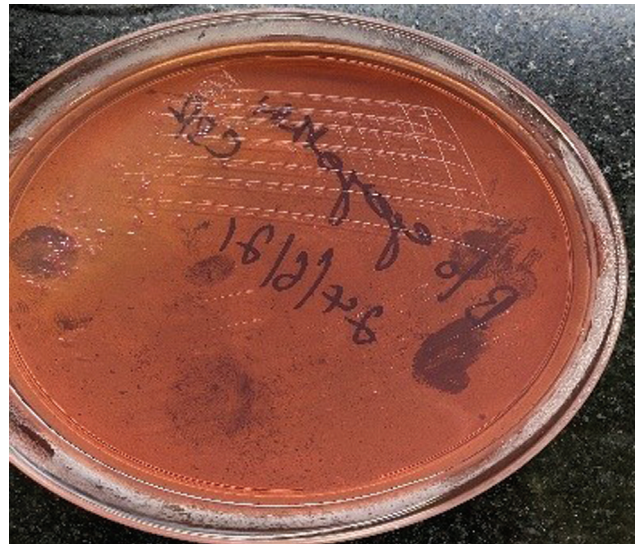

Fig. 1 Pale pink colonies on MacConkey agar.

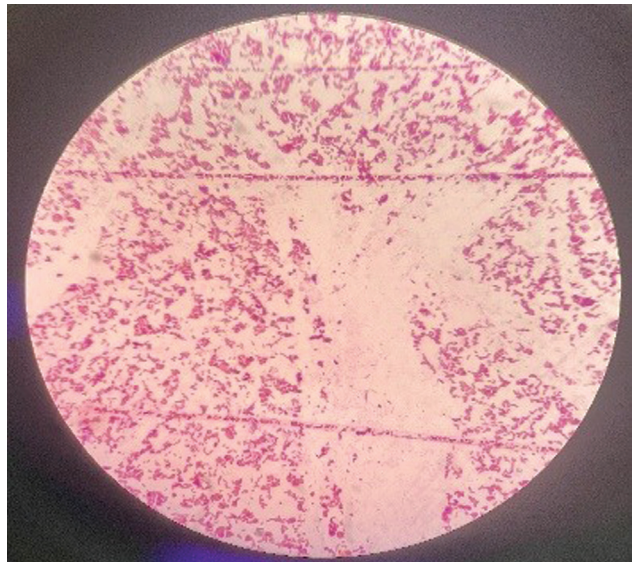


Fig. 2 Smear from culture showing gram-negative bacilli.

lethal infections. The mortality rate associated with this rare pathogen is around 23%.^{5,9} Essentially the genus is composed of saprophytic bacteria capable of survival in chlorinated water, hospital equipment, and pediatric nurseries.¹⁰ Interestingly although deemed to be an opportunistic pathogen commonly infecting the immunocompromised subjects, *Elizabethkingia* species are not part of the normal human microbial flora. The bacteria belonging to this genus are known to possess virulence attributes such as proteases, catalases, acetyltransferases, peroxidases, heat shock proteins, capsular polysaccharide, and lipooligosaccharides.¹¹ The adherence ability of *E. meningoseptica* NCTC 10016^T onto abiotic surfaces such as intravascular devices via formation of biofilms has been well established.¹² Multiple possible pathways of exposure and mechanisms of

pathogenesis have been contemplated. However, exact mechanism of pathogenesis remains obscure.¹¹

Considering the fact that bacterial species belonging to the genus *Elizabethkingia* are usually multidrug resistant, laboratory affirmed identification is of prime importance. On the laboratory front, strain-dependent variabilities² in culture growth make manual identification unreliable. Commercial automated microbial identifications systems provide accurate and quick genus level identification of *Elizabethkingia* species. However, *Elizabethkingia* reference databases on commercial microbial identification systems find partial concordance with 16S rRNA gene sequencing-based specific species identification.^{13,14} Advances in automation and microbiological diagnostics bring with it the advantage of early diagnosis and better detection rates of *Elizabethkingia* species, thereby averting inappropriate antimicrobial therapy and outbreak prevention.

Members of the genus *Elizabethkingia* are by and large resistant to antimicrobials such as tetracycline, chloramphenicol, extended-spectrum β -lactams, and aminoglycosides. Biologically plausible chromosome and plasmid mediated β -lactam resistance due to Ambler class D extended-spectrum serine- β -lactamase coding *bla*_{CME} genes and carbapenem resistance due to *bla*_B(subclass B1) and *bla*_{GOB}(subclass B3) genes have been documented.¹⁵ Fluoroquinolones exhibit uniform volume distribution and better penetration of the blood brain barrier by virtue of their lipophilic nature.^{15,16} The child in our case report also demonstrated clinical improvement with 7 days of parenteral ciprofloxacin therapy and was discharged on day 8 of admission with no documented untoward incidents.

Conclusion

E. meningoseptica is a difficult to diagnose saprophytic non-fermenter with a handful of cases being reported from pediatric nurseries and critical care units in the recent times. This aggrandize with respect to notification of *E. meningoseptica* infections is attributable to the availability of rapid, accurate, commercial identification systems for laboratory diagnosis. In conclusion, given the independent attributable mortality/morbidity and multidrug resistance profile of *Elizabethkingia*, development of robust standard infection control practices to combat this emerging pathogen is inevitable. Armed with automated identification systems, the microbiology laboratory can combat the formidable rapid identification challenge paving way toward early appropriate treatment initiation, resulting in favorable patient outcome as documented in our case report.

Funding

No separate funding was received apart from using laboratory facilities as part of the routine laboratory support from JSS medical college.

Conflict of Interest

None declared.

References

- Long SS. Principles and Practice of Pediatric Infectious Diseases. Fourth edition; 2012:1547–1712
- Kim KK, Kim MK, Lim JH, Park HY, Lee S-T. Transfer of *Chryseobacterium meningosepticum* and *Chryseobacterium miricola* to *Elizabethkingia* gen. nov. as *Elizabethkingia meningoseptica* comb. nov. and *Elizabethkingia miricola* comb. nov. Int J Syst Evol Microbiol 2005;55(Pt 3):1287–1293
- Matyi SA, Hoyt PR, Hosoyama A, Yamazoe A, Fujita N, Gustafson JE. Draft genome sequences of *Elizabethkingia meningoseptica*. Genome Announc 2013;1(04):e00444–e13
- Chen S, Soehnlén M, Downes FP, Walker ED. Insights from the draft genome into the pathogenicity of a clinical isolate of *Elizabethkingia meningoseptica* Em3. Stand Genomic Sci 2017; 12:56
- Bhat KS, Priya R, Krishnan L, Kanungo R. *Elizabethkingia meningoseptica* bacteremia in a neonate: a case report and mini-review of the literature. J Curr Res Sci Med 2016;2:42–45
- Amer MZ, Bandey M, Bukhari A, Nemenqani D. Neonatal meningitis caused by *Elizabethkingia meningoseptica* in Saudi Arabia. J Infect Dev Ctries 2011;5(10):745–747
- Rastogi N, Mathur P, Bindra A, et al. Infections due to *Elizabethkingia meningoseptica* in critically injured trauma patients: a seven-year study. J Hosp Infect 2016;92(01):30–32
- Kellogg JA, Manzella JP, Bankert DA. Frequency of low-level bacteremia in children from birth to fifteen years of age. J Clin Microbiol 2000;38(06):2181–2185
- Lin YT, Chiu CH, Chan YJ, et al. Clinical and microbiological analysis of *Elizabethkingia meningoseptica* bacteremia in adult patients in Taiwan. Scand J Infect Dis 2009;41(09): 628–634
- Steinberg JP, Burd EM. Other gram negative and gram variable bacilli. In: Mandell GL, Bennett JE, and Dolin R, eds. Mandell, Douglas and Bennett's Principles and Practice of Infectious Diseases. Seventh edition. United States: Churchill Livingstone; 2010:3015–3033
- Chen S, Soehnlén M, Blom J, Terrapon N, Henrissat B, et al. Comparative genomic analyses reveal diverse virulence factors and antimicrobial resistance mechanisms in clinical *Elizabethkingia meningoseptica* strains. PLOS ONE 2019;14(10):e0222648
- Jacobs A, Chenia HY. Biofilm formation and adherence characteristics of an *Elizabethkingia meningoseptica* isolate from *Oreochromis mossambicus*. Ann Clin Microbiol Antimicrob 2011; 10:16
- Lau SKP, Chow W-N, Foo C-H, et al. *Elizabethkingia anophelis* bacteremia is associated with clinically significant infections and high mortality. Sci Rep 2016;6:26045
- Lin J-N, Lai C-H, Yang C-H, Huang Y-H, Lin H-F, Lin H-H. Comparison of four automated microbiology systems with 16S rRNA gene sequencing for identification of *Chryseobacterium* and *Elizabethkingia* species. Sci Rep 2017;7(01):13824
- Huang YC, Lin YT, Wang FD. Comparison of the therapeutic efficacy of fluoroquinolone and non-fluoroquinolone treatment in patients with *Elizabethkingia meningoseptica* bacteraemia. Int J Antimicrob Agents 2018;51(01):47–51
- Vincent JL, Bassetti M, François B, et al. Advances in antibiotic therapy in the critically ill. Crit Care 2016;20(01):133