



# A Rare Case of Isolated Vesical Mucormycosis in a Patient with COVID-19 Pneumonitis

Mridula Manohar Muthe<sup>1</sup> Sankalp Dilip Shirsath<sup>2</sup> Raunaklaxmi Dilip Shirsath<sup>2</sup>  
Vikrant Prabhakar Firke<sup>1</sup>

<sup>1</sup>Department of Radiology, LTMMC and LTMGH, Mumbai, Maharashtra, India

<sup>2</sup>Department of Radiology, Pravara Rural Medical College, Mumbai, Maharashtra, India

Address for correspondence: Mridula Manohar Muthe, DNB, Saideep 1, B Wing, Flat No. 3, Sindhi Society, Chembur Est, Mumbai 400071, Maharashtra, India (e-mail: muthe99@gmail.com).

Indian J Radiol Imaging 2022;32:408–410.

## Abstract

### Keywords

- mucormycosis
- COVID-19
- fungal infections
- urinary tract infections
- diabetes
- steroid
- *Rhizopus*

We present the case of a 60-year-old diabetic female who was diagnosed with coronavirus disease 2019 (COVID-19) pneumonitis. After her recovery during follow-up, she presented with recurrent hematuria, burning of micturition and, occasional lower abdominal discomfort, with unsatisfactory response to oral antibiotics. On imaging evaluation, there was mild right hydronephrosis and hydroureter with urothelial thickening involving the right lower ureter and a filling defect in the urinary bladder close to the vesicoureteric junction seen on excretory phase images. Cystoscopy revealed a whitish friable mass-like lesion that was retrieved, histopathology of which revealed fungal elements, and *Rhizopus* was isolated in culture. Thus, the diagnosis of urinary bladder fungal ball due to mucormycosis infection of the urinary tract was reached. The patient was asymptomatic after 10 weeks of antifungal treatment. The treating physicians, urologist, and radiologists need to have a high index of suspicion of urinary mucormycosis in patients with COVID-19 pneumonia.

## Introduction

As COVID-19 continues to infect vast numbers of the population, an increasing number of unusual and rare complications are being reported, some of them being fatal; one such complication is secondary infections. Among the secondary infections of particular importance are opportunistic fungal infections like mucormycosis that primarily affect immunosuppressed or diabetic patients. Numerous cases of mucormycosis infections are being reported particularly involving the lungs or paranasal sinuses; however, there have been no reports of mucormycosis affecting the urinary tract in a patient with a history of COVID-19 infection. We report a case of isolated fungal ball cystitis without renal involve-

ment or dissemination in a patient treated for COVID-19 pneumonitis.

## Case History

A 60-year-old female patient presented with increased frequency of micturition and dysuria. She had been tested positive for the severe acute respiratory syndrome coronavirus 2 reverse transcription polymerase chain reaction test, 8 weeks back with a computed tomography (CT) severity score of 21 and was admitted to the intensive care unit for the same. During the hospital stay, she was treated with high flow oxygen, prednisolone, and broad-spectrum antibiotics.

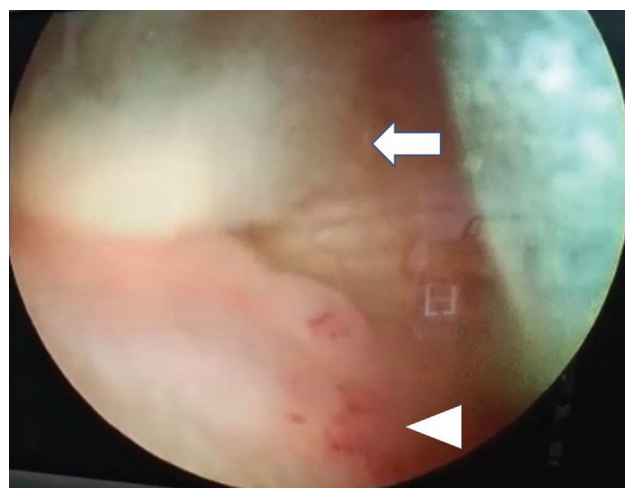
published online  
August 17, 2022

DOI <https://doi.org/10.1055/s-0042-1744137>.  
ISSN 0971-3026.

© 2022. Indian Radiological Association. All rights reserved.  
This is an open access article published by Thieme under the terms of the Creative Commons Attribution-NonDerivative-NonCommercial-License, permitting copying and reproduction so long as the original work is given appropriate credit. Contents may not be used for commercial purposes, or adapted, remixed, transformed or built upon. (<https://creativecommons.org/licenses/by-nc-nd/4.0/>)  
Thieme Medical and Scientific Publishers Pvt. Ltd., A-12, 2nd Floor, Sector 2, Noida-201301 UP, India

She was recently diagnosed with type 2 diabetes mellitus during her admission and was on monotherapy of metformin. After discharge, during follow-up she complained of dysuria and lower abdominal discomfort. Her general examination was unremarkable apart from suprapubic tenderness. Her biochemistry parameters were normal, blood sugar levels were between 180 and 220 mg/dL, and glycosylated hemoglobin was 5.8%. Urinalysis revealed few epithelial cells, increased red blood cells—138/high-power field (HPF) and raised leukocytes—146/HPF. Glucose levels in urine were 32mg/dL. She was treated with oral antibiotics for 10 days, her symptoms persisted and she was restarted on second-line antibiotics and a urine sample was sent for culture, the culture was negative for bacterial growth. On ultrasonography (USG), right-sided hydronephrosis and hydroureter were detected. On further evaluation with CT study, there was circumferential enhancing thickening seen involving the right lower ureter with mild hydronephrosis and hydroureter in entire extent and evidence of a filling defect in the urinary bladder close to the vesicoureteric junction seen on excretory phase images (►Fig. 1). CT scan of the thorax revealed sequelae of viral pneumonitis. The possibility of urothelial carcinoma was considered on radiological imaging. Cystoscopy was performed that revealed a whitish friable mass-like lesion, which looked like a tuft of cotton in the urinary bladder close to the right ureteric orifice (►Fig. 2). The adjacent bladder mucosa appeared erythematous. The mass-like lesion was resected histology that revealed abundant fungal hyphae, which were broad, nonseptate with irregular branching at right angles (►Fig. 3). There was no evidence of atypical cells seen. The sample was sent for bacterial and fungal culture. The culture showed rapid growth on potato dextrose agar within 72 hours in the form of whitish layers. Lactophenol cotton blue mount of the growth revealed rhizoids, sporangium, and sporangiophore appearance characteristic for *Rhizopus* species (►Fig. 3). Thus, the diagnosis of vesical mucormycosis was reached.

The patient was started on intravenous liposomal amphotericin B that was continued for 6 weeks followed by posaconazole 300 mg daily for 4 weeks. Her blood sugars were controlled on metformin and sitagliptin. She was asymptomatic after 10 weeks of antifungal treatment. Uri-



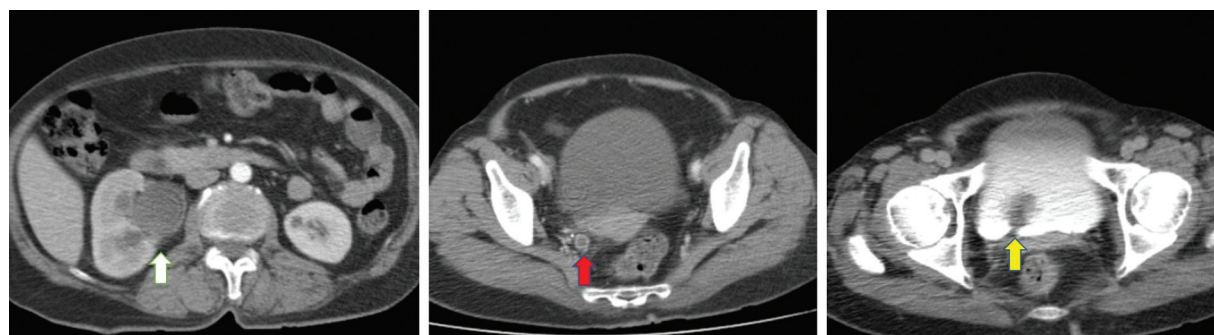
**Fig. 2** Cystoscopy image revealing a whitish friable mass-like lesion looking like a tuft of cotton in the urinary bladder close to the right ureteric orifice (arrow) and erythematous changes seen in the adjacent bladder mucosa (arrowhead).

nalys is was unremarkable with no growth seen on culture. Repeat USG and cystoscopy revealed response to treatment.

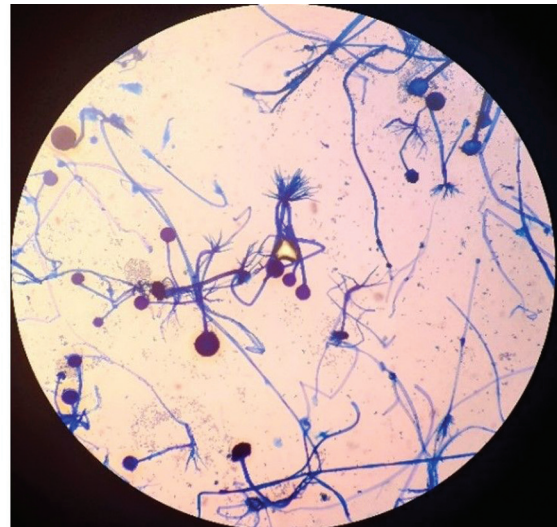
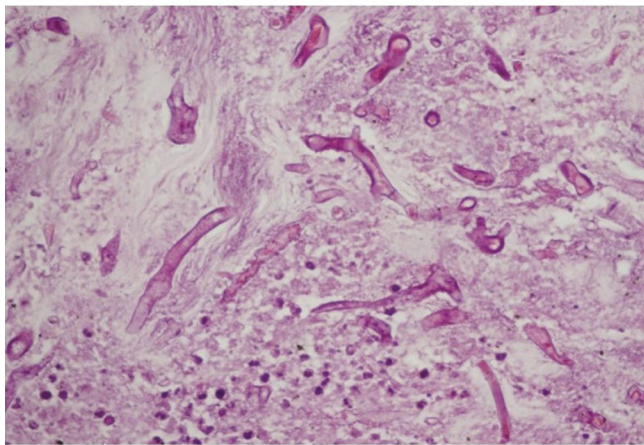
## Discussion

In the current COVID-19 pandemic, there has been a rise in the incidence of mucormycosis in India, due to multiple factors such as the high prevalence of Mucorales in the environment, steroid overuse in the management of COVID-19 resulting in new-onset diabetes, and irrational use of broad-spectrum antibiotics. Mucormycosis is caused by fungi of the order Mucorales that belongs to a class of Zygomycetes. Isolated mucormycosis involving the urinary bladder is rare.<sup>1</sup>

Very few cases of mucormycosis involving the urinary bladder have been described in the literature. A vesical noninvasive *Rhizopus* fungal ball infection with ascending pyelonephritis has been described previously in a patient with poorly controlled diabetes mellitus.<sup>2</sup> However, isolated bladder mucormycosis has been reported previously in an elderly patient with a permanent bladder catheter.<sup>3</sup> Fungal bezoars causing ureteric obstruction are rare. *Candida* is the



**Fig. 1** The right kidney shows a suboptimal nephrogram with hydronephrosis (white arrow). The right lower ureter appears dilated with enhancing urothelial thickening (red arrow). A filling defect (yellow arrow) is seen in the urinary bladder close to the vesicoureteric junction on excretory phase images.



**Fig. 3** Tissue sections (hematoxylin and eosin  $\times 400$ ) reveal nonseptate hyphae of mucormycetes with wide-angle branching (right) and lactophenol cotton blue mount revealing rhizoids, sporangium, and sporangiophore appearance characteristic for *Rhizopus* species (left).

most common causative organism, with other fungi being aspergillus, penicillium, and mucor.<sup>3</sup>

These patients may present with nonspecific symptoms or symptoms of urinary tract infections as in our patient. Often nasal cavity, paranasal sinuses, or the lungs are the primary focus of infection with involvement of other organs by dissemination from these sites. However, in our case, there was no evidence of involvement of other organs on clinical as well as imaging evaluation.

USG findings are usually nonspecific. It can enable the identification of hydronephrosis and hydroureter in cases of a fungal bezoars causing ureteric obstruction. If large enough, fungal balls may be identified as hypoechoic round masses with no internal vascularity in color doppler study. In our case, USG failed to identify the fungal ball. CT findings include bladder or ureteric wall thickening, hydronephrosis, and hydroureter. Like in our case, vesical fungal bezoars have been described as radiolucent masses that appear as filling defects on excretory or retrograde urography study.<sup>4</sup> Cystoscopy may reveal ulcerated bladder mucosa, multiple mounds of tissue, and architectural distortion of the bladder.<sup>5,6</sup> The presence of broad septate or pauciseptate hyphae with wide-angle branching is characteristic of Mucorales fungi.<sup>2</sup>

The presence of suspicious features on imaging and identification of Mucorales on fungal culture calls for prompt intervention. Commonly a combination of medical as well as surgical management is necessary. The management of predisposing factors such as control of blood sugar levels or reduction in immunosuppressive therapy is also of utmost importance.

Early diagnosis is crucial in the management of mucormycosis as prompt treatment can prevent dissemination of

disease process and involvement of critical organs, thus allowing a favorable prognosis.

#### Conflicting Interest

None declared.

#### Acknowledgment

We thank Dr. Avinash Dyandeo Talele and Dr. Dipak Najan for providing patient's clinical information and Dr. Divya Patekar for providing microbiological details.

#### References

- Petrikkos G, Skiada A, Lortholary O, Roilides E, Walsh TJ, Kontoyiannis DP. Epidemiology and clinical manifestations of mucormycosis. *Clin Infect Dis* 2012;54(Suppl 1):S23–S34
- Barnes AMT, Crespo-Diaz RJ, Cohenour J, Kirsch JD, Arbefeveille S, Ferrieri P. A noninvasive *Rhizopus* infection with a bladder fungal ball in a patient with poorly controlled diabetes mellitus. *Lab Med* 2017;49(01):75–79
- Praz V, Burrini R, Meid F, Wisard M, Jichlinski P, Tawadros T. Fungus ball in the urinary tract: a rare entity. *Can Urol Assoc J* 2014;8(1-2):E118–E120
- Nain PS, Singal R, Goyal A, Singh K, Matta H, Singal S. An awareness of a possible cause of obstruction due to an ureteric aspergilloma mistaken for stone. *Maedica (Bucur)* 2013;8(03):272–275
- Izquierre-Anariba DE, Chee F, Thet Z, Lanza J. An interesting case of a 57-year-old male with an upper gastrointestinal bleeding and obstructive uropathy with bilateral hydronephrosis diagnosed with systemic mucormycosis. *Case Rep Infect Dis* 2018; 2018:6283701. Doi: 10.1155/2018/6283701
- Gupta K, Nada R, Joshi K, Rohilla M, Walia R. Can ascending infection from bladder serve as the portal of entry for primary renal zygomycosis? *Mycopathologia* 2010;170(05):357–360