



Epidemiological Analysis of Glomus Tumors of the Hand and Association with Recurrence Rate

Análisis epidemiológico de los tumores glómicos de la mano y asociación con la tasa de recurrencia

Giovanni Vilardo Cerqueira Guedes¹ Daniel Torres Jácome¹ Gabriel Farias Alves²
Anderson Vieira Monteiro¹

¹ Division of Hand Surgery, Department of Orthopedics and Traumatology, Instituto Nacional de Traumatologia e Ortopedia Jammil Haddad (INTO), Rio de Janeiro, RJ, Brazil

² Department of Orthopedics and Traumatology, Instituto Nacional de Traumatologia e Ortopedia Jammil Haddad (INTO), Rio de Janeiro, RJ, Brazil

Address for correspondence Giovanni Vilardo Cerqueira Guedes, MD, Divisão de Cirurgia da Mão, Departamento de Ortopedia e Traumatologia, Instituto Nacional de Traumatologia e Ortopedia Jammil Haddad (INTO), Avenida Brasil 500, Caju, Rio de Janeiro, RJ, 20940-070, Brasil (e-mail: vcggiovanni@gmail.com).

Rev Iberam Cir Mano 2022;50(1):e27–e33.

Abstract

Introduction Glomus tumors are benign, characterized by microvascular alteration, and mostly found in the subungual region of the hand. They are rare and associated with paroxysmal pain, tenderness on palpation, and thermal sensitivity. The aim of the present research was to analyze the epidemiology of glomus tumors and relate each of the variables with cases of recurrence.

Materials and Methods A retrospective review of medical records was undertaken in our hospital to collect epidemiological numerical variables (time between the onset of symptoms and diagnosis and surgery, age, size of the tumor on magnetic resonance imaging and the histopathological examination, time until recurrence and reoperation after surgery, duration of the follow-up) and categorical variables (gender, ethnicity, laterality, affected finger, location in the hand, surgical technique, smoking, preoperative symptoms, recurrence, and comorbidities). Then, we performed a statistical analysis to identify possible associations of the hand tumors with recurrences.

Results The review identified 66 patients with glomus tumors 52 of which were located in the hand. The mean age of the sample was 49 years, and it was mostly composed of white female patients. Pain was the main related symptom, and most tumors presented sizes between 5 mm and 1 cm. Among the 52 patients, 11 cases presented recurrences, with a mean time until onset of 39.4 months, but 3 of them were initially operated on at other hospitals. None of the variables was shown to be a predictor of recurrence, although we saw that bone involvement on radiographs was only present in certain cases of recurrence.

Keywords

- ▶ epidemiology
- ▶ glomus tumor
- ▶ hand

received
December 22, 2021
accepted
February 8, 2022

DOI <https://doi.org/10.1055/s-0042-1744466>.
ISSN 1698-8396.

© 2022. SECMA Foundation. All rights reserved.

This is an open access article published by Thieme under the terms of the Creative Commons Attribution-NonDerivative-NonCommercial-License, permitting copying and reproduction so long as the original work is given appropriate credit. Contents may not be used for commercial purposes, or adapted, remixed, transformed or built upon. (<https://creativecommons.org/licenses/by-nc-nd/4.0/>)

Thieme Revinter Publicações Ltda., Rua do Matoso 170, Rio de Janeiro, RJ, CEP 20270-135, Brazil

Conclusion The sample studied was large for this rare disease, and reinforced previous results regarding its epidemiology. As 54% of the cases of recurrence occurred at least twice, we think that genetic, histological and immunohistochemical analyses should be the focus of futures studies, as well as a search for bone and tendon involvement.

Resumen

Introducción Los tumores glómicos son benignos, caracterizados por una alteración microvascular, y se encuentran con más frecuencia en la región subungueal de la mano. Son raros, y están asociados con dolor paroxístico, y sensibilidad al tacto y térmica. El objetivo de esta investigación fue analizar la epidemiología de los tumores glómicos y relacionar cada una de las variables con casos de recurrencia.

Materiales y métodos Se realizó una revisión retrospectiva de los historiales en nuestro hospital para recoger variables epidemiológicas numéricas (tiempo entre el inicio de los síntomas y el diagnóstico y la cirugía, edad, tamaño del tumor en resonancia magnética y en el examen histopatológico, tiempo hasta la recurrencia y la reintervención después de la cirugía, y tiempo de seguimiento) y categóricas (género, etnia, lateralidad, dedo afectado, localización en la mano, técnica quirúrgica, tabaquismo, síntomas preoperatorios, recurrencia, y comorbilidades). Luego, se realizó un análisis estadístico para identificar posibles asociaciones de los tumores de la mano con recurrencias.

Resultados La revisión identificó 66 pacientes con tumores glómicos, de los cuales 52 fueron localizados en la mano. La edad media de la muestra fue de 49 años, y la mayoría era de mujeres blancas. El dolor fue el principal síntoma relacionado, y la mayoría de los tumores presentaron tamaños entre 5 mm y 1 cm. De los 52 pacientes, 11 casos presentaron recurrencias con un tiempo medio de inicio de 39,4 meses, pero 3 de ellos fueron operados inicialmente en otros hospitales. Ninguna de las variables demostró ser un predictor de recurrencia, aunque vimos que el acometimiento óseo en la radiografía sólo estaba presente en algunos casos de recurrencia.

Conclusión La muestra estudiada fue grande para esta enfermedad rara, y reforzó los resultados previos en cuanto a su epidemiología. Como el 54% de los casos de recurrencia ocurrieron al menos 2 veces, creemos que el análisis genético, histológico e inmunohistoquímico debería ser el foco de los estudios futuros, así como la búsqueda de acometimiento óseo y tendinoso.

Palabras clave

- ▶ epidemiología
- ▶ tumor glómico
- ▶ mano
- ▶ recurrencia

Introduction

Glomus tumors are characterized by a microvascular alteration most commonly found in the subungual region of the hand,¹ more specifically in the central proximal region of the nail bed² (► **Fig. 1**). They were first described by Wood in 1812 as painful subcutaneous tubercles, and present a classical triad of paroxysmal pain, tenderness, and thermal sensitivity (mainly to cold).³ Glomus tumors are usually benign and represent between 1% and 5% of soft-tissue tumors of the hand.⁴

The treatment of choice for the lesion is total excision, which has shown excellent results, especially in terms of pain reduction⁵ (► **Fig. 2**). Tumor recurrence rates are reported to be above 20% by some authors.⁶ Some cases of recurrence are believed to occur due to inadequate excision, while there is also the possibility of recurrence

due to satellite lesions not detected at the time of the diagnosis.^{7,8} The reported epidemiology of this neoplasm is similar in most studies, but the majority lack a large sample. Those with the largest samples are usually epidemiologic studies conducted in a specific country,⁹ or studies on surgeries performed in different centers.¹⁰ In addition, there are few articles¹¹ that evaluate any potential association between the appearance of glomus tumors and ethnicity.

The present study was conducted in Brazil, a country with great ethnic diversity, among patients treated at our institution, which is a center of excellence where the management of specific pathologies follows similar treatment protocols, thus ensuring uniform results. The aim of the present study was to analyze the epidemiology of glomus tumors and relate a range of variables with cases of recurrence to identify any undiscovered associations.

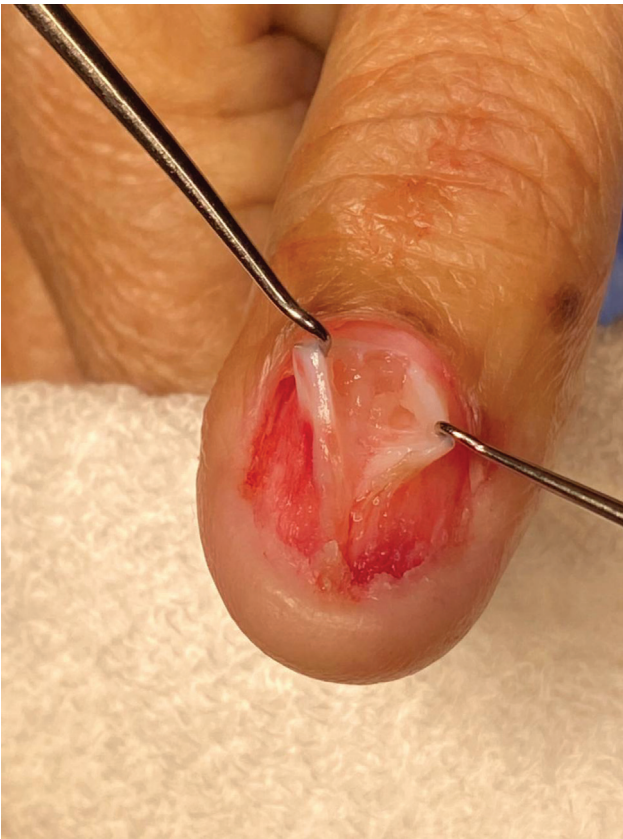

Fig. 1 Subungual glomus tumor.

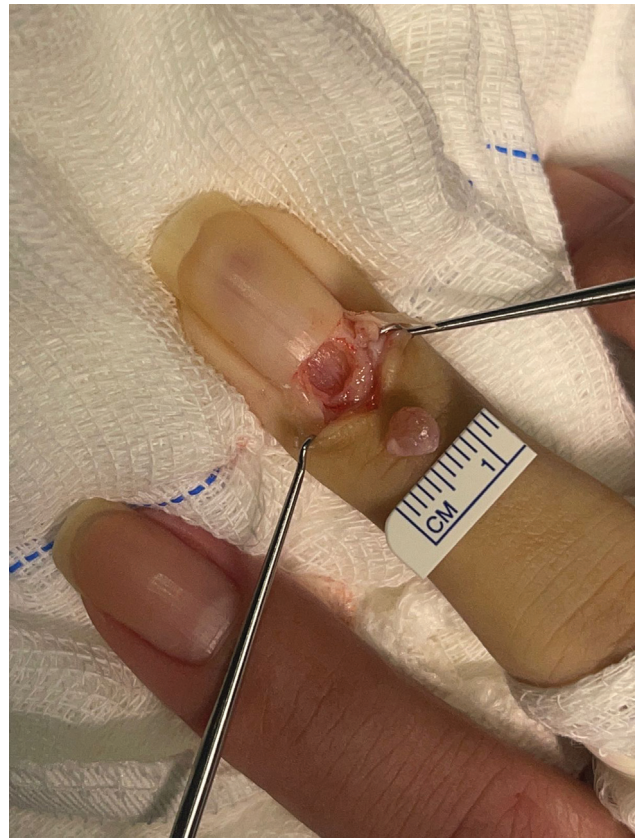


Fig. 2 Excised glomus tumor.

Materials and Methods

A search was performed on the database of our Department of Pathology to identify histopathological reports that included diagnoses of “glomus tumor,” “glomangioma,” “glomangiomyoma,” “glomangiosarcoma,” and “malignant glomus tumor.” A total of 68 patients were identified from February 2000 to January 2021. Subsequently, the medical records of these patients were requested for analysis and to complete a data collection form. The records of two of the patients were not available, so they were excluded from the study, leaving a final sample of 66 patients. The project was approved by our institutional review board, with an exemption being granted for the need for a specific written informed consent form in line with the rules of the institution.

The data collection form recorded a range of numerical variables (time between the onset of symptoms and surgery, age at the date of the surgery, time from the onset of symptoms until diagnosis, size of the tumor on magnetic resonance imaging, time until recurrence after surgery, time until reoperation after recurrence, duration of the follow-up, histopathological size) and categorical variables (gender, ethnicity, laterality, affected finger, location in the hand, surgical technique, smoking, preoperative symptoms, recurrence, and comorbidities). Radiographs of the patients were also checked in the hospital database to assess bone involvement.

We then developed a table detailing the patients who had the tumor in the hand and those who presented another topography. This was used to correlate the categorical variables with the recurrence of the tumor using the Chi-squared test (considering significant a p values ≤ 0.05).

Results

A total of 52 (78.8%) patients had a history of glomus tumor in the hand, and 14 (21.2%), in other locations in the body. Of the latter, 2 (14.3%) were in the leg, 3 (21.4%), in the knee, 6 (42.9%), in the foot, and 3 (21.4%), in the forearm. In the hand, 40 (75.5%) cases occurred in the subungual region, 9 (17.0%), in the digital pulp, and 4 (7.5%), in other parts of the hand (it is worth mentioning that the sum is higher than the total number because 1 patient had a tumor in 2 locations). Only one case of malignant tumor (located in the leg) was evidenced.

Tumor topography is described in ►Table 1. Among those found in other regions of the hand, 2 (50.0%) were in areas of soft tissue in the proximal phalanx of the index finger, 1 (25.0%), in the tip of the ring finger, and 1 (25.0%), in the area of soft tissue around the metacarpophalangeal joint of the little finger, with no involvement of the thumb or middle finger observed. In terms of laterality, 24 (46.1%) cases were in the right hand, and 27 (51.9%), in the left hand, with 1 (1.9%) bilateral case. In demographic terms, 44 (84.6%) participants

Table 1 Tumor topography

	Thumb	Index finger	Middle finger	Ring finger	Little finger
Subungual	15 (37.5%)	5 (12.5%)	10 (25%)	7 (17.5%)	3 (7.5%)
Digital pulp	2 (22.2%)	1 (11.1%)	0 (0%)	3 (33.3%)	3 (33.3%)

Table 2 Time periods observed (in months)

	Average time	Standard deviation	Shortest	Longest
ΔT Diagnosis-surgery	63.1	± 59.6	3	264
ΔT Onset of symptoms-diagnosis	52	± 48.24	4	240
ΔT Follow-up	19.3	± 44.5	3	240
ΔT Recurrence	39.4	37.6	5	120

were female, and 8 (15.4%), male. Regarding ethnicity, 26 (51.0%) patients were white, 14 (27.4%), mixed-race (people who do not self-identify as black, indigenous, Asian or white), and 11 (21.6%), black. The mean age of the sample was of 49 (standard deviation [SD]: ± 12.2) years, with the oldest patient being 81 and the youngest, 23 years old.

Of the 41 patients who did not have recurrences, only 5 had radiographic records, none with bone involvement. As for the cases of recurrence, 6 patients had radiographic records, 4 of which had bone involvement.

Of the classic signs and symptoms, the main one was pain (96.1%), followed by cold sensitivity (25.0%), nail deformity (19.2%) and color change (7.7%). Regarding the comorbidities, systemic arterial hypertension (44.2%), diabetes mellitus (15.4%) and hypothyroidism (11.5%) were the most found. One patient presented neurofibromatosis. Only 8 patients (15.7%) were smokers. The time periods observed are described in **Table 2**.

Regarding surgical techniques, the most used was the transungual approach in 38 (73.0%) cases, followed by the volar approach in 10 (19.2%), the midlateral in 3 (5.8%), and the dorsal only in 1 (1.9%) case. As for the size of the hand tumors, 16 (32.0%) patients had tumors smaller than 5 mm, 29 (58.0%), between 5 mm and 1 cm, and 5 (10.0%), between 1 cm and 2 cm. The tumors presented a mean length of 6.5 mm (SD: ± 4.4 mm) and a mean width of 5.0 mm (SD: ± 3.2 mm). The largest tumor observed in the hand had dimensions of 30 \times 20 mm (in the digital pulp) and the smallest, 1 \times 1 mm (subungual). The largest subungual tumor presented dimensions of 14 \times 12 mm.

Within the sample studied, 11 (22%) patients had tumor recurrence, with 5 patients having a second episode of recurrence, and 1, a third. A total of 3 patients had undergone surgery at a different institution, so only 8 (15.3%) of our primary surgeries recurred. Of the variables studied, none presented any statistical correlation with the recurrences, as shown in **Table 3**.

Discussion

Glomus tumors can appear on different locations in the human body, including the fingers, legs, chin, trachea and even organs such as the stomach.¹² Most tumors in our sample were in the hand, which is probably due to the fact that our center specializes in traumatology and orthopedics, while patients with tumors in other areas are usually referred to hospitals with other specialties, such as dermatology. Even so, a case of a malignant glomus tumor in the leg was found, which, as the literature shows, is extremely rare, locally aggressive, and rarely presents metastasis.^{13,14} A review study¹⁵ states that there are only six cases reported in the hand.

Regarding the epidemiology, as in other studies in the literature,¹⁶ there was a predominance of cases in female patients. The mean age also followed previous studies.¹⁷ Regarding ethnicity, our results suggest that glomus tumors are more prevalent in the white population, as observed in a previous study¹⁰ conducted in Brazil with a smaller sample. It is important that future studies also consider this factor to better establish whether there is an association between ethnicity and the condition.

Magnetic resonance imaging (**Fig. 3**) is an extremely important tool to help in the diagnosis of glomus tumors, not only in terms of the initial diagnosis of subungual tumors with few visible alterations on a physical examination,¹⁸ but also in cases of recurrence, to differentiate tumors from scar tissue or to identify complications such as neoplastic tissue neuromas.¹⁹ Ultrasound usually shows a well-defined small hypoechoic nodule beneath the nail bed, with adjacent distal phalangeal bony erosion. Doppler can show prominent internal vascularity, which is an important finding.²⁰

In our review of the medical records, it was notable that 4 of the cases of recurrence were shown to have bone involvement on plain radiography (**Fig. 4**). It was not possible to perform a statistical analysis of this variable due to the lack of radiographs in the cases that did not have recurrence; however, apart from the fact that we did not find any

Table 3 Statistical correlation analysis of recurrence

	Recurrence	No recurrence	p-value
Gender			
Female	11	31	0.1
Male	0	8	
Ethnicity			
White	7	17	0.5
Mixed-race	2	12	
Black	2	9	
Tumor location			
Subungual	10	29	0.6
Digital pulp	1	7	
Hand	0	4	
Surgical technique			
Transungual	10	27	0.5
Volar	1	8	
Dorsal	0	1	
Midlateral	0	3	
Smoking			
Yes	1	7	0.5
No	10	31	
Laterality			
Right	3	20	0.3
Left	8	18	
Bilateral	0	1	
Multicentric			
Yes	0	1	0.6
No	11	38	
Histopathological size			
< 5 mm	3	13	1.0
0.5–1 cm	5	22	
1–2 cm	1	4	

Note: Some patients did not present complete data in their medical records, which excluded them from some of the analyses performed.

evidence, we think it would be worthwhile for future studies to evaluate the value of plain radiography to predict recurrence.

In the analysis of the cases of recurrence, it was not possible to find a statistical correlation among the variables studied. In the literature, there is a great deal of variability in the estimates of the rates of recurrence, with a mean value of 20%, and multiples hypotheses with respect to the reasons for recurrence, such as incomplete excision,²¹ the presence of multiple tumors,²² or malignancy.²³

In our sample, more than half (6 out of 11) of the patients who had recurrence also had a further episode of recurrence, which leads us to believe that it is possible that inherent characteristics of the tumor, such as gene expression and

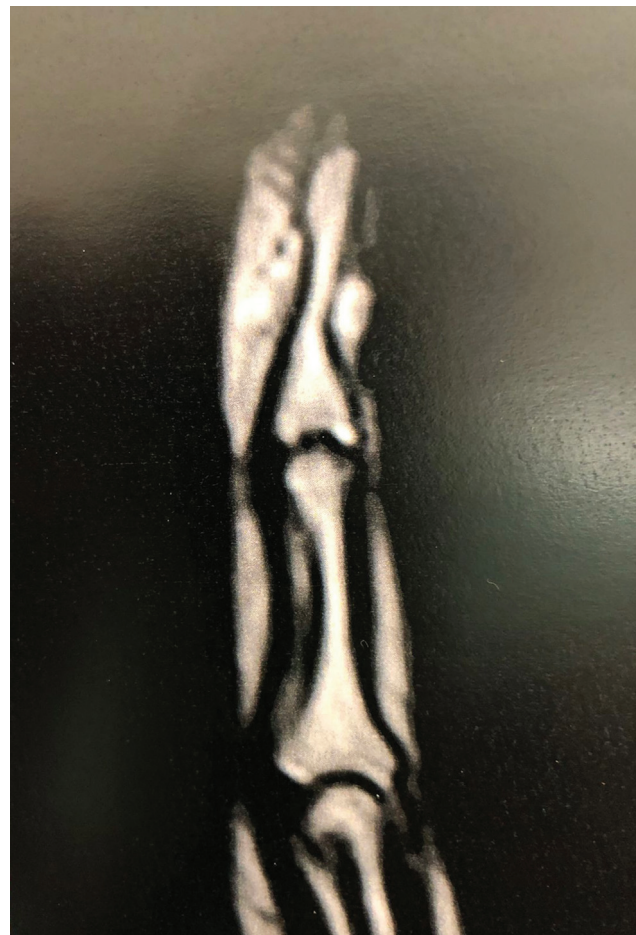

Fig. 3 Magnetic resonance imaging scan of a finger showing a subungual glomus tumor.

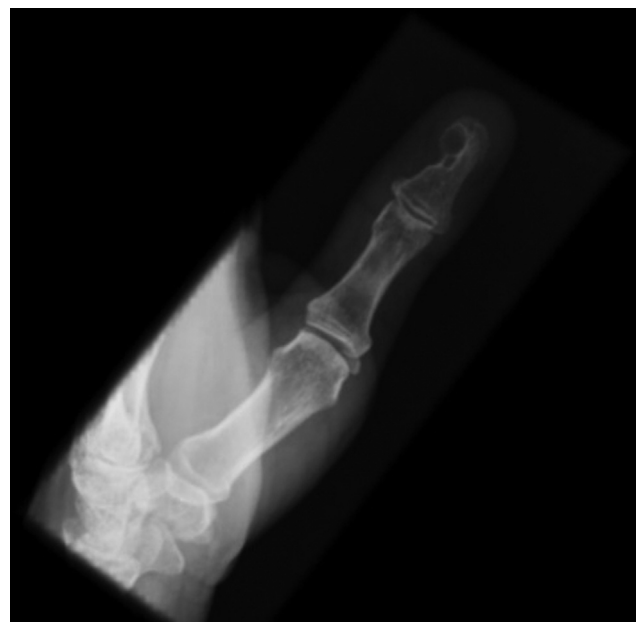

Fig. 4 Radiograph showing bone involvement after recurrence of a glomus tumor.

histological type contribute more to its recurrence than failures of the surgical procedure. We believe that this is a

more likely explanation given the highly specialized care provided by our institution in cases in which recurrence has already been observed.

It is believed that most glomus tumors are sporadic; however a glomangioma familial variant linked to the 1p21–22 chromosome and involving mutations in the glomulin gene has been identified.²⁴ As for immunohistochemistry, almost 100% of tumors present a positive response to α -smooth muscle actin, muscle specific actin, and vimentin, and a negative one to CD31, desmin, keratins, and S100, with CD34 appearing in 32% and calponin, in 80% of the cases.²⁵ The histology depends on the proportion of glomus cells, the vascular tissue, and stroma.²⁶

The present is a retrospective study, which leads to a limitation in the sense of generating causal hypotheses for the results. In addition, we have very few patients radiographed at the time of diagnosis. On the other hand, we have shown, in the same hospital, a large sample of a rare disease with many epidemiological peculiarities, including racial predilection, which has been little discussed so far.

Conclusions

The results of the present study show that, as with other hand diseases (such as macrodactyly²⁷ and other types of tumors), genetic, histological and immunohistochemical analyses should be the focus of future research, aiming to identify the possible causes and predictors of glomus tumors and their recurrence, and to find a cure. Likewise, preoperative bone and tendon involvement could be studied in more detail to reveal the predisposition to recurrence.

Ethical Approval Declaration

Ethical approval to report this case was obtained from the Ethics Committee of Instituto Nacional de Traumatologia e Ortopedia Jamil Haddad (INTO).

Informed Consent Declaration

A waiver of written informed consent was obtained according to the Ethics Committee of Instituto Nacional de Traumatologia e Ortopedia Jamil Haddad (INTO)

Contributorship Details

Giovanni Guedes and Gabriel Alves wrote the first draft of the manuscript. All authors reviewed and edited the manuscript and approved the final version.

Funding Statement

The authors have received no financial support for the research, authorship, and/or publication of the present article.

Conflict of Interests

The authors have no conflict of interests to declare.

References

- McDermott EM, Weiss A-PC. Glomus tumors. *J Hand Surg Am* 2006;31(08):1397–1400
- Civan O, Güntürk ÖB, Özaksar K, Cavit A, Özcanlı H. Glomus tumors of the nail bed: topographic anatomy and an algorithmic approach based on the topography. *Handchir Mikrochir Plast Chir* 2020;52(03):202–206
- Lee W, Kwon SB, Cho SH, Eo SR, Kwon C. Glomus tumor of the hand. *Arch Plast Surg* 2015;42(03):295–301
- Nazerani S, Motamedi MHK, Keramati MR. Diagnosis and management of glomus tumors of the hand. *Tech Hand Up Extrem Surg* 2010;14(01):8–13
- Takata H, Ikuta Y, Ishida O, Kimori K. Treatment of subungual glomus tumour. *Hand Surg* 2001;6(01):25–27
- Netscher DT, Aburto J, Koeplinger M. Subungual glomus tumor. *J Hand Surg Am* 2012;37(04):821–823, quiz 824
- Dailiana ZH, Drapé JL, Le Viet D. A glomus tumour with four recurrences. *J Hand Surg [Br]* 1999;24(01):131–132
- Gandhi J, Yang SS, Hurd J. The anatomic location of digital glomus tumor recurrences. *J Hand Surg Am* 2010;35(06):986–989
- Moojen TM, Houpt P. Glomus tumors of the hand in the Netherlands: analysis of 107 patients. *Eur J Plast Surg* 2000;23(04):224–226
- Kim YJ, Kim DH, Park JS, Baek JH, Kim KJ, Lee JH. Factors affecting surgical outcomes of digital glomus tumour: a multicentre study. *J Hand Surg Eur Vol* 2018;43(06):652–658
- Vanti AA, Cucé LC, Di Chiacchio N. Subungual glomus tumor: epidemiological and retrospective study, from 1991 to 2003. *An Bras Dermatol* 2007;82(05):425–431
- Schiefer TK, Parker WL, Anakwenze OA, Amadio PC, Inwards CY, Spinner RJ. Extradigital glomus tumors: a 20-year experience. *Mayo Clin Proc* 2006;81(10):1337–1344. Doi: 10.4065/81.10.1337
- Park J-H, Oh S-H, Yang M-H, Kim N-I. Glomangiosarcoma of the hand: a case report and review of the literature. *J Dermatol* 2003;30(11):827–833. Doi: 10.1111/j.1346-8138.2003.tb00486.x
- Rahbari K, Farzan M, Saffar H, Farhoud AR. Glomus Tumor of Uncertain Malignant Potential in Thumb: A Case Report and Review of Literature. *Arch Bone Jt Surg* 2020;8(01):117–120. Doi: 10.22038/abjs.2019.35225.1928
- Woodward JF, Jones NF. Malignant Glomus Tumors of the Hand. *Hand (N Y)* 2016;11(03):287–289. Doi: 10.1177/1558944715614874
- Van Geertruyden J, Lorea P, Goldschmidt D, et al. Glomus tumours of the hand. A retrospective study of 51 cases. *J Hand Surg [Br]* 1996;21(02):257–260. Doi: 10.1016/s0266-7681(96)80110-0
- Obeid AE, Al-Nasheet H, Alsharakat AH, et al. Clinical and Histopathological diagnosis of glomus tumor: A 6 year institutional retrospective study. *Int J Orthopaed Sci* 2020;6(04):285–288. Doi: 10.22271/ortho.2020.v6.i4e.2352
- Ham KW, Yun IS, Tark KC. Glomus tumors: symptom variations and magnetic resonance imaging for diagnosis. *Arch Plast Surg* 2013;40(04):392–396. Doi: 10.5999/aps.2013.40.4.392
- Theumann NH, Goettmann S, Le Viet D, et al. Recurrent glomus tumors of fingertips: MR imaging evaluation. *Radiology* 2002;223(01):143–151. Doi: 10.1148/radiol.2231010977
- Nepal P, Songmen S, Alam SI, Gandhi D, Ghimire N, Ojili V. Common Soft Tissue Tumors Involving the Hand with Histopathological Correlation. *J Clin Imaging Sci* 2019;9:15. Doi: 10.25259/JCIS-6-2019
- Hazani R, Houle JM, Kasdan ML, Wilhelmi BJ. Glomus tumors of the hand. *Eplasty* 2008;8:e48
- Hamdi MF. Glomus tumour of fingertip: report of eight cases and literature review. *Musculoskelet Surg* 2011;95(03):237–240. Doi: 10.1007/s12306-011-0133-8
- Chou T, Pan SC, Shieh SJ, Lee JW, Chiu HY, Ho CL. Glomus Tumor: Twenty-Year Experience and Literature Review. *Ann Plast Surg* 2016;76(Suppl 1):S35–S40. Doi: 10.1097/SAP.0000000000000684
- Gombos Z, Zhang PJ. Glomus tumor. *Arch Pathol Lab Med* 2008;132(09):1448–1452. Doi: 10.5858/2008-132-1448-GT
- Mravic M, LaChaud G, Nguyen A, Scott MA, Dry SM, James AW. Clinical and histopathological diagnosis of glomus tumor: an

- institutional experience of 138 cases. *Int J Surg Pathol* 2015;23(03):181–188. Doi: 10.1177/1066896914567330
- 26 Liapi-Avgeri G, Karabela-Bouropoulou V, Agnanti N. Glomus tumor. A histological, histochemical and immunohistochemical study of the various types. *Pathol Res Pract* 1994;190(01):2–10. Doi: 10.1016/S0344-0338(11)80490-5
- 27 Sun B, Jiang Y, Cui H, et al. Activating PIK3CA mutation promotes adipogenesis of adipose-derived stem cells in macrodactyly via up-regulation of E2F1. *Cell Death Dis* 2020;11(07):600. Doi: 10.1038/s41419-020-02806-1