



Growing Teratoma Syndrome—A Clinicoradiological Series

Sheena Prineethi¹ Aparna Irodi¹ Anu Eapen¹ Sharon Milton² Anjana Joel³

¹Department of Radiology, Christian Medical College, Vellore, Tamil Nadu, India

²Department of Pathology, Christian Medical College, Vellore, Tamil Nadu, India

³Department of Medical Oncology, Christian Medical College, Vellore, Tamil Nadu, India

Address for correspondence Anjana Joel, MD, DM, DNB, Department of Medical Oncology, Christian Medical College, Vellore 632004, Tamil Nadu, India (e-mail: anjanajoel@gmail.com).

Indian J Radiol Imaging 2022;32:301–307.

Abstract

Context Growing teratoma syndrome (GTS) is a rare entity seen following chemotherapy for metastatic nonseminomatous germ cell tumors, characterized by increase in size of the metastatic deposits, with normal serum tumor markers.

Aims In this article, we aim to describe the various clinicoradiological presentations of GTS treated at our center.

Design All patients who satisfied the GTS criteria from 2001 to 2019 were included. Characteristic imaging appearances along with sites of primary lesion and metastatic disease, stage and risk stratification at diagnosis, details of chemotherapy, details of surgical treatment and histopathology, levels of tumor markers, serum β -human chorionic gonadotropin, lactate dehydrogenase, and alpha fetoprotein levels at baseline and at the end of all chemotherapy were analyzed.

Results The significant radiological findings observed were an increase in the fat and cystic components and appearance of coarse calcifications within the lesions. Majority of the cases were male patients (87.5%) with testicular primaries and GTS transformation in nodal metastases being the most common occurrence (75%). All eight cases (100%) showed an increase in size and cystic component, whereas four out of eight cases (50%) had presence of internal septations and internal calcification.

Conclusion Early recognition of this entity and clinical decision making through serial radiological imaging are of utmost importance as these growing deposits are resistant to chemotherapy and radiotherapy, with complete surgical excision being the only curative and definitive treatment option.

Keywords

- ▶ growing teratoma syndrome
- ▶ germ cell tumor
- ▶ nonseminomatous germ cell tumor
- ▶ mature teratoma
- ▶ chemotherapy

Introduction

Growing teratoma syndrome (GTS) is a rare entity, with an estimated incidence of 1.9 to 12%, following chemotherapy for nonseminomatous germ cell tumors (NSGCTs) of gonadal

and extragonadal origin, respectively.¹ Patients with an increase in size of metastatic lesions (in case of gonadal primaries) in the presence of normalized serum tumor markers fit into the label of “growing teratoma syndrome.”² Though GTS is commonly diagnosed at the end of first-line

published online
August 17, 2022

DOI <https://doi.org/10.1055/s-0042-1744519>.
ISSN 0971-3026.

© 2022. Indian Radiological Association. All rights reserved.
This is an open access article published by Thieme under the terms of the Creative Commons Attribution-NonDerivative-NonCommercial-License, permitting copying and reproduction so long as the original work is given appropriate credit. Contents may not be used for commercial purposes, or adapted, remixed, transformed or built upon. (<https://creativecommons.org/licenses/by-nc-nd/4.0/>)
Thieme Medical and Scientific Publishers Pvt. Ltd., A-12, 2nd Floor, Sector 2, Noida-201301 UP, India

chemotherapy for gonadal GCTs, there are also reports of GTS transformation in primary lesions of mediastinal GCTs as described in this case series.³

Following the initial report by Logothetis et al, three criteria are essential for the diagnosis of GTS: (i) normalization of previously elevated serum tumor markers, that is, alpha fetoprotein (AFP), and/or β -human chorionic gonadotrophin (β -HCG); (ii) increase in size of tumor while on or after completion of chemotherapy for NSGCT; and (iii) absence of any viable NSGCT component other than mature teratoma in the resected specimen.⁴ GTS, thus, poses a diagnostic dilemma, owing to the improving clinical condition of the patient with radiological progression in the setting of normal tumor markers. Early diagnosis of GTS is of utmost importance since these patients have an excellent prognosis, following early and complete resection of the metastatic lesions.^{5,6} Since GTS does not respond to chemotherapy or radiation therapy, timely recognition of this condition is essential to avoid unnecessary escalation of treatment to subsequent lines of salvage chemotherapy, which adds unnecessary toxicity in lieu of any additional benefit to the patient. Complete surgical resection is the current gold standard for treatment of GTS.⁷

In this case series, we describe eight patients with proven GTS, with different modes of presentation and at different timelines from the initiation of chemotherapy. We aim to provide more insight into GTS, in terms of the varying clinicoradiological presentations and their outcomes following appropriate surgical intervention.

Methodology

We reviewed the computed tomographic (CT) imaging of all patients diagnosed with germ cell tumors at our center from 2001 to 2019. All patients whose scans showed a significant increase in size of tumor deposits in the presence of normalized tumor markers following chemotherapy were included. Baseline characteristics including the sites of primary lesion and metastatic disease, stage and risk stratification at diagnosis, details of chemotherapy, details of surgical treatment, and histopathology were collected. We noted the levels of tumor markers, serum β -HCG, lactate dehydrogenase, and AFP levels, at baseline and at the end of all chemotherapy. In addition to increase in the size of the lesions on imaging as mentioned above, we also reviewed few specific radiological findings like increase in cystic/fat components and appearance of calcifications in these lesions. All the cases were analyzed by three radiologists with 3 to 15 years of reporting experience among them, two of them specialized in chest and abdominal radiology. These radiological findings are described in detail in ►Table 1. Histopathology of all the cases were analyzed by pathologists with a minimum of 3 years pathology reporting experience. Seven out of the eight patients had histopathology fulfilling the criteria of GTS (presence of mature teratomatous components only). One patient (ovarian primary) fulfilled all the criteria of GTS, but did not undergo surgery and hence no histopathological evidence. All patients were followed up with serial CT imag-

ing and estimation of tumor markers at intervals of 4 to 6 months. Exclusion criteria included patients with radiological evidence of increase in size of the lesions with infiltration into surrounding structures, elevated tumor markers/insufficient laboratory evidence of tumor markers, and incomplete follow-up imaging.

Results

There were eight cases that satisfied the inclusion criteria and were analyzed accordingly. The demographic, radiological, and histopathology results of all the eight cases have been tabulated in ►Table 1.

Demographic results: Out of the eight cases, seven were male and only one was female patient. Age group was 17 to 44 years with mean age of 27 years.

Primary site: In our study, testicular primaries were the commonest, accounting for six (75%) out of eight patients in our series. Ovarian primary and primary mediastinal primary GCT accounted for one patient each, indicating the rarity of this association.

GTS transformation: Of our eight cases, there was a rare occurrence of GTS transformation of the primary site in one patient with primary mediastinal NSGCT. Among the remaining, GTS was encountered in nodal metastases in seven (75%) out of eight cases, all of whom had a primary of gonadal germ cell tumors. Five (62.5%) of our eight cases had retroperitoneal nodal metastases.

Radiological features: All the eight cases (100%) showed an increase in size and cystic component and well-circumscribed margins with no infiltration into the surrounding structures. Four out of the eight cases (50%) had the presence of internal septations and internal calcification. Only one case had an increase in the fat component.

Discussion

Though the term “growing teratoma syndrome” was first coined by Logothetis et al in 1982, the description of benign enlargement of metastatic lesions, among patients with NSGCTs following chemotherapy, was described almost a decade earlier by many other centers.^{4,8-10} The exact etiology of this condition is poorly understood; however, the proposed theories attribute this to the target specificity of chemotherapy to destroy only malignant cells, leaving behind residual benign mature teratomatous cells that continue to proliferate, (or) an alteration of cell kinetics by chemotherapy, resulting in a benign proliferation of mature teratomatous cells leading to increase in size of these metastatic lesions.^{9,10}

The chemotherapeutic agents used in treatment of GCTs are platinum based, with a combination of bleomycin, etoposide, and cisplatin (BEP) being the standard of care as first-line treatment.¹¹⁻¹³ Six out of eight cases received four cycles of BEP chemotherapy as first-line treatment, one received three cycles, and one received six cycles of BEP chemotherapy. All cases had documented normal tumor markers at the end of treatment.

Table 1 Summary of clinico-radiological findings of all patients (n = 8)

Age/sex	Primary	Treatment received	Site of metastases	Radiological characteristics—postchemotherapy						Treatment received for metastatic lesions	Histopathology findings
				Change in size	Margins	Cystic areas	Fat density	Septa	Calcification		
Case 1	34 /M NSGCT—left testis	Left: high inguinal orchiectomy 4 cycles of BEP chemotherapy	Left: paraaortic nodal mass	Significant increase	Well defined	Predominant	—	+	—	Total excision	Mature teratoma with areas of necrosis
Case 2	17/M NSGCT—right testis	Right: high inguinal orchiectomy 4 cycles of BEP chemotherapy	Left: cervical, retroperitoneal and mediastinal nodal mass	Significant increase and decrease in the internal vascularity	Better delineated and smooth margins	New cystic areas present with increase in the areas of necrosis	—	—	—	Total excision of all the nodal masses	Mature teratomatous components
Case 3	18/M Mixed GCT—left testis	Left: high inguinal orchiectomy 4 cycles of BEP chemotherapy	Left: paraaortic nodal mass at presentation before start of chemotherapy Interim CECT, post two cycles of chemotherapy New lesion—left level 5 cervical nodal mass	Significant increase	Well defined	Increased	—	—	—	Total excision of all the nodal masses	Mature teratomatous elements only—postpubertal type Areas of tumor necrosis, organizing hemorrhage, and no evidence of viable tumor
Case 4	26/M GCT—left testis	Left: high inguinal orchiectomy 3 cycles of BEP chemotherapy	Left: lung upper lobe lesion. Mediastinal and left paraaortic nodal mass	Significant increase	Well defined	Significant increase	—	—	+	Excision in stages – First mediastinal nodal mass, 4 months later lung lesion and left para-aortic nodal mass	Mature cystic teratoma
Case 5	48/M NSGCT—left testis	Left: high inguinal orchiectomy 6 cycles of BEP chemotherapy	Retrocaval nodal mass—metastatic lesion follow-up CT scans done 10, 11, and 24 years post-treatment	Significant increase	Well encapsulated with no infiltration into the surrounding structures	Predominant, with subsequent disappearance of small eccentric solid component over the years	—	+	+	Total excision	Well-differentiated benign teratomatous elements with no malignant cells.
Case 6	34/M NSGCT—left testis	Left: high inguinal orchiectomy 4 cycles of BEP chemotherapy	Left: paraaortic nodal mass	Increase in size	Well defined	Predominant	—	—	—	Total excision	Mature cystic teratomatous components
Case 7	17/M Anterior mediastinal mass	4 cycles of BEP chemotherapy	—	Significant increase	Well defined	Large cystic areas	Increased	+	+	CT-guided biopsy	Mature teratomatous component (squamous epithelium with mucous glands and fibrosis)
Case 8	22/F Right ovary—GCT	2 cycles of EP neoadjuvant chemotherapy, followed by surgery, followed by 2 more cycles of EP chemotherapy	Right subdiaphragmatic lesion seen at presentation New lesion—Pleural-based posterior pleura in the follow-up scans in the presence of normalized tumor markers	Increase in size Increase in size	Well defined	Increased	—	+	+	Surgery awaited	

Abbreviations: BEP, bleomycin, etoposide, and cisplatin; CECT, contrast-enhanced computed tomography; GCT, germ cell tumor; NSGCT, nonseminomatous germ cell tumor.

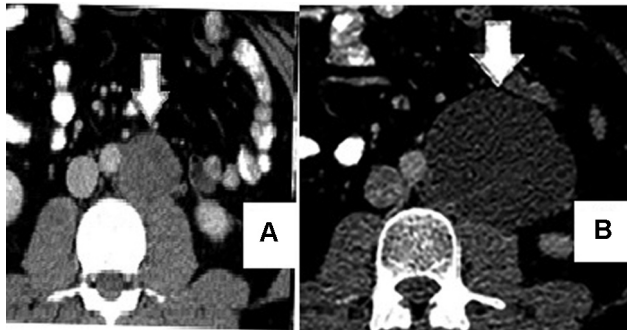


Fig. 1 Prechemotherapy axial contrast-enhanced computed tomography (CECT) scan of mid abdomen (A) showing a left paraaortic nodal mass that is predominantly solid with central necrosis. Postchemotherapy CECT scan (B) at the same level showing significant increase in the size of the left paraaortic mass, currently with a predominant cystic appearance and thin internal septations.

GTS most commonly occurs in residual nodal masses, in the setting of testicular NSGCT.^{6,14} The most common type of metastatic lesions involved are retroperitoneal nodal metastases followed by lung lesions and supraclavicular nodes.^{6,14} A representative figure of classical GTS transformation in retroperitoneal paraaortic node is shown in **Fig. 1**. Five (62.5%) of our eight cases had GTS in retroperitoneal nodal metastases. We also noted that GTS lesions have a varied growth rate with increase in size of the lesions being detected at different timeframes ranging from just after the initiation of chemotherapy, 2 years postchemotherapy and up to a period of 25 years after initial treatment.

Prompt recognition of salient radiological features favoring a diagnosis of GTS by the radiologist plays a crucial role in directing the management of postchemotherapy masses in patients with GCTs, especially in the scenario of an enlarging previously seen mass with normal serum tumor markers. The presence of a well circumscribed margin, curvilinear calcifications increase, or new appearance of fat and cystic components are typically described and are the “radiological equivalents” of mature teratomatous elements seen on histopathology.^{15–17} Salient radiological features are shown in **Figs. 2, 3, and 4**.

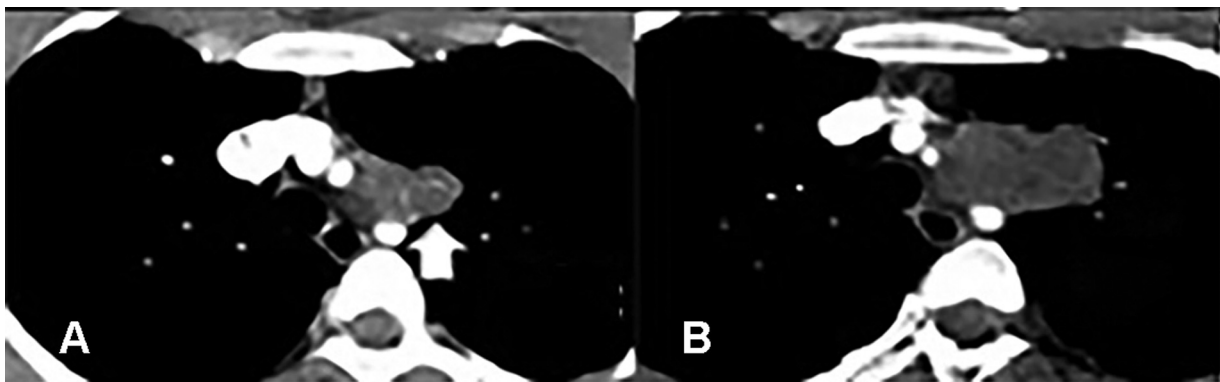


Fig. 2 Prechemotherapy axial contrast-enhanced computed tomography (CECT) image of thorax (A) showing a conglomerate enhancing prevascular mediastinal nodal mass (arrow in A) with prominent vessels supplying it. Postchemotherapy axial CECT images of thorax (B), showing significant increase in size with reduction in the enhancement, more cystic/necrotic areas and decrease in the vascularity as compared with the prechemotherapy scan.

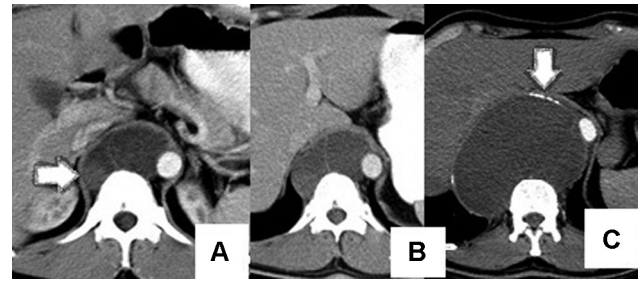


Fig. 3 Contrast-enhanced computed tomography (CECT) at presentation (A) showing a predominantly cystic retrocrural mass with a small eccentric solid component on the right side (arrow); CECT done a year later (B), showing a mild increase in the retrocrural mass and CECT done 24 years postorchidectomy (C), showing significant increase in size of the retrocrural lesion with only cystic component, thin internal septations, and calcification (arrow).

All of our patients showed increase in size and cystic component on imaging in the presence of normalized serum markers, which fulfil all the criteria of GTS and were supported by the presence of only mature teratomatous elements on histology. A representative histology picture from one of our cases is shown in **Fig. 5**.

Another important radiological feature specific to GTS is the absence of infiltration of surrounding structures, despite the large size and significant mass effect as evident in all of our cases where the lesions showed well-defined, rounded margins. The absence of uptake on fluorodeoxyglucose positron emission tomography (if performed) and lack of locoregional infiltration are attributed to the absence of viable tumor cells and may help differentiate GTS from residual viable tumor radiologically.¹⁸

There are other transformations that occur postchemotherapy in GCTs, like carcinomatous or sarcomatous transformations or chemotherapeutic retroconversion (CR) that occur either in a primary GCT or in the metastatic lesions.⁷ The radiological characteristics differentiating these conditions are given in **Table 2**. Increase in the size of the lesions is the most important sign to distinguish a GTS from CR. Serial review of all previous imaging helps distinguish GTS from CR as the tumor masses in GTS grow to large sizes and

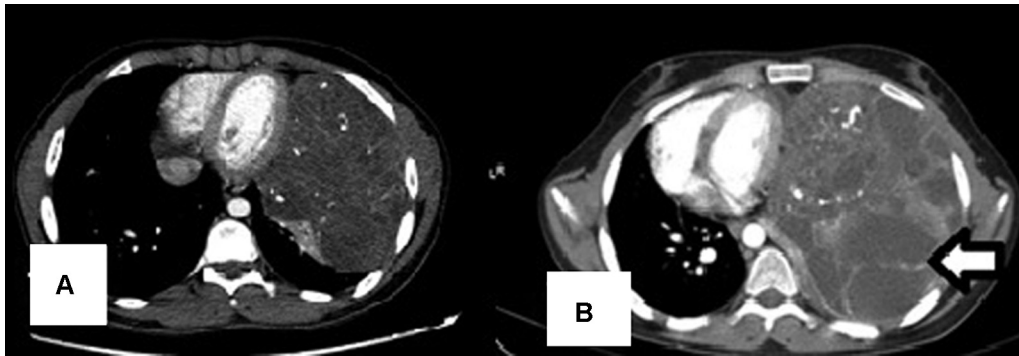


Fig. 4 Prechemotherapy contrast-enhanced computed tomography (CECT) thorax (A) shows a left anterior mediastinal mass with solid and cystic areas and coarse calcifications. Repeat CECT after four cycles of bleomycin, etoposide, and cisplatin chemotherapy (B), demonstrating a significant increase in the size and large cystic areas within and presence of thin internal septations (arrow).

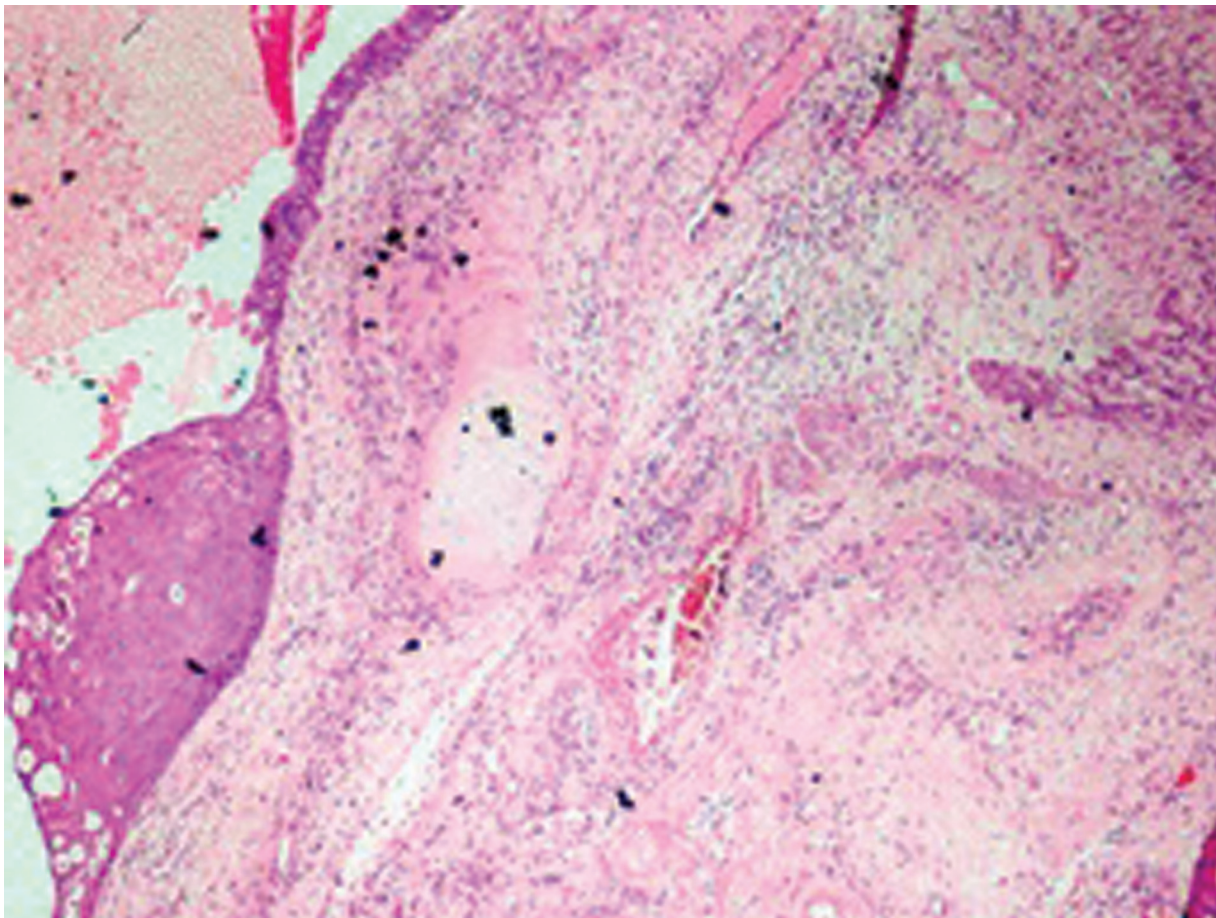


Fig. 5 Mature cystic teratomatous elements hematoxylin and eosin at 40x magnification showing parts of a cyst wall lined partly by squamous epithelium and partly by columnar epithelium. The cyst wall shows mature cartilage, fibrous connective tissue, and muscle fibers.

cause various locoregional complications as described below in contrast to tumor masses in CR that do not show a gross increase in size.¹⁹ Complete surgical resection is the most effective treatment and is associated with high cure rates (~89%).^{5,6,14,20} For partially resected or recurrent tumors, there may be a need for periodic imaging and repeat surgical excision in the event of radiological progression, due to the chemo-resistant nature of the disease and due to the probability of viable tumor being left behind. Despite their non-

malignant nature, these large lesions pose the higher risk of intraoperative complications including cardiopulmonary deterioration.²⁰ In our study, two cases had only partial resection of the metastatic lesions and were kept on follow-up; one case had no surgery and was kept on follow-up for the metastatic lesion. All these residual metastatic lesions developed GTS transformation over a period of time; this reinforces the need for early detection, recognition, and complete surgical resection of all the lesions in GTS.

Table 2 Summary of characteristics to distinguish between GTS, chemotherapeutic retroconversion and malignant transformation

	Growing teratoma syndrome	Chemotherapeutic retroconversion	Malignant transformation (carcinomatous/sarcomatous)
Tumor markers	Normal/decreased	Normal/decreased	Elevated
Size	Gross increase	No/mild increase	Increase
Margins	Well-defined	Well-defined	Ill-defined and infiltration of surrounding structures
Cystic areas	+	+	+/-
Calcification, internal septations, necrotic areas	+/-	+/-	+/-

Medical therapy with interferon has been reported to have some benefit in patients with large lesions with size-related complications and not suitable for surgery.²¹ After surgery for GTS, patients are followed up with serial CT imaging at least once every 6 months for the first year and then yearly for the minimum next 4 years, as late recurrences of GTS have been described and also seen in our case series.¹⁷ Two of our cases showed the development of new lesions with GTS transformation (which were not seen in the initial scans) during/post completion of chemotherapy. Hence, follow-up imaging plays a very crucial role. We acknowledge that our study is limited by its retrospective nature and the small numbers. However, generation of real-world data plays a significant role in guiding treatment decisions in rare entities like GTS.

Patients with NSGCTs from low middle-income countries like ours often present with large retroperitoneal or mediastinal masses that may not be amenable for surgical excision due to their extent and often remain on follow-up.²² There is also a higher rate of treatment abandonment among our patients with testicular cancer when compared with their Western counterparts, which in turn increases the likelihood of GTS transformation of residual masses.²² This reiterates the need for early recognition of GTS among our patients, considering that timely surgery is curative.

Conclusion

GTS is a rare entity characterized by the increase in size of metastatic lesions in patients with NSGCTs on or following chemotherapy, in the presence of normal serum tumor markers. Diagnosis is made on serial radiological imaging and presence of only residual mature teratoma on the excised surgical specimen. Radiological features in favor of GTS are the development of better-defined lesions with development of cystic areas, fat density, and calcifications. Early clinicoradiological diagnosis followed by complete surgical excision improves survival outcomes of these patients and avoids unnecessary and futile escalation to other lines of chemotherapy.

Conflicting Interest

Nil.

References

- Tangjitgamol S, Manusirivithaya S, Leelahakorn S, Thawaramara T, Suekwatana P, Sheanakul C. The growing teratoma syndrome: a case report and a review of the literature. *Int J Gynecol Cancer* 2006;16(Suppl 1):384-390
- Gorbatiy V, Spiess PE, Pisters LL. The growing teratoma syndrome: current review of the literature. *Indian J Urol* 2009;25(02):186-189
- Diong NC, Dharmaraj B, Joseph CT, Sathiamurthy N. Growing teratoma syndrome of mediastinal nonseminomatous germ cell tumor. *Ann Thorac Med* 2020;15(01):38-40
- Logothetis CJ, Samuels ML, Trindade A, Johnson DE. The growing teratoma syndrome. *Cancer* 1982;50(08):1629-1635
- Spiess PE, Kassouf W, Brown GA, et al. Surgical management of growing teratoma syndrome: the M. D. Anderson cancer center experience. *J Urol* 2007;177(04):1330-1334, discussion 1334
- André F, Fizazi K, Culine S, et al. The growing teratoma syndrome: results of therapy and long-term follow-up of 33 patients. *Eur J Cancer* 2000;36(11):1389-1394
- DiSaia PJ, Saltz A, Kagan AR, Morrow CP. Chemotherapeutic retroconversion of immature teratoma of the ovary. *Obstet Gynecol* 1977;49(03):346-350
- Smithers DW. Maturation in human tumours. *Lancet* 1969;2(7627):949-952
- Merrin C, Baumgartner G, Wajzman Z. Letter: Benign transformation of testicular carcinoma by chemotherapy. *Lancet* 1975;1(7897):43-44
- Willis GW, Hajdu SI. Histologically benign teratoid metastasis of testicular embryonal carcinoma: report of five cases. *Am J Clin Pathol* 1973;59(03):338-343
- Cheng L, Albers P, Berney DM, et al. Testicular cancer. *Nat Rev Dis Primers* 2018;4(01):29
- Veneris JT, Mahajan P, Frazier AL. Contemporary management of ovarian germ cell tumors and remaining controversies. *Gynecol Oncol* 2020;158(02):467-475
- Stram AR, Kesler KA. Mediastinal germ cell tumors: updates in diagnosis and management. *Surg Oncol Clin N Am* 2020;29(04):571-579
- Maroto P, Taberero JM, Villavicencio H, et al. Growing teratoma syndrome: experience of a single institution. *Eur Urol* 1997;32(03):305-309
- Lee DJ, Djaladat H, Tadros NN, et al. Growing teratoma syndrome: clinical and radiographic characteristics. *Int J Urol* 2014;21(09):905-908
- Han NY, Sung DJ, Park BJ, et al. Imaging features of growing teratoma syndrome following a malignant ovarian germ cell tumor. *J Comput Assist Tomogr* 2014;38(04):551-557
- Saso S, Galazis N, Iacovou C, et al. Managing growing teratoma syndrome: new insights and clinical applications. *Future Sci OA* 2019;5(09):FSO419

- 18 Aide N, Comoz F, Sevin E. Enlarging residual mass after treatment of a nonseminomatous germ cell tumor: growing teratoma syndrome or cancer recurrence? *J Clin Oncol* 2007;25(28):4494–4496
- 19 Djordjevic B, Euscher ED, Malpica A. Growing teratoma syndrome of the ovary: review of literature and first report of a carcinoid tumor arising in a growing teratoma of the ovary. *Am J Surg Pathol* 2007;31(12):1913–1918
- 20 Kesler KA, Patel JB, Kruter LE, et al. The “growing teratoma syndrome” in primary mediastinal nonseminomatous germ cell tumors: criteria based on current practice. *J Thorac Cardiovasc Surg* 2012;144(02):438–443
- 21 Kattan J, Droz JP, Culine S, Duvillard P, Thiellet A, Peillon C. The growing teratoma syndrome: a woman with nonseminomatous germ cell tumor of the ovary. *Gynecol Oncol* 1993;49(03):395–399
- 22 Saju SV, Radhakrishnan V, Ganesan TS, et al. Factors that impact the outcomes in testicular germ cell tumors in low-middle-income countries. *Med Oncol* 2019;36(03):28