



# MRI Findings in Case of Post-COVID-19 Vaccination Rhabdomyolysis: A Rare Postvaccination Adverse Effect

Tushar M. Kalekar<sup>1</sup> Radhika K. Jaipuria<sup>1</sup> Rahul Srichand Navani<sup>1</sup>

<sup>1</sup>Department of Radiodiagnosis, Dr. D Y Patil Medical College, Pimpri, Pune, Maharashtra, India

Address for correspondence Rahul Navani, MBBS, Resident, Department of Radiodiagnosis, Dr. D Y Patil Medical College, Pimpri, Pune 411018, Maharashtra, India (e-mail: drsrnradio@gmail.com).

Indian J Radiol Imaging 2022;32:256–259.

## Abstract

### Keywords

- ▶ postvaccination rhabdomyolysis
- ▶ post-COVID-19 vaccination
- ▶ post-COVID-19 vaccination adverse effects
- ▶ post-COVID-19 vaccination rhabdomyolysis

In the era of this pandemic, without any proper and efficacious availability of antiviral agents against the novel coronavirus disease 2019 (COVID-19), vaccines have come as a hope for humankind. Although adverse reactions are common after getting the COVID-19 vaccine, serious or life-threatening side effects are very uncommon in these new emergency-approved vaccines. In this case report, we describe an unusual case of adverse reaction in a patient who received the COVID-19 vaccination. The patient who received the COVID-19 vaccination presented with progressive right lower limb pain and swelling, which further progressed to bilateral shoulder pain and swelling. Ultrasonography, Doppler, and magnetic resonance imaging of right lower limb were done for the patient.

## Key Messages

In this era of COVID-19 pandemic with arrival of vaccines, in patients with complaints of progressive muscular pain post-vaccination, MRI should be done for ruling out any untoward adverse event like myositis and prompt treatment should be started on diagnosis, to prevent further morbidity.

## Introduction

We are currently in the state of an ongoing pandemic, the first of the twenty-first century, affecting almost 223 countries worldwide till now.<sup>1</sup> Almost a decade after the last pandemic of H1N1 Swine flu, this pandemic of novel coronavirus disease 2019 (COVID-19) is caused by severe acute respiratory syndrome coronavirus-2 (SARS-CoV-2). The disease has caused serious mortality globally.<sup>2</sup>

Currently, no specifically targeted and efficacious antiviral agents are available to combat the SARS-CoV-2. However, two restricted emergency-approved vaccines for use by the Subject Expert Committee of Central Drugs Standard Control Organization of the Drugs Controller General of India, which are available in India as of February 2021, are:

1. Recombinant Chimpanzee Adenovirus vector vaccine encoding the SARS-CoV-2 Spike (S) glycoprotein.
2. Whole Virion Inactivated Corona Virus Vaccine.<sup>3</sup>

The vaccines have brought great hope in these adverse times. The side-effect profile of Recombinant Chimpanzee Adenovirus vector vaccine encoding the SARS-CoV-2 Spike (S) glycoprotein declared by the manufacturers as per clinical trials ranges from injection site tenderness, pain, warmth, erythema, pruritus, swelling, bruising, fatigue, malaise, pyrexia, and chills to rare but serious side effects like neuroinflammatory disorders.<sup>4,5</sup>

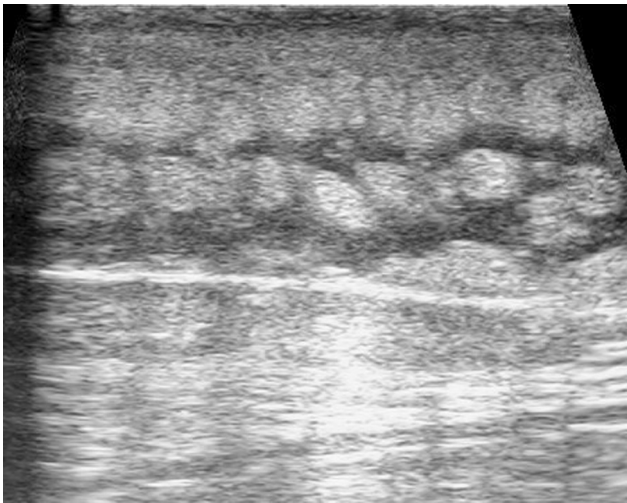
published online  
July 13, 2022

DOI <https://doi.org/10.1055/s-0042-1748534>.  
ISSN 0971-3026.

© 2022. Indian Radiological Association. All rights reserved.

This is an open access article published by Thieme under the terms of the Creative Commons Attribution-NonDerivative-NonCommercial-License, permitting copying and reproduction so long as the original work is given appropriate credit. Contents may not be used for commercial purposes, or adapted, remixed, transformed or built upon. (<https://creativecommons.org/licenses/by-nc-nd/4.0/>)

Thieme Medical and Scientific Publishers Pvt. Ltd., A-12, 2nd Floor, Sector 2, Noida-201301 UP, India

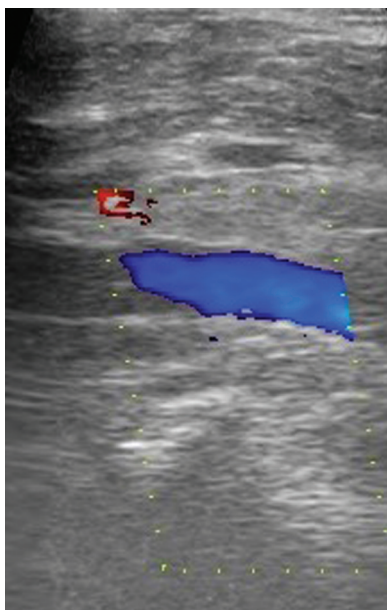

**Fig. 1** Gray scale ultrasonography image in longitudinal section of lower limb at the level of right calf shows extensive subcutaneous edema with hyperechoic muscle.

We describe here a unique case of not previously known/documentated (as per the knowledge of authors) post-vaccination rhabdomyolysis with its ultrasonography (USG), Doppler, and magnetic resonance imaging (MRI) findings.

### Case History

In this case report, we are describing a case of a 31-year-old female, health care worker, who took the COVID-19 vaccine (Recombinant Chimpanzee Adenovirus vector vaccine encoding the SARS-CoV-2 Spike [S] glycoprotein). She developed right lower limb progressive swelling and pain on day 10 and it progressed to bilateral shoulders on day 11. Laboratory investigations, USG with Doppler, and MRI of the right lower limb were done. She did not have any symptoms



**Fig. 2** Color Doppler image at the level of proximal calf on right side showed normal color flow in popliteal vein.

of SARS-CoV-2 at that time. Nor did the patient have any previous history of COVID-19, or any close contact with a known patient. She was referred for MRI on day 11 of the post-COVID-19 vaccine jab. There was also no similar history in the past. No significant comorbidities were associated with the patient. There was no incident of trauma. The patient had a sedentary lifestyle and had no history of any alcohol intake, medications, or any metabolic disorders.

Laboratory reports showed serum lactate dehydrogenase = 350 units/L (raised), serum creatinine phosphokinase (CPK) = 15,000 (significantly raised), while serum creatinine and erythrocyte sedimentation rate values were within normal limits.

USG right lower limb Doppler done on day 10 of symptoms, in view of suspicion of deep venous thrombosis, showed no evidence of any superficial or deep vein thrombosis. It showed increased echogenicity in visualized calf muscles with extensive subcutaneous edema. Also, the serum electrolytes were within normal limits.

Since the incidence of myositis and rhabdomyolysis has been reported in COVID-19 disease, mostly in its severe manifestation,<sup>6,7</sup> reverse transcriptase-polymerase chain reaction test was done for the same, which turned out to be negative.

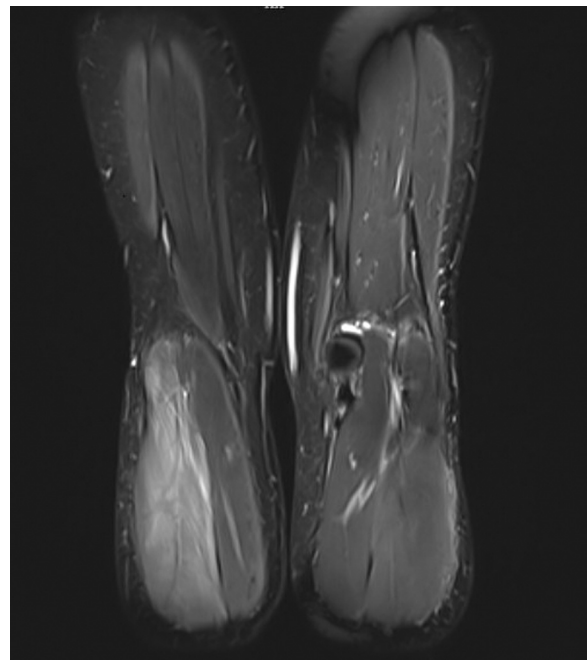
USG and Doppler were done for right lower limb, which revealed following findings (→ **Figs. 1** and **2**):

MRI right lower limb was done in view of further progression of symptoms on day 11.

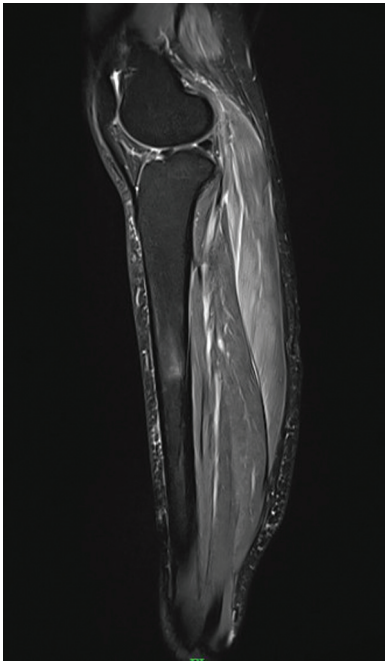
### MRI Findings

Machine used: Siemens Magnetom VIDA 3 Tesla.

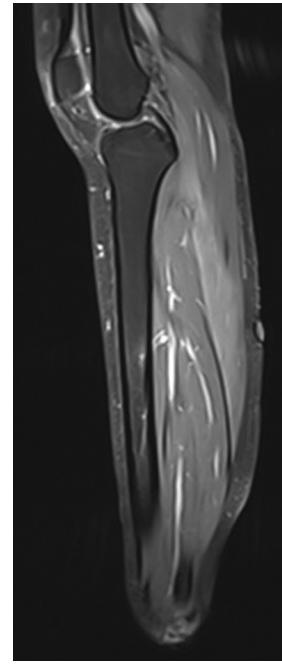
MRI findings (→ **Figs. 3–7**) in right lower limb showed mildly bulky and edematous lateral head of right-sided



**Fig. 3** Short tau inversion recovery coronal section shows a hyperintense signal in the lateral head of right gastrocnemius muscle, with muscle appearing mildly bulky.



**Fig. 4** T2 Weighted Fat Sat sagittal image showing hyperintense signal along the lateral head of right gastrocnemius muscle, as compared to surrounding muscles.



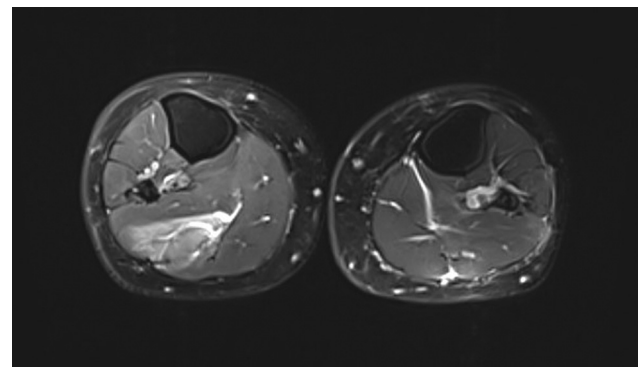
**Fig. 5** Post Contrast T1 weighted Fat Sat sagittal image showing heterogeneous post contrast enhancement in lateral head of right gastrocnemius muscle as compared to surrounding muscles.

gastrocnemius muscle, which was appearing T2 hyperintense, without any fat suppression, and showing mild contrast enhancement. It was associated with subcutaneous edema, seen as a T2WI hyperintense signal in the subcutaneous plane along the lateral aspect of the right lower limb. Imaging of the shoulder or any other body part was not done.

## Discussion

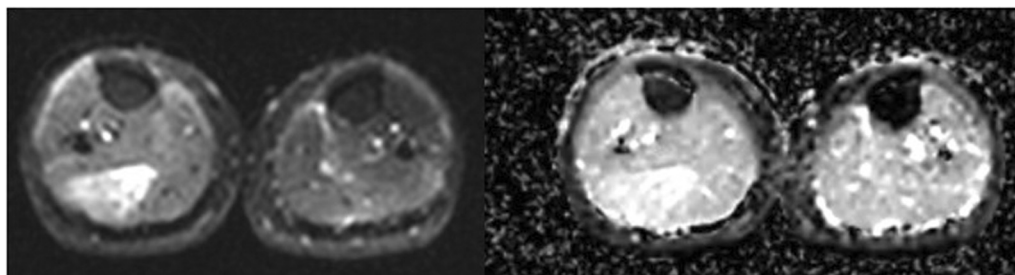
Rhabdomyolysis is primarily an outcome of acute muscle injury, with sarcolemmal injury at microscopic levels causing resultant release of potentially toxic substances including electrolytes, myoglobin, and enzymes such as CPK into circulation, responsible for its life-threatening nature. Clinical presentation of rhabdomyolysis is primarily significant myalgia, fatigue, and may potentially cause kidney injury.<sup>8</sup> It is diagnosed on the basis of clinical parameters, laboratory correlation, and radiological imaging—of which MRI being most sensitive in imaging.<sup>9</sup>

MRI findings of rhabdomyolysis may range from initial changes of edema to the later stages of myonecrosis and



**Fig. 6** T2 Weighted Fat Sat axial section shows the hyperintense signal in the right lateral head of the gastrocnemius. There is associated subcutaneous edema along the lateral aspect on the right side, shown by T2-weighted imaging hyperintense signal in the subcutaneous plane.

liquefaction, according to the severity. Some cases may also show hyperintensities in T1-weighted images due to the hemorrhage or protein content. Contrast study in these cases is not usually done due to associated renal failure.



**Fig. 7** Diffusion-weighted/apparent diffusion coefficient images at the same level show T2 shine through.

Postcontrast images may show enhancement in the edematous region with areas of nonenhancement in the areas of myonecrosis. In our case, abnormal signal changes in T2WI and STIR sequences suggested changes in rhabdomyolysis, along with clinical and laboratory findings.<sup>10,11</sup>

It is attributed to various causes such as various drugs, infectious, inflammatory, and metabolic causes, rigorous muscle exercises, direct muscular injuries, various ischemic etiologies, heatstroke, previous inflammatory myopathies, or various hereditary enzyme defects. Vaccines are known to have been causing inflammatory myopathies as well as rhabdomyolysis.<sup>12</sup>

Rhabdomyolysis is known to be seen in rare cases of postvaccination of H1N1 influenza and recombinant zoster vaccines.<sup>13–15</sup>

However, no previous evidence of any postvaccination rhabdomyolysis is documented to be associated with the use of Recombinant Chimpanzee Adenovirus vector vaccine as per the knowledge of authors or in clinical trials of the vaccine as per drug manufacturer's Web site.

## Conclusion

From our findings, the likely cause of rhabdomyolysis is due to post-Recombinant Chimpanzee Adenovirus vector vaccine rhabdomyolysis.

Based on clinical, laboratory, and MRI findings,<sup>16</sup> the patient was treated with intravascular fluids and steroids (prednisolone) in view of rhabdomyolysis and was relieved. As the patient was relieved with early therapeutic intervention, no histopathological confirmation was done.

### Conflicting Interest

None declared.

## References

- 1 WHO. WHO novel coronavirus 2019 dashboard. 2019 <https://www.who.int/emergencies/diseases/novel-coronavirus-2019>. Accessed January 23, 2022
- 2 Katal S, Pouraryan A, Gholamrezanezhad A. COVID-19 vaccine is here: practical considerations for clinical imaging applications. *Clin Imaging* 2021;76:38–41
- 3 Press Information Bureau, Government of India. Press statement by the Drugs Controller General of India (DCGI) on restricted emergency approval of COVID-19 virus vaccine. 2021 <https://pib.gov.in/PressReleasePage.aspx?PRID=1685761>. Accessed January 23, 2022
- 4 Serum Institute of India. Side effect profile of recombinant chimpanzee adenovirus vector vaccine. 2021 [https://www.seruminstitute.com/pdf/Recombinant\\_Chimpanzee\\_Adenovirus\\_vector\\_vaccine\\_ChAdOx1\\_nCoV19\\_corona\\_virus\\_vaccine\\_insert.pdf](https://www.seruminstitute.com/pdf/Recombinant_Chimpanzee_Adenovirus_vector_vaccine_ChAdOx1_nCoV19_corona_virus_vaccine_insert.pdf) Accessed January 23, 2022; Or Voysey M, Clemens SAC, Madhi SA, et al; Oxford COVID Vaccine Trial Group. Safety and efficacy of the ChAdOx1 nCoV-19 vaccine (AZD1222) against SARS-CoV-2: an interim analysis of four randomised controlled trials in Brazil, South Africa, and the UK. *Lancet* 2021;397(10269):99–111.
- 5 Ramasamy MN, Minassian AM, Ewer KJ, et al; Oxford COVID Vaccine Trial Group. Safety and immunogenicity of ChAdOx1 nCoV-19 vaccine administered in a prime-boost regimen in young and old adults (COV002): a single-blind, randomised, controlled, phase 2/3 trial. *Lancet* 2021;396(10267):1979–1993
- 6 Zhang Q, Shan KS, Minalyan A, O'Sullivan C, Nace T. A rare presentation of Coronavirus Disease 2019 (COVID-19) induced viral myositis with subsequent rhabdomyolysis. *Cureus* 2020;12(05):e8074
- 7 Paliwal VK, Garg RK, Gupta A, Tejan N. Neuromuscular presentations in patients with COVID-19. *Neurol Sci* 2020;41(11):3039–3056
- 8 Knochel JP. Mechanisms of rhabdomyolysis. *Curr Opin Rheumatol* 1993;5(06):725–731
- 9 Lamminen AE, Hekali PE, Tiula E, Suramo I, Korhola OA. Acute rhabdomyolysis: evaluation with magnetic resonance imaging compared with computed tomography and ultrasonography. *Br J Radiol* 1989;62(736):326–330
- 10 Smitaman E, Flores DV, Mejía Gómez C, Pathria MN. MR imaging of atraumatic muscle disorders. *Radiographics* 2018;38(02):500–522
- 11 May DA, Disler DG, Jones EA, Balkissoon AA, Manaster BJ. Abnormal signal intensity in skeletal muscle at MR imaging: patterns, pearls, and pitfalls. *Radiographics* 2000;20(Spec No):S295–S315
- 12 Orbach H, Tanay A. Vaccines as a trigger for myopathies. *Lupus* 2009;18(13):1213–1216
- 13 Raman KS, Chandrasekar T, Reeve RS, Roberts ME, Kalra PA. Influenza vaccine-induced rhabdomyolysis leading to acute renal transplant dysfunction. *Nephrol Dial Transplant* 2006;21(02):530–531
- 14 Callado RB, Carneiro TG, Parahyba CC, Lima NdeA, da Silva Junior GB, Daher EdeF. Rhabdomyolysis secondary to influenza A H1N1 vaccine resulting in acute kidney injury. *Travel Med Infect Dis* 2013;11(02):130–133
- 15 Rajaratnam N, Govil S, Patel R, Ahmed M, Elias S. Rhabdomyolysis after recombinant zoster vaccination: a rare adverse reaction. *J Community Hosp Intern Med Perspect* 2021;11(01):145–146
- 16 Moratalla MB, Braun P, Fornas GM. Importance of MRI in the diagnosis and treatment of rhabdomyolysis. *Eur J Radiol* 2008;65(02):311–315