




Rehabilitation in Triangular Fibrocartilage Complex Injuries: Treatment Algorithm

Rehabilitación en las lesiones del complejo fibrocartilago triangular: Algoritmo de tratamientos

Eva Guisasola Lerma¹  Francisco Javier Lucas Garcia² Alberto Márquez Caraballo³
David Santosjuanes Royo³

¹ Hand and Upper Limb Surgery Unit, Hospital QuirónSalud Valencia, Valencia, Spain

² Hospital QuirónSalud Valencia, Valencia, Spain

³ Hospital QuirónSalud Valencia, Valencia, Spain

Address for correspondence Dra. Eva Guisasola Lerma, Unidad de Cirugía de la Mano y Miembro Superior, Hospital QuirónSalud Valencia, Valencia, España (e-mail: evaguisa@yahoo.es).

Rev Iberam Cir Mano 2022;50(1):e49–e59.

Abstract

Keywords

- ▶ distal radioulnar instability
- ▶ neuromuscular control
- ▶ dynamic stabilizers
- ▶ exercise program
- ▶ orthosis

Injuries to the triangular fibrocartilage complex (TFCC) can lead to instability of the distal radioulnar joint (DRUJ). In fact, they are the most frequent cause of it. But, in other cases, depending on the type of injury, the DRUJ remains stable. This will condition different types of treatments, from conservative management to the different options of surgical treatment. Since a controversy persists regarding the management of these lesions, our purpose is to disclose the foundations of the rehabilitation treatment and propose an algorithm of treatment according to the different types of injuries and their repairs.

Resumen

Palabras Clave

- ▶ inestabilidad radiocubital distal
- ▶ control neuromuscular
- ▶ estabilizadores dinámicos
- ▶ programa de ejercicios
- ▶ ortesis

Las lesiones del complejo del fibrocartilago triangular (CFCT) pueden provocar una inestabilidad de la articulación radiocubital distal (ARCD). De hecho, son la causa más frecuente de ésta. Pero, en otras ocasiones, según el tipo de lesión, la ARCD se mantiene estable. Esto va a condicionar distintos tipos de tratamientos, desde el conservador hasta distintas opciones de intervenciones quirúrgicas. Dado que persiste la controversia en cuanto al manejo de estas lesiones, nuestro propósito es exponer las bases del tratamiento rehabilitador y proponer un algoritmo de tratamiento según los distintos tipos de lesiones y sus reparaciones.

received
March 12, 2022
accepted
March 22, 2022

DOI <https://doi.org/10.1055/s-0042-1748854>.
ISSN 1698-8396.

© 2022. SECMA Foundation. All rights reserved.

This is an open access article published by Thieme under the terms of the Creative Commons Attribution-NonDerivative-NonCommercial-License, permitting copying and reproduction so long as the original work is given appropriate credit. Contents may not be used for commercial purposes, or adapted, remixed, transformed or built upon. (<https://creativecommons.org/licenses/by-nc-nd/4.0/>)

Thieme Revinter Publicações Ltda., Rua do Matoso 170, Rio de Janeiro, RJ, CEP 20270-135, Brazil

Introduction

Triangular fibrocartilage complex (TFCC) injuries are a common cause of disability and pain in the ulnar edge of the wrist.

The extensive biomechanical knowledge currently available has enabled hand surgeons to develop several surgical procedures, **from debridement with no repair to arthroscopy-assisted reconstruction plasties**.^{1,2} It has also enabled the development of various exercise programs to treat general instabilities at the distal radioulnar joint (DRUJ). However, there is no consensus whether the best treatment for TFCC lesions with a stable DRUJ is conservative or surgical.³ The present paper summarizes the most recent anatomical, biomechanical, and pathophysiological studies. Based on this information, we propose rehabilitation treatments depending on DRUJ stability, as well as the postoperative management according to the surgical technique.

Anatomy and Biomechanics

Stability of the DRUJ relies on bone congruence, the integrity of the ligaments, proper functioning of the adjacent muscles, good muscle tone, and adequate proprioceptive control.⁴

1. The chief intrinsic stabilizer for the DRUJ is the TFCC, which consists of (► Fig. 1):

- 1.1 The avascular *joint disc* formed by collagen fibers.
- 1.2 The *homologous meniscus*, which is a highly-vascularized synovial tissue that corresponds to the inner wall of the joint capsule and transmits loads from the carpus to the distal ulnar pole.
- 1.3 The *dorsal and volar radioulnar ligaments, with their deep and superficial portions*. These vascularized structures account for the sliding of the radiocarpal joint at the ulnar surface. The deep ligaments attach to the ulnar fovea, and the superficial ligaments attach to the ulnar styloid. The deep ligaments form an obtuse angle

from the fovea to the medial surface of the radius, providing better radioulnar stability during the pronosupination movement. **Therefore, they are responsible for DRUJ stability.** However, the superficial radioulnar ligaments form an acute angle with the radial surface and play a much less important role in stability.⁵

1.4 The *floor of the extensor carpi ulnaris (ECU) sheath*, which is a thickening of the ulnocarpal capsule expanding towards the ulnar fovea. It stabilizes the radius at the ulna during pronosupination.⁶

1.5 The *ulnocarpal (ulnotriquetral and ulnolunate) ligaments attached to the fovea*. As such, their injury results in DRUJ instability. These ligaments support the ulnar margin of the carpus like a hammock.

1.6 The *ulnocarpal capsule*, which plays an important role at a mechanical level (**in maximum supination and pronation**) and a proprioceptive level (due to the **number of mechanoreceptors**). It does not play a relevant role in DRUJ stabilization in neutral rotation.⁷

2. The **bony portion of the joint** consists of the ulnar head and the sigmoid cavity of the radius. Its range of anteroposterior translation in pronosupination is of 5.5 mm. **The rotational axis of the forearm passes through the radial head at the level of the elbow and through the ulnar fovea at the level of the wrist.** The congruence between the radius and the ulna is greater in neutral rotation (60%) and lower in extreme pronosupination (10%). Thus, the joint compression forces are maximum with an axial load and the arm in neutral rotation. However, a decrease in the articular contact surface (**as in maximum supination and pronation**) **minimizes the compressive forces and increases shear forces, resulting in subluxation.** Here, DRUJ static and dynamic stabilizers are put to the test. Maximal supination stresses the deep fibers of the dorsal radioulnar ligament, the volar capsule, and the pronator quadratus (PQ) muscle. On the

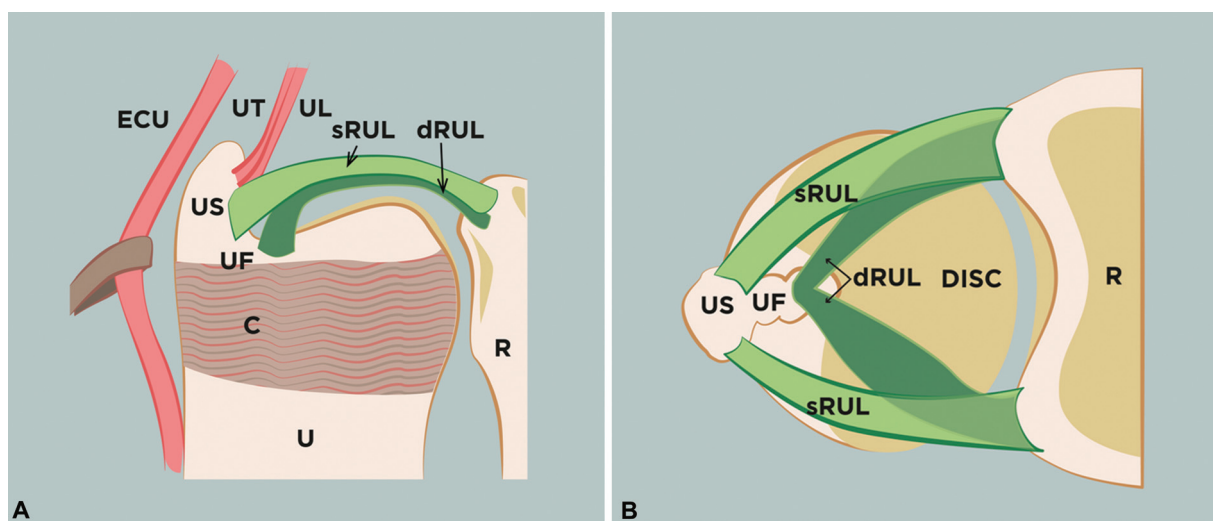


Fig. 1 Wrist with DRUJ stabilizers. (A) Coronal plane. (B) Axial plane. The deep radioulnar ligaments attach to the fovea, whereas the superficial radioulnar ligaments attach to the ulnar styloid. Abbreviations: dRUL, deep radioulnar ligaments; sRUL, superficial radioulnar ligaments; US, ulnar styloid; UF, ulnar fovea; C, capsule; ECU, extensor carpi ulnaris; UT, ulnotriquetral ligament; UL, ulnolunate ligament; U, ulna; R, radius.

other hand, maximum pronation stresses the deep fibers of the volar distal radioulnar ligaments, the dorsal capsule, and the ECU muscle.⁸

3. **Distal oblique band of the interosseous membrane:** located between the ulna and the radius, it consists of collagen and elastin fibers and has an approximate extension of 10 cm. At the distal level, its oblique band, only present in 40% of the population, controls DRUJ stability because **it tightens more during forearm supination**.⁹ In addition, it is **richly innervated by mechanoreceptors**, playing a role in the neuromuscular control of DRUJ stability. Its injury can cause instability, and its fibrosis potentially results in DRUJ stiffness. Several muscles attach along the entire interosseous membrane, requiring special consideration, such as the flexor digitorum profundus, flexor digitorum superficialis (FDS), flexor pollicis longus, extensor pollicis longus, extensor pollicis brevis (EPB), abductor pollicis longus (APL), and extensor indicis.
4. **The ECU muscle** and its sheath play a pivotal role in anteroposterior stability of the DRUJ in supination and neutral rotation, especially because it is more located more dorsally over the ulnar head in the supine position.¹⁰

The PQ muscle is a deep muscle on the anterior aspect of the distal forearm. It has a superficial and a deep band. The anterior interosseous nerve supplies the PQ muscle, which contributes to stability in two ways: **the oblique**

fiber orientation of the deep band provides stability in supination, and its attachment to the capsule favors capsular tension during its contraction.¹¹

5. **Other agonist and antagonist muscles providing DRUJ stability:** Some agonist muscles dynamically stabilize the DRUJ by generating forces that increase joint compression. These include the **brachialis (B)**, **abductor pollicis longus (APL)**, PQ, and ECU muscles. On the other hand, some antagonist muscles also provide dynamic DRUJ stability because their contraction decreases stress. These include the **brachioradialis (BR)** and the **triceps (T)** muscles.¹² The posterior interosseous nerve, in addition to the articular branches and the dorsal sensorial branch of the ulnar nerve, supply the TFCC. The dorsal and volar radioulnar ligaments, the capsule, and the ulnotriquetral ligament have many mechanoreceptors. This fact explains the importance of proprioception in the treatment of these injuries.

Potential Surgical Treatment for TFCC Injuries

A successful clinical outcome requires the detection of DRUJ instability accompanying a TFCC injury (→ Fig. 2).

1. **Acute TFCC injuries with no DRUJ instability** require immobilization for four to six weeks with an orthosis

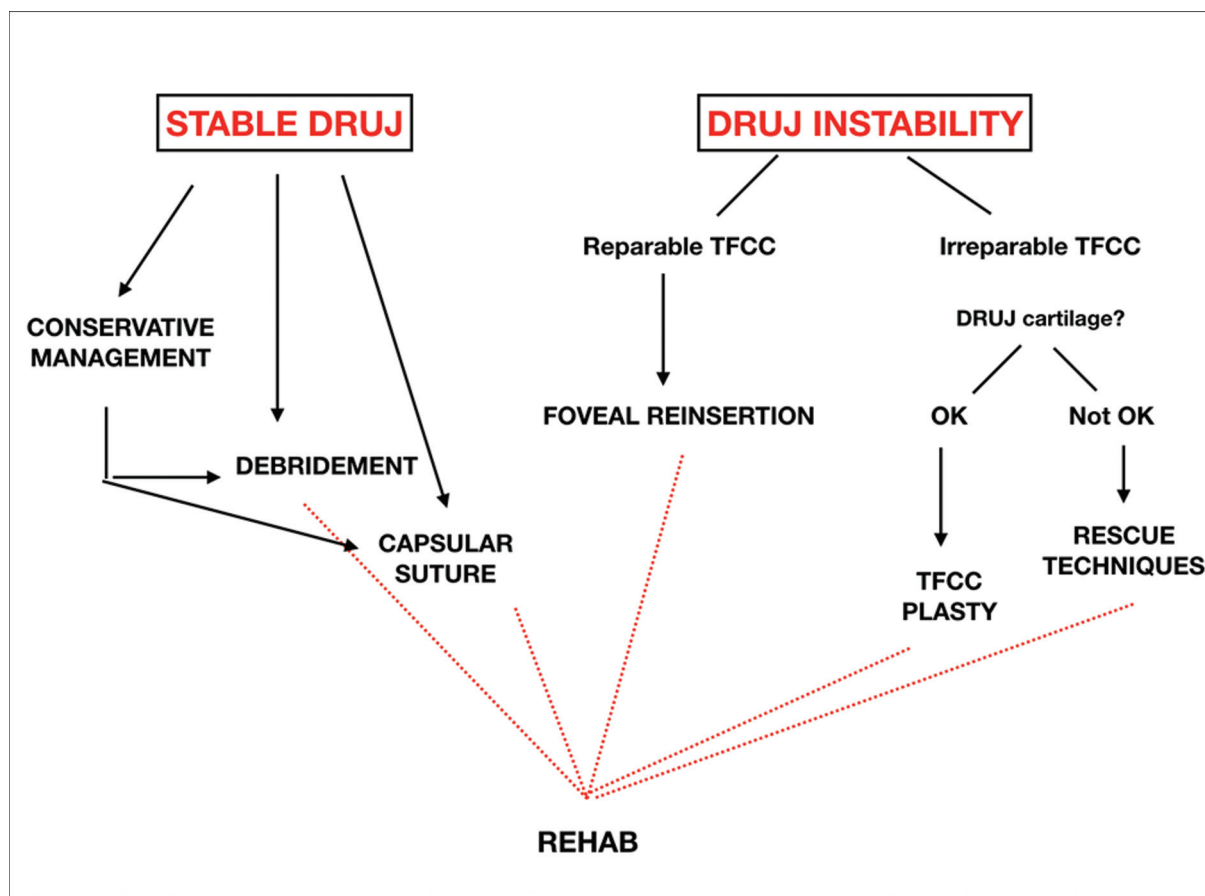


Fig. 2 Treatment algorithm for stable and unstable DRUJ injuries.

blocking pronosupination, followed by conservative management with a specific rehabilitation program.¹³ In patients with no pain relief or function improvement after three months of treatment, surgery may be an option. However, some authors opt directly for surgery, using two techniques:

1.1 Debridement with no repair: Debridement can occur in the avascular zone of the disc. It can also treat injuries with a dorsal distal capsule or distal meniscoid detachment.¹⁴ After surgery, we recommend one or two weeks of immobilization with a forearm splint in a neutral pronosupination position to reduce pain and edema.

1.2 Capsular suture: This procedure treats injuries at the superficial radioulnar ligaments with no DRUJ instability. A motorized unit causes bleeding, followed by an articular capsule suture. The patient is immobilized for three to four weeks with a brachial cast or Münster-type orthosis to block pronosupination with the forearm in a neutral position and the wrist in slight ulnar deviation. Next, the patient uses a forearm cast for two weeks, keeping the elbow free.

2. In injuries with DRUJ instability:

2.1 Foveal reattachment is performed in cases of repairable injuries that affect the proximal insertion.¹⁵ Since distal radioulnar ligaments that lost their attachment to the fovea do not retract or degenerate, their reattachment can be successful if performed within three months. The immobilization can be the same as the one performed in capsular sutures (at the surgeon's discretion), using a Münster-type orthosis with pronosupination block or a brachial splint with the elbow flexed at 90° and the forearm in neutral rotation for 3 to 4 weeks. Next, the patient uses an antebrachial splint for another two weeks. Then, we recommend a removable nighttime orthosis for two more weeks.

2.2 Arthroscopic ligamentoplasty treats symptomatic DRUJ instabilities with good articular cartilage and non-repairable TFCC in which reattachment is not feasible,² or when previous repairs have failed. This technique reconstructs the distal radioulnar (volar and dorsal) ligaments with a free graft of the palmaris longus or flexor carpi radialis. Postoperative immobilization is shorter, using a brachial splint or Münster-type orthosis for two weeks. Next, we recommend a removable nighttime orthosis for four more weeks.

Rehabilitation

The rehabilitation of these injuries begins with immobilization. Each stage has clear goals. (→ Fig. 3).

1. Orthotics and rehabilitation exercises during immobilization
Immobilize the patient as soon as possible after the injury. In stable injuries, use a forearm splint or ulnar canal

orthosis with the elbow free for two weeks. Although these immobilization methods do not block pronosupination, they provide some resistance to rotation. In surgical cases, immobilization varies according to the repair, as aforementioned. **The patient's elbow must be at 90° of flexion, with the forearm in neutral rotation and the wrist in slight ulnar deviation**¹⁶ (→ Fig. 4). This orthosis must prevent pronosupination and stress on the capsule and radioulnar ligaments. After an average of three weeks, it is changed to another orthosis with a free elbow for 1 to 2 weeks. However, in ligamentoplasties, the orthosis is only maintained for two weeks, and then it may be replaced by a removable device.

Inform all patients about wrist anatomy, TFCC function, the type of injury they have sustained, and the repair performed. This information will help them understand the exercises and increase treatment adherence, improving functional outcomes.

The main goals during this stage include inflammation and pain control per the rest, ice, compression, and elevation (RICE) protocol. In addition, this type of immobilization enables **isometric exercises for the PQ and ECU muscles and concentric work of the elbow (T, B, BR) and thumb (APL and EPB) muscles**. Cross-education programs provide early proprioceptive work during immobilization.¹⁷

2. Exercise program

After removal of the immobilization, the exercise program consists of three recovery stages with clear objectives. The implementation of each stage depends on whether and how the TFCC was repaired:

First stage (after removal of the immobilization): pain and edema control and mobility recovery without putting the repair at risk. We must control edema and pain to ensure the effectiveness of our exercise program. For sutures or foveal reattachments, we pay attention to the pain at the suture site; for ligamentoplasties, we consider the stress over the donor area on the volar antebrachial aspect. Transcutaneous electrical nerve stimulation (TENS) analgesic electrotherapy, cryotherapy, or muscle-aponeurotic massage can assist in this stage.

The ranges of motion (ROMs) of the wrist must recover little by little, to avoid generating stress in repaired tissues. Active and assisted mobilizations in flexion-extension and pronosupination must pay special attention to the control and quality of the movement.¹⁸ Active exercises for fingers, elbows, shoulders, and the cervical spine supplement this stage.

First stage of **proprioceptive reeducation exercises to promote conscious joint control:** through **mirror therapy (MT)**, it is believed that the visual stimulation of the uninjured arm promotes tissue reorganization, reducing pain and improving the cortical representation of the injured wrist. **Tactile and vibratory stimulation** help in pain control and prevent neuroplasticity changes.¹⁹ **Joint**

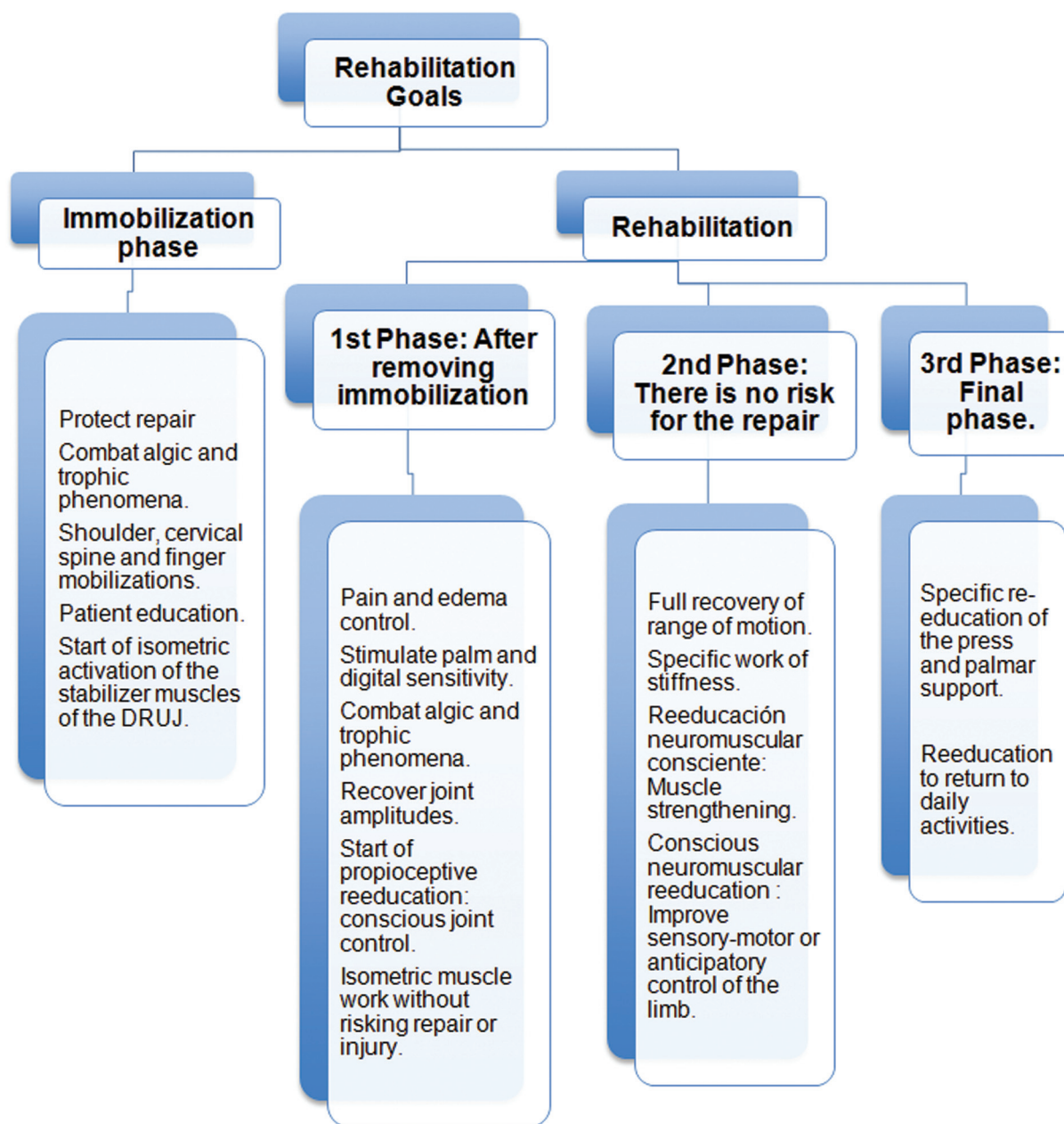


Fig. 3 Goals of each stage of the functional recovery of TFCC complex injuries, ranging from the immobilization period to the resumption of normal activities.

position sense (JPS) refers to the ability to accurately reproduce a given wrist position. First, the physical therapist places the wrist in a given degree of pronation, supination, or flexion-extension. Next, the physical therapist puts the wrist in any other position and asks the patient to reproduce the first position. All of these maneuvers occur while the patient has their eyes closed. Finally, **closed kinetic chain active ROM exercises** help the performance of controlled movements with no tissue

stress or pain. Such exercises may include rolling a ball over a table or wheel-assisted interventions (►Fig. 5).

At the end of this stage, sustaining proper pain control, we can add **isometric contraction exercises for chief DRUJ stabilizing muscles**. In these exercises, muscular contractions correspond to the resistance applied with no joint movement. They include **PQ isometric exercises** either with a flexed or extended elbow. The PQ fibers, especially

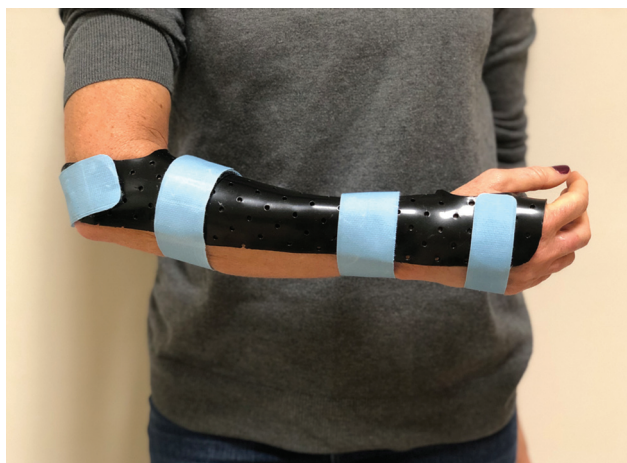

Fig. 4 Münster-type orthosis to block pronosupination. The arm is at 90° of flexion, and the forearm is in a neutral rotation.

the deeper ones, cause significant DRUJ coaptation.²⁰ This muscle is exercised with the arm in supination. **Isometric exercises for the ECU muscle:** when relaxed, this muscle has the shape of a wide S. Its contraction results in DRUJ coaptation. This effect is more pronounced in supination due to its dorsal location. However, if exercised in supination, the ECU is more stressed and can be overloaded. Therefore, we believe that exercising it in pronation is better. **Isometric exercises for the elbow muscles (B, BR, and T):** although they are distant from the wrist, these muscles account for the dynamic stabilization of the DRUJ. **Isometric exercises for the thumb muscles (APL and flexor pollicis brevis [FPB]):** these muscles originate near the interosseous membrane, and they have many mechanoreceptors.

During this period, the patient can use a removable nighttime orthosis to avoid harmful positions during sleep.

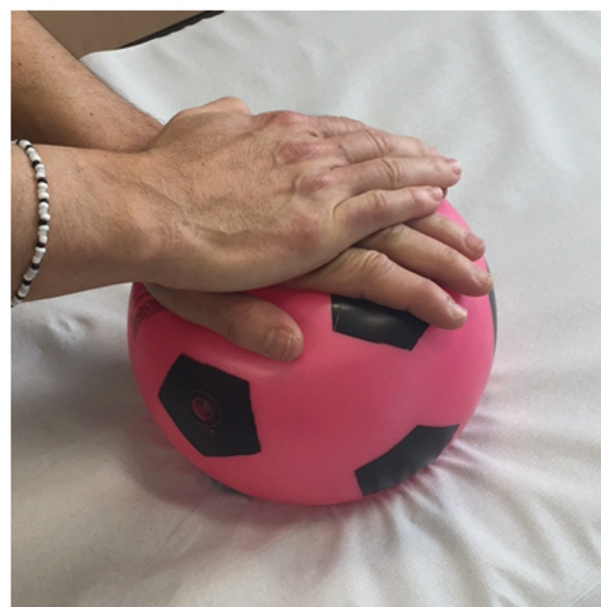Second stage (when the repair is no longer at risk): this is a strengthening stage for complete mobility recovery and improvement of conscious and unconscious neuromuscular capacities. This stage can only begin after the repaired tissues have healed.

At this stage, the goal is complete mobility recovery and specific treatment of any stiffness on pronosupination (► Fig. 6). **It consists of complete active and assisted mobilizations in flexion-extension and pronosupination.** The presence of stiffness on pronosupination must result in specific DRUJ treatment, with deep massage of the interosseous membrane and stretching of the muscles attached to it. Some cases require proximal radioulnar joint mobilization.²¹

Conscious neuromuscular control through isotonic potentiation of the stabilizing muscles of the DRUJ: we mainly exercise the **PQ** muscle with the arm in supination and using Thera-Band (Performance Health, Warrenville, IL, US). We start with the forearm in supination and the elastic band knotted on the back of the hand; next, we move to a pronated position. Isotonic exercises for the **ECU** muscle: with the forearm in pronation and the Thera-Band knotted on the back of the hand, perform a slight extension with ulnar deviation. We can also do it manually against the resistance provided by the therapist. (► Fig. 7). We exercise the elbow



A



B

Fig. 5 Conscious joint control. (A) Mirror therapy. The affected hand is inside the box and tries to reproduce the gestures made by the healthy wrist outside the box and reflected in the mirror. (B) Ball rolling on the table in closed chain kinetics.

muscles (**BR, B, and T**) with elbow flexion-extension exercises and the forearm in any position. It is easy to exercise the **APL and FPB** muscles against the manual resistance provided by the therapist. Other muscles can help DRUJ coaptation, including the **FDS** in closed kinetic contraction (with a small weight held with the proximal interphalangeal joints, the arm close to the body, and an extended elbow).

Unconscious neuromuscular control uses reflexes for active joint locking, partly compensating for its passive instability. The exercises are performed in open, closed, or semi-closed kinetic chain, with the arm on pronation or supination.¹⁸ Examples:

- **Advance closed kinetic chain exercises** include ball rolls on the wall (the therapist can destabilize it in



A



B

Fig. 6 Assisted movements to gain pronosupination. (A) Assisted pronation using a 3D wheel and Thera-Band. (B) Pronation assisted by FlexBar.



Fig. 8 Unconscious neuromuscular control through a 3D maze ball control exercise.

different directions to increase difficulty) or support exercises on BOSU.

– **Semi-closed kinetic chain exercises** include controlling a ball through a maze on the palm (► **Fig. 8**).

– **Open kinetic chain perturbation exercises** include FlexBar (Performance Health), Bodyblade (Hymanson,



A



B

Fig. 7 Isotonic potentiation with Thera-Band. (A) For the PQ, we start with the forearm in supination and then bring it to the pronated position. (B) For the ECU, we pronate the forearm and perform wrist extension with ulnar deviation.

Inc., Playa del Rey, CA, US), and Powerball (Kernpower GmbH, Himmelstadt, Germany), in this order,²² or laser drawings on the wall (► **Fig. 9**). It is possible to modify open kinetic chain exercises in form and difficulty according to the needs of each patient.

Third (last) stage: Specific reeducation of the apprehension movement, palmar support, and activities according to the needs of each patient. Initially, we exercise the **apprehension movement** specifically in supination, then, with the forearm in neutral position, and, eventually, in pronation due to the positive ulnar variance caused by the latter position.²³

We perform different wrist angulations until regaining complete **palmar support**. First, we elevate the heel of the hand with foam, open the fingers for load distribution, and shift the weight to the distal area of the fingers; we can also use specific devices for this purpose (► **Fig. 10**).

In addition, we prescribe **plyometric exercises** for the upper extremity. In these exercises, a concentric contraction follows a fast eccentric contraction. An example is throwing a




Fig. 9 Open chain exercises with perturbation. (A) Disturbance caused by FlexBar movement. (B) Powerball random gyroscope; the multidirectional forces generated by the gyroscope cause reactive muscle contractions. (C) Laser placement on the back of the wrist to try to reproduce tortuous paths without touching the lines.



Fig. 10 Reeducation of palmar support. (A) Lower wrist angulation. (B) Full palmar support.

ball: initially, we may use a 500-g ball, and increase its weight later. Another example are the wall push-ups, with the palms planted on a wall, elbow flexion, and bouncing back to the starting position.

Finally, **specific exercises for sports or work activities** can recreate biomechanical actions for individual cases.

Rehabilitation Protocols Per Surgical Technique

The rehabilitation treatment follows the same progression, except for a few details. However, the time to start these exercises varies according to the surgical intervention and the technique employed in it (> **Table 1**).

Patients treated conservatively must use a forearm orthosis for two to three weeks depending on the injury (the patient can keep the orthosis at night for two more weeks).

Pain control *after orthosis removal* uses electrotherapy, anti-inflammatory agents, and muscle-aponeurotic massage for two weeks. We perform active and self-assisted flexion-extension and pronosupination exercises for the wrist. In addition, we start conscious joint control through MT, JPS, and exercises with a ball on the table.

During the next 2 weeks, as tolerated, we must recover full joint ROM with passive exercises under the guidance of a physical therapist. We begin the isotonic workout of stabilizer muscles using Thera-Band and implement advanced closed kinetic chain exercises, including rolling a ball on the wall, and open chain perturbation interventions using Flex-Bar, Powerball, or laser control.

By the *sixth week*, we introduce full-load exercises²⁴ specific for apprehension and palmar support. If symptoms last more than three months, it may be time to consider surgical intervention.

Table 1 Rehabilitation protocols for triangular fibrocartilage complex injuries with no repair or after different surgical treatments

	Immobilization	Beginning of the rehabilitation	Rehabilitation protocol
Unrepaired triangular fibrocartilage complex	Forearm brace for 2 weeks + removable nighttime orthosis for 2 weeks	Third week	3 to 4 weeks: Pain control. Active and assisted exercises in flexion-extension and pronation with no stress. Mirror therapy, joint position sense. Closed kinetic chain ROM exercises. Isometric exercises for the PQ, ECU; B, BR, T; APL, EPB. 5 to 6 weeks: Total ROM gain. Treat any stiffness. Isotonic exercises for the PQ, ECU; B, BR, T; APL, EPB; FDS. Advanced closed kinetic chain, semi-closed kinetic chain, open kinetic chain perturbation exercises. > 6 weeks: Specific exercises for apprehension and palmar support.
		Third week	
Debridement			
Capsular suture/foveal reattachment	Münster-type orthosis for 3-4 weeks + forearm splint for 2 weeks + removable nighttime orthosis for 2 weeks	Sixth week	6 to 8 weeks: Pain and edema control. Active and assisted exercises in flexion-extension and pronosupination with no stress. Mirror therapy, joint position sense. Closed kinetic chain ROM exercises. Isometric exercises for the PQ, ECU; B, BR, T; APL, EPB. 9 to 11 weeks: Total ROM gain. Treat any stiffness. Isotonic exercises for the PQ, ECU; B, BR, T; APL, EPB; FDS. Advanced closed kinetic chain, semi-closed kinetic chain, open kinetic chain perturbation exercises. 12 weeks: Specific exercises for apprehension and palmar support, plyometric exercises.
Ligamentoplasty	Münster-type orthosis for 2 weeks + removable nighttime orthosis for 4 weeks	Third week	3 to 5 weeks: Pain and edema control. Active and assisted exercises in flexion-extension and pronosupination with no stress. Mirror therapy, joint position sense. Closed kinetic chain ROM exercises. Isometric exercises for the PQ, ECU; B, BR, T; APL, EPB. 6 to 11 weeks: Total ROM gain. Treat any stiffness. Isotonic exercises for the PQ, ECU; B, BR, T; APL, EPB; FDS. Advanced closed kinetic chain, semi-closed kinetic chain, open kinetic chain perturbation exercises. 12 weeks: Specific exercises for apprehension and palmar support, plyometric exercises.

Abbreviations: APL, abductor pollicis longus; B, brachialis; BR, brachioradialis; ECU, extensor carpi ulnaris; EPB, extensor carpi ulnaris; FDS, flexor digitorum superficialis; PQ, pronator quadratus; ROM, range of motion; T, triceps.

Note: Immobilization and the starting time of the exercise program will vary in each case.

After debridement, the management is similar, using a forearm orthosis with the wrist in slight extension for two weeks. Exercises begin after orthosis removal, and the patient can use a removable nighttime device for another two weeks. Full-load exercises start in the sixth week.

Patients submitted to **capsular sutures or foveal reattachment** must use a brachial splint that enables elbow flexion and keeps the forearm in a neutral position or a Münster-type orthosis blocking pronosupination for three to four weeks. Next, we replace the orthosis for a forearm brace with a free elbow for two weeks. During these five to six weeks, we must control pain and monitor digital edema. Patients can start isometric exercises despite immobilization.

After splint removal, we must pay close attention to potential trophic conditions and pain. Mobility recovery in flexion-extension and pronosupination starts in two weeks, with no excessive force. In addition, we implement isometric exercises and begin joint proprioceptive control.

For the following two to three weeks, as long as there is proper pain control, we exercise the entire joint path with greater intensity assisted by a physical therapist or mechanotherapy. This includes strengthening exercises for the PQ, ECU, B, BR, T, APL, and FPB using Thera-Band and advanced proprioceptive reeducation.

Apprehension, palmar support reeducation, plyometric, and specific exercises for different tasks or sports only start in the third month.

Patients submitted to **ligamentoplasties** begin rehabilitation earlier. They must use a brachial splint with the elbow flexed at 90° or a Münster-type orthosis for 2 weeks. Later, a removable wrist orthosis replaces the device. The patient must remove this orthosis to perform the exercises but can use it at night up to the sixth week or longer. Remember that the remodeling stage of the plasty peaks at the sixth week, lasts until the twelfth week, and reduces resistance.

Exercises progress as previously described. Reeducation exercises for palmar support, specific apprehension movements, and plyometric exercises with a ball only begin in the third month.

Conclusions

The biomechanical knowledge available to us enables the development of rehabilitation protocols for TFCC injuries. However, it is critical to distinguish how and when these treatments will be used based on the type of injury and surgical intervention. We have emphasized the importance of a correct period of immobilization and the corresponding orthoses for each case. Several studies have demonstrated the stabilizing role of the PQ and ECU. New data show how other muscles aid in this stabilization, and protocols must include exercises focused on them. All works agree on the convenience of neuromuscular rehabilitation for the correct functioning of the DRUJ, and this is one of the foundations of our treatments. We define a successful outcome as complete

lack of pain under loading in the different pronosupination positions.

Conflict of Interests

The authors have no conflict of interests to declare.

References

- Atzei A. DRUJ instability: arthroscopic ligament reconstruction. In: Del Piñal F, Manthoulin C, Luchetti R, eds. *Arthroscopic Management of ulnar pain*. Berlin: Springer Verlag; 2012: 147–160
- Carratalá Baixauli V, Lucas García FJ, Martínez Andrade C, Carratalá Baixauli R, Guisasaola Lerma E, Corella Montoya F. All-arthroscopic triangular fibrocartilage complex. Ligamentoplasty for chronic DRUJ instability. *Tech Hand Up Extrem Surg* 2019;23(01):44–51
- Schädel-Höpfner M, Müller K, Gehrman S, Lögters TT, Windolf J. [Therapy of triangular fibrocartilage complex lesions]. *Unfallchirurg* 2012;115(07):582–588
- Mirghasemi AR, Lee DJ, Rahimi N, Rashidinia S, Elfar JC. Distal radioulnar joint instability. *Geriatr Orthop Surg Rehabil* 2015;6(03):225–229
- William B. Stability of the distal radioulnar joint: biomechanics, pathophysiology, physical diagnosis, and restoration of function what we have learned in 25 years. *J Hand Surg Am* 2007;32(07): 1086–1106
- Moritomo H. The distal oblique bundle of the distal interosseous membrane of the forearm. *J Wrist Surg* 2013;2(01):93–94
- Watanabe H, Berger RA, An KN, Berglund LJ, Zobitz ME. Stability of the distal radioulnar joint contributed by the joint capsule. *J Hand Surg Am* 2004;29(06):1114–1120
- Morrey B, An KN. Stability of the elbow osseous constraints. *J Shoulder Elbow Surg* 2005;14(1 Suppl S):174S–178S
- Manson TT, Pfaeffle HJ, Herdon JH, Tomaino MM, Fischer KJ. Forearm rotation alters interosseous ligament strain distribution. *J Hand Surg Am* 2000;25(06):1058–1063
- Spinner M, Kaplan EB. Extensor carpi ulnaris. Its relationship to the stability of the distal radio-ulnar joint. *Clin Orthop Relat Res* 1970;68(68):124–129
- Stuart PR. Pronator quadratus revisited. *J Hand Surg [Br]* 1996;21(06):714–722
- Esplugas M, García-Elías M. *Terapia de Mano basada en el razonamiento y la práctica clínica. Biomecánica del antebrazo y aplicaciones prácticas 2020* Sevilla: Universidad Internacional de Andalucía 2020
- Bonhof-Jansen EDJ, Kroon GJ, Brink SM, van JHuchelen. Rehabilitation with a stabilizing exercise program in triangular fibrocartilage complex lesions with distal radioulnar joint instability: A pilot intervention study. *Hand Ther* 2019;24(04):116–122
- Esplugas M, Llovet VA. Lesiones del complejo del fibrocartilago triangular. Tipos de reparación *Rev Esp Artros Cir Articul*. 2014; 21(01):14–27
- Atzei A, Luchetti R. Foveal TFCC tear classification and treatment. *Hand Clin* 2011;27(03):263–272
- Bachinskas AJ, Helsen EA, Morris HA, Hearon BF. Nonsurgical treatment for acute posttraumatic distal radioulnar joint instability: a case series. *J Hand Surg Global Online* 2020;2(01):35–41
- Magnus CR, Arnold CM, Johnston G, Haas VDB, Basran J, Krentz JR, Farthing JP. Cross-education for improving strength and mobility after distal radius fractures: a randomized controlled trial. *Arch Phys Med Rehabil* 2013;94(07):1247–1255
- Mesplé G, Grelet V, Léger O, Lemoine S, Ricarrère D, Geoffroy C. Rehabilitation of distal radioulnar joint instability. *Hand Surg Rehabil* 2017;36(05):314–321

- 19 Hagert E, Hagert CG. Understanding stability of the distal radio-ulnar joint through an understanding of its anatomy. *Hand Clin* 2010;26(04):459–466
- 20 Mesplie G. Stabilité de l'articulation radio-ulnaire distale: quid du carré pronateur kinesithérapie. *Law Rev* 2007; 68:58–62
- 21 LaStayo PC, Lee MJ. The forearm complex: anatomy, biomechanics and clinical considerations. *J Hand Ther* 2006;19(02): 137–144
- 22 Arora S, Button DC, Basset FA, Behm DG. The effect of double versus single oscillating exercise devices on trunk and limb muscle activation. *Int J Sports Phys Ther* 2013;8(04):370–380
- 23 Minami A, Kato H. Ulnar shortening for triangular fibrocartilage complex tears associated with ulnar positive variance. *J Hand Surg Am* 1998;23(05):904–908
- 24 Sander AL, Sommer K, Kaiser AK, Marzi I, Frank J. Outcome of conservative treatment for triangular fibrocartilage complex lesions with stable distal radioulnar joint. *Eur J Trauma Emerg Surg* 2021;47(05):1621–1625