



Spinal Melorheostosis Associated with Intradural Fibrous Band and Extensive Lipomatosis Causing Thoracic Cord Tethering and Myelomalacia: A Unique Case Highlighting Importance of MRI in Management

Kanchan Vivek Dhanokar¹ B.T. Pushpa¹ Ajoy Prasad Shetty² S. Rajasekaran²

¹Department of Radiology, Ganga Hospital, Coimbatore, Tamil Nadu, India

²Department of Orthopaedics and Spine Surgery, Ganga Hospital, Coimbatore, Tamil Nadu, India

Address for correspondence Pushpa BT, DNB, FRCR, Department of Radiology, Ganga Medical Centre and Hospitals Pvt Ltd, 313, Mettupalayam Road, Coimbatore, Tamil Nadu, India. Pin: 641043 (e-mail: ocpushpa@gmail.com).

Indian J Radiol Imaging 2022;32:411–415.

Abstract

Axial melorheostosis is rare with only few cases reported and even fewer with symptoms. While symptoms secondary to neural foramen or spinal canal stenosis caused by hyperostotic bone are common, only three symptomatic cases of spinal melorheostosis with associated intradural lipomatous lesions have been reported to date. In none of them the fibrous component of lipofibromatous lesion was identified preoperatively on magnetic resonance imaging. We report here a case of 18-year-old male who presented with thoracic myelopathy secondary to widespread spinal melorheostosis associated with extensive intradural lipomatosis and fibrous component in thoracic lipoma, causing tethering of thoracic spinal cord and myelomalacia. The patient was treated with T2 to T9 posterior instrumented stabilization followed by T3 to T8 laminectomy along with selective thoracic lipofibromatous tumor debulking. Detection of the fibromatous component in multilevel extensive intradural lipomatosis associated with melorheostosis is helpful in planning selection of the level of surgical excision and decompression.

Keywords

- ▶ fibrous band
- ▶ spinal melorheostosis
- ▶ intradural lipoma
- ▶ cord tethering
- ▶ lipofibromatous

Introduction

Melorheostosis is a rare hereditary sclerosing mesodermal dysplasia of the bone that commonly presents in the appendicular skeleton, with an estimated prevalence of one case/million.¹ Very few cases of symptomatic spinal melorheostosis are documented in the literature. We report a rare case of spinal melorheostosis and extensive intradural lipomatosis presenting with myelopathy due to a coexistent

intradural fibrous band in the thoracic region, resulting in cord tethering and myelomalacia.

Case Report

An 18-year-old male patient presented with insidious onset of progressive gait instability over 4 months without radiculopathy, back pain, or sensory disturbances. He had broad-

published online
July 31, 2022

DOI <https://doi.org/10.1055/s-0042-1748883>.
ISSN 0971-3026.

© 2022. Indian Radiological Association. All rights reserved.
This is an open access article published by Thieme under the terms of the Creative Commons Attribution-NonDerivative-NonCommercial-License, permitting copying and reproduction so long as the original work is given appropriate credit. Contents may not be used for commercial purposes, or adapted, remixed, transformed or built upon. (<https://creativecommons.org/licenses/by-nc-nd/4.0/>)
Thieme Medical and Scientific Publishers Pvt. Ltd., A-12, 2nd Floor, Sector 2, Noida-201301 UP, India

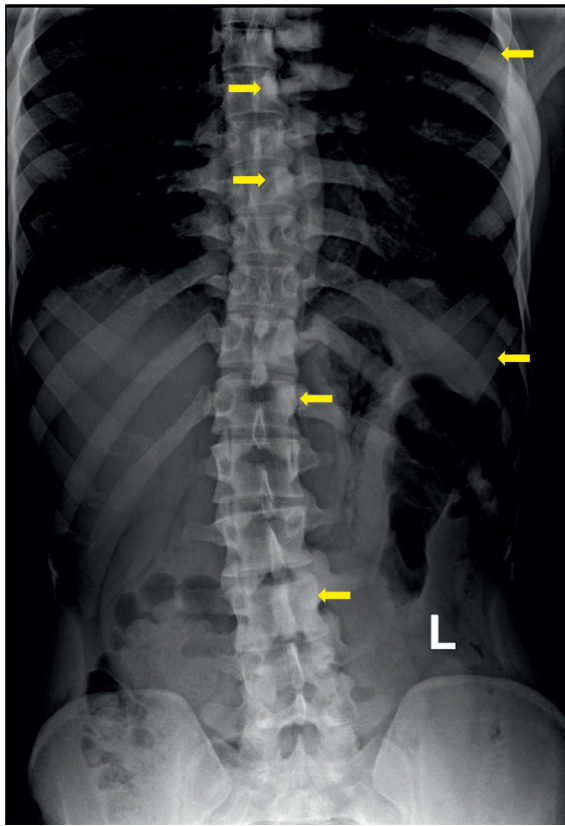


Fig. 1 X-ray thoracic spine showing hyperostosis (arrows) involving left half of T1, T2, T4–7, T11, T12, L3–5 vertebral bodies, left 5th, 6th, 10th, 11th ribs.

based myelopathic gait with upper motor neuron signs of the lower limbs on examination. Neurology in both upper limb and hematological profile was normal. Thoracolumbar radiograph (►**Fig. 1**) revealed hyperostosis of left halves of T1 to T8, T11, T12, L3, L4 vertebral bodies and posterior elements, left 2nd, 3rd, 5th to 7th, 11th, 12th ribs. Unilateral flowing multilevel hyperostosis showing the typical dermatomal distribution and lack of aggressive features suggested the diagnosis of axial melorheostosis.

Magnetic resonance imaging (MRI) revealed multilevel hyperostosis predominantly on the left half of vertebral bodies, posterior elements, and left ribs (►**Fig. 2**). Three discrete intradural lipomas were present at C7 to T1, T3 to T8, and T12–L1 levels on the dorsal surface of the cord. Cervical intradural lipoma (►**Fig. 3**) measured 27×7 mm, thoracolumbar junctional lipoma (►**Fig. 4**) measured 49×20 mm and were displacing the spinal cord without compression. Thoracic lipoma (►**Fig. 5**) measured 10 cm in length and 3 cm in thickness. There was myelomalacia in the cord at T6 to 7 level, which on scrutiny was observed to be caused by a vertically oriented, 3 cm long, thick fibrous band within the lipoma causing tethering of the cord to the left side. The band was extending into the left neural foraminal region across the dura. Computed tomographic scan confirmed these findings (►**Fig. 6**).

Thoracic lipofibromatous tumor debulking was performed (►**Figs. 7 and 8**). Histopathological evaluation revealed thick fibrous dural septae and mature adipose tissue. The patient had complete recovery at 6 weeks follow-up visit.

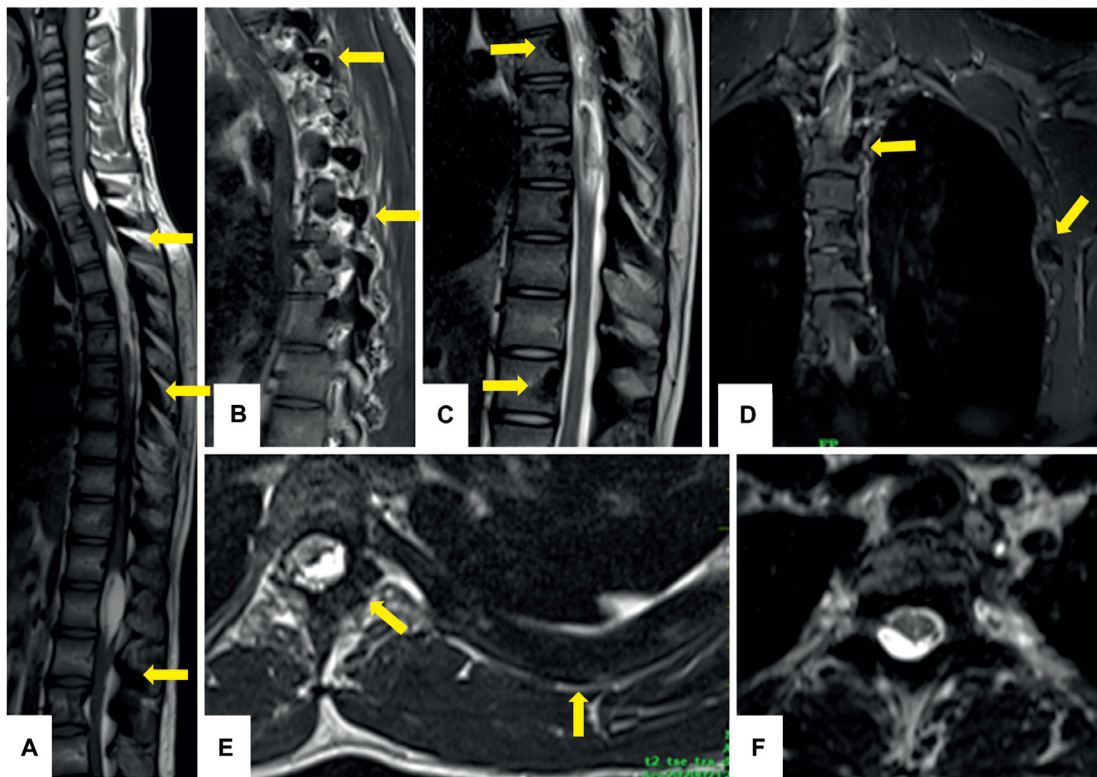


Fig. 2 Sagittal T1 (A, B) T2 (C), short tau inversion recovery (STIR) (D), and axial T2 (E, F) images—hypointensity involving left half of multiple vertebral bodies, posterior elements, left ribs (arrows) suggestive of hyperostosis. Spinal hyperostosis is not causing spinal canal stenosis or cord compression.

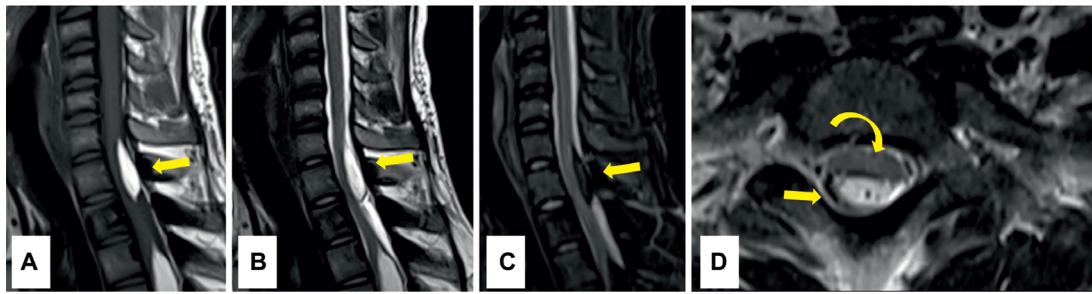


Fig. 3 Sagittal T1 (A), T2 (B), short tau inversion recovery (STIR) (C) images—well-defined dorsal intradural lipoma (arrows) at C7 to T1 level, measuring 27 × 7mm, hyperintense on T1, T2-weighted images, hypointense on STIR images. Axial T2 (D) image—cord displaced anteriorly (curved arrow) without myelomalacia.

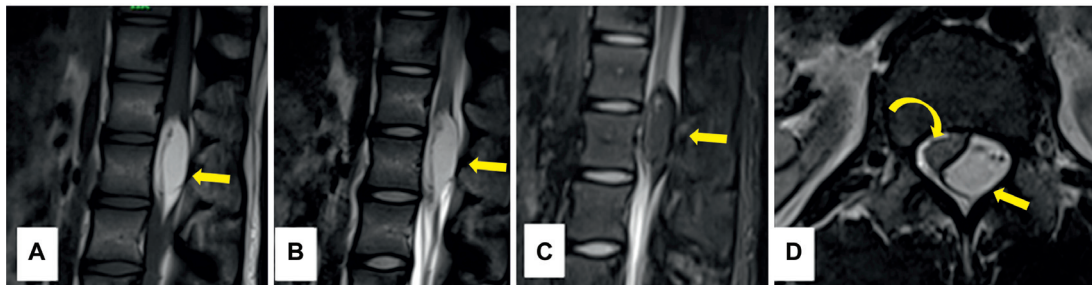


Fig. 4 Sagittal T1 (A), T2 (B), and short tau inversion recovery (STIR) (C) images showing dorsal intradural lipoma (arrows) at T12-L1 level, measuring 49 × 20mm, hyperintense on T1, T2-weighted images, hypointense on STIR images. Axial T2 (D) image—cord displaced by lesion (curved arrow) without myelomalacia.

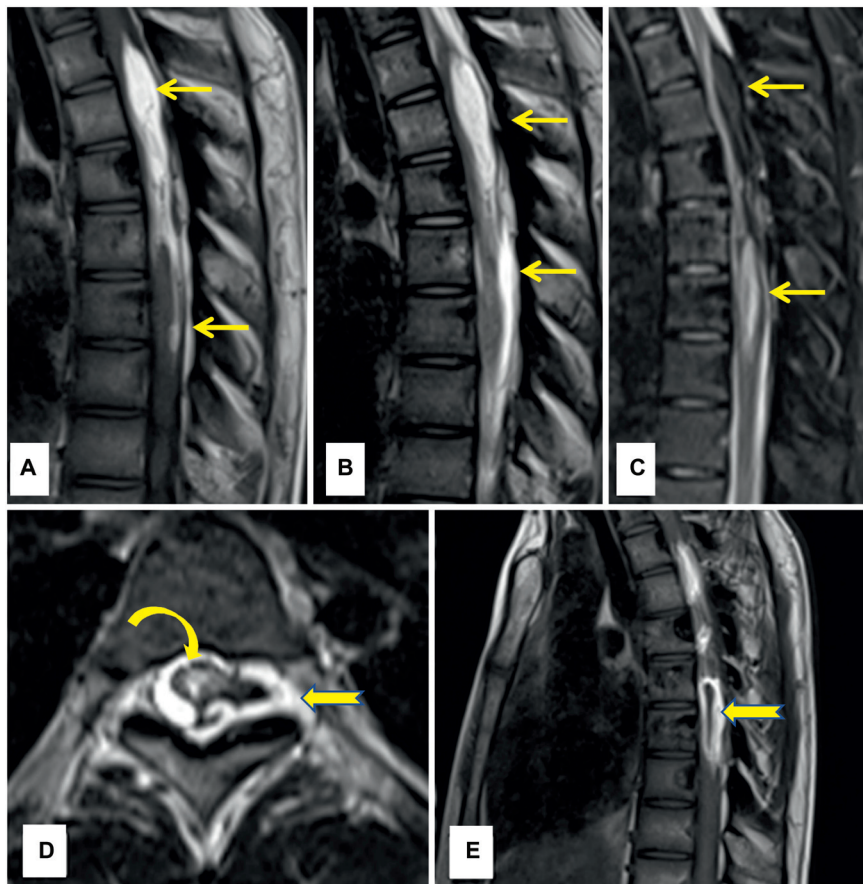


Fig. 5 Sagittal T1(A), T2 (B), and short tau inversion recovery (C) images—T3 to T8 level dorsal intradural lipoma (straight arrows). Myelomalacia and leftward kinking of the cord (curved arrow) at T6 to T8 level. Axial, sagittal T2 (D, E) images—thin hypointense fibrous band (notched arrows).

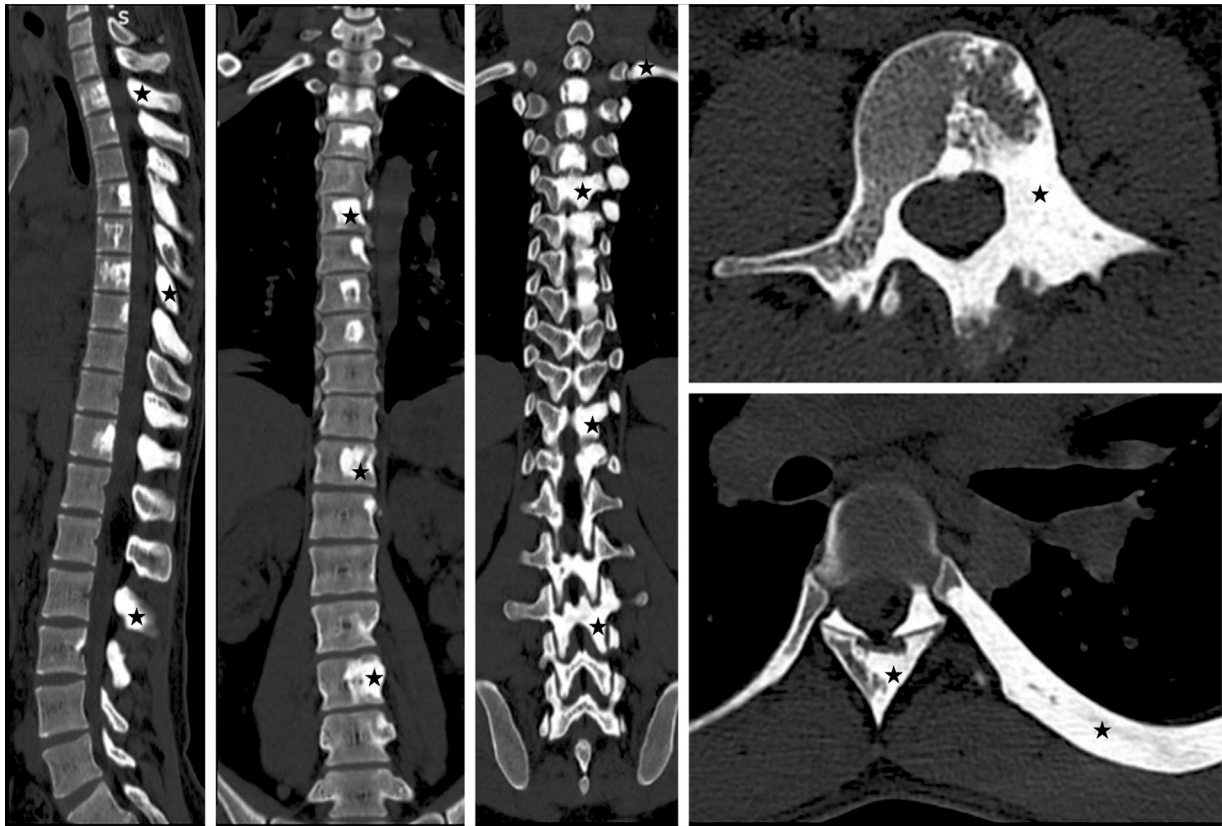

Fig. 6 Computed tomography sagittal and axial images showing diffuse hyperostosis (asterisk) involving left half of multiple vertebral bodies, pedicles, left ribs.

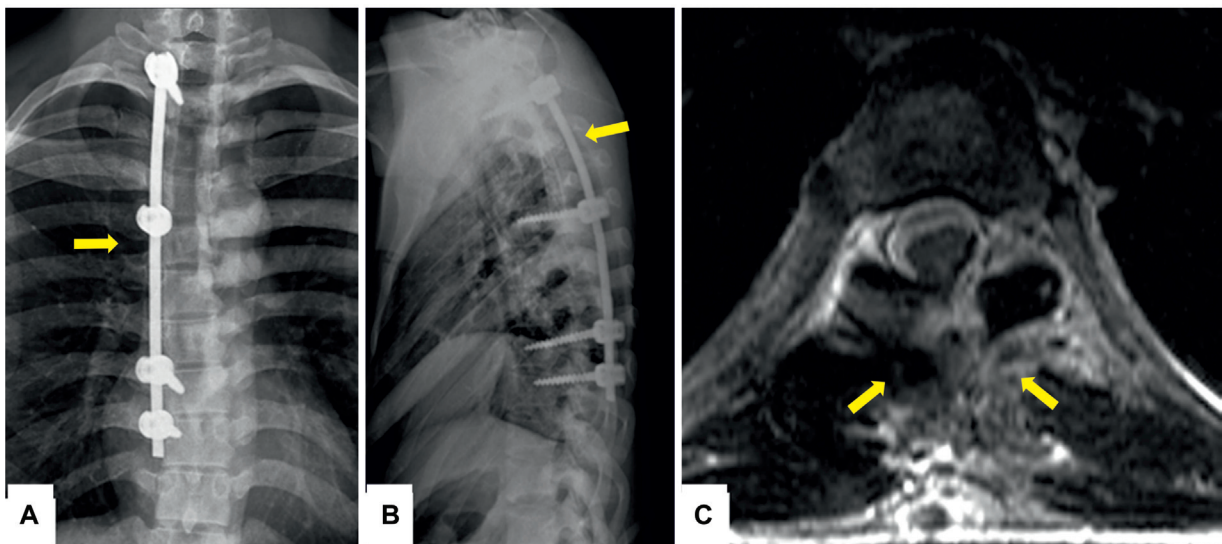


Fig. 7 Postoperative anteroposterior radiograph (A) and lateral radiograph (B)—T2 to T9 posterior instrumented stabilization, strategic pedicle screws, and rod (straight arrows). T2-weighted axial magnetic resonance imaging (C)—adequate canal decompression, debulking of lipofibromatous tumor (straight arrow), expansion of the cord.

Discussion

Based on our literature search, only 40 cases of spinal melorheostosis have been reported so far. Radiological appearance in axial melorheostosis ranges from unilateral focal sclerotic lesions resembling enostosis to bulky and deformative hyperostosis spanning across multiple segments. Our

case showed clear demarcation between involved and normal bone at all the levels supporting sclerotomal distribution of hyperostosis.¹ Most of the reported cases are incidentally detected²⁻⁶ or presenting with vague back pain.^{7,8} Cases with myelopathic symptoms secondary to the spinal cord or nerve root compression by hyperostotic bone in melorheostosis have been reported.⁹⁻¹⁴

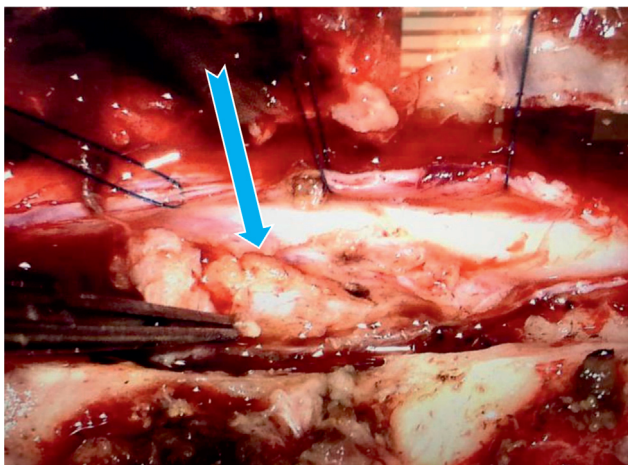


Fig. 8 Intraoperative photograph showing an intradural component of thoracic lipofibromatous lesion (arrow) which was strongly adherent to the cord.

Only three cases of spinal melorheostosis and coexisting intradural lipomas are reported to date. Garver et al and Isaacs and Resnick reported a case of rib, spinal, and pelvic melorheostosis, multilevel intradural lipoma causing myelomalacia and quadriparesis.^{15,16} Raby and Vivian reported a case of spinal melorheostosis with C6 to T6 intradural lipoma causing myelopathy.¹⁷ Schellhammer et al reported a case of spinal melorheostosis and cervicothoracic junctional intradural lipoma causing brachialgia.¹⁸ Of these, only the case reported by Graver et al showed microscopic fibrous components on histopathology. Our case is the first reported case in which MRI showed a distinct and thick fibrous band within the lipomatous mass causing tethering of the spinal cord and myelomalacia. Although there were three distinct lipomas in our patient, identification of fibrous band helped in the selection of the level of surgical excision and decompression rather than extensive surgery of the entire lipomatosis.

Conclusion

Axial melorheostosis is usually incidentally detected. Neurological manifestations in spinal melorheostosis are mainly due to nerve entrapment and cord compression by the hyperostosis itself or rarely due to associated lipofibromatous lesions compressing the cord and nerves. These lipofibromatous lesions can be diffuse, as in this case, for which MRI is of great utility to locate the exact area to be decompressed rather than extensive surgery.

Conflict of Interest

None declared.

References

- Murray RO, McCredie J. Melorheostosis and the sclerotomes: a radiological correlation. *Skeletal Radiol* 1979;4(02):57–71
- Bayya N, Fairfax A, Dey C, Butela S, Mihlon F. Axial melorheostosis: a rare presentation. *Radiol Case Rep* 2020;15(11):2415–2417
- Hoang VT, Van HAT, Chansomphou V, Trinh CT. The dripping candle wax sign of melorheostosis. *SAGE Open Med Case Rep* 2020;8:1–6
- Guler I, Aybay MN, Cengiz A, Eser G. Melorheostosis of the spine and ribs. *Spine J* 2015;15(08):1901–1902
- Motimaya AM, Meyers SP. Melorheostosis involving the cervical and upper thoracic spine: radiographic, CT, and MR imaging findings. *AJNR Am J Neuroradiol* 2006;27(06):1198–1200www.ajnr.org Accessed January 28, 2021
- Lone AR, Ahmad M, Aziz SA, et al. Melorheostosis with renal arterio-venous malformation: a case report with review of literature. *Indian J Med Paediatr Oncol* 2009;30(01):39–42
- McCarthy M, Mehdian H, Fairbairn KJ, Stevens A. Melorheostosis of the tenth and eleventh thoracic vertebrae crossing the facet joint: a rare cause of back pain. *Skeletal Radiol* 2004;33(05):283–286
- Sear HR. Melorheostosis and the creeping periostitic form of leontiasis; report of a case of osteitis in a rib showing apparently a connecting link between these two lesions. *Br J Radiol* 1947;20(239):470–473
- Zeiller SC, Vaccaro AR, Wimberley DW, Albert TJ, Harrop JS, Hilibrand AS. Severe myelopathy resulting from melorheostosis of the cervicothoracic spine. A case report. *J Bone Joint Surg Am* 2005;87(12):2759–2762
- Reznik M, Fried GW. Myelopathy associated with melorheostosis: a case report. *Arch Phys Med Rehabil* 2005;86(07):1495–1497
- Saxena A, Neelakantan A, Jampana R, Sangra M. Melorheostosis causing lumbar radiculopathy: a case report and a review of the literature. *Spine J* 2013;13(08):e27–e29
- Renjith KR, Shetty AP, Kanna P RM, Rajasekaran S. Spinal melorheostosis: a rare cause for thoracic radiculopathy. *Int J Spine Surg* 2020;14(02):209–212
- Sureka B, Mittal MK, Udhaya K, Sinha M, Mittal A, Thukral BB. Melorheostosis: two atypical cases. *Indian J Radiol Imaging* 2014;24(02):192–195
- Yoon J, Al Shafai L, Nahal A, Turcotte RE, Martin MH. Melorheostosis of the sacrum causing acute-onset neurological symptoms. *Skeletal Radiol* 2011;40(10):1369–1373
- Garver P, Resnick D, Haghghi P, Guerra J. Melorheostosis of the axial skeleton with associated fibrolipomatous lesions. *Skeletal Radiol* 1982;9(01):41–44
- Isaacs P, Resnick D. MR appearance of axial melorheostosis. *Skeletal Radiol* 1993;22(01):47–48
- Raby N, Vivian G. Case report 478: melorheostosis of the axial skeleton with associated intrathecal lipoma. *Skeletal Radiol* 1988;17(03):216–219
- Schellhammer F, Rapp M, Saleh A. Melorheostose der HWS bei einem intraspinalen Lipom. *RoFo Fortschr Geb Rontgenstr Nuklearmed* 2006;178(08):822–823