

Multimorbidity in a 35-Year-Old Female Patient Treated with Homeopathy: A Case Report

Jayasubhashini Mallangi¹ Jyotika Chaudhuri² Roja Varanasi² Praveen Oberai²

¹Department of Materia Medica, Guru Mishri Homoeopathic Medical College and Hospital, Jalna, Maharashtra, India

²Clinical Research Unit, Central Council for Research in Homoeopathy, New Delhi, India

Address for correspondence Jyotika Chaudhuri, BHMS, MD (Hom.), Central Council for Research in Homoeopathy, 65, Institutional Area, Opposite D-block, Janakpuri, New Delhi 110058, India (e-mail: drjyotika.1992@gmail.com).

Homeopathy 2023;112:135–142.

Abstract

Background Multimorbidity, a prevailing trend in the primary care population of all ages, is a challenge for health care systems that are largely configured for single disease management. Homeopathy has shown competence in the management of chronic diseases, whether they occur as a single ailment or as a multimorbidity.

Case History A 35-year-old female patient presenting with hemorrhoids, low back pain, hypothyroidism, fibroadenosis breasts (bilateral), and fibroid uterus was given homeopathic treatment for 33 months at Nandigama AYUSH Lifestyle Disorders Clinic, Andhra Pradesh. She was prescribed the homeopathic medicines *Lachesis mutus* and *Thyroidinum* at different time intervals based on the totality of symptoms.

Results Following treatment, a reduction in the size of the uterine fibroid and complete regression of breast lumps in ultrasonography were noted. The modified Naranjo criteria total score was 10 out of 13. Further, significant improvement in symptoms and laboratory parameters, such as triiodothyronine (T3), tetra-iodothyronine (T4), and thyroid-stimulating hormone (TSH), indicated that a well-chosen homeopathic medicine may be beneficial in managing multimorbidity.

Conclusion This case study reveals a positive role of homeopathic treatment in multimorbidity. More case studies and well-designed controlled research should be used to further investigate homeopathic intervention in multimorbidity.

Keywords

- ▶ multimorbidity
- ▶ homeopathy
- ▶ polypharmacy
- ▶ *Lachesis mutus*
- ▶ *Thyroidinum*

Introduction

“Multimorbidity”, defined as the co-existence of two or more chronic conditions in an individual,¹ significantly affects the elderly and incurs a heavy burden on health care.² According to the WHO’s Study on Global Aging and Adult Health (SAGE) in India, 60.7% of those aged 70 and more, and 12.3% of those aged 18 to 49, reported having multiple chronic conditions.³ The rapid growth in non-communicable diseases and the persistence of infectious diseases are combining to make multimorbidity a major public health challenge in the BRICS nations.⁴ The gravity of

this public health issue can be weighed through its effects on the ability to work and on employability, disability and mortality within the population.⁵ Furthermore, because clinical treatments frequently focus on one disease at a time, people with multimorbidity have difficulty adhering to therapy and have lower quality of life.⁵

In such a situation, a therapy that is both cost-effective and comprehensive would be highly desirable. Based on a holistic therapeutic strategy and patient-centered care, the homeopathic system of medicine can deliver both cost-effective and complete medical care.⁶ Randomized controlled trials (RCTs),^{7,8} observational studies^{9–11} and case

received

October 28, 2021

accepted after revision

February 24, 2022

article published online

October 2, 2022

© 2022. The Faculty of Homeopathy.

All rights reserved.

Georg Thieme Verlag KG,

Rüdigerstraße 14,

70469 Stuttgart, Germany

DOI <https://doi.org/>

10.1055/s-0042-1749594.

ISSN 1475-4916.

reports^{12,13} on the management of the different clinical conditions manifested in the case under study have shown varying success.

There have also been case reports on the benefits of homeopathy in multimorbidity.^{14–16} In support of a positive role of homeopathy, there is a published case report of the homeopathic management of multimorbidity (severe climacteric syndrome, pelvic inflammatory disease, dyslipidemia, obesity, hepatic steatosis, pancreatic lipomatosis, gall bladder disease, and mild subclinical hypothyroidism) after surgical menopause.¹⁴ In another study, two siblings with multimorbidity – i.e., dyslexia, dyspraxia, asthma, eczema, hypertension, recurrent urinary tract infections, allergies – were treated by a homeopath employing a variety of homeopathic methods and medicines over a period of 1 year. This resulted in improvements in ADHD status, patient-generated outcomes and parent-reported pathology, and a reduction in conventional medication.¹⁵

In the present case study, homeopathic management of multimorbidity comprising five clinical conditions – namely fibroid uterus, fibroadenosis breasts, hypothyroidism, low back pain, and hemorrhoids – is reported with the goal of inspecting whether individualized homeopathy plays a role in the management of multimorbidity.

Case Presentation

A 35-year-old woman, tall statured, moderately built, and fair complexioned, visited the Lifestyle Disorders clinic, a co-located AYUSH set-up at the Community Health Centre, Nandigama, Krishna District, Andhra Pradesh, India, on August 6, 2018 with the complaints, in order of their appearance, of (1) mass per rectum diagnosed as hemorrhoids (ICD 10 N: K64.1); (2) pain in the lower back region (ICD 10 N: M54.5); (3) diagnosed hypothyroidism (ICD 10 N: E03.9); (4) painful lumps in both breasts, diagnosed as bilateral fibroadenosis (ICD 10 N: D24); and (5) profuse, irregular menses (every 2 months) with concurrent pain in lower abdomen, diagnosed as fibroid uterus (ICD 10 N: D25).

History of Presenting Complaints

The patient had noticed a mass per rectum five and a half years earlier, along with bleeding and a dull, aching pain during defecation. The mass retracted on its own following defecation. She also suffered from low back pain which was aggravated by motion and exertion. In early 2017, she entered an early stage of hypothyroidism, as per laboratory reports (– **Table 1**). She was treated with *Thyronorm* 25 mg once a day for 1 year after her diagnosis, after which she was referred for homeopathic treatment by a conventional physician. The patient also had persistent pain in her left breast, which worsened during menses and was aggravated by the slightest touch or jarring. Her breast pain was treated with analgesics, but the alleviation was only temporary. Later, pain in the right breast emerged, with recurrence in the left breast. Pain became more pronounced in the right breast and was diagnosed as fibroadenosis according to ultragraphy (USG) (– **Table 1**). In the meanwhile, she had been experienc-

ing a profuse menstrual flow along with a dull ache in her lower abdomen. Since then, menses had become profuse, dark, and clotted, with irregular cycles of approximately 2 months. In the USG pelvis, a bulky uterus with a fibroid sized 1.8 × 1.1 cm was discovered (– **Table 1**). She also complained of persistent lethargy, with decreased desire to perform daily household activities.

Personal History

Menarche occurred at the age of 13 years. Her menses had been regular since then until her complaints began. She prefers a non-vegetarian diet and has no tobacco, alcohol, or other stimulant addictions.

Life and Accessory Circumstances

The patient was born and brought up in a family of low socio-economical strata. While conversing about her family, with whom she had resentments over a housing dispute, she became agitated and restless. The patient had a history of grief due to changing her house after a conflict with relatives 5 years ago. She is adamant about reclaiming her home, for which she also threatened to retaliate against her relatives if the house was not returned. She wished for her families' pain or accidents. She was envious of her relatives' improving economic status. She refused to let her husband and children visit their relatives because she was afraid they would be poisoned. She avoided all gatherings in which those relatives were involved.

Mind and Disposition

- Anxiety and fear of ghosts and evil.
- Fear of being poisoned.
- Maliciousness.
- Ailments from grief and betrayal.
- Desires company during the time of her complaints.
- Revengeful.
- Suspicion toward relatives.

Physical Generals

Thermal reaction: hot patient; desire for cold food and drinks.

Clinical Findings

A palpable, smooth, hard, and tender lump, approximately 4 cm in diameter, was discovered in the left breast during a physical examination. Another lump with similar characteristics was identified in the right breast measuring 3 cm in diameter. The lumps in both breasts appeared to be surrounded by diffused swelling.

Diagnostic Assessment

The patient was diagnosed with multimorbidity, which included hypothyroidism, fibroadenosis in both breasts and fibroid uterus (based on ultrasound of the breasts and pelvis respectively), as well as thyroid function tests (triiodothyronine [T3], tetra-iodothyronine [T4], thyroid-stimulating hormone [TSH]). Clinical examination and clinical features indicated the presence of second-degree hemorrhoids and low back pain.

Table 1 Details of the timeline of follow-up

Date	Indications for prescription	Findings of laboratory investigations	Medicine with dose and repetition
August 6, 2018	LMP = July 30, 2018 (History of menstrual cycles: May 26, 2018, April 11, 2018), profuse, delayed, and irregular menses; painful lumps on both breasts (pain in the right breast more prominent than the left breast; appeared first in the left breast); lethargy; hemorrhoids with bleeding and aching in the rectum while defecating; low backache; restlessness; and agitation while conversing about relatives.	<p><i>Thyroid function test</i></p> <ul style="list-style-type: none"> T3-0.139 µg/dL [0.06-0.2 µg/dL], T4-12.3 µg/dL [4.5-12.0 µg/dL], TSH: <0.01 µIU/mL [0.30-5.5 µIU/mL]. (Date: January 7, 2017) T3: 0.112 µg/dL [0.08-0.2 µg/dL], T4: 8.21 µg/dL [5.1-14.1 µg/dL], TSH: 9.57 µIU/mL [0.27-4.2 µIU/mL]. (Date: July 13, 2017) <p><i>Ultrasound breasts:</i> February 22, 2017: Diffuse prominent fibro glandular tissue with few homogeneous hypoechoic nodules noted in both breasts with right > left. (Date: February 22, 2017)</p> <p><i>Ultrasound of whole abdomen</i></p> <p>April 4, 2017: Mildly bulky uterus with 1.8 × 1.1 cm fibroid in posterior myometrium. (Date: April 1, 2017)</p>	Lachesis 200c: one dose. Sac lac for 1 month. Patient continued with Thyronorm 25 mg.
September 3, 2018	LMP: September 1, 2018; menses were on time and normal flow; pain in breast lumps persisted; occasional tiredness; pain in anus on defecation but bleeding per rectum on and off; low backache; full of resentments, much as before the initial prescription.	-	Sac lac for 1 month. Patient continued with Thyronorm 25 mg.
October 8, 2018	LMP: September 29, 2018; menses were regular, profuse with pain in the lower abdomen and low back; pain of reduced intensity was present in breast lumps; hemorrhoidal pain was same; tiredness better; lethargy absent.	-	Sac lac for 1 month. Patient continued with Thyronorm 25 mg.
November 20, 2018	LMP: October 26, 2018; menses were profuse; painful hemorrhoids; pain in breast lumps lessened; low back pain reduced as it no longer occurred on motion but only after exertion; lethargy on and off; tiredness was absent, and she had a few fearful dreams whose details she did not remember on waking up.	-	Patient continued with Thyronorm 25 mg.
January 9, 2019	LMP: December 25, 2018; menses were delayed, normal flow; patient noticed a reduction in the size of breast lumps, with on and off occurrence of pain; hemorrhoidal pain on defecation was reduced in intensity; occasional low back pain and lethargy.	-	Sac lac for 1 month. Patient stopped Thyronorm 25 mg voluntarily.
February 11, 2019	LMP: January 24, 2019; menses were regular, with normal flow; lower abdominal pain occurred during last menses; pain in breast lumps recurred, aggravated by touch; profuse bleeding hemorrhoids thrice in the previous month; back pain was improving slightly; lethargy only during menses.	-	Lachesis 200c: one dose. Sac lac for 2 weeks.
March 19, 2019	LMP: March 27, 2019; improved menstrual flow and quantity, reduced abdominal pain; the size of the breast lumps seemed reduced with no tenderness; reduced low back pain; hemorrhoidal pain without bleeding on defecation; reduced tiredness, patient	-	Sac lac for 1 month.

(Continued)

Table 1 (Continued)

Date	Indications for prescription	Findings of laboratory investigations	Medicine with dose and repetition
April 27, 2019:	started participating in household chores with interest, unlike earlier; while following up on the case, she appeared less thoughtful about relative's behavior; she was calm and composed. LMP: April 25, 2019; general condition was better; pain in hemorrhoids became better, with no bleeding per rectum on defecation; her menstrual flow was regular; no tiredness; the patient could perform all her household chores properly; mental symptoms improved.	–	<i>Sac lac</i> for 1 month.
July 8, 2019:	LMP: June 21, 2019; regular menses during last 4 months; pain in the lower abdomen on and off during menses; dark and normal quantity of menstrual flow; no palpable breast lumps; slight back pain persisted; the patient was referred for ultrasound breasts and abdomen.	–	<i>Sac lac</i> for 1 month.
August 21, 2019	LMP: July 27, 2019; general condition was better; no menstrual complaint; low back pain improved; hemorrhoidal pain reduced without rectal bleeding.	Ultrasound of breasts: Regressed lumps in breasts—normal study. (Date: August 20, 2019) Ultrasound of whole abdomen: Reduction in size of the fibroids, i.e., 1.4 × 0.8 cm. (Date: August 20, 2019)	<i>Sac lac</i> for 1 month.
September 16, 2019	The patient was being monitored for thyroid complaints and hemorrhoids; she had no menstrual complaints; she started attending gatherings that involved her relatives; she grew hopeful about the possibility of purchasing a new home rather than resenting about a housing dispute.	–	<i>Sac lac</i> for 1 month.
October 26, 2019	General condition improved; low back pain intensity lessened; occasional hemorrhoidal pain without bleeding.	–	<i>Sac lac</i> for 1 month.
December 2, 2019	General condition better, but back pain persisted with exertion; hemorrhoidal pain and rectal bleeding were absent.	–	<i>Sac lac</i> for 1 month.
January 2, 2020	General condition better; Tiredness was reduced. No hemorrhoidal pain or rectal bleeding; improved back pain.	Thyroid function test: T3: 0.093 µg/dL [0.07–0.2 µg/dL], T4: 9.72 µg/dL [4.6–10.5 µg/dL], TSH: 6.49 µIU/mL [0.4–4.5 µIU/mL]. (Date: December 28, 2019)	<i>Sac lac</i> for 1 month.
February 11, 2020	No menstrual complaint; lethargy was reduced; low back pain was better and hemorrhoidal pain was on and off; the patient was referred for thyroid function test and ultrasound whole abdomen.	–	<i>Sac lac</i> for 1 month.
October 29, 2020	Palpitations and tiredness persisted occasionally; low back pain improved; hemorrhoidal pain during defecation.	Ultrasound of whole abdomen: Small uterine fibroid measuring 1 × 0.6 cm in size. (Date: October 20, 2020) Thyroid function test:	<i>Thyroidinum</i> 6c, 4 pills, once daily for 1 month.

Table 1 (Continued)

Date	Indications for prescription	Findings of laboratory investigations	Medicine with dose and repetition
December 3, 2020	Occasional tiredness while performing household chores; palpitations on exertion; hemorrhoidal pain during defecation; low back pain was better; no menstrual complaint.	TSH: 6.93 µIU/mL [0.550–4.780 µIU/mL] (Date: October 9, 2020)	<i>Thyroidinum 6c</i> , once daily for 2 months.
March 15, 2021	General condition was better; reduced tiredness; reduced palpitations; hemorrhoidal pain was reduced in intensity but persisted; the patient was calm and composed; thyroid profile test was suggested.	–	<i>Sac lac</i> for 1 month.
May 7, 2021	Hemorrhoidal pain did not occur with every episode of defecation; low back pain improved; reduced anxiety; the patient became more hopeful and less worried about the past.	Thyroid function test: T3: 1.17 ng/mL [0.60–1.81 ng/mL], T4: 8.0 µg/dL [4.5–12.6 µg/dL], TSH: 3.81 µIU/mL [0.35–5.50 µIU/mL]. (Date: May 3, 2021)	<i>Sac lac</i> for 1 month.

Abbreviations: LMP, last menstrual period; T3, triiodothyronine; T4, tetra-iodothyronine; TSH, thyroid-stimulating hormone.

Therapeutic Intervention

Based on the totality of symptoms and a reportorial analysis performed by using Repertory software, Cara 1.4 (►Fig. 1), the first five medicines with the number of rubrics covered and the grades of each medicine were *Lachesis* (8/17), *Belladonna* (7/13), *Calcarea carb* (7/13), *Phosphorus* (7/16), and *Arsenicum album* (6/14). Differentially, *Belladonna* is predominantly a right-sided medicine, and it does not address the patient's symptoms of revengefulness and hatred. It is the medicine given for sudden, violent onset. *Calcarea carb* patients are leuco-phlegmatic, fat, and perspiring individuals who are forgetful, apprehensive, and get worse from cold in every form, which did not match the lean, thin build, and mental symptoms of the patient. *Phosphorus* is a medicine for hemorrhage, and it is suitable for bright red menses that appear too early and are long-lasting and scanty. The burning sensation is marked as a keynote symptom of this medicine. *Phosphorus* patients, like the patient in this study, desire company but are neither revengeful nor malicious. While some of the symptoms of *Arsenicum album*, such as maliciousness, tiredness, restlessness and anxiety, matched the patient's complaints, other symptoms such as burning sensation, fear of death, fastidiousness and early menses did not.¹⁷

Furthermore, a keynote symptom of *Lachesis* wherein “diseases begin on the left and go to the right side” was justified by the appearance of pain in the left breast that proceeded to the right breast.¹⁸ The patient mentioned that she had not been well since the series of events that occurred during her house dispute (fights with relatives).¹⁸ Likewise, *Lachesis* is suitable for a woman who has not recovered from the change of life: “I have never felt well since that time”. *Lachesis* is a hot patient, malicious, suspicious and restless, with ailments appearing from long-lasting grief. *Lachesis* has a marked hemorrhagic tendency, protruding hemorrhoids during stool, dark menstrual blood, swelling in the mammary glands, anxiety, and fear of being poisoned.^{17,19} Based on the above, the patient received the individualized homeopathic treatment *Lachesis mutus* 200c (one dose), four globules moistened with medicine, and given orally. The patient was also advised lifestyle modifications such as regular exercise, yoga, increased consumption of a high fiber diet, and avoiding fried food.

Follow-up and Outcome

During follow-ups, the repeat USG-breasts and lower abdomen, plus thyroid function test, revealed marked overall improvement. Menses became regular, the uterine fibroid decreased in size, and TSH levels decreased. Further, the homeopathic remedy *Lachesis* ameliorated pain in both breasts, followed by regression of breast lumps. After the patient voluntarily discontinued the Thyronorm in January 2019 her symptoms steadily decreased but the TSH levels nevertheless increased after a period of 1 year, which led to the prescription of *Thyroidinum 6c* (4 pills, once daily) for 3 months. Symptoms of the patient, such as weakness, easy fatigue, uterine fibroids, fibroid tumors of the breast and hypothyroidism, concurred with those of *Thyroidinum*.^{17,19}

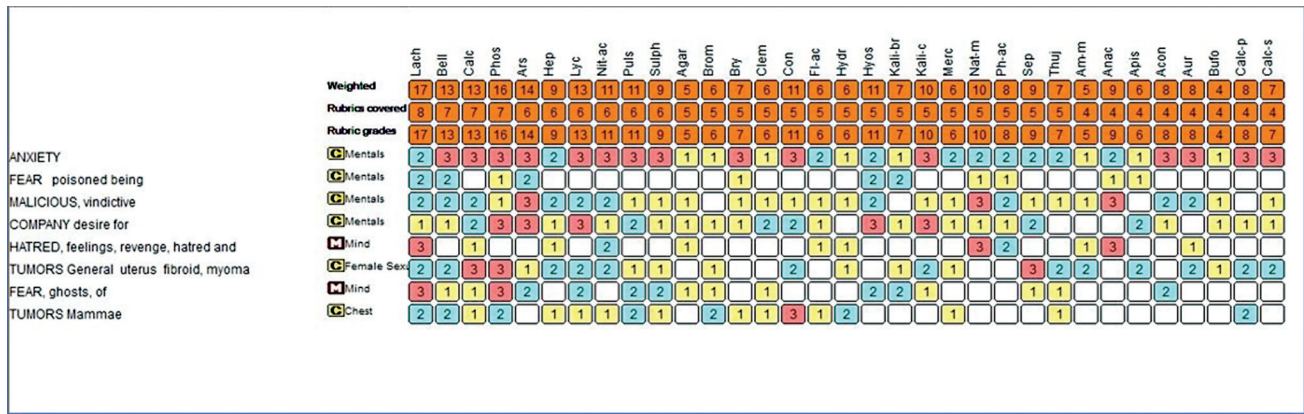


Fig. 1 Repertorial sheet from Repertory software version Cara 1.4 (Repertorial chart = *Lachesis*: 8/17, *Belladonna*: 7/13, *Calcarea carbonica*: 7/13, *Phosphorus*: 7/16, *Arsenicum album*: 6/14).

Considering the homeopathic principle of prescribing one simple medicine at a time to a patient, the homeopathic medicine *Thyroidinum 6c* was not given concurrently with *Lachesis* during the follow-up period. Thereafter, placebo was continued soon after improvement was observed in the patient (–Table 1). This shows the complete coverage capacity of an individualized homeopathic remedy, selected on the totality of symptoms according to homeopathic principles. This case study has been drafted in conformity with the HOM-CASE guidelines for clinical case reporting (–Supplementary Table S1, available online only).^{20,21} The patient signed a consent form permitting her medical images and other clinical information to be published anonymously in an academic journal. The patient expressed understanding that her name and initials would not be published, and that all due efforts would be made to conceal her identity.

MONARCH Inventory Score

The MONARCH inventory^{20,21} applied in this case study showed a total score of (10/13 (–Table 2). Details of the positive scores are as follows: criteria 1, 2, 4, and 5 (improvement in general well-being of the patient as assessed by interview with the patient on multiple visits); criterion 6A (fibroid uterus was last to appear and improved first; afterward breast fibroadenosis was reduced in size and thyroid function tests showed improvement; both of which came before fibroid uterus in order); criterion 8 (no other medication intake during homeopathic treatment, though lifestyle modifications were advised but as an adjunct); criterion 9 (regression of breast lumps and fibroid uterus confirmed by USG scan reports during homeopathic treatment; TSH levels were reduced during homeopathic treatment); and criterion 10 (a clinical improvement on repeat dosing). Based on the MONARCH score, it can be concluded that there is some evidence to attribute a causal link between the treatment and the clinical improvement in the patient.

Patient Perspective

The patient reports that she is feeling healthier, more active, and has a sense of mental peace. She says, “I feel very happy that after taking homeopathic treatment for the uterine

problem and breast lumps, no surgery was required, and I feel healthier and energetic while doing my household work”. She says she is sleeping peacefully and feels comfortable about herself, in contrast to her previous state of mind when she experienced disturbed sleep while thinking about her surgery. After being referred by her conventional doctor to homeopathy for management of her condition, she was relieved of her physical complaints as well as the anxiety. She mentions that her homeopathic doctor enquired about all her complaints in detail and gave her encouragement along with medicines. She says, “My physical complaints were subsiding and later, when I self-examined my breasts as instructed by my doctor, I noticed that the size of nodes had reduced. This was confirmed when my breast ultrasound report revealed a normal picture. I am very happy that no surgery was required thereafter”. She says that her anxiety and her resentments toward relatives are well controlled, with a reduced sense of suspicion and vengeance toward them. She ended her remarks by stating that all of her complaints had gradually faded away, and she was satisfied that her mind was also at peace.

Discussion

The homeopathic system of medicine is based on the “Law of Similars”. It means that the symptoms produced by a homeopathic medicine in a healthy individual are similar to those of the disease condition to be treated. The most similar and suitable medicine is prescribed based on the totality of symptoms, in singular and simple form, to treat people who are sick, not the diseases in themselves.²² On the other hand, conventional health care systems revolve around specialized disciplines and the identification and management of individual conditions.⁴ Moreover, medical research traditionally focuses on understanding and developing treatments for individual conditions. Thus, multimorbidity presents a profound challenge to the way medicine is delivered, taught, and researched.⁴

However, this case under study suggests that homeopathic treatment can be beneficial in cases of multimorbidity, including fibroid uterus, fibroadenosis breasts,

Table 2 MONARCH Inventory (improved version of the Modified Naranjo Criteria for Homeopathy). Maximum possible score = +13, minimum score = -6

No.	Domain	Grading of response to medication		
		Yes	No	Not sure
1	Was there an improvement in the main symptom or condition for which the homeopathy medicine was prescribed?	+2	-1	0
2	Did the clinical improvement occur within a plausible timeframe relative to the medicine intake?	+1	-2	0
3	Was there a homeopathic aggravation of symptoms?	+1	0	0
4	Did the effect encompass more than the main symptom or condition (i.e., were other symptoms, not related to the main presenting complaint, improved or changed)?	+1	0	0
5	Did overall well-being improve? (Suggest using a validated scale or mention about changes in physical, emotional, and behavioral elements)	+1	0	0
6A	Direction of cure: did some symptoms improve in the opposite order of the development of the symptoms of the disease?	+1	0	0
6B	Direction of cure: did at least two of the following aspects apply to the order of improvement of symptoms: <ul style="list-style-type: none"> • from organs of more importance to those of less importance? • from deeper to more superficial aspects of the individual? • from the top downwards? 	+1	0	0
7	Did “old symptoms” (defined as non-essential and non-clinical symptoms that were previously thought to have resolved) reappear temporarily during the course of improvement?	+1	0	0
8	Are there alternative causes (i.e., other than the medicine) that—with a high probability—could have produced the improvement? (Consider known course of disease, other forms of treatment, and other clinically relevant interventions).	-3	+1	0
9	Was the health improvement confirmed by any objective evidence? (e.g., investigations, clinical examination, etc.)	+2	0	0
10	Did repeat dosing, if conducted, create similar clinical improvement?	+1	0	0
	Total score	+10		

Note: The score for each item is shown in bold.

hypothyroidism, hemorrhoids, and low back pain. In this case study, a complete patient picture was elicited through the physician's observations and the patient's symptoms, as well as laboratory measures such as abdominal USG, breast USG, thyroid function tests, and clinical examination. The patient's symptomatology and pathological abnormalities improved over a 33-month period, according to laboratory parameters. Additionally, the MONARCH score attributed to the treatment implies a link between the medicines prescribed on the basis of homeopathic principles and the clinical improvement in the patient.

Keeping in view that elderly patients are more likely to develop multimorbidity, an observational study by Teut et al²³ demonstrated that elderly individuals with long-standing chronic diseases seek homeopathic treatment and that the severity of their complaints reduced significantly in the first 3 months after beginning treatment.

Multimorbidity is posing a widely recognized challenge to the whole medical profession, from primary care to acute and long-term hospital treatment.²⁴ Single-disease clinical practice guidelines (CPGs) are not designed to consider patients with multiple chronic conditions or multimorbidity.²⁵ Furthermore, following different CPGs would make treatment time-consuming, costly, and disruptive.²⁵ More-

over, applying multiple CPGs on a single patient may create an overwhelming treatment burden, which can lead to poor compliance and clinical outcomes.²⁵ The three broad challenges identified for treating multimorbidity are: (1) defining and measuring multimorbidity; (2) effects of multimorbidity on study design, implementation, and analysis; and (3) difficulties inherent in studying heterogeneity of treatment effects in patients with differing comorbid conditions.^{26,27}

In a systematic review of 600 research studies, it was found that RCTs testing behavioral interventions rarely consider individuals with multi-morbidity.²⁸ Placebo-controlled RCTs are considered the “gold standard” of evidence but they may have drawbacks in terms of external validity, especially when it comes to multimorbidity.²⁹ As a result, it may be necessary to apply a broader range of research methods that can provide converging evidence on treatment effects to address multiple chronic conditions.²⁹ At this juncture, pragmatic RCTs or comparative effectiveness studies are recommended for such research. Pragmatic trials, such as in the cohort multiple RCT design where “treatment as usual” is compared with the offer of study treatment, study patients in a “real world” setting and tend to emphasize patient-reported outcome measures.³⁰ The present case report can

be seen as contributory to that evidence building on the role of homeopathic management in multimorbidity.

Conclusion

The findings of this case study show that individualized homeopathic intervention may be useful in a patient with multimorbidity. The observations reinforce the need for conducting well-designed studies to further test the impact of homeopathy in such patients.

Highlights

- A female patient, aged 35 years, was treated successfully with individualized homeopathy for the multimorbidity of hemorrhoids, low back pain, hypothyroidism, fibroadenosis breasts, and fibroid uterus.
- Homeopathic medicines found useful for the case were *Lachesis* 200c and *Thyroidinum* 6c prescribed on separate occasions, depending upon the particular totality of symptoms.

Supplementary Material

– **Supplementary Table S1.** HOM-CASE checklist covered in the case.

Conflict of Interest

None declared.

Authors' Contribution

J.M. treated the case and made the first draft. J.C., R.V., and P.O. conceptualized and edited the draft for its content and all contributors approved the final draft for submission.

References

- 1 Van den Akker M, Buntinx F, Knottnerus JA. Comorbidity or multimorbidity: what's in a name? A review of literature. *Eur J Gen Pract* 1996;2:65–70
- 2 Himanshu H, Talukdar B. Prevalence of multimorbidity (chronic NCDS) and associated determinants among elderly in India. *Demogr India* 2017;69–76
- 3 International Institute for Population Sciences (IIPS) NPHCE, MoHFW, Harvard T.H. Chan School of Public Health (HSPH) and the University of Southern California (USC) 2020. Longitudinal Ageing Study in India (LASI) Wave 1, 2017–2018; Mumbai, India
- 4 The Academy of Medical Sciences. Addressing the Global Challenge of Multimorbidity: Lessons from the BRICS countries. March 27–28, 2017. London: Academy of Medical Sciences
- 5 Boyd CM, Fortin M. Future of multimorbidity research: how should understanding of multimorbidity inform health system design? *Public Health Rev* 2010;32:451–474
- 6 Frei H. Homeopathic treatment of multimorbid patients: a prospective outcome study with polarity analysis. *Homeopathy* 2015;104:57–65
- 7 Oberai P, Indira B, Varanasi R, et al. A multicentric randomized clinical trial of homeopathic medicines in fifty millesimal potencies vis-à-vis centesimal potencies on symptomatic uterine fibroids. *Indian J Res Homoeopathy* 2016;10:24–35
- 8 Kiruthiga S. Homeopathic *Thyroidinum* 3x—an adjuvant in the treatment of hypothyroidism. *Int J Complement Altern Med* 2018;11:00339
- 9 Quadri IJ, Ali MD, Vatsalya B, Ponnambam HB, Parveen S. Role of homeopathic medicines in treating uterine fibroid: a prospective observational study. *Ind J Res Homoeopathy* 2012; 6:8
- 10 Das KD, Ghosh S, Das AK, et al. Treatment of hemorrhoids with individualized homeopathy: an open observational pilot study. *J Intercult Ethnopharmacol* 2016;5:335–342
- 11 Witt CM, Lüdtke R, Baur R, Willich SN. Homeopathic treatment of patients with chronic low back pain: A prospective observational study with 2 years' follow-up. *Clin J Pain* 2009;25:334–339
- 12 Wadhwa B. A case report of fibroadenosis alleviated with homeopathy. *Indian J Res Homoeopath* 2017;11:196–202
- 13 Shukla P, Misra P, Jain RK, Misra RK. Successful homeopathic treatment of phyllodes tumour: a case study. *Homeopath Links* 2021;34:130–140
- 14 Mahesh S, Denisova T, Gerasimova L, Pakhmutova N, Mallappa M, Vithoulkas G. Multimorbidity after surgical menopause treated with individualized classical homeopathy: a case report. *Clin Med Insights Case Rep* 2020;13:1179547620965560
- 15 Fibert P. Case report of two siblings with multi-morbidities receiving homeopathic treatment for one year. *Eur J Integr Med* 2016;8:141–145
- 16 Chakma A, Sarangi MR. Homeopathic treatment of hepatic haemangioma with ovarian cyst. *Indian J Res Homoeopath* 2019; 13:244
- 17 Boericke W. Boericke's New Manual of Homeopathic Materia Medica with Repertory. Third Revised and Augmented Edition Based on Ninth Edition. New Delhi, India: B. Jain Publishers; 2010
- 18 Allen HC. Allen's Keynotes Rearranged and Classified with Leading Remedies of the Materia Medica and Bowel Nosodes. 10th Reprint Edition. New Delhi, India: B. Jain Publishers; 2006
- 19 Kent JT. Repertory of the Homeopathic Materia Medica. Reprinted from Sixth American Edition. New Delhi, India: B. Jain Publishers; 2009
- 20 van Haselen RA. Homeopathic clinical case reports: development of a supplement (HOM-CASE) to the CARE clinical case reporting guideline. *Complement Ther Med* 2016;25:78–85
- 21 Lamba CD, Gupta VK, van Haselen R, et al. Evaluation of the modified Naranjo criteria for assessing causal attribution of clinical outcome to homeopathic intervention as presented in case reports. *Homeopathy* 2020;109:191–197
- 22 Hahnemann Samuel. Organon of Medicine. Fifth and Sixth Edition, 26th Impression. New Delhi: B. Jain Publishers (P) Ltd.; 2010:242–244
- 23 Teut M, Lüdtke R, Schnabel K, Willich SN, Witt CM. Homeopathic treatment of elderly patients—a prospective observational study with follow-up over a two year period. *BMC Geriatr* 2010;10:10
- 24 Whitty CJM, MacEwen C, Goddard A, et al. Rising to the challenge of multimorbidity. *BMJ* 2020;368:l6964
- 25 Ong KY, Lee PSS, Lee ES. Patient-centred and not disease-focused: a review of guidelines and multimorbidity. *Singapore Med J* 2020; 61:584–590
- 26 Weiss CO, Varadhan R, Puhana MA, et al. Multimorbidity and evidence generation. *J Gen Intern Med* 2014;29:653–660
- 27 Pearson-Stuttard J, Ezzati M, Gregg EW. Multimorbidity—a defining challenge for health systems. *Lancet Public Health* 2019;4: e599–e600
- 28 Stoll CRT, Izadi S, Fowler S, et al. Multimorbidity in randomized controlled trials of behavioral interventions: A systematic review. *Health Psychol* 2019;38:831–839
- 29 Martin F, Susan SM. Improving the external validity of clinical trials: the case of multiple chronic conditions. *J Comorb* 2013; 3:30–35
- 30 Relton C, Torgerson D, O'Cathain A, Nicholl J. Rethinking pragmatic randomised controlled trials: introducing the “cohort multiple randomised controlled trial” design. *BMJ* 2010;340:c1066