



Posttraumatic Tension Pneumocephalus Causing Atropine-Resistant Bradycardia

Yagna M. Gali¹ Lakshman K. Kommula¹ Subba R. Kesavarapu² Shekhar R. Gurralla³

¹Department of Neuroanaesthesiology and Neuro Critical Care, Apollo Hospitals, Jubilee Hills, Hyderabad, Telangana, India

²Department of Critical Care Medicine, Apollo Hospitals, Jubilee Hills, Hyderabad, Telangana, India

³Department of Neuroanaesthesiology and Neuro Critical Care, Apollo Hospitals, Hyderabad, Telangana, India

Address for correspondence Yagna Munesh Gali, MD, Department of Neuroanaesthesiology and Neuro Critical Care, Apollo Hospitals, Jubilee Hills, Hyderabad, Telangana 500033, India (e-mail: gmunesh@gmail.com).

J Neuroanaesthesiol Crit Care 2022;9:204–206.

Abstract

Pneumocephalus is a serious complication following brain trauma. Tension pneumocephalus (TP) is entrapment of a large volume of air in the cranial vault causing mass effect on the brain parenchyma. It is the intracranial counterpart of tension pneumothorax and if neglected, can be life threatening. TP should be timely differentiated from benign pneumocephalus owing to its various nonspecific and lethal complications. Our patient is a 37-year-old male with a history of road traffic accident who presented to our hospital with headache and nasal discharge for the last two days. Computed tomography showed multiple skull fractures and extensive pneumocephalus. His preoperative heart rate was 38 beats per minute that was resistant to pharmacological interventions and required a temporary pacemaker for surgery. He underwent uneventful craniotomy for dura repair and was discharged home with no neurological deficit.

Keywords

- bradycardia
- pacemaker
- pneumocephalus

Introduction

Pneumocephalus is defined as the presence of air in the cranial vault. Neurotrauma is the most common cause accounting to around 75% of all cases presenting with pneumocephalus.¹ It is usually asymptomatic but may cause headache, nausea, vomiting, altered sensorium, and seizures. Rarely, it may progress to tension pneumocephalus (TP) causing focal neurological deficits, cranial nerve palsies, cardiac arrhythmias, and cardiac arrest.^{2,3} TP is a neurosurgical emergency and it may prove fatal if not managed urgently.

Case Report

A 37-year-old male with a history of road traffic accident presented to the emergency department with complaints of

headache and clear watery nasal discharge for last two days. He was conservatively managed in another hospital for head injury and laceration to the left eyebrow. On examination, he was conscious, coherent, and oriented to time, place, and person. Vital parameters were as follows—blood pressure: 130/80 mmHg, heart rate: 38/min, regular rhythm, oxygen saturation: 98% on 10L O₂ supplemented via face mask with a reservoir bag. On systemic examination, heart sounds were normal with no murmurs, lung sounds were normal with no added sounds, Glasgow Coma Scale (GCS) score was 15/15, and both pupils were normal in size and reacting to light. All biochemical parameters, especially serum electrolytes along with serum magnesium and serum calcium, were in normal range. On electrocardiogram (► Fig. 1), rhythm was sinus with a heart rate of 38/min and with no other abnormality. Echocardiography was normal. Computed tomography of the

article published online
December 17, 2022

DOI <https://doi.org/10.1055/s-0042-1751091>.
ISSN 2348-0548.

© 2022. Indian Society of Neuroanaesthesiology and Critical Care. All rights reserved.

This is an open access article published by Thieme under the terms of the Creative Commons Attribution-NonDerivative-NonCommercial-License, permitting copying and reproduction so long as the original work is given appropriate credit. Contents may not be used for commercial purposes, or adapted, remixed, transformed or built upon. (<https://creativecommons.org/licenses/by-nc-nd/4.0/>)

Thieme Medical and Scientific Publishers Pvt. Ltd., A-12, 2nd Floor, Sector 2, Noida-201301 UP, India

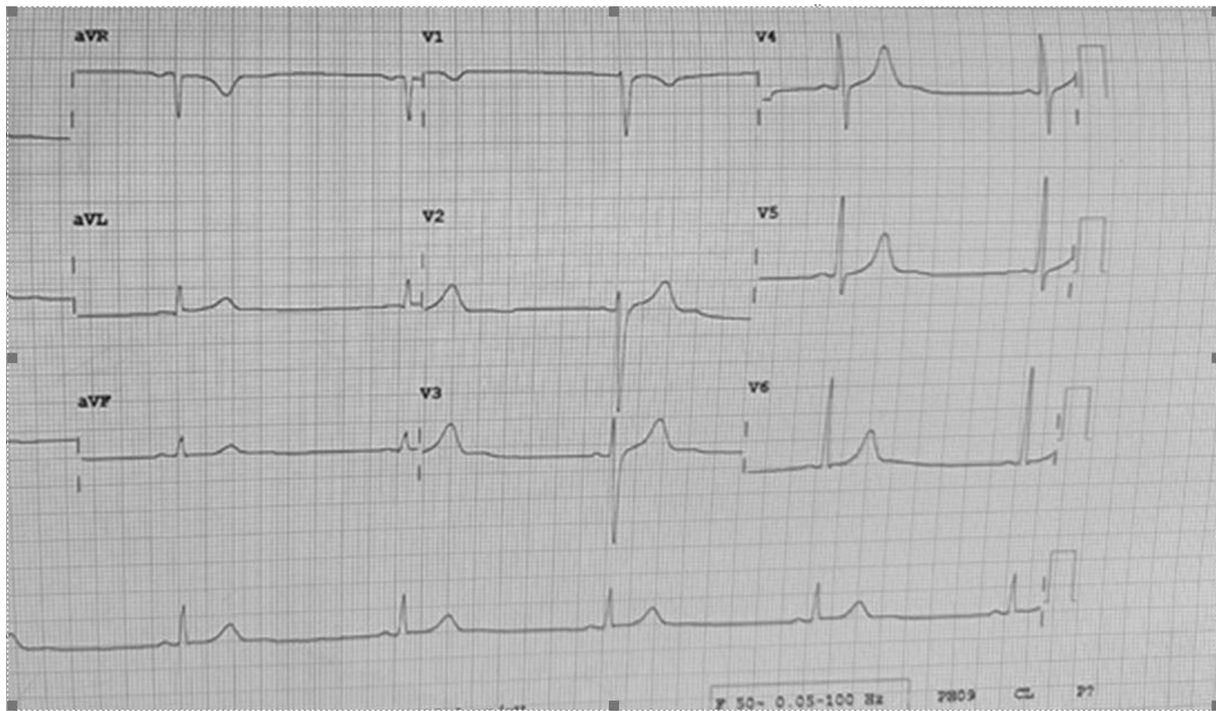


Fig. 1 Preoperative electrocardiogram.

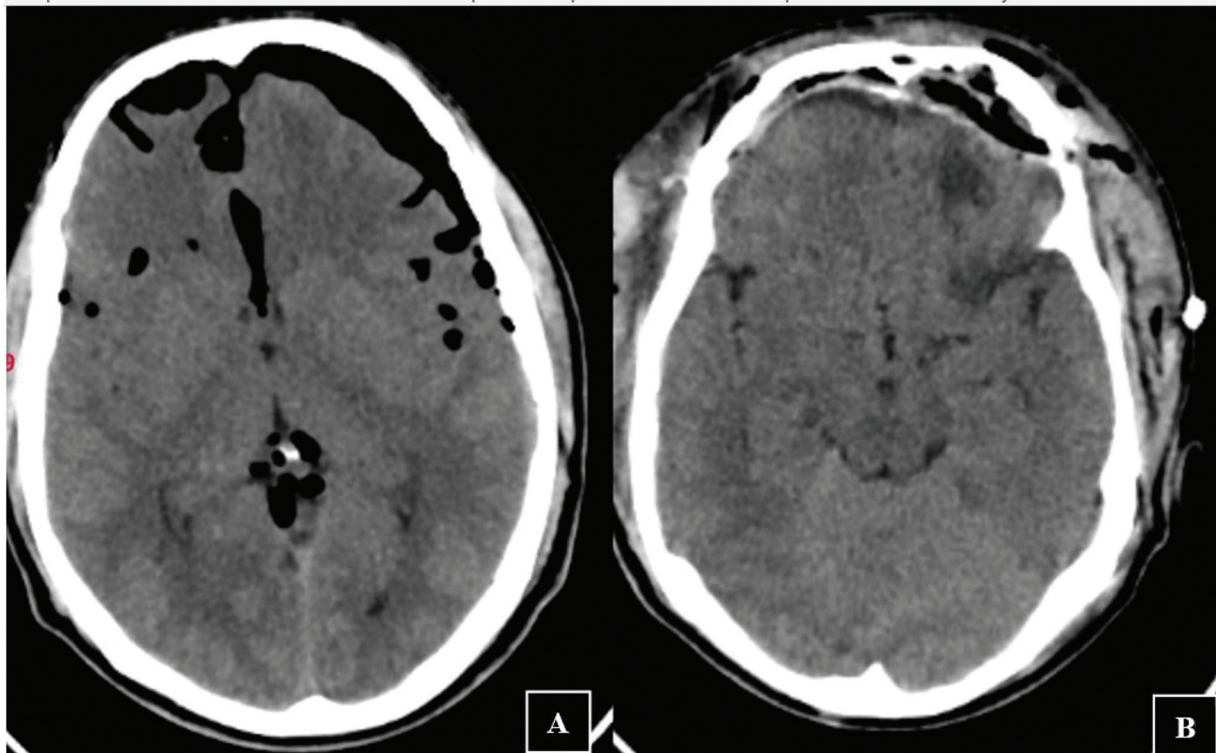


Fig. 2 (A) Preoperative and (B) postoperative computed tomographic images of the brain.

brain (►**Fig. 2A**) showed extensive pneumocephalus with fractures involving the left frontal bone, zygomatic arch, greater wing of the sphenoid, lateral wall of the maxillary sinus, lateral wall of the sphenoid sinus, walls of the posterior ethmoid air cells, roof, medial and lateral walls of the orbit,

and posterior table of the frontal sinus with pansinusitis. Multiple air pockets were noted in both the cerebral hemispheres, predominantly in the left cerebral hemisphere. Brain stem and cerebellum appeared normal. No evidence of midline shift was found. Owing to nonavailability of

facility to detect β_2 transferrin in nasal discharge, Pandey's test on the nasal fluid specimen was done. It was positive indicating cerebrospinal fluid (CSF) leak. No other major injuries were noted. Patient was planned for surgery. Preoperatively, bradycardia was initially managed in the neuro-intensive care unit with three bolus doses of intravenous Atropine 0.6 mg at an interval of 15 minutes between each bolus dose, one dose of intravenous Deriphyllin (2 mL containing Etofylline 170 mg and Theophylline 50 mg) and intravenous Isoprenaline infusion at 5 μ g/min. The maximum heart rate achieved was 48/min. The patient was finally inserted with a single-chamber temporary pacemaker in the right ventricle before taking up for surgery. The pacemaker was set in VVI (Ventricle pacing, Ventricle sensing, Inhibition response to sensing) mode with sensitivity of 1.5 mV, amplitude of 8 V, and pulse rate of 70/minute. Bifrontal craniotomy, extradural and intradural repair of the anterior cranial fossa along with trans-sphenoidal repair of the floor of the sella were done under general anesthesia. Intraoperatively, electrocardiogram, oxygen saturation, blood pressure, heart rate, end-tidal CO₂ concentration, and temperature were monitored. He remained hemodynamically stable during the entire surgical period. He was mechanically ventilated overnight postsurgery. He was extubated on the first postoperative day. Pacemaker rate was slowly reduced until his innate heart rate was consistently more than 60/min and removed on the second postoperative day. The patient was discharged with no neurological deficit after 7 days of hospital stay.

Discussion

The development of pneumocephalus has been explained by two plausible mechanisms. The Horowitz's inverted soda bottle mechanism involves CSF leak resulting from discontinuity of the cranium and leptomeningeal disruption. This subsequently causes a relatively negative intracranial pressure (ICP) and a vacuum effect drawing air into the cranium.⁴ The other mechanism described is the one-way valve or ball valve mechanism at the site of the leptomeningeal tear.⁵ Here, the positive endotympanic pressure exceeds the ICP and air is forced from the paranasal sinuses into the cranial cavity. Treatment of simple pneumocephalus involves 100% oxygen supplementation, placing the patient in 30 degrees Fowler's position, antibiotics, analgesics, and bed rest. Treatment of TP is done by drilling of burr holes, needle aspiration, and closure of dural defect.² The pressure exerted by the intracranial air upon the brain may lead to extra-axial mass effect with subsequent compression of the frontal lobe thus giving the "Mount Fuji appearance" on computed tomographic scan of the brain described by Sadeghian.⁶ The Mount Fuji sign is the diagnostic radiological feature of TP.⁷

In our case, resistant bradycardia may be the result of raised ICP due to pneumocephalus causing compression of

the brain stem and continuous vagal stimulation.⁸ Another likely explanation is the Cushing's reflex wherein the arterial blood pressure exceeds the ICP to restore blood flow to the brain. The increased arterial blood pressure stimulates the baroreceptors of carotid bodies, thus drastically slowing the heart rate.⁹

Once the extradural and intradural repair of the anterior cranial fossa and trans-sphenoidal repair of the sella floor was done, and the pneumocephalus reduced (**Fig. 2B**), heart rate improved to normal and therefore the pacemaker was no longer required for further management, hence removed.

Various case studies have been published on posttraumatic TP and its management.^{5,10} But the case described above is extremely rare wherein the patient presented with severe bradycardia resistant to multiple pharmacological interventions.

Conclusion

Persistent bradycardia resistant to pharmacological intervention can be a serious complication of posttraumatic TP and needs to be recognized early and given prime importance as it may prove fatal to the patient. Temporary pacemaker seems to be the only treatment modality for persistent bradycardia in these cases. Definitive management lies in surgical intervention to reduce the ICP caused by TP.

Conflict of Interest
None declared.

References

- 1 Dabdoub CB, Salas G, Silveira EdoN, Dabdoub CF. Review of the management of pneumocephalus. *Surg Neurol Int* 2015;6:155
- 2 Das M, Bajaj J, Pneumocephalus J. In: StatPearls. Treasure Island (FL): StatPearls Publishing; 2022
- 3 Thiagarajah S, Frost EA, Singh T, Shulman K. Cardiac arrest associated with tension pneumocephalus. *Anesthesiology* 1982; 56(01):73–75
- 4 Horowitz M. Intracranial pneumocele. An unusual complication following mastoid surgery. *J Laryngol Otol* 1964;78:128–134
- 5 Pillai P, Sharma R, MacKenzie L, et al. Traumatic tension pneumocephalus - two cases and comprehensive review of literature. *Int J Crit Illn Inj Sci* 2017;7(01):58–64
- 6 Sadeghian H. Mount Fuji sign in tension pneumocephalus. *Arch Neurol* 2000;57(09):1366
- 7 Heidari SF. A patient with massive pneumocephalus without sign of tension pneumocephalus. *J Intensive Crit Care* 2016;2:3
- 8 Faried A, Sendjaja AN, Melia R, Arifin MZ. Bradycardia without hypertension and bradypnea in acute traumatic subdural hematoma is a sensitive predictor of the Cushing triad: 3 case reports. *Interdiscip Neurosurg* 2016;6:84–86
- 9 Dinallo S, Waseem M. Cushing reflex. In: StatPearls. Treasure Island (FL): StatPearls Publishing; 2021
- 10 Kankane VK, Jaiswal G, Gupta TK. Posttraumatic delayed tension pneumocephalus: rare case with review of literature. *Asian J Neurosurg* 2016;11(04):343–347