



Long-Term Evaluation of the Lip and Nose in Bilateral Complete Cleft Lip Patients following Lip Adhesion and Secondary Nose Correction

Ryuck Seong Kim, MD¹  Hyung Joon Seo, MD^{1,2}  Min Suk Park, MD¹  Yong Chan Bae, MD, PhD^{1,2} 

¹Department of Plastic and Reconstructive Surgery, Pusan National University, School of Medicine, Busan, Korea

²Biomedical Research Institute, Pusan National University Hospital, Busan, Korea

Address for correspondence Yong Chan Bae, MD, PhD, Department of Plastic and Reconstructive Surgery, School of Medicine, Pusan National University, 179, Gudeok-ro, Seo-gu, Busan 49241, Korea (e-mail: baeyc2@hanmail.net).

Arch Plast Surg 2022;49:510–516.

Abstract

Background Surgical correction of bilateral cleft lip deformities remains one of the most challenging areas in facial plastic surgery. Many surgical techniques and conservative devices have been offered for the early management of bilateral cleft lip in infants. The purpose of this study was to evaluate the effect of lip adhesion on the lip and nose of patients with bilateral cleft lip.

Methods A retrospective review of 13 patients with bilateral cleft lip was performed and compared with age-matched noncleft children. Patients underwent lip adhesion at a mean age of 2.8 months, and cheiloplasty at 6.6 months of age using a modification the Mulliken method. Secondary rhinoplasty was performed at the age of 6 in 13 patients. The surgical results were analyzed using photographic records obtained at the age of 1 and 7 years. Twelve length measurements and one angle measurement were obtained.

Results All measurements were not statistically different from those of the noncleft age-matched control group at the age of 1. At 7 years of age, upper lip height and vermilion mucosal height were shorter ($p < 0.05$) than in the control group. Nasal tip protrusion and the nasolabial angle were greater ($p < 0.05$) than in the control group.

Conclusion Lip adhesion followed by secondary rhinoplasty resulted in an acceptable lip and nasal appearance. Although nasoalveolar molding is now widely used, lip adhesion can be an appropriate alternative if an orthodontist is not available due to geographical or economic constraints.

Keywords

- ▶ bilateral cleft lip
- ▶ lip adhesion
- ▶ secondary rhinoplasty

Introduction

Surgical correction of bilateral cleft lip deformities remains one of the most challenging areas in facial plastic surgery.^{1–4} Various methods to treat bilateral cleft lip and palates have been developed during the last few centuries. However, it is

difficult to obtain acceptable results in the shape of the lips and nose for patients with bilateral cleft lip with a wide cleft.

Recently, many surgical techniques and conservative devices have been offered for the early management of bilateral wide cleft lip in infants. Nasoalveolar molding (NAM) has been widely used in recent years as it provides

DOI <https://doi.org/10.1055/s-0042-1751106>.
ISSN 2234-6163.

© 2022. The Korean Society of Plastic and Reconstructive Surgeons. All rights reserved.

This is an open access article published by Thieme under the terms of the Creative Commons Attribution-NonDerivative-NonCommercial-License, permitting copying and reproduction so long as the original work is given appropriate credit. Contents may not be used for commercial purposes, or adapted, remixed, transformed or built upon. (<https://creativecommons.org/licenses/by-nc-nd/4.0/>)

Thieme Medical Publishers, Inc., 333 Seventh Avenue, 18th Floor, New York, NY 10001, USA

excellent cosmetic effects in infants with bilateral clefts through the nasal and labial philtrum format.⁵ However, these methods are complicated and expensive,⁶ and they often require an expert neonatal orthodontist and maximum cooperation from the child's parent.⁷ Therefore, if a hospital is far and visiting is difficult, or if the patient cannot afford medical expenses, an alternative method is warranted.

Lip adhesion (LA) has been one of the most used techniques since its introduction by Millard in 1964.⁸ LA is used for wide unilateral cleft lip or bilateral cleft lip, which is difficult to correct with a single cheiloplasty. This technique produces the same shape as an incomplete cleft lip by pulling the edges of both lips. Although there is a disadvantage of requiring additional surgery in addition to cheiloplasty, this technique can result in alignment of the alveolar segment, increase the orbicularis oris muscle length, and increase in the cutaneous lip height.⁶

In our hospital, among patients with a bilateral wide cleft lip, LA was performed before cheiloplasty in patients with geographical, economic, and time constraints. We report the long-term follow-up results of these patients.

Methods

Patients

Between 1998 and 2013, 13 patients who had a wide bilateral cleft lip with no other anomalies, who had undergone LA, and were able to be followed up for more than 7 years were enrolled. Patients with bilateral clefts underwent LA when the cleft was wide or for severe protrusion of the premaxilla, to reduce the gap between clefts and facilitate primary cheiloplasty. Of the 13 patients treated, 11 (six boys and five girls) had a complete bilateral cleft lip and two patients (two boys) had bilateral cleft lips with one side complete and the other incomplete (►Fig. 1).

Methods of Treatment

LA was performed in one stage on both sides (►Fig. 2), at a mean age of 2.8 months (range: 46–105 days). For patients

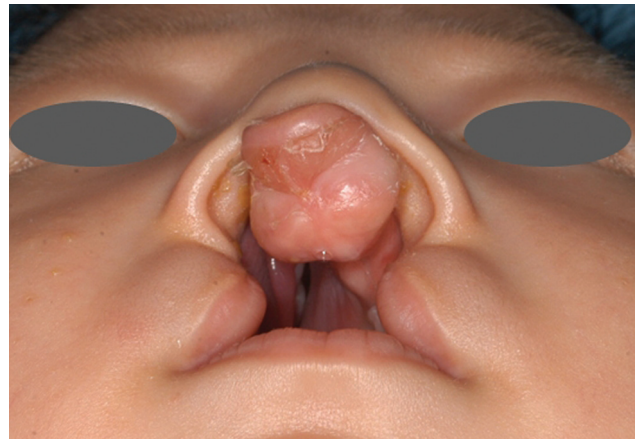

Fig. 1 Patients with bilateral wide clefts and severe protrusion of the premaxilla.

with one side complete and the other incomplete, LA was performed only on the side with the complete cleft. The cheiloplasty was performed using a modified Mulliken's cheiloplasty at a mean age of 6.6 months (range: 95–268 days). Eleven patients underwent secondary nasal reconstruction at a mean age of 6 years (range: 5.1–6.6 years).

An open rhinoplasty approach was used for secondary rhinoplasty. To improve the columellar lengthening and lobular projection, a V-shape design on the columella and a design for seagull-wing incision on both rims were implemented. Dissection was performed along the supra perichondrial plane to the keystone area, and the fibrous connection between the interdomal suspensory ligament and the scroll area was dissected to secure the mobility of the alar cartilage. Then, an interdomal fixation suture was performed with Ethilon 5–0. If necessary, the upper lateral cartilage and the dome of the alar cartilage were fixed with an absorbable plate (Osteotrans MX®, Takiron, Osaka, Japan) to prevent cephalic rotation of the nasal tip. Columella advanced the V-shape incision area into a Y-shape and lengthened the columella. Through a back cut in both vestibules, the internal valve was widened and the nasal lining

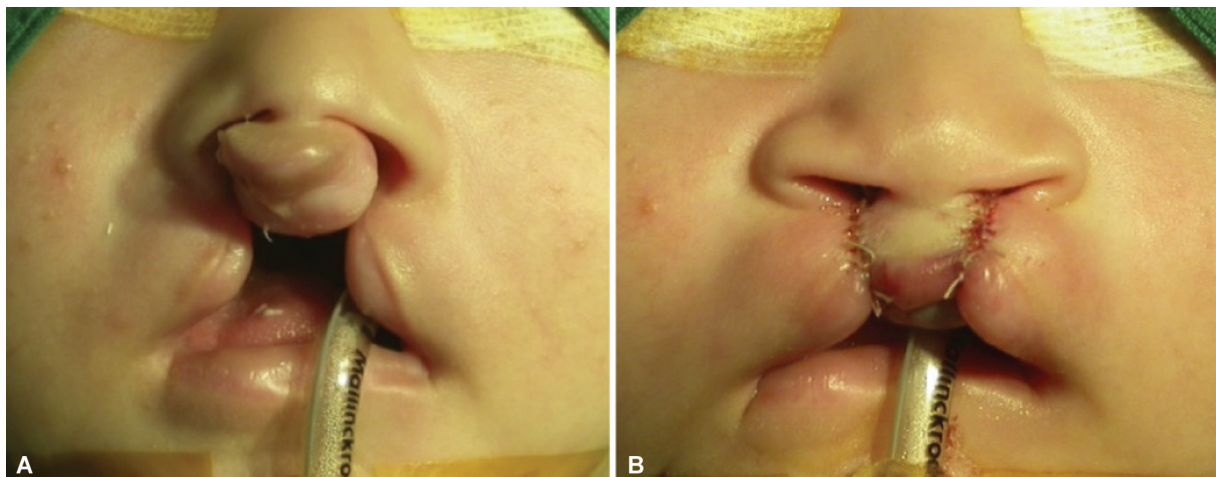


Fig. 2 (A) Preoperative photograph of a patients with bilateral cleft lip. (B) Immediate postoperative photograph of the same patient, following the adhesion procedure.

was medialized. The skin incision was then closed with 6–0 Prolene suture.

Methods of Examination

After LA followed by cheiloplasty, photos of 13 patients were obtained 1 year after the tissues stabilized. The control group included 13 age-matched patients who visited the division of plastic and reconstructive surgery at our hospital and did not have facial deformities.

Subsequent secondary rhinoplasty was performed at the age of 6 years and 1 year after the tissues were stabilized; we acquired pictures of 13 of these 7-year-old patients. The control group included 13 age-matched patients who visited the division of plastic and reconstructive surgery at our hospital and did not have facial deformities. Length, symmetry, and angle of the lip and nose were assessed through photometric measurements.

Photometric Measurements

A photometric measurement technique was used to assess the lip and nose in the patient and control groups. Photographs of frontal, lateral, and basilar views were used to evaluate the length, symmetry, and nasolabial angle of the lip and nose. Additionally, the sizes of the frontal view and basilar view photographs were standardized based on the intercanthal distance to reduce magnification errors. Afterward, each measured value was expressed as a ratio to the intercanthal distance. The average Schendel⁹ intercanthal distance of patients with their corresponding age was multiplied by the ratio, and the actual length was expressed in mm:

$$\text{Actual length} = \frac{\text{Photometric length}}{\text{Photometric intercanthal distance}} \times \text{Farkas intercanthal distance}$$

In the 13 patients who were approximately 1 year old at 1 year after lip-repair surgery, eight photometric measurements, including the upper lip height, cutaneous lip height, vermilion mucosal height, upper philtral width, lower philtral width, alar base width (ABW) ratio, columella peak height (CPH) ratio, and lip width ratio, were performed to assess the upper lip.

In the 13 patients who were approximately 7 years old at 1 year after secondary rhinoplasty, nasal width (al-al), nasal tip protrusion (Sn-prn), columellar length (Sn-c), columella width, and nasolabial angle were measured, in addition to the above measurements, to assess the nose (**Fig. 3**).

Labial measurements:

1. Upper lip height (sn-sto)
2. Cutaneous lip height (sn-ls)
3. Vermilion mucosal height (ls-sto)
4. Upper philtral width (cphs-cphs)
5. Lower philtral width (cphi-cphi)
6. ABW ratio (sn-al/sn-al)
7. CPH ratio (sn-cphi/sn-cphi)
8. Lip width ratio (cphi-ch/cphi-ch)

Nasal measurements:

9. Nasal width (al-al)
10. Nasal tip protrusion (sn-prn)
11. Columella length (sn-c)
12. Columella width (sn'-sn')
13. Nasolabial angle

Statistical Analysis

All results are reported as mean ± standard deviation. A Wilcoxon rank-sum test was used for statistical comparisons with the age-matched control group. A *p*-value < 0.005 was considered statistically significant.

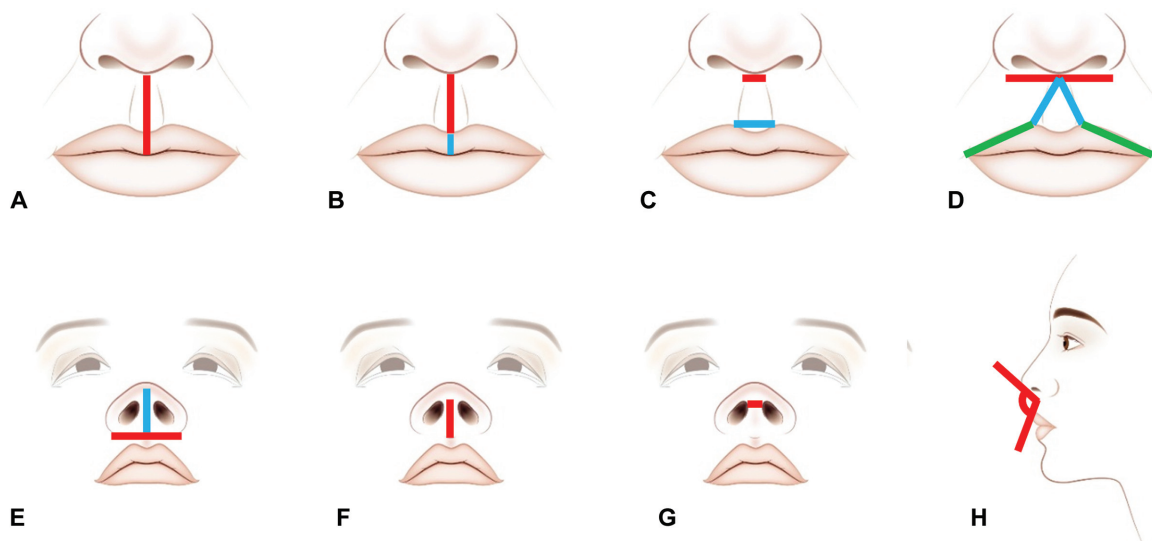


Fig. 3 Photographic measurements of the nasolabial region (A) red line: upper lip height; (B) red line: cutaneous lip height, blue line: vermilion mucosal height; (C) red line: upper philtral width, blue line: lower philtral width; (D) red line: alar base width ratio, blue line: columella peak height ratio, green line: lip width ratio; (E) red line: nasal width, blue line: nasal tip protrusion; (F) red line: columella length; (G) red line: columella width; (H) nasolabial angle.

Table 1 Postoperative anthropometry compared with age-matched controls

At 1 year	Lip adhesion	Control	p-Value
Upper lip height, mm	14.08	14.07	0.801
Cutaneous lip height, mm	8.91	9.21	0.264
Vermilion mucosal height, mm	5.95	4.64	0.057
Upper philtral width, mm	5.32	4.82	0.362
Lower philtral width, mm	6.1	6.53	0.243
ABW ratio	0.95	0.95	0.614
CPH ratio	0.95	0.97	0.081
Lip width ratio	0.94	0.93	0.880
At 7 years	Lip adhesion	Control	p-value
Upper lip height, mm	9.7	11.47	0.023 ^a
Cutaneous lip height, mm	6.02	5.46	0.519
Vermilion mucosal height, mm	14.83	17.5	0.040 ^a
Upper philtral width, mm	5.84	5.78	0.562
Lower philtral width, mm	6.29	7.82	0.007 ^a
ABW ratio	0.96	0.98	0.270
CPH ratio	0.94	0.97	0.217
Lip width ratio	0.91	0.94	0.270
Nasal width, mm	28.78	29.27	0.606
Nasal tip protrusion, mm	15.85	12.33	0.007 ^a
Columella length, mm	7.5	5.66	0.019 ^a
Columella width, mm	7.43	7.15	0.847
Nasolabial angle, degrees	129.4	111.8	0.034 ^a

Abbreviations: ABW, alar base width; CPH, columella peak height.

^a $p < 0.05$.

Results

The results of the study were summarized in **Table 1**.

Upper Lip Height (sn-sto)

The mean upper lip height measured at 2 years of age was 14.48 ± 2.01 and 14.40 ± 1.12 mm in the patient and control groups, respectively; no statistical difference was observed between the two groups. However, the mean upper lip height measured at 7 years of age was 9.11 ± 2.37 mm in the patient group and 11.78 ± 2.32 mm in the control group; this difference was statistically significant ($p < 0.05$).

Cutaneous Lip Height (sn-ls)

The mean cutaneous lip height measured at 2 years of age was 8.70 ± 2.02 and 9.60 ± 1.56 mm in the patient and control groups, respectively; there was no statistical difference between the two groups. The mean cutaneous lip height measured at 7 years of age was 6.04 ± 1.31 and 5.64 ± 1.58 mm in the patient and control groups, respectively; no statistical difference was observed between the two groups.

Vermilion Mucosal Height (ls-sto)

The mean vermilion mucosal height at 2 years of age was 5.66 ± 1.22 and 4.70 ± 1.02 mm in the patient and control

groups. Although the difference was not statistically significant, the vermilion mucosal height in the patient group was greater. The vermilion mucosal height at 7 years of age was a mean of 15.19 ± 2.33 and 17.32 ± 1.88 mm in the patient and control groups, respectively. The vermilion mucosal height at 7 years of age was significantly smaller in the patient group than in the control group.

Upper Philtral Width (cphs-cphs) and Lower Philtral Width (cphi-cphi)

Both upper and lower philtral widths at the age of two were not significantly different between the two groups. However, the lower philtral width at the age of 7 was significantly narrower in the patient group.

ABW Ratio, CPH Ratio, and Lip Width Ratio (cphi-ch)

ABW, CPH, and lip width ratios were not significantly different between the two groups at 2 and 7 years of age.

Nasal Width (al-al)

The nasal width at 7 years of age was a mean of 29.93 ± 2.66 and 29.20 ± 2.06 mm in the patient and control groups, respectively. The difference in the nasal width between the two groups was not significant.

Nasal Tip Protrusion (sn-prn)

At 7 years of age, the mean nasal tip protrusion was 14.89 ± 3.07 and 12.63 ± 1.78 mm in the patient and control groups, respectively. Moreover, the columella height protrusion was 7.52 ± 2.69 mm in the patient group and 5.40 ± 1.30 mm in the control group. Nasal tip protrusion and columella height were significantly greater in the patient group who received secondary rhinoplasty ($p < 0.005$).

Columella Width (sn'-sn')

The mean columella width measured at 7 years of age was 7.12 ± 1.07 and 7.34 ± 0.49 mm in the patient and control groups, respectively; the columella width was not significantly different between the groups at 7 years of age, 1 year after secondary rhinoplasty.

Nasolabial Angle

The mean nasolabial angle at 7 years of age was 123.99 ± 16.49 and 107.97 ± 14.39 degrees in the patient and control groups, respectively, and was significantly greater in the patient group that received secondary rhinoplasty than in the control group.

Discussion

In this retrospective observational study, we followed up patients with bilateral cleft lip with a wide cleft who underwent LA and secondary rhinoplasty for a period of 7 years and found that satisfactory results for lip and nose length and symmetry were obtained (→ Fig. 4). Bilateral complete cleft lip is usually accompanied by various deformations, such as wide defects of the upper lip, severe nasal deformity, wide alveolar bone defects, and alveolar arch protrusion.¹⁰⁻¹³ Therefore, severe dysmorphia of the face, maxillary growth disorder, and functional disorder of the teeth may occur when appropriate treatment is not provided in the early stages. Millard⁸ reported that presurgical orthodontics and LA before primary cheiloplasty are two important methods in cleft treatment

protocols. After these methods, the surrounding soft and skeletal tissues move closer to the normal position, which facilitates primary cheiloplasty and rhinoplasty.¹⁴

LA has, however, received criticism in published papers. Bardach et al¹⁵ described the “far superior” subjective results of single-step cheiloplasty, referring to the risks of additional surgery in LA, the possibility of postoperative complications, and the burden of additional surgical costs. However, satisfactory surgical results in bilateral cleft lip with a wide cleft are difficult to obtain with a single-step lip closure, and presurgical orthodontics and LA may lead to better outcomes.¹⁴

In this study, there was no difference in the symmetry and length of the upper lip measured 1 year after cheiloplasty, between patients with bilateral complete cleft lip and healthy control patients, which was consistent with the findings of previous studies.^{16,17} However, scars of the mucocutaneous, vermilion, and/or muscular regions after surgery could lead to differences in growth of the nose and lips between the patient and control groups (→ Fig. 5). This may cause the symmetry and length of the upper lip to differ between the patient and healthy control groups. Therefore, long-term follow-up of patients is essential.

In a study by Kim and Mulliken¹⁶ reporting the long-term assessment of patients with bilateral cleft lip, it was observed that the growth of the philtral height was relatively reduced compared with the control group, and as a result, the total upper labial height was slightly less than the average. In the current study, upper lip height at 1 year of age was not significantly different between the two groups. However, at 7 years of age, the upper lip height was shorter than that observed in the control group. This difference was caused by the shorter vermilion mucosal height in the patient group compared with the control group, which opposes the findings of previous studies where the total upper labial height was shorter due to a lack of philtral height. In this study, additional surgeries such as augmentation of the median tubercle, thought to be one of the causes of shorter vermilion mucosal height, were not performed. Therefore, it is

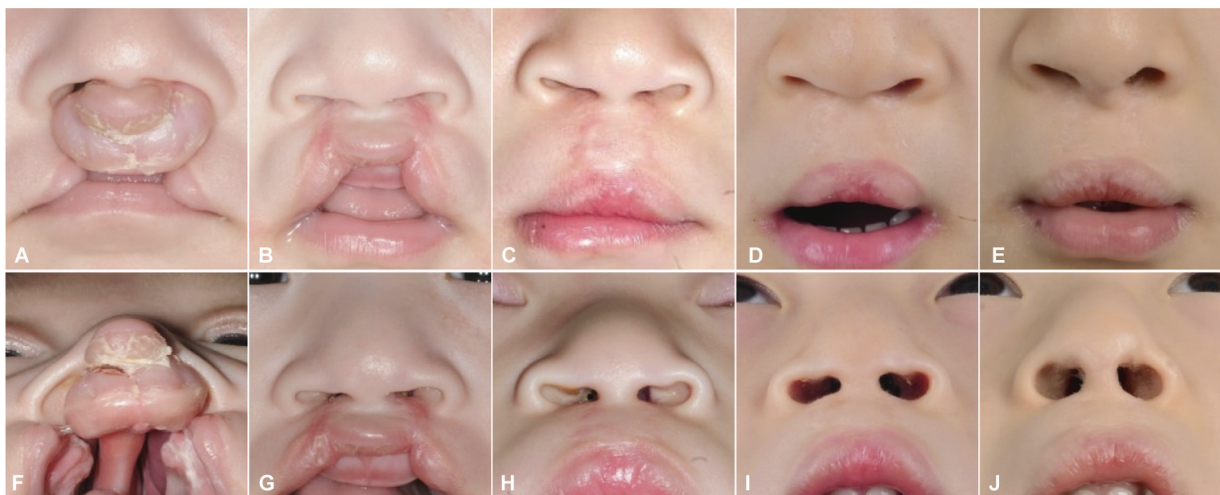


Fig. 4 Frontal (above) and basilar (below) view photographs of patient 6: (A, F) preoperative photos of the patient with bilateral complete cleft lip; (B, G) 1 month after lip adhesion; (C, H) 1 year after modified Mulliken's cheiloplasty; (D, I) before secondary nose correction at around 6 years of age; (E, J) 1-year after secondary nose correction at around 7 years of age.

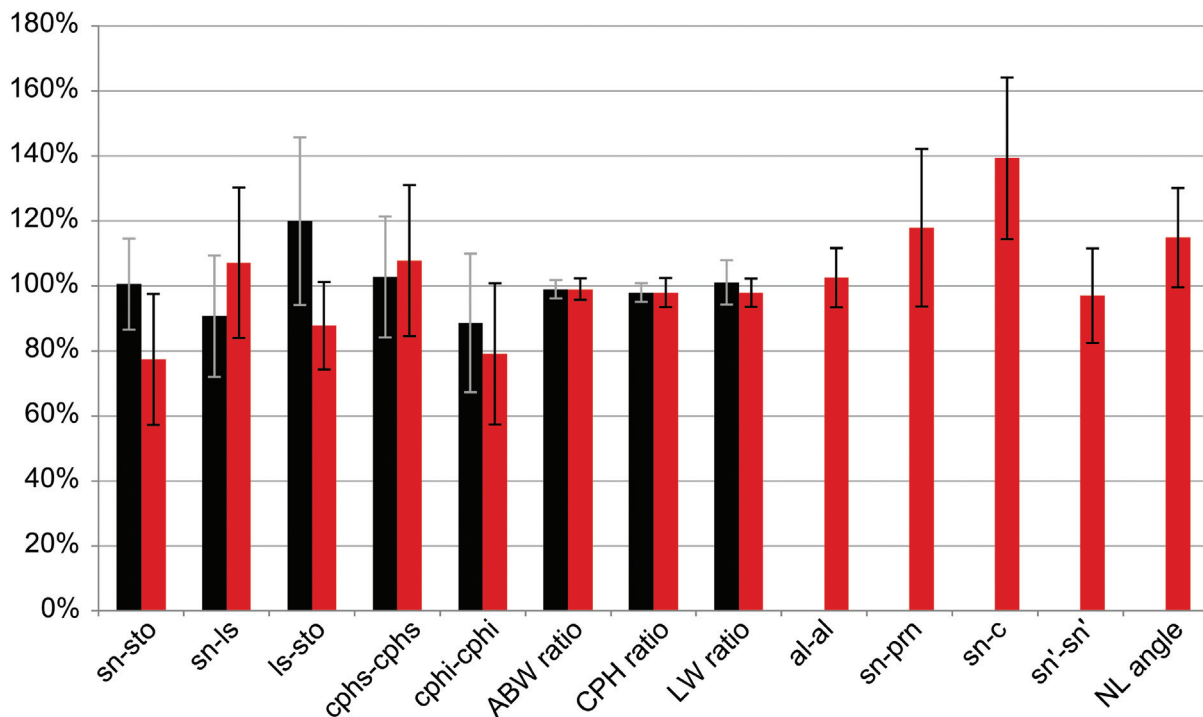


Fig. 5 Length and angle of lip and nose measured 1 year (black) and 7 years (red) after surgery. Data are expressed as percentages of Farkas's normal values ($100\% \pm 1$ standard deviation). sn-sto, upper lip height; sn-ls, cutaneous lip height; ls-sto, vermilion mucosal height; cphs-cphs, upper philtral width; cphi-cphi, lower philtral width; ABW, alar base width; CPH, columella peak height; LW, lip width; al-al, nasal width; sn-prn, nasal tip protrusion; sn-c, columella length; sn'-sn', columella width; NL, nasolabial.

recommended to use the full height of the vermilion mucosal height, to ensure that it is as plump as possible for the subsequent cheiloplasty. Moreover, although not performed in this study, augmentation of the median tubercle with a dermal graft may help to correct the upper lip height.¹⁵

Upper philtral widths measured at 2 years of age after cheiloplasty were similar between the two groups. Similarly, the lower philtral width was slightly narrower in the patient group compared with the control group, and the difference was not significant. However, at 7 years of age, the upper philtral width of the patient group was greater than that of the control group. In contrast, the lower philtral width was narrower in the patient group than in the control group. Differences between the two groups were significant. In a study by Kim et al,¹⁷ upper and lower philtral widths were maintained within the normal range after surgery and subsequent growth. Additionally, growth of the upper philtral width was faster than that of the lower philtral width. The current study demonstrated a similar tendency in the control group; however, growth of the lower philtral width was lacking in the patient group. Therefore, if the shape of the philtral flap is over-corrected by designing the philtral flap of the columellar-labial junction narrower than the desired width, and the peaks of Cupid's bow are wider than the desired width, better results would be obtainable.

Mulliken and Kim¹⁸ described that nasal deformities were clearly identified in the complete cleft lip rather than in the incomplete cleft lip, and recently, NAM has been used to increase columella length and nasal protrusion. In the current study, secondary rhinoplasty was performed once,

around 6 years after cheiloplasty, without using a presurgical device. One year after the surgery, the columella height of the patient group was significantly greater than that of the control group. Therefore, this technique seems to be beneficial for achieving columellar lengthening. Furthermore, nasal tip protrusion and columellar length are slow-growing dimensions. It is recommended to overlengthen them and conduct additional follow-up. However, it should be noted that the nasolabial angle may increase due to surgery.¹⁷

Although preoperative NAM is widely used in infants with bilateral cleft lip, it also has many drawbacks, which are the time required for follow-up after NAM, additional costs incurred in this process, and complications that may occur with NAM.¹⁹ A study on the complications of NAM reported that 30% of patients did not comply with continuous outpatient appointments, and complications were observed in 10% of patients who were undergoing NAM.¹⁹ Additionally, in a previous study, dehiscence rates after LA were estimated at 4 to 7%.⁶ In this study, wound dehiscence was observed in one patient (7.6%) from the patient group, and reoperation was conducted 1 week after its occurrence. The patient was then treated in accordance with the protocol of the hospital and recovered without any abnormalities. We suggest that LA with secondary rhinoplasty could overcome some of the obstacles encountered in the application of preoperative NAM.^{16,18}

In this study, the surgical results were evaluated by retrospectively analyzing two-dimensional photos, which can lead to errors. To compensate for those errors, the author had set a standard technique for shooting pictures and for the selection of pictures after shooting them. When shooting in

the frontal and basilar views, two imaginary lines connecting the medial canthus and both tragiions were set to be parallel with the horizontal line of the view finder. During subsequent photo selection, we checked whether the parallelism was good; moreover, a vertical line was drawn from the midpoint of the medial canthal line to select a photo at a similar distance from both the tragiions. In lateral view, where the cilia of the upper eyelid on one side overlapped with that on another side, the picture was taken so that the line connecting the midpupil and cheilion was parallel to the perpendicular line of the view finder. When selecting a photo, these points were considered and checked. Photoshop 9.0 (Adobe Systems Inc, San Jose, CA) was used for photo verification and correction after shooting.

This study has several limitations. First, data on the specific age were not obtained for all patients, and data obtained were not continuous due to the long study period. Furthermore, the measurements obtained were limited to Asian patients. Third, photogrammetry was used to assess patient data. Studies have shown that reliable data can be obtained using photogrammetry.^{20,21} However, it is important to note that photogrammetry is limited in presenting accurate measurement values, although it can reliably measure ratios. Finally, follow-up was only performed for up to 1 year after secondary rhinoplasty, and subsequent adolescent nose growth could not be evaluated. Therefore, this needs to be confirmed with additional long-term follow-up.

Author Contributions

Y.C.B. conceptualized the study. R.S.K. was involved in writing—review and editing. M.S.P. wrote the original draft. H.J.S. contributed to writing—review and editing.

Ethical Approval

The study was approved by the Institutional Review Board of Pusan National University Hospital (IRB No. 2102–023–100).

Patient Consent

Written informed consent was obtained from all the patients.

Funding

This work was supported by a clinical research grant from Pusan National University Hospital in 2022.

Conflict of Interest

None declared.

References

- Byrd HS, Ha RY, Khosla RK, Gosman AA. Bilateral cleft lip and nasal repair. *Plast Reconstr Surg* 2008;122(04):1181–1190
- Chung KH, Lo LJ. One-stage versus two-stage repair of asymmetric bilateral cleft lip: a 20-year retrospective study of clinical outcome. *Plast Reconstr Surg* 2018;141(05):1215–1224
- Patel TA, Patel KG. Comparison of the fisher anatomical subunit and modified Millard rotation-advancement cleft lip repairs. *Plast Reconstr Surg* 2019;144(02):238e–245e
- Zaidi SH, Rehman JU, Rahman HU, Ahmed N. Lip adhesion- a viable alternative to pre-surgical orthodontics for the management of wide cleft lips in third world countries. *J Ayub Med Coll Abbottabad* 2018;30(02):171–174
- Raposo-Amaral CE, Denadai R, Almeida RRG, Marques FF, Lee MM, Raposo-Amaral CA. Does a premaxillary setback and lip adhesion have a negative impact on lip outcome in bilateral cleft patients? *J Craniofac Surg* 2017;28(07):1730–1736
- Gatti GL, Lazzeri D, Romeo G, Balmelli B, Massei A. Effect of lip adhesion on maxillary arch alignment and reduction of a cleft's width before definitive cheilognathoplasty in unilateral and bilateral complete cleft lip. *Scand J Plast Reconstr Surg Hand Surg* 2010;44(02):88–95
- Kalanzi EW, Gatti GL, Massei A. The role of lip adhesion in the treatment of cleft lips. *East Cent Afr J Surg* 2004;9:61–66
- Millard DRJ Jr. Refinements in rotation-advancement cleft lip technique. *Plast Reconstr Surg* 1964;33:26–38
- Schendel SA. Anthropometry of the head and face. *Plast Reconstr Surg* 1995;96:480
- Garfinkle JS, King TW, Grayson BH, Brecht LE, Cutting CB. A 12-year anthropometric evaluation of the nose in bilateral cleft lip-cleft palate patients following nasolabial molding and cutting bilateral cleft lip and nose reconstruction. *Plast Reconstr Surg* 2011;127(04):1659–1667
- Chang CS, Liao YF, Wallace CG, et al. Long-term comparison of the results of four techniques used for bilateral cleft nose repair: a single surgeon's experience. *Plast Reconstr Surg* 2014;134(06):926e–936e
- Aburezq H, Daskalogiannakis J, Forrest C. Management of the prominent premaxilla in bilateral cleft lip and palate. *Cleft Palate Craniofac J* 2006;43(01):92–95
- Iino M, Sasaki T, Kochi S, Fukuda M, Takahashi T, Yamaguchi T. Surgical repositioning of the premaxilla in combination with two-stage alveolar bone grafting in bilateral cleft lip and palate. *Cleft Palate Craniofac J* 1998;35(04):304–309
- Rogers BO. Cleft craft: the evolution of its surgery, vol 2: bilateral and rare deformities. *JAMA* 1978;240:1282
- Bardach J, Salyer KE, Randall P. Surgical techniques in cleft lip and palate. Second Edition. *Plast Reconstr Surg* 1992;90(01):130
- Kim DC, Mulliken JB. Direct anthropometry of repaired bilateral complete cleft lip: a long-term assessment. *Plast Reconstr Surg* 2017;140(02):326e–332e
- Kim SK, Kim TH, Park SS, et al. Surgical treatment of the unilateral and bilateral cleft lip patients using Mulliken method: 10 year results. *Arch Craniofac Surg* 2012;•••:13
- Mulliken JB, Kim DC. Repair of bilateral incomplete cleft lip: techniques and outcomes. *Plast Reconstr Surg* 2013;132(04):923–932
- Levy-Bercowski D, Abreu A, DeLeon E, et al. Complications and solutions in presurgical nasolabial molding therapy. *Cleft Palate Craniofac J* 2009;46(05):521–528
- Nechala P, Mahoney J, Farkas LG. Digital two-dimensional photogrammetry: a comparison of three techniques of obtaining digital photographs. *Plast Reconstr Surg* 1999;103(07):1819–1825
- Ferrario VF, Sforza C, Serrao G, Ciusa V, Dellavia C. Growth and aging of facial soft tissues: a computerized three-dimensional mesh diagram analysis. *Clin Anat* 2003;16(05):420–433