


Closed Traumatic Avulsion of Both Flexor Digitorum Tendons: An Addition to the Leddy and Packer Classification and Review of the Literature

Conor Cuggy¹  Jack F.C. Woods¹ Emma Carr¹ Natalie Jumper¹ Nicola Lynch¹ Roisin Dolan¹

¹ Plastic and Reconstructive Surgery Unit, St. Vincent's University Hospital, Dublin, Ireland

Address for correspondence Conor Cuggy, MB, BCH, BAO, MCh, Plastic and Reconstructive Surgery Unit, St. Vincent's University Hospital, Dublin 4, Co. Dublin, Ireland (e-mail: conorcuggy@rcsi.com).

J Hand Microsurg

Abstract

Objective We encountered the case of a patient who presented with an avulsion of both flexor digitorum profundus (FDP) and flexor digitorum superficialis (FDS) tendons from their respective insertion in the ring finger. We aim to discuss the novel treatment of this injury pattern in the context of all previously encountered cases in the literature.

Materials and Methods We examined the case of our patient with avulsion of both flexor tendons in the same finger and discuss the novel method of treatment in our case. Additionally, we performed a literature review of all previous reported cases and discuss the treatment modalities and outcomes associated with each.

Results We have shown a novel and successful treatment technique for avulsion of both the FDP and FDS tendons. We identified twelve other cases of this injury pattern and have compared all outcomes documented.

Conclusion Closed tendon avulsion of both flexor tendons in the same finger is rare. We described a case and additionally propose a modification to the flexor tendon avulsion classification to incorporate this injury pattern and aid its management.

Keywords

- ▶ anchor reinsertion
- ▶ FDP and FDS avulsion
- ▶ FDP avulsion
- ▶ Leddy and Packer classification

Introduction

Closed tendon avulsion is a well-documented injury in hand surgery literature.^{1,2} Avulsion of the flexor digitorum profundus (FDP), also called “jersey finger” is classically caused by forced hyperextension against a fully flexed finger. It is seen commonly in contact sports, mainly in the context of a player grasping his opponents' shirt with the tip of his finger, while the opponent is running away.

However, closed avulsion of the flexor digitorum superficialis (FDS) tendon associated with an avulsion of the FDP tendon is a rare occurrence without preexisting pathology. It can occur at the insertions or at the midsubstance of the tendons. Only 14 cases in 12 hands of closed ruptures of both FDS and FDP tendons from their insertions have been reported since the first series in 1960.³⁻¹⁰ A further six cases have been reported of rupture in the midsubstance of both tendons.¹¹⁻¹⁴

We encountered an unusual case of closed avulsion of both flexor tendons of the ring finger with rupture of the FDP and FDS tendons, both from their respective sites of insertion. This is the most recent reported combination of this rare presentation. We will present our case, review the literature, and present our treatment strategy.

Case Report

A right hand dominant 27-year-old male, with no past medical history and no regular medications presented to the emergency department immediately after a Gaelic Athletic Association Hurling match with no ability to flex the ring finger of his left hand. Hurling is a sport of Irish origin in which players hit a small ball with wooden sticks and is a contact sport that involves tackling. This player had been involved in an altercation during the game and reported

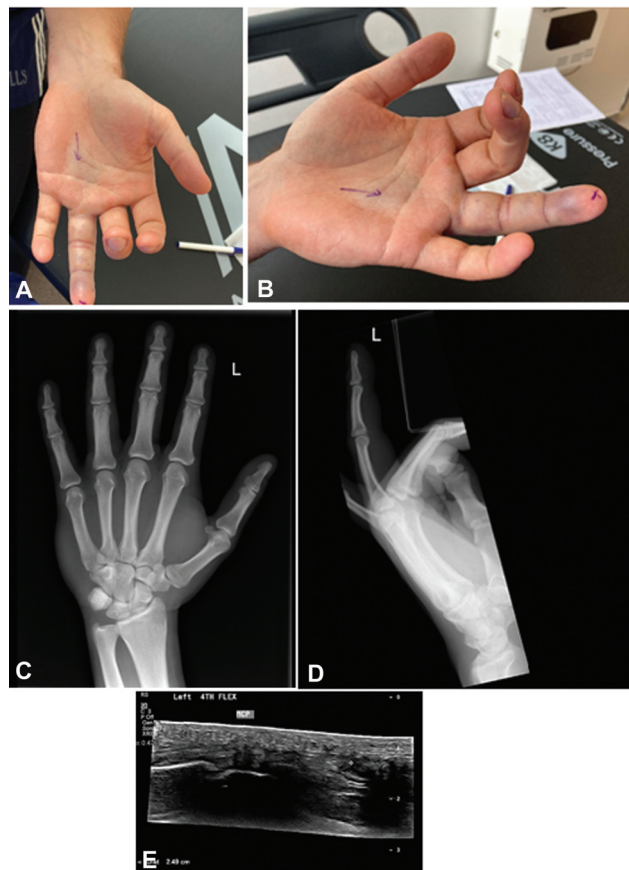


Fig. 1 (A, B) Clinical presentation. (C, D) X-ray images at presentation with no bone avulsion injury. (E) US images showing a reported 2.49-cm gap in the FDP tendon. FDP, flexor digitorum profundus; US, ultrasound.

catching his left ring finger in his opponent's jersey during the incident. He reported immediately feeling pain and subsequent swelling within a few minutes of the incident.

On examination, he had a swollen and tender ring finger which was held in extension at rest with an abnormal

cascade. Isolating both the FDS and FDP, he could actively flex neither the distal nor proximal interphalangeal joint; however, normal passive range of motion was preserved. Additionally, he had a palpable mass just proximal to the level of the A1 pulley, suggesting the presence of one or both flexor tendons in zone III. There was no bony injury seen on radiographs of his hand. His clinical presentation and radiographs can be seen in ►**Fig. 1**.

Clinical judgement led us to believe that there was an FDP avulsion, associated with a possible FDS rupture. Given the rarity of this presentation, an ultrasound scan was performed. This reported an FDP avulsion that had retracted 2.5-cm proximal to the metacarpophalangeal joint (MCPJ) but suggested that the FDS tendon was still intact.

Surgical exploration with Bruner's incisions, as shown in ►**Fig. 2**, was performed the following day, demonstrating an avulsion of both the FDP and FDS tendons from their points of insertion. No previous trauma or other pathology could explain this double rupture. We also noted a rupture of the A4 pulley with both volar plates being intact.

Both tendons were retrieved from the palm with a pediatric nasogastric tube and 3-0 Prolene, to preserve the remaining pulley system. The two FDS tendon slips were reattached to their sites of insertion in the middle phalanx using two micro-Mitek suture anchors (DePuy Synthes) with a modified Kessler suture. The FDP tendon was replaced to its anatomical position through the chiasm and inserted into the base of the distal phalanx also with two micro-Mitek suture anchors with hemi-Adelaide's to each slip.¹⁵ A 5-0 p-dioxanone (PDS) epitendinous suture from the FDP tendon to the distal phalanx periosteum was also performed. The A4 pulley was not repaired as the remaining pulley system was intact and no bowstringing was encountered. The patient was dressed and placed in a dorsal blocking splint in the intrinsic plus position¹⁶ post-operatively following closure with nonabsorbable sutures. Both tendons had good glide intraoperatively, with no gapping.

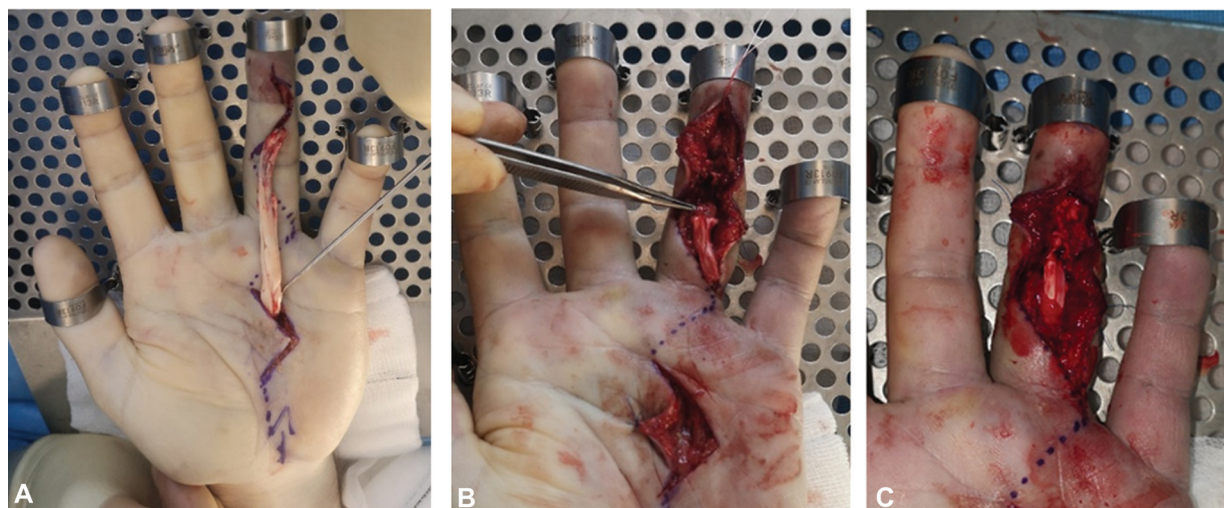


Fig. 2 (A) Tendons retrieved proximally. (B) FDS repaired at insertion, as indicated by the forceps. This FDP is turned backward and overlies the A2 pulley to show the insertion of the FDS tendon. (C) Both FDS and FDP tendons repaired before skin closure. FDP, flexor digitorum profundus; FDS, flexor digitorum superficialis.

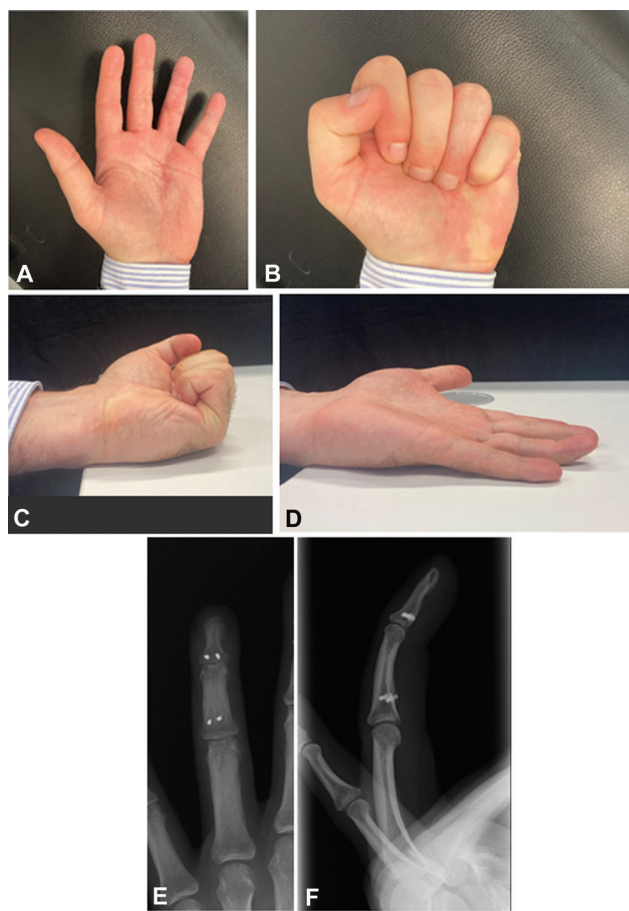


Fig. 3 (A–D) Clinical outcome after completion of 12 months of follow-up. (E, F) X-ray outcome at completion of 12 months of follow-up.

He started early active mobilization protocol as per the Manchester Rehabilitation Protocol¹⁷ for flexor tendon lesions at day 3 with the hand therapists. At this stage, he was also changed to a thermoplastic dorsal Duran splint.

Follow-up at 13 weeks showed that the patient was able to achieve flexion to the midpalmar crease and range of motion of the MCPJ of 0 of 100, proximal interphalangeal joint (PIPJ) of –8 of 98, and distal interphalangeal joint (DIPJ) of –6 of 40. The contralateral finger had range of motion of MCPJ grip strength that was 58% of the contralateral side. The patient returned to low manual stress work after completing 8 weeks of rehabilitation and to high-level sports training after completion of week 12. There were no limitations in activities of daily living. Clinical and imaging outcomes can be seen in ►Fig. 3.

Discussion

Closed rupture of both digital flexor tendons is a rare occurrence, with the described mechanism of injury varying greatly in the literature. We report a case of a closed FDP and FDS tendon avulsion injury following forced hyperextension against a flexed finger (“classic” jersey finger). This patient presented early and was appropriately clinically assessed. An exploration and repair was undertaken on the second day after the injury, within 48 hours of the event.

We conducted a review of cases reported in peer-reviewed literature, identifying 20 cases in total, as can be seen in ►Table 1. Of these cases, 14 reported ruptures of both FDP and FDS tendons from their insertions and six reported ruptures in the midsubstance of the tendons. Where demographic information was included, the median age of the described cases was 27.5 years old (mean: 28.8 years), and all patients were male. The ring finger was most commonly affected. Overall, six different mechanisms were encountered including six other patients presenting with the mechanism of a typical jersey finger.

One other author used ultrasound as an adjunct to diagnosis. In our case, while ultrasound did not give us a definitive diagnosis, it did allow us to define our preoperative surgical strategy. The use of ultrasound has been studied in the context of single flexor tendon injuries; however, its utility for multiple closed tendon injuries has yet to be established.^{11,18,19}

FDP avulsion injuries were classically described by Leddy and Packer² and included three subtypes as follows—I: a tendinous avulsion with disruption of the vinculum and retraction into the palm; II: a tendinous avulsion which retracts to the PIPJ with intact vinculum; and III: a bony avulsion injury with retraction to the A4 pulley. This classification has since been modified to include type IV²⁰; a combination of a bony avulsion and tendon avulsion with secondary tendon retraction into the finger or palm and a distal phalanx fracture incarcerated at the A4 pulley. A further addition to the classification described a type V,²¹ an intra-articular bony avulsion associated with an extra-articular fracture. We propose that this injury, FDP avulsion, accompanied by avulsion of the FDS tendon, having been seen a similar number of times in the literature to the type-V injury, warrants inclusion as a separate entity in the Leddy and Packer classification as a “type VI” injury.^{2,20–22} It has been suggested that the pathological mechanism for this might be due to a trapping of the FDP tendon at the decussation of the FDS tendon at the level of Camper’s chiasm, with continued extension force against the contracted FDS/FDP tendons, resulting in FDS rupture from its insertion.¹⁰ Awareness of a type-VI Leddy and Packer injury would encourage clinicians to consider this diagnosis early in patient care and plan for operative intervention appropriately. It would also enable rehabilitation specialists to derive plans to manage this type of injury as a distinct entity from a closed single-tendon avulsion.

Our case is unusual as both tendons had been avulsed from their insertion sites with no associated bony injury. The decision on whether to repair both tendons is controversial. Some experts advocate for FDS repair to provide independent PIPJ flexion and increase power grip; however, it theoretically increases the risk of tendon adhesion which may reduce the total range of motion and increase the possibility of requiring secondary tenolysis. The only evidence for this is a trial of tendon injury in zone 2C, with a small number of patients.²³ We decided to repair the FDS in our case, as the injury was at the FDS insertion (zone 2A), the flexor sheath and pulley system was intact proximal to the

Table 1 Published reports of closed injuries of both FDS and FDP tendons

Author	Age (y)	Sex	Mechanism	Involved finger	Site rupture	Technique	Time to surgery	Follow-up	Outcome
Our case	27	M	Jersey finger	Ring finger	FDP: zone 1 FDS: zone 2 Both at insertions	FDP: suture anchor FDS: suture anchor	2 days	12 months	E/F-MCP: +10/90 PIP: 0/112 DIP: 16/64 Grip strength: 72% of contralateral side (dominant side) Tip to distal palmar crease = 0 cm
Boyes et al ³	Multiple (5 cases, ages not given)	Multiple (5 cases, sex not given)	Hyperextension × 4 Jersey finger × 1	Multiple (5 cases, finger not given)	FDP: zone 1 FDS: zone 2 Both at insertions in all 5 cases	Not described	N/A	N/A	N/A
Cheung and Chow ⁴	24	M	Jersey finger	Ring finger	FDP: zone 1 FDS: zone 2 Both at insertions	Both tendons sutured to periosteal flap. FDP reinforced w/ pull-out suture	4 days	3.5 months	Full ROM MCP and PIP, DIP 0–4 degrees
Cañadas Moreno et al ⁵	16	M	Blast	Index finger and middle finger	FDP: zone 1 FDS: zone 2 Both at insertions	FDP: pull-out suture FDS: anchor suture	0 days	4 months	DIP flexion: 30 degrees × 2 digits
Toussaint et al ⁶	23	M	Blast	Ring finger and little finger	FDP: dilacerated in zone 1 + volar plate pull-out. FDS: zone 2 Both at insertions	FDP: pull-out suture FDS: resected	1 day	7 months	D4: DIP flexion 15; PIP flexion: 10 D5: DIP 40 PIP flexion: 10
Backe and Posner ⁷	23	M	Traction hyperextension	Ring finger	FDP: zone 1 FDS: zone 2 Both at insertions	Palmaris longus tendon graft	4 weeks	NM	Complete extension and active flexion within 1.5 cm of midpalmar crease DIP stiffness
Lanzetta and Conolly ⁸	28	M	Traction hyperextension	Ring finger	FDP: zone 1 FDS: zone 2 Both at insertions	Two stage repair: excision both tendons, left palmaris tendon graft 9 weeks post first surgery	3 days	4 months	Full extension and flexion recovered
Johnson and Coville ⁹	35	M	Traction hyperextension	Ring finger	FDP: zone 2 FDS: zone 2 Both at insertions	FDP: intraosseous repair FDS: resected	4 weeks	5 months	E/F-MCP: 0/82 PIP: 4/102 DIP: 10/20 Tip to distal palmar crease = 0 cm
Jordan et al ¹⁰	20	M	Jersey finger	Middle finger	FDP: zone 1 FDS: zone 2 Both at insertions	FDP: pull-out suture FDS: resected	14 days	4 months	Full movement of PIP and arc of 20–70 at DIPJ
Soro et al ¹¹	30	M	Jersey finger	Little finger	FDP: zone 1 FDS: zone 3 FDP at insertion FDS midsubstance	FDP: pull-out suture FDS: tendon graft	0 days	6 months	E/F-MCP: 0/95 PIP: 10/85 DIP: 10/22 Tip to distal palmar crease = 0 cm

Table 1 (Continued)

Author	Age (y)	Sex	Mechanism	Involved finger	Site rupture	Technique	Time to surgery	Follow-up	Outcome
Boyes et al ³	37	M	Jersey finger	Middle finger	FDP: zone 3 FDS: zone 3 Both midsubstance at lumbrical origin	Not described	N/A	N/A	N/A
Boyes et al ³	42	M	Hyperextension	Little finger	FDP: zone 3 FDS: zone 3 Both midsubstance at lumbrical origin	Not described	N/A	N/A	N/A
Oğün et al ¹²	21	M	Jersey finger	Ring finger	FDP: zone 1 FDS: zone 2 Both midsubstance	FDP: pull-out suture FDS: resected	0 days	19 months	TAM = 230 degrees PIP and DIP stiffness
Naohito et al ¹³	49	M	Direct shock	Little finger	FDP: zone 2 FDS: zone 2 Both midsubstance	FDP: end-to-end suture, FDS: resected	20 days	4 months	E/F-MCP: 30/0/80 PIP 0/40/85 DIP: 0/15/60
Matthews and Walton ¹⁴	28	M	Repeated microtrauma	Middle finger	FDP: zone 2, FDS: zone 2 Both midsubstance	2 stage repair: silicone rod, reoperation at 10 weeks, PL graft	14 days	3.5 months	Good result: normal flexion DIP and PIP stiffness

Abbreviations: DIP, distal interphalangeal; DIPJ, DIP joint; E/F, extension/flexion; FDP, flexor digitorum profundus; FDS, flexor digitorum superficialis; M, male; MCP, metacarpophalangeal joint; N/A, not available; NM, not mentioned; PIP, proximal interphalangeal; ROM, range of motion; TAM, total active motion.

FDS insertion, and our patient competed in high-level sport where grip strength is important. His compliance with rehabilitation was also likely to be high, thus mitigating the likelihood of adhesion formation through inactivity during rehabilitation. We debated intraoperatively whether one slip of the FDS tendon would be sufficient, given the preference of some surgeons for this method but due to the nature of this specific injury, we felt it was reasonable to restore anatomic and kinematic normality by repairing both slips.^{24,25}

Half of the other authors in our review decided to resect the FDS, but in cases where the FDS was ruptured from its insertion site, it was fixed with a transosseous suture. Both of these cases were associated with avulsion fractures. Our case saw a pure tendinous rupture from the insertion into the middle phalanx. We repaired the FDS slips using two suture anchors. We also repaired the FDP tendon using suture anchors, a technique adopted by only one other author. Other described techniques included the use of a pull-out suture, end-to-end suture (where appropriate), or resection and subsequent tendon grafting. Suture anchors seem to confer increased strength²⁶ and allow for quicker return to work²⁷ in comparison to pull-out suture techniques for zone-I FDP avulsions.

Conclusion

This unusual presentation is not one that many clinicians frequently encounter. We believe that if presented with a similar case of pure tendinous avulsion injuries of both FDS and FDP tendons, suture anchor repair of both tendons can provide an excellent outcome, and we would recommend this technique. We suggest that this combination of closed avulsions of FDP and FDS tendons from their insertions should be added to the Leddy and Packer classification as a “type-VI” injury, due to its distinction from a simple FDP avulsion injury and the complexities in its management.

Conflict of Interest

None declared.

References

- 1 Wolfe SW, Pederson WC, Kozin SH. Green’s Operative Hand Surgery. 6th ed. Philadelphia, PA: Elsevier/Churchill Livingstone; 2011
- 2 Leddy JP, Packer JW. Avulsion of the profundus tendon insertion in athletes. *J Hand Surg Am* 1977;2(01):66–69
- 3 Boyes JH, Wilson JN, Smith JW. Flexor-tendon ruptures in the forearm and hand. *J Bone Joint Surg Am* 1960;42-A:637–646
- 4 Cheung KM, Chow SP. Closed avulsion of both flexor tendons of the ring finger. *J Hand Surg [Br]* 1995;20(01):78–79
- 5 Cañadas Moreno O, Martínez González-Escalada R, Lara García FJ. Multiple closed avulsions of flexor tendons of the hand caused by a firecracker blast. *Ann Plast Surg* 2012;68(02):158–160
- 6 Toussaint B, Lenoble E, Roche O, Iskandar C, Dossa J, Allieu Y. [Subcutaneous avulsion of the flexor digitorum profundus and flexor digitorum superficialis tendons of the ring and little fingers caused by blast injury]. *Ann Chir Main Memb Super* 1990;9(03):232–235
- 7 Backe H, Posner MA. Simultaneous rupture of both flexor tendons in a finger. *J Hand Surg Am* 1994;19(02):246–248

- 8 Lanzetta M, Conolly WB. Simultaneous rupture of both flexor tendons in a finger. *J Hand Surg Am* 1996;21(06):1114–1115
- 9 Johnson MA, Colville J. Closed traumatic avulsion of both ring finger flexors with successful primary repair more than 4 weeks after injury and a review of the literature. *J Surg Case Rep* 2020; 2020(07):a160
- 10 Jordan RW, Lotfi N, Shyamalan G. Simultaneous closed rupture of flexor digitorum superficialis and flexor digitorum profundus tendons in the middle finger: a case report. *Case Reports Plast Surg Hand Surg* 2015;2(01):1–3
- 11 Soro MA, Christen T, Durand S. Unusual closed traumatic avulsion of both flexor tendons in zones 1 and 3 of the little finger. *Case Rep Orthop* 2016;2016:6837298
- 12 Oğün TC, Ozdemir HM, Senaran H. Closed traumatic avulsion of both flexor tendons in the ring finger. *J Trauma* 2006;60(04): 904–905
- 13 Naohito H, Masato A, Rui A, Daisuke H, Yusuke Y, Koichi I. Closed rupture of both flexor digitorum profundus and superficialis tendons of the small finger in zone II: case report. *J Hand Surg Am* 2011;36(01):121–124
- 14 Matthews RN, Walton JN. Spontaneous rupture of both flexor tendons in a single digit. *J Hand Surg [Br]* 1984;9(02):134–136
- 15 Sandow MJ, McMahon M. Active mobilisation following single cross grasp four-strand flexor tenorrhaphy (Adelaide repair). *J Hand Surg Eur Vol* 2011;36(06):467–475
- 16 James JJ. Fractures of the proximal and middle phalanges of the fingers. *Acta Orthop Scand* 1962;32:401–412
- 17 Peck FH, Roe AE, Ng CY, Duff C, McGrouther DA, Lees VC. The Manchester short splint: a change to splinting practice in the rehabilitation of zone II flexor tendon repairs. *Hand Ther* 2014;19 (02):47–59
- 18 Sığün TS, Karabay N, Toros T, Ozaksar K, Kayalar M, Bal E. Validity of ultrasonography in surgically treated zone 2 flexor tendon injuries. *Acta Orthop Traumatol Turc* 2010;44(06):452–457
- 19 Cohen SB, Chhabra AB, Anderson MW, Pannunzio ME. Use of ultrasound in determining treatment for avulsion of the flexor digitorum profundus (rugger jersey finger): a case report. *Am J Orthop* 2004;33(11):546–549
- 20 Smith JH Jr. Avulsion of a profundus tendon with simultaneous intraarticular fracture of the distal phalanx—case report. *J Hand Surg Am* 1981;6(06):600–601
- 21 Al-Qattan MM. Type 5 avulsion of the insertion of the flexor digitorum profundus tendon. *J Hand Surg [Br]* 2001;26(05): 427–431
- 22 Robins PR, Dobyns JH. Avulsion of the insertion of the flexor digitorum profundus tendon associated with fracture of the distal phalanx: a brief review. In *AAOS Symposium on Tendon Surgery in the Hand*. St. Louis: Mosby; 1975:151–156
- 23 Tang JB. Flexor tendon repair in zone 2C. *J Hand Surg [Br]* 1994;19 (01):72–75
- 24 Pike JM, Gelberman RH. Zone II combined flexor digitorum superficialis and flexor digitorum profundus repair distal to the A2 pulley. *J Hand Surg Am* 2010;35(09):1523–1527
- 25 Henry M. Zone II: repair or resect the flexor digitorum superficialis? *J Hand Surg Am* 2011;36(06):1073–1074, quiz 1075
- 26 McCallister WV, Ambrose HC, Katolik LI, Trumble TE. Comparison of pullout button versus suture anchor for zone I flexor tendon repair. *J Hand Surg Am* 2006;31(02):246–251
- 27 Brustein M, Pellegrini J, Choueka J, Heminger H, Mass D. Bone suture anchors versus the pullout button for repair of distal profundus tendon injuries: a comparison of strength in human cadaveric hands. *J Hand Surg Am* 2001;26(03):489–496