



Pattern Recognition of Abdominal Vasculature on Color Doppler in the Fetus as a Tool for Early Diagnosis of Bladder Exstrophy in the First and Early-Second Trimester: Initial Observations

Kavita Aneja¹ Sanjay Gandhi² Jeena Bordoloi Deka³ Meenal S. Deshmukh⁴

¹ Images Ultrasound Centre, Naveda Healthcare Centre, Rohini, New Delhi, India

² Research & Innovation Lead for Core Clinical Services, North Bristol NHS Trust, Bristol, United Kingdom

³ Dispur Polyclinic & Hospitals Pvt Ltd, Guwahati, Assam, India

⁴ Nidaan Diagnostic Centre, Pusad, Yavatmal, Maharashtra, India

Address for correspondence Kavita Aneja, MD, Images Ultrasound Centre, Naveda Healthcare Centre, House number 81, Pocket A1, Sector 8 Rohini, New Delhi 110085, Delhi, India (e-mail: drkavitaaneja@gmail.com).

Indian J Radiol Imaging 2022;32:403–407.

Abstract

Early prenatal diagnosis of bladder exstrophy is challenging because of its variable size and presentation. This article brings forth new signs on color Doppler (CD) to help establish the diagnosis in a suspected case. Two cases of omphalocele-exstrophy-imperforate anus-spinal defects complex presenting as a solid-cystic ventral mass at 11 weeks and a solid lower abdominal wall mass at 20 weeks, with nonvisualization of the urinary bladder, were studied by gray-scale and CD in sagittal and transverse-bladder views of the abdomen. The sagittal view on CD revealed an altered intrafetal course of umbilical artery (UA), widened UA-aorta angle (K angle), a break in the intersection of UA, and umbilical vein (UV) at the umbilicus—broken “X-sign” with distortion of the equilateral triangle normally formed by aorta, UA, and UV. The transverse-bladder view showed an altered divergent course of single-UA. Combination of these findings substantiated early diagnosis of bladder exstrophy, thus facilitating prenatal counseling.

Keywords

- ▶ CD
- ▶ umbilical artery
- ▶ exstrophy bladder
- ▶ omphalocele
- ▶ abdominal wall
- ▶ K angle

Key Messages

- Early prenatal diagnosis of bladder exstrophy is possible by pattern recognition of abdominal vasculature on color Doppler.
- The new signs—“X” and “Y” derived on color Doppler, as a clue to early diagnosis of bladder exstrophy—have not been identified in the current literature that makes this article unique.

published online
August 23, 2022

DOI <https://doi.org/10.1055/s-0042-1754363>.
ISSN 0971-3026.

© 2022. Indian Radiological Association. All rights reserved.
This is an open access article published by Thieme under the terms of the Creative Commons Attribution-NonDerivative-NonCommercial-License, permitting copying and reproduction so long as the original work is given appropriate credit. Contents may not be used for commercial purposes, or adapted, remixed, transformed or built upon. (<https://creativecommons.org/licenses/by-nc-nd/4.0/>)
Thieme Medical and Scientific Publishers Pvt. Ltd., A-12, 2nd Floor, Sector 2, Noida-201301 UP, India

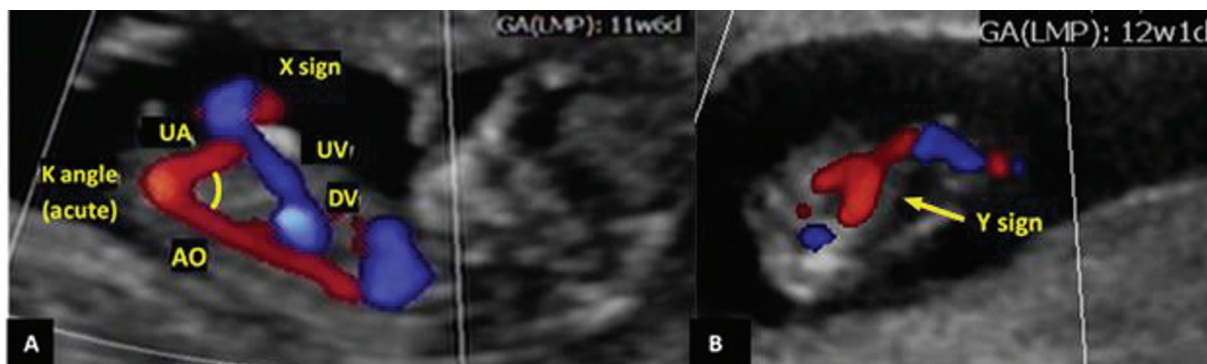


Fig. 1 Color Doppler in a normal fetal abdomen—(A) Sagittal view shows equilateral triangle formed by aorta (AO), umbilical artery (UA), and umbilical vein (UV) at 12 weeks; acute “K angle”; “X-sign.” (B) Transverse-bladder view shows “Y-sign” at 12 weeks.

Introduction

Bladder exstrophy is a rare severe congenital malformation with a reported incidence of 1 in 40,000 live births.¹ Early prenatal diagnosis is scarcely described in the literature.² For a comprehensive understanding of the role of color Doppler (CD) in early diagnosis of bladder exstrophy, it is imperative to understand the signature pattern of relevant abdominal vasculature on CD in a normal fetus at first-trimester-morphology scan. Sagittal view of the abdomen shows an equilateral triangle formed by aorta, umbilical artery (UA; one behind the other) and umbilical vein (UV). The perivesical UAs, arising from internal iliac arteries, run obliquely to emerge at the umbilicus where they intersect with UV to mimic the letter “X.” An intact “X-sign” indicates that UAs emerge normally at the umbilicus. The transverse-bladder view shows the two UAs converging across the urinary bladder (UB) within the pelvis, as they exit together to form a “Y.” The intact “Y-sign,” establishes that the bladder is positioned normally in the pelvis. UA-aorta angle (K angle) is an acute angle in sagittal view of a normal fetus because of the fixed intrafetal course of perivesical UAs (→Fig. 1).¹

Bladder exstrophy reveals an altered intrafetal course of UAs resulting in distortion of the normal classic pattern of abdominal vasculature. This observation when applied to cases with nonvisualization of UB helps establish the early prenatal diagnosis of bladder exstrophy.

Case Reports

Case 1

A 30-year-old primigravida with unremarkable family and personal history had early morphology scan at 11 weeks gestation.

Two-dimensional and three-dimensional ultrasound revealed increased nuchal translucency (4 mm), obliterated intracranial lucency, a solid-cystic lower abdominal wall mass, absence of UB, and lumbar meningocele (→Fig. 2A–D). Anus could not be commented upon.

CD of the fetal abdomen in sagittal view revealed low emergence of UA, widened obtuse “K angle” (146 degrees), and UV coursing the center of solid ventral mass through prolapsed liver to enter the abdomen at the umbilicus. UA and UV did not intersect at the umbilicus (but do so outside the abdomen) resulting in broken “X-sign” with consequent distortion of the equilateral triangle normally formed by aorta, UA, and UV. Transverse-pelvic view showed an altered divergent course of the single-umbilical artery (SUA) as it emerges alongside the cystic exstrophic mass (→Fig. 3A–C).

Noninvasive-prenatal test was normal and maternal serum α -fetoprotein was raised.

A diagnosis of omphalocele-exstrophy-imperforate anus-spinal defects (OEIS) complex was given. The patient underwent termination by dilatation and evacuation. Hence, autopsy could not be conducted.

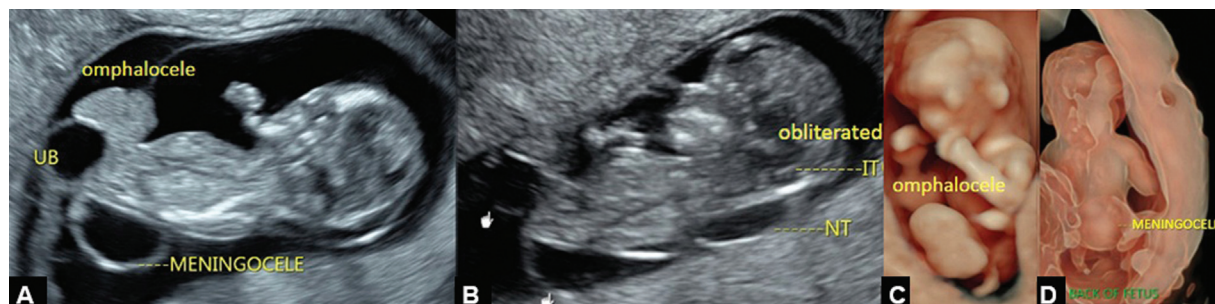

Fig. 2 Case 1 at 11 weeks—(A and B) Sagittal views show a solid cystic mass from the lower abdominal wall, meningocele, increased nuchal translucency (NT), obliterated intracranial lucency (IT). (C and D) Three-dimensional view shows omphalocele, meningocele.

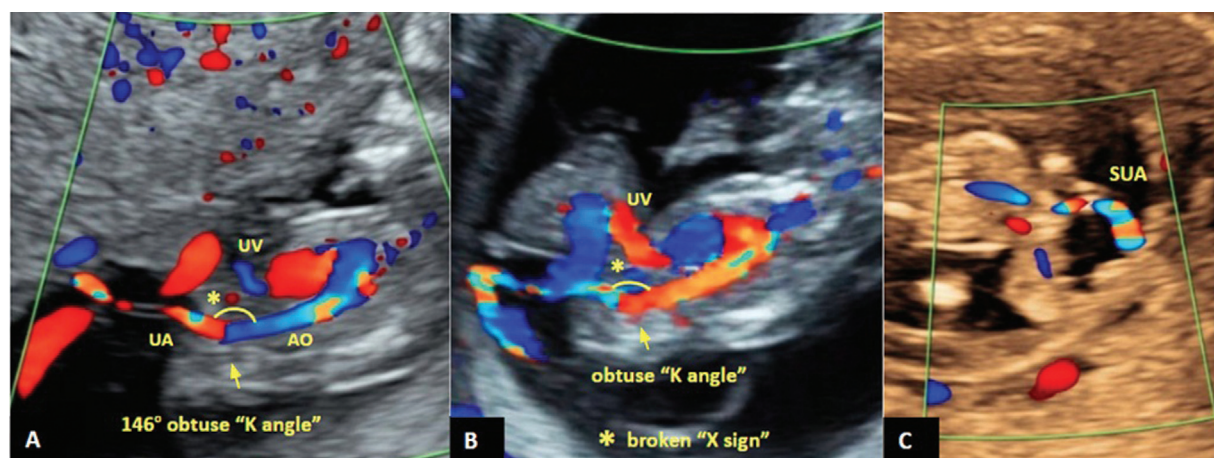


Fig. 3 Case 1 at 11 weeks—(A and B) Color Doppler shows altered intrafetal course of umbilical artery (UA), obtuse “K angle,” broken “X-sign” (*), distorted equilateral triangle formed by aorta (AO), UA, umbilical vein (UV) (C) Transverse-pelvic view shows a divergent single-umbilical artery (SUA).

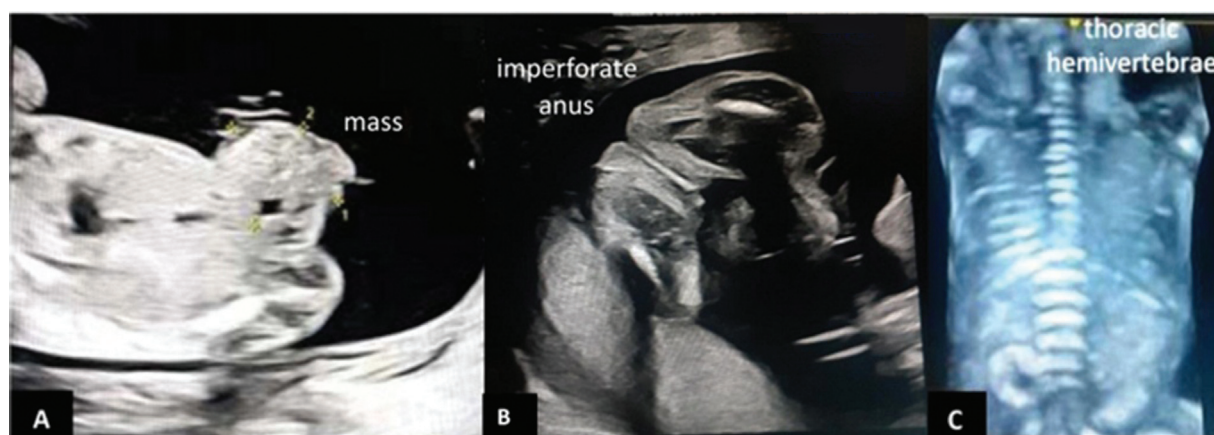


Fig. 4 Case 2 at 20 weeks—(A) Gray-scale two-dimensional image shows a solid ventral mass from lower abdomen. (B) Imperforate anus. (C) Three-dimensional image shows thoracic hemivertebrae.

Case 2

A 23-year-old primigravida had her anomaly scan at 20 weeks with a presumptive diagnosis of omphalocele. Her second-trimester serum screening was normal.

Two-dimensional and three-dimensional ultrasound revealed an irregular solid lower abdominal wall mass, nonvisualization of UB, bilateral club feet, hemivertebrae in the thoracic region, and imperforate anus (→ Fig. 4A–C).

CD of the abdomen in sagittal view showed an altered intrafetal course of UA, obtuse “K angle” (110 degrees), broken “X-sign” as UA emerge infraumbilically, falling apart from UV at the umbilicus, consequently distorting the equilateral triangle. Transverse-pelvic view showed divergent SUA as it emerges from the pelvis (→ Fig. 5A–C).

A diagnosis of OEIS complex was given, which was confirmed postnatally in the abortus (→ Fig. 6A and B).

Discussion

The OEIS complex has a sporadic occurrence with an incidence of 1:200,000 to 1:400,000 live births.¹ Isolated exstrophy bladder has a reported detection rate of 15%.² The anterior abdomi-

nal wall and anterior bladder wall are deficient and posterior bladder wall protrudes through the defect. It could rarely present as a cloacal membrane cyst.¹ Nonvisualization of the UB with normal kidneys and amniotic-fluid index raises the suspicion of bladder exstrophy. However, the classic sign of nonvisualization of the bladder may not be reliable during early gestation because of limited fetal urine production and other causes. Additionally, other lower abdominal cystic structures may mimic a bladder in the pelvis.³ Application of CD to these fetuses substantiates the diagnosis of bladder exstrophy by demonstrating altered abdominal vasculature.

In the first trimester, CD reveals a signature pattern of abdominal vasculature in sagittal and transverse-bladder views of a normal fetus (which can be extrapolated to mid-second-trimester scan).

CD in the current cases of bladder exstrophy presenting as a component of OEIS complex revealed altered intrafetal course of UAs as they emerge infraumbilically alongside the bladder exstrophy, with consequent widening of “K angle” (obtuse), broken “X-sign,” distorted equilateral triangle in sagittal view and divergent course of SUA in transverse-bladder view (→ Figs. 3 and 5).

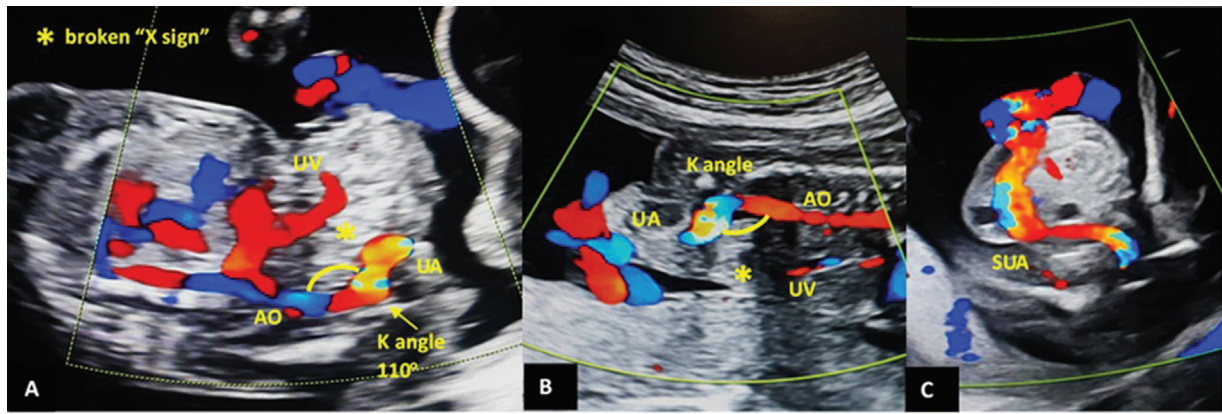


Fig. 5 (A–C) Color Doppler in sagittal view (supine and prone) shows altered course of intrafetal umbilical artery (UA) with widening of “K angle,” broken “X-sign” (*), and distorted equilateral triangle (aorta [AO]-umbilical artery [UA]-umbilical vein [UV]). Transverse-pelvic view shows divergent single-umbilical artery (SUA) emerging below the ventral mass.

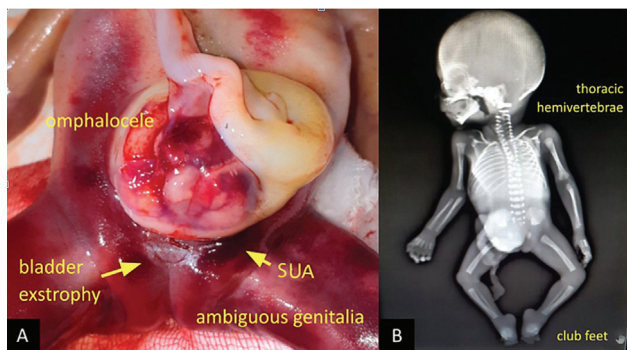


Fig. 6 (A) Picture of abortus shows bladder exstrophy with single-umbilical artery (SUA) emerging alongside bladder exstrophy below the omphalocele mass, ambiguous genitalia. (B) X-ray of abortus shows hemivertebrae and club feet

In case 2, the presumptive diagnosis of omphalocele was changed to OEIS complex due to the obtuse “K angle” sign seen on CD that points to the presence of bladder exstrophy along with omphalocele. In an isolated omphalocele, CD reveals normal acute “K angle” because of the normal oblique perivesical course of UA along normally positioned UB in the pelvis.¹

To further validate the usefulness of these novel signs, we refer to two cases of bladder exstrophy from literature—a case of cystic bladder exstrophy confluent with omphalocele (OEIS complex) at 17 weeks and another case of isolated cystic bladder exstrophy at 16 weeks.^{1,4} Broken “X-sign” is apparent on sagittal view in both the cases as depicted in the schematic diagram (→ Fig. 7G–J). Additionally, the presence of both UA in these cases reveals open “Y-sign” on transverse-bladder view as they emerge parallel/divergent, alongside the interposed exstrophic bladder to meet across the ventral mass outside the coelomic cavity. These novel signs, although apparent on images of these reviewed cases, have not been identified/described in the publications.^{1,4}

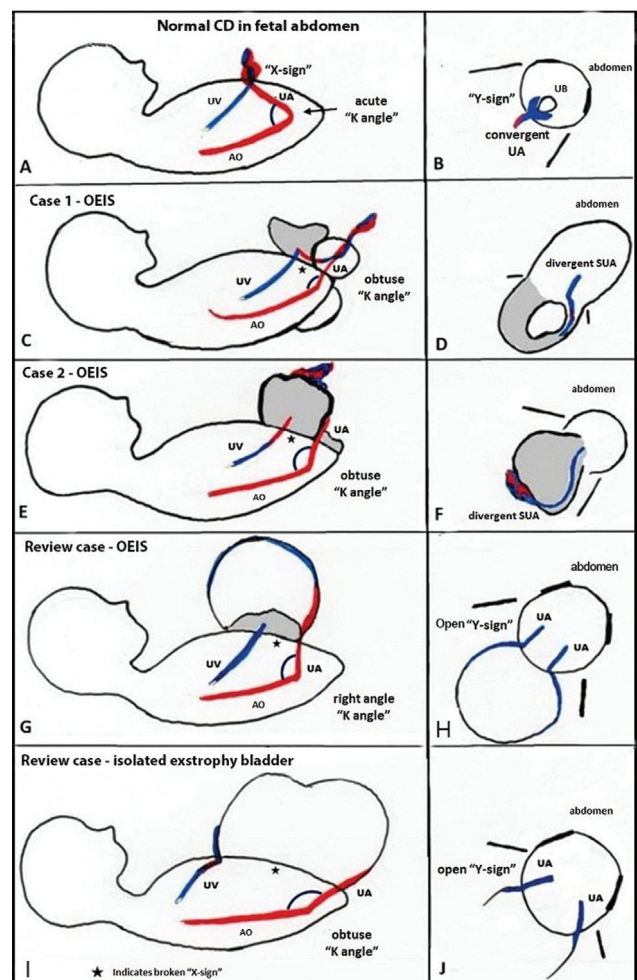


Fig. 7 Schematic representation of a comparative of normal abdominal vasculature and altered abdominal vasculature in current cases and review cases of bladder exstrophy in sagittal and transverse-pelvic views. (A, B) Normal color Doppler in the fetal abdomen. (C–F) Cases 1, 2. (G–J) Review cases. AO, aorta; OEIS, omphalocele-exstrophy-imperforate anus-spinal defects; SUA, single-umbilical artery; UA, umbilical artery; UV, umbilical vein.

Early prenatal diagnosis of bladder exstrophy is challenging.⁵ Low insertion of umbilical cord helps in the diagnosis of bladder exstrophy between 14 and 17 weeks, when there is no ventral mass bulge.²

Conclusion

With the help of two cases, our article highlights the potential of pattern recognition of abdominal vasculature by CD for diagnosis of bladder exstrophy at first and mid-second-trimester morphology scan. Altered intrafetal course of UA manifesting as aforementioned novel signs, put together in a suspected case, could establish the diagnosis with utmost certainty, facilitating early decision making.

We feel that these initial observations could pave the way for a larger study on the subject to validate these signs.

Source(s) of Support

Nil.

Presentation at a Meeting

Nil.

Any other Disclosure

None.

Conflict of Interest

None.

Acknowledgments

Nil.

References

- 1 Aneja K. A rare case of OEIS complex - newer approach to diagnosis of exstrophy bladder by color doppler and its differentiation from simple omphalocele. *Indian J Radiol Imaging* 2017;27(04):436–440
- 2 Fishel-Bartal M, Perlman S, Messing B, et al. Early diagnosis of bladder exstrophy: quantitative assessment of a low-inserted umbilical cord. *J Ultrasound Med* 2017;36(09):1801–1805
- 3 Goldstein I, Shalev E, Nisman D. The dilemma of prenatal diagnosis of bladder exstrophy: a case report and a review of the literature. *Ultrasound Obstet Gynecol* 2001;17(04):357–359
- 4 Juhas M, Janovsky J. [cited 2020 September 18]. Available from: <https://sonoworld.com/TheFetus/Case.aspx?Case-Id=3335&answer=1>. Accessed March 19, 2022
- 5 Wu J-L, Fang K-H, Yeh G-P, Chou P-H, Hsieh CT-C, Using CD. Using color Doppler sonography to identify the perivesical umbilical arteries: a useful method in the prenatal diagnosis of omphalocele-exstrophy-imperforate anus-spinal defects complex. *J Ultrasound Med* 2004;23(09):1211–1215