



# Endobiliary and Pancreatic Radiofrequency Ablations

Anurag Lavekar<sup>1</sup> Saurabh Mukewar<sup>2</sup>

<sup>1</sup>Department of Gastroenterology, Triveni Hospital, Nanded, Maharashtra, India

<sup>2</sup>Department of Gastroenterology, Midas Hospital, Nagpur, Maharashtra, India

Address for correspondence Saurabh Mukewar, MD, Consultant Gastroenterologist and Hepatologist, Midas Hospital, Midas Heights, Central Bazar Road, Nagpur – 440010, Maharashtra, India (e-mail: saurabhmukewar@gmail.com).

J Digest Endosc 2023;14:41–48.

## Abstract

### Keywords

- ▶ biliary cancer
- ▶ biliary RFA
- ▶ pancreatic cystic neoplasm
- ▶ pancreatic neuroendocrine tumor
- ▶ pancreatic RFA

Radio frequency ablation (RFA) involves use of thermal energy to perform ablation of tissues. It has a wide range of application in gastrointestinal tract. Over the last few years, several studies have reported successful and safe application in the biliary and pancreatic tissues. It is particularly beneficial in patients with biliary malignancies in whom it has shown to improve survival. Additionally, it can be applied in occluded metal stents secondary to tumor ingrowth to prolong the patency of stents. In pancreas, RFA can successfully ablate cystic lesions and neuroendocrine tumors. It has also been applied in unresectable pancreatic cancers. This review discusses the application of endobiliary and pancreatic RFAs.

## Introduction

Radio frequency ablation (RFA) involves the use of catheters to ablate tissues with thermal energy generated through bipolar electrodes. Electricity travels in the range of 450 to 500 kHz alternatively between positive and negative electrodes and delivers thermal energy surrounding the electrodes. This results in coagulation and destruction of microvessels and tissues. To enhance the efficacy of ablation, electrodes are applied in direct contact with the targeted tissue. Depth of ablation depends on the energy power, duration of impacts, and energy density. Typically, in the digestive tract the depth of ablation can go as deep as the muscularis mucosae (700–800 microns in depth). RFA acts by causing thermal coagulative necrosis of unwanted tissue. It has a wide range of applications such as in treatment of cardiac arrhythmias, varicose veins, and ablation of malignancies. In the field of gastroenterology, RFA is commonly used for management of biliary and pancreatic malignancies, dysplastic Barrett's esophagus, and also ablation of gastric antral vascular ectasia and radiation proctocolitis. In this review,

we specifically discuss the biliary and pancreatic applications of RFA.

## Biliary RFA

Malignant biliary obstruction (MBO) resulting from cholangiocarcinoma of the bile ducts or gallbladder, carcinoma of pancreas, and liver or a lymph node metastasis usually carries a dismal prognosis at the time of diagnosis. Typically, management involves placement of stents via endoscopic retrograde cholangiopancreatography or percutaneous transhepatic biliary drainage to relieve the biliary obstruction followed by surgery or palliative chemotherapy. Plastic stents are generally preferred for resectable cases and uncovered self-expanding metal stents (SEMS) for unresectable cases. SEMS has several advantages over plastic stents including increased patency and reduced migration risk. However, there are some limitations of SEMS such as stent occlusion due to tumor ingrowth or biliary stones/sludge.<sup>1</sup> Several alterations in these methods aimed at prolonging stent patency have proven to be of limited utility so far and

article published online  
December 23, 2022

DOI <https://doi.org/10.1055/s-0042-1756485>.  
ISSN 0976-5042.

© 2022. The Author(s).

This is an open access article published by Thieme under the terms of the Creative Commons Attribution License, permitting unrestricted use, distribution, and reproduction so long as the original work is properly cited. (<https://creativecommons.org/licenses/by/4.0/>)

Thieme Medical and Scientific Publishers Pvt. Ltd., A-12, 2nd Floor, Sector 2, Noida-201301 UP, India

**Table 1** Types of radio frequency ablation devices

System or catheter	Catheter diameter	Length	Electrode dimensions (length × diameter)
Habib EUS-RFA	1 Fr	220 cm	20 mm × 1 Fr
Habib Endo HPB	8 Fr	200 cm	8 mm × 8 Fr (2 electrodes)
EUSRA™ RF Electrode	18 G	150 cm	7 mm × 18 G
ELRA™ endobiliary RFA	7 Fr	175 cm	18 and 33 mm × 7 Fr

Source: Adapted from Navaneethan et al<sup>22</sup>

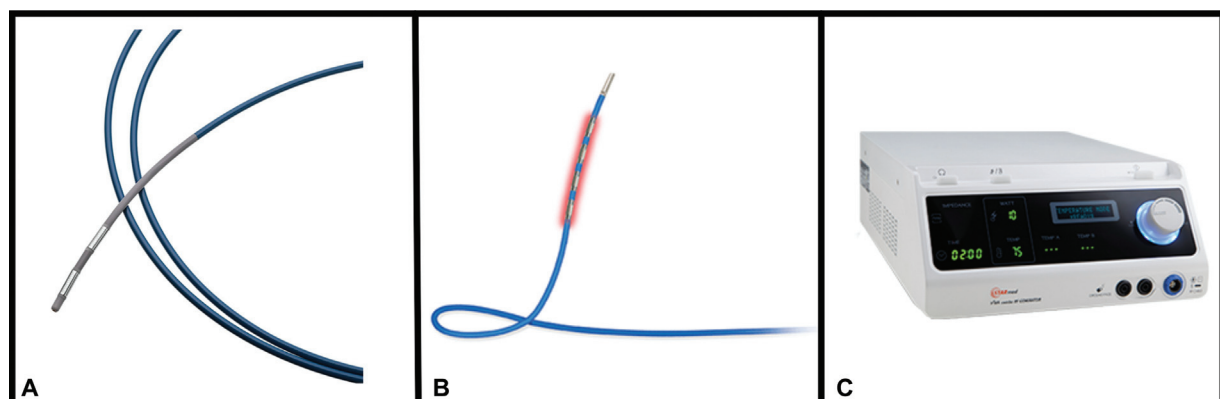
there is a need to use adjunct techniques for this purpose. Endobiliary radio frequency ablation (EB-RFA) is an emerging modality to supplement conventional management in patients with MBO.<sup>2</sup> There are a variety of devices available for biliopancreatic RFA, which are summarized in ►Table 1.

Following an endoscopic sphincterotomy, a 0.025/0.035 inch guidewire is advanced into the biliary system at the target site. This is followed by insertion of RFA catheter over the guidewire (►Fig. 1). Usual length is 8 mm and the two electrodes are 8 mm apart from each other. Distal electrode is 5 mm away from the tip of the probe. Radio frequency (RF) power is applied to its two tip electrodes. The RF energy passes through tissues to attain controlled heating with the highest power density. A high-frequency alternating electric current is applied through probe electrodes for a duration of 60, 90, or 120 seconds, which results in rapid intracellular ionic movement in opposite directions. This in turn creates frictional forces that generate heat and cause necrosis of the surrounding tissue. In an animal study, the duration of catheter application was the most important parameter that influenced the depth of thermal injury rather than the effect setting or power output.<sup>3</sup> The two electrodes of RFA are positioned in contact with stricture and ablation is performed with 7 to 10 watts<sup>4</sup> (►Fig. 2). For long strictures (more than 25 mm), catheter is moved by 1 cm and ablation is repeated till complete length of stricture is treated. After the complete ablation, single or multiple stents are placed depending on the number, length, and position of strictures. EB-RFA has an additional benefit of local thermal effect of ablation to destroy the malignant biliary stricture, which ultimately leads to disappearance of tumor blood vessels and enlargement of bile duct lumen. It is speculated to stimulate

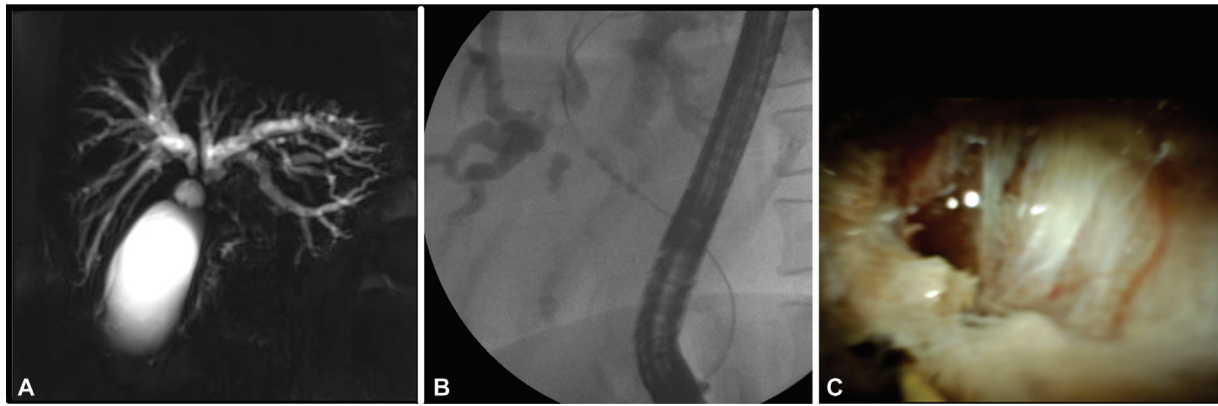
antitumor systemic immunity and helps in reducing adverse effects as well as improving overall survival.<sup>5</sup> EB-RFA probe with sensors that control the temperature at the tissue–electrode interface has been introduced. It is shown to restrict charring of surface electrode and thus brings precision in ablation and helps minimizing adverse events.

There is a growing amount of evidence favoring usage of EB-RFA followed by biliary stenting.<sup>4</sup> In a study by Inoue et al,<sup>4</sup> median survival in cholangiocarcinoma patients undergoing EB-RFA followed by stenting was reported to be 244 days. Adverse events (excluding recurrent biliary obstruction [RBO] events, 7.7%) consisted of cholecystitis, non-occlusion cholangitis, and liver abscess. Incidence of RBO was reported to be 38.5% (15/39). Median time required to develop RBO was 230 days. Development of RBO had a positive correlation with length of the stricture (stricture of more than 15 mm significantly associated with development of RBO). Success rate for reintervention for RBO was 92.3% (12/13). Reintervention was not possible in one patient because of development of duodenal stricture.

Initial probing of EB-RFA alone without subsequent stenting of the biliary system has yielded discouraging results owing to higher incidence of thrombus secondary to bleeding in the biliary system with resultant reobstruction within short span of time.<sup>6</sup> EB-RFA specifically improves the patency of uncovered SEMS by preventing tumor ingrowth.<sup>7</sup> Kong et al in their study compared RFA followed by stenting with stenting alone.<sup>6</sup> The stent patency was significantly higher in patients with RFA followed by stenting ( $p = 0.027$ ). Number of interventions required and number of stents placed were also significantly higher among RFA followed by stenting group ( $p = 0.006$  and  $p < 0.001$ , respectively). Adverse events



**Fig. 1** Endobiliary radio frequency ablation (RFA) devices: EndoHPB Bipolar Radiofrequency Catheter (A) by Boston Scientific, USA; ELRA Endobiliary RFA Catheter (B); and VIVA combo RF System (C) by STARmed, South Korea.



**Fig. 2** Patient with type 4 hilar cholangiocarcinoma seen on magnetic resonance cholangiopancreatography (A) underwent endobiliary radio frequency ablation (RFA) (B). Post-RFA digital spyglass cholangioscopy showing ablated and sloughed tissue (C).

such as mild biliary bleeding not requiring blood transfusion ( $p = 0.011$ ) and moderate pain after intervention ( $p = 0.02$ ) were significantly higher among RFA followed by stenting group compared to stenting alone. Incidence of moderate biliary bleeding, acute pancreatitis, bile leak, and recurrent biliary infection was not significant across both study groups.

► **Table 2** summarizes results of the studies of EB-RFA + biliary stenting against biliary stenting alone across different studies. These studies include randomized trials as well as retrospective studies. EB-RFA followed by stenting group had a better overall survival and stent patency rates compared to biliary stenting group alone. Most common adverse event was cholangitis. Other commonly reported adverse events with EB-RFA are hemobilia, gallbladder empyema, liver infection, nausea, and vomiting. Initial apprehensions about perforations secondary to EB-RFA, given the differences between malignant biliary tissue and normal biliary epithelium, are apparently theoretical, hypothetical, and overestimated and the present data do not favor this hypothesis.<sup>6</sup>

Patient selection bias may be a confounding factor contributing to complications. For example, patients with obstructed biliary pathways due to intrahepatic cholangiocarcinoma were reported to have increased incidence of moderate bleeding and recurrent biliary infections.<sup>6</sup> Kallis et al speculated that intrahepatic cholangiocarcinoma is associated with bile duct–fistula formation and is a possible explanation for intrahepatic cholangiocarcinoma being an independent risk factor for RBO post EB-RFA.<sup>8</sup> It is recommended to select patients with intrahepatic cholangiocarcinoma for EB-RFA with caution.

Use of RFA against photodynamic therapy (PDT) has also been established through few studies.<sup>9</sup> A significant post-procedure reduction in bilirubin, higher stent patency rate, and lesser incidence of complications were observed with the RFA group than PDT group. Also, the need for premature stent replacement (before 3 months) was higher in the PDT group. Both these studies were performed among patients of cholangiocarcinoma. Even though there was no significant difference in the overall survival between two groups, patients from RFA group required significantly less number

of stents than patients from PDT group but suffered more episodes of stent occlusion.<sup>9</sup>

EB-RFA offers advantage of being a repeatable procedure and occlusion/obstruction of previously deployed stent can be cleared even without stenting in subsequent procedures<sup>10</sup> (► **Fig. 3**). Another emerging indication for EB-RFA is refractory bilioenteric anastomotic strictures not responding to multiple sessions of balloon dilatation and long-term biliary drainage. Clinical success and catheter removal were achieved in 100% (6/6) patients in whom EB-RFA was performed for this indication with a mean symptom-free period of 430 days after EB-RFA.<sup>11</sup> However, this series has reported success of EB-RFA in a small number of patients and it will be premature to extrapolate its inferences to a large group of patients. Further studies are needed to clarify the role of EB-RFA in benign biliary strictures. EB-RFA has also shown to be effective in conjunction with endoscopic ultrasound (EUS)-guided hepaticoenterostomy with antegrade stenting with a technical and functional success rate of 80% (16/20).<sup>12</sup> The reasons for failure in the remaining (20%) cases were failure of passage of RFA catheter through the fistula or through the stricture. Early and late adverse events other than RBO occurred in 10% (2/20) and 13% (2/16) of subjects, respectively. The RBO rate was 25% (4/16), and the median time to RBO was 276 days. The success rate of endoscopic re-intervention using hepaticoenterostomy was 100% (4/4).

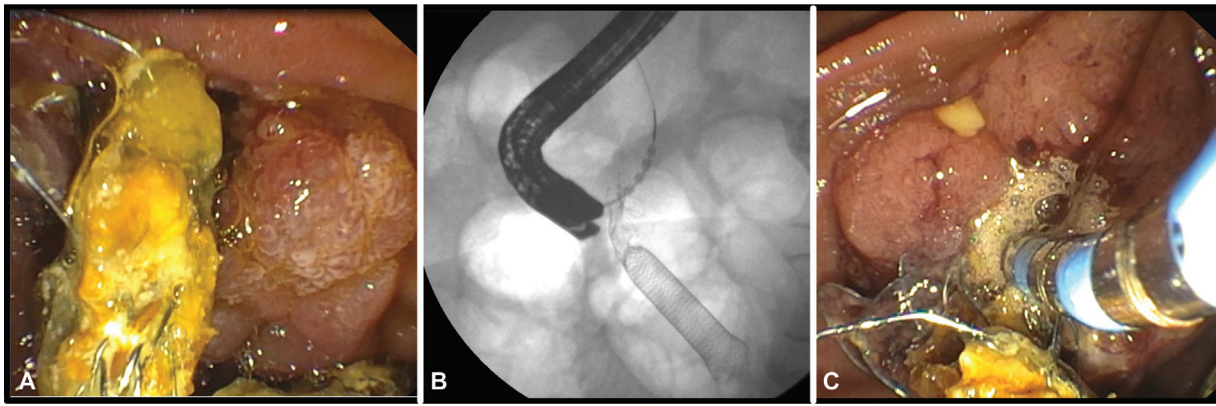
## Pancreatic RFA

Similar to the biliary tract, RFA can be applied on pancreatic tissue. The electrode is delivered via EUS-fine needle aspiration (FNA) needles or special needles with electrodes at the tip of the FNA needle. Earlier, there were concerns of complications with pancreatic RFA, since pancreas is an extremely thermosensitive organ and thermal ablation of the pancreas can result in complications such as pancreatitis, leakage of pancreatic juice resulting in pancreatic ascites/peripancreatic fluid collections, fibrotic and cystic transformation, and injury to surrounding structures—stomach, or small and large bowel.<sup>13</sup> However, these complications

**Table 2** Outcomes of studies comparing results of RFA and stenting versus stenting alone in patients with malignant biliary obstruction

Study	Study design	No. of patients		Outcome	Median time (95% CI, mo)		HR (95% CI) for RFA	Adverse events
		RFA + S	Stent		RFA + S	Stent		
Shariha et al (2014) <sup>23</sup>	Retrospective	26	40	Overall survival	5.9 for both groups (not reported for each group)		0.29 (0.11–0.76)	Abdominal pain 3; pancreatitis 1; cholecystitis 1
Kallis et al (2015) <sup>8</sup>	Retrospective	23	46	Overall survival	7.5	4.1	0.66 (0.410–1.063)	Hyperamylasemia 1; cholangitis 1
				Stent patency	15.7	10.8	1.186 (0.536–2.656)	
Hu et al (2016) <sup>24</sup>	RCT	32	31	Overall survival	10.4 (8.0–12.7)	57.3 (4.8–6.6)	0.48 (0.27–0.85)	Bleeding 1; cholangitis 20; cholecystitis 7
				Stent patency	5 (3.0–7.1)	3.9 (2.6–5.2)	0.90 (0.52–1.55)	
Wang et al (2016) <sup>25</sup>	Retrospective	18	18	Overall survival	6.1 (4.8–15.2)	5.8 (4.2–16.5)	0.598 (0.324–1.324)	Cholangitis 3
				Stent patency	5.8 (2.8–11.5)	4.5 (2.4–8.0)	0.49 (0.25–0.93)	
Dutta et al (2017) <sup>26</sup>	Retrospective	15	16	Overall survival	7.3	4.9	0.39 (0.17–0.92)	Pancreatitis 1; Cholangitis 1
Yang et al (2018) <sup>27</sup>	RCT	32	33	Overall survival	13.2 ± 0.6 b)	8.2 ± 0.5 b)	0.182 (0.08–0.322)	Cholangitis 2
				Stent patency	6.8 (3.6–8.2)	3.4 (2.4–6.5)	N/A	
Bokemeyer et al (2019) <sup>28</sup>	Retrospective	20	22	Overall survival	11.4	7.4	0.54 (0.29–0.99)	Cholangitis 6; pancreatitis 2; intestinal perforation 1 d
Kang et al (2021) <sup>29</sup>	RCT	24	24	Overall survival	8.3 (3.9–12.3)	6.0 (0.9–11.1)	0.71 (0.38–1.33)	Cholangitis 1
				Stent patency	4.4 (3.3–5.5)	3.9 (1.1–5.9)	0.80 (0.45–1.42)	
Gao et al (2021) <sup>30</sup>	RCT	87	87	Overall survival	14.3 months	9.2 months	0.48 (0.35–0.67)	Acute cholecystitis; cholangitis; post-ERCP pancreatitis; bleeding
				Stent patency	3.7 months	4.1 months		

Abbreviations: CI, confidence interval; ERCP, endoscopic retrograde cholangiopancreatography; HR, hazard ratio; N/A, not available; mo, months; RCT, randomized controlled trial; RFA, radio frequency ablation; S, stenting.



**Fig. 3** Patient with tissue ingrowth in distal margin of metal stent preventing removal (A). Endobiliary radio frequency ablation (RFA) was performed. Fluoroscopy (B) showing catheter at distal end of common bile duct and endoscopic view (C) showing catheter in the bile duct. RFA was successfully performed and stent removed.

appear to be related to the duration of ablation as in case of biliary RFA.<sup>14</sup> More recently, there is an increasing amount of evidence suggesting that RFA is a safe and a feasible tool for application in pancreas.<sup>15</sup>

RFA has a role in treatment of pancreatic neuroendocrine tumors (NETs) and pancreatic cystic neoplasms (PCNs). In a prospective open-label multicentric study done on 30 patients, EUS-guided RFA was found to be safe in management of pancreatic NETs smaller than 2 cm in size and PCNs (branch duct intraductal papillary mucinous neoplasms and mucinous cystadenomas).<sup>16</sup> In this study, EUS-RFA was performed with an 18G RFA cooling needle. The overall complication rate was 10% (3/30)—acute pancreatitis, small bowel perforation, and pancreatic ductal stenosis. It was of note that modifications in protocols such as antibiotic prophylaxis with intravenous amoxicillin and clavulanic acid, rectal administration of diclofenac, or suctioning of the majority of cystic fluid contents prior to RFA to evade delivery of excess current into liquid component appeared to significantly reduce the rate of complications. As far as efficacy of EUS-RFA was concerned, pancreatic NETs exhibited 86% resolution rate at 1-year follow-up, whereas PCNs showed significant response rate of 71% (complete disappearance and one diameter that decreased by more than 50%).

Imperatore et al<sup>17</sup> in a systematic review studied results of EUS-guided RFA among 73 pancreatic NETs. Patients included were from 12 different studies. The overall effectiveness of EUS-RFA was 96% without major safety issues. Tumor size was the predictor of treatment failure: 21.8 mm in the nonresponse group versus 15.07 mm in the response group. In the receiver operating characteristic analysis, a pancreatic NET size cutoff value of 18 mm or less predicted response to treatment with a sensitivity of 80%, specificity of 78.6%, and positive predictive value of 97.1% area under curve of 81.

—**Table 3** summarizes results of application of RFA in pancreatic NETs. It is observed that the procedure is mostly efficacious, safe, and free of adverse events and has promising results. However, the studies have a smaller sample size and larger studies are needed to define the role of RFA in pancreatic NETs.

At the time of diagnosis, most patients with pancreatic cancer have advanced disease and carry a poor prognosis. In some cases that are resectable, surgery can offer a chance for cure. However, even in these patients the 5-year survival rate remains low: approximately 18 to 24%.<sup>18</sup> Results with chemotherapy are not encouraging and there is an unmet need for other therapeutic modalities. RFA may offer better palliative or alternative therapy for “difficult to treat” pancreatic malignancies. Though it does not aim at eradicating the tumor, it significantly reduces the bulk of tumor load. When combined with other therapies such as chemotherapy, it may help in prolongation of survival.<sup>19</sup> Moreover, it is also postulated that by inciting an antitumor immune response, RFA helps in combating cancer load.<sup>20</sup> Thus, even a suboptimal RFA may play a useful cytoreductive role. —**Table 4** summarizes results of RFA in pancreatic adenocarcinoma. Studies are limited to case series and highlight the feasibility of performing pancreatic RFA. Safety remains a concern with morbidity rates ranging from 10 to 40% in most studies. With refinement in devices and techniques, hopefully the complication rates will reduce in future. The reported survival after RFA in these patients ranged between 3 and 36 months. However, due to a lack of a comparative control group it is unclear if RFA leads to improved survival.

Another emerging indication for pancreatic RFA is EUS-guided RFA of the celiac ganglion for control of pain in pancreatic cancer. Bang et al compared effectiveness of EUS-celiac plexus neurolysis (CPN) and EUS-RFA for palliation of pain in pancreatic cancer and observed that patients treated with EUS-RFA experienced significantly less pain and less severe gastrointestinal (GI) symptoms than patients who were treated with EUS-CPN.<sup>21</sup> This needs to be substantiated through further studies.

## Conclusion

RFA is a useful technology in management of various GI conditions. In biliary tract, application of RFA has demonstrated improved stent patency and increased survival as well. It has also been successfully applied for benign

**Table 3** Results of EUS RFA in treatment of pancreatic NETs

Study	No. of patients	No. of PNET	Age, in years (range)	Sex	Functional/nonfunctional PNET	Mean size (range)	Location	RF device	RF session	Power (Watt)	Maximum degree	RFA duration (seconds)	Probe length (cm)	Efficacy	Follow-up (months)	Mild adverse events	Moderate adverse events	Severe adverse events
Rossi et al (2014) <sup>13</sup>	1	1	72	M	0/1	9	Head	Habib EUS RFA	1	10-15	90	360	190	100%	34	0	0	0
Armellini et al (2015) <sup>31</sup>	1	1	76	M	0/1	20	Tail	18 G, STARmed	1	NR	NR	NR	NR	100%	1	0	0	0
Pai et al (2015) <sup>32</sup>	2	2	69.5 (57-82)	F	0/2	27.5 (15-40)	Head	Habib EUS RFA	1.5 (1-2)	5-25	90-105	90-120	190	100%	6	2	0	0
Lakhtakia et al (2016) <sup>33</sup>	3	3	45 (41-52)	M	3/0	17.7 (14-22)	2 head, 1 body	19 G, STARmed	1	50	NR	10-15	140	100%	12	0	0	0
Waung et al (2016) <sup>34</sup>	1	1	70	F	1/0	18	Uncinate	Habib EUS RFA	3	10	NR	90-120	190	100%	10	0	0	0
Bas-Cutrina et al (2017) <sup>35</sup>	1	1	63	F	1/0	10	Body	Habib EUS RFA	1	10	NR	120	190	100%	10	0	0	0
Choi et al (2018) <sup>36</sup>	8	8	56.1 (34-70)	4 M, 4 F	1/7	20 (8-28)	3 head, 5 body	19 G, STARmed	1.75 (1-3)	50	NR	NR	140	75%	13	2	0	0
Thosani et al (2018) <sup>37</sup>	3	3	NR	NR	3/0	NR	NR	NR	NR	NR	NR	NR	NR	100%	5	0	0	0
Lamine et al (2018) <sup>38</sup>	1	1	69	F	1/0	12	Body	19 G, EUSRATM needle	1	50	NR	NR	140	100%	2	1	0	0
Barthel et al (2019) <sup>16</sup>	12	14	59.9 (45-77)	7 M, 5 F	0/14	13.1 (10-20)	3 head, 6 body, 5 tail	19 G, STARmed	NR	50	NR	NR	140	86%	12	1	1	0
Oleinikov et al (2019) <sup>39</sup>	18	27	60.4 (28-82)	10 M, 8 F	7/20	14.3 (4.5-30)	10 head, 8 body, 5 uncinate, 2 tail	19 G, STARmed	1	50	NR	5-12	140	96.3%	8.7	2	0	0
de Nucci et al (2020) <sup>40</sup>	10	11	78.6	6 M, 4 F	5/6	14.5 (9-20)	3 head, 5 body, 3 tail	19 G, STARmed	1	20	NR	10-15	140	100%	12	2	0	0

Abbreviations: F, female; M, male; NR, not reported; PNET, pancreatic neuroendocrine tumor; RF, radio frequency; RFA, radio frequency ablation.

**Table 4** Results of radio frequency ablation in pancreatic ductal adenocarcinoma

Authors	Number of patients	Age (years)	Morbidity (%)	Mortality (%)	Survival (months)
Matsui et al (2000) <sup>41</sup>	20	59	10	5	3
Wu et al (2006) <sup>42</sup>	16	67	37	19	–
Spillotis et al (2007) <sup>43</sup>	12	66	16	0	33
Girellie et al (2010) <sup>44</sup>	100	64	15	3	20
Singh et al (2011) <sup>45</sup>	10	45–72	10	0	9–36
Hadjicostas et al (2006) <sup>46</sup>	04	70	0	0	7
Varshney et al (2006) <sup>47</sup>	03	58	–	0	7
Casadei et al (2010) <sup>48</sup>	03	66	100	–	4
Zou et al (2010) <sup>49</sup>	32	68	9.3	–	17.6
Ikuta et al (2012) <sup>50</sup>	01	60	0	0	18
Date et al (2005) <sup>51</sup>	01	58	–	–	3

indications such as bilioenteric anastomotic strictures. Although there were initial safety concerns with pancreatic RFA, with refinement in technology and techniques, the rate of adverse events has reduced. RFA is effective in management of PNETs and PCNs, especially less than 2 cm in size. Role of RFA in management of unresectable pancreatic cancer remains to be defined. Adverse events are a concern and there is a lack of comparative data to determine any survival benefit. Future comparative studies with controls and use of newer RFA probes are needed. In addition, there are several upcoming technologies such as irreversible electroporation that appear to have the advantage of being selective for tissues and thus, potentially lower rates of complications. Comparison of RFA to these newer technologies will be needed to define its role in management of pancreatic and biliary conditions.

#### Grant Support

Midas Medical Foundation, Nagpur, India.

#### Conflict of Interest

None declared.

#### References

- 1 Cho JH, Lee KH, Kim JM, Kim YS, Lee DH, Jeong S. Safety and effectiveness of endobiliary radiofrequency ablation according to the different power and target temperature in a swine model. *J Gastroenterol Hepatol* 2017;32(02):521–526
- 2 Larghi A, Rimbaş M, Tringali A, Boškoski I, Rizzatti G, Costamagna G. Endoscopic radiofrequency biliary ablation treatment: a comprehensive review. *Dig Endosc* 2019;31(03):245–255
- 3 Barret M, Leblanc S, Vienne A, et al. Optimization of the generator settings for endobiliary radiofrequency ablation. *World J Gastrointest Endosc* 2015;7(16):1222–1229
- 4 Inoue T, Ibusuki M, Kitano R, et al. Endobiliary radiofrequency ablation combined with bilateral metal stent placement for malignant hilar biliary obstruction. *Endoscopy* 2020;52(07):595–599
- 5 Cui W, Fan W, Lu M, et al. Percutaneous intraductal radiofrequency ablation for malignant biliary obstruction caused by recurrence and metastasis after primary tumor resection. *Oncol Res Treat* 2018;41(1-2):22–28
- 6 Kong YL, Zhang HY, Liu CL, et al. Improving biliary stent patency for malignant obstructive jaundice using endobiliary radiofrequency ablation: experience in 150 patients. *Surg Endosc* 2022;36(03):1789–1798
- 7 Sofi AA, Khan MA, Das A, et al. Radiofrequency ablation combined with biliary stent placement versus stent placement alone for malignant biliary strictures: a systematic review and meta-analysis. *Gastrointest Endosc* 2018;87(04):944–951.e1
- 8 Kallis Y, Phillips N, Steel A, et al. Analysis of endoscopic radiofrequency ablation of biliary malignant strictures in pancreatic cancer suggests potential survival benefit. *Dig Dis Sci* 2015;60(11):3449–3455
- 9 Wadsworth CA, Westaby D, Khan SA. Endoscopic radiofrequency ablation for cholangiocarcinoma. *Curr Opin Gastroenterol* 2013;29(03):305–311
- 10 Laleman W, van der Merwe S, Verbeke L, et al. A new intraductal radiofrequency ablation device for inoperable biliopancreatic tumors complicated by obstructive jaundice: the IGNITE-1 study. *Endoscopy* 2017;49(10):977–982
- 11 Akinci D, Unal E, Ciftci TT, Kyendyebai S, Abbasoglu O, Akhan O. Endobiliary radiofrequency ablation in the percutaneous management of refractory benign bilioenteric anastomosis strictures. *AJR Am J Roentgenol* 2019;212(03):W83–W91
- 12 Inoue T, Ibusuki M, Kitano R, et al. Endoscopic ultrasound-guided antegrade radiofrequency ablation and metal stenting with hepaticoenterostomy for malignant biliary obstruction: a prospective preliminary study. *Clin Transl Gastroenterol* 2020;11(10):e00250
- 13 Rossi S, Viera FT, Ghittoni G, et al. Radiofrequency ablation of pancreatic neuroendocrine tumors: a pilot study of feasibility, efficacy, and safety. *Pancreas* 2014;43(06):938–945
- 14 Gaidhane M, Smith I, Ellen K, et al. Endoscopic ultrasound-guided radiofrequency ablation (EUS-RFA) of the pancreas in a porcine model. *Gastroenterol Res Pract* 2012;2012:431451
- 15 Song TJ, Seo DW, Lakhtakia S, et al. Initial experience of EUS-guided radiofrequency ablation of unresectable pancreatic cancer. *Gastrointest Endosc* 2016;83(02):440–443
- 16 Barthelet M, Giovannini M, Lesavre N, et al. Endoscopic ultrasound-guided radiofrequency ablation for pancreatic neuroendocrine tumors and pancreatic cystic neoplasms: a prospective multicenter study. *Endoscopy* 2019;51(09):836–842
- 17 Imperatore N, de Nucci G, Mandelli ED, et al. Endoscopic ultrasound-guided radiofrequency ablation of pancreatic

- neuroendocrine tumors: a systematic review of the literature. *Endosc Int Open* 2020;8(12):E1759–E1764
- 18 Hidalgo M. Pancreatic cancer. *N Engl J Med* 2010;362(17):1605–1617
  - 19 Cantore M, Girelli R, Mambrini A, et al. Combined modality treatment for patients with locally advanced pancreatic adenocarcinoma. *Br J Surg* 2012;99(08):1083–1088
  - 20 Haen SP, Pereira PL, Salih HR, Rammensee HG, Gouttefangeas C. More than just tumor destruction: immunomodulation by thermal ablation of cancer. *Clin Dev Immunol* 2011;2011:160250
  - 21 Bang JY, Sutton B, Hawes RH, Varadarajulu S. EUS-guided celiac ganglion radiofrequency ablation versus celiac plexus neurolysis for palliation of pain in pancreatic cancer: a randomized controlled trial (with videos). *Gastrointest Endosc* 2019;89(01):58–66.e3
  - 22 Navaneethan U, Thosani N, Goodman A, et al; ASGE Technology Committee. Radiofrequency ablation devices. *VideoGIE* 2017;2(10):252–259
  - 23 Sharaiha RZ, Natov N, Glockenberg KS, Widmer J, Gaidhane M, Kahaleh M. Comparison of metal stenting with radiofrequency ablation versus stenting alone for treating malignant biliary strictures: is there an added benefit? *Dig Dis Sci* 2014;59(12):3099–3102
  - 24 Hu B, Gao DJ, Zhang X, Zhang YC. Endobiliary radiofrequency ablation improve overall survival of cholangiocarcinoma: a multicenter randomized control study. *Gastrointest Endosc* 2016;83(05):AB126
  - 25 Wang J, Zhao L, Zhou C, et al. Percutaneous intraductal radiofrequency ablation combined with biliary stent placement for nonresectable malignant biliary obstruction improves stent patency but not survival. *Medicine (Baltimore)* 2016;95(15):e3329
  - 26 Dutta AK, Basavaraju U, Sales L, Leeds JS. Radiofrequency ablation for management of malignant biliary obstruction: a single-center experience and review of the literature. *Expert Rev Gastroenterol Hepatol* 2017;11(08):779–784
  - 27 Yang J, Wang J, Zhou H, et al. Efficacy and safety of endoscopic radiofrequency ablation for unresectable extrahepatic cholangiocarcinoma: a randomized trial. *Endoscopy* 2018;50(08):751–760
  - 28 Bokemeyer A, Matern P, Bettenworth D, et al. Endoscopic radiofrequency ablation prolongs survival of patients with unresectable hilar cholangiocellular carcinoma - a case-control study. *Sci Rep* 2019;9(01):13685
  - 29 Kang H, Chung MJ, Cho IR, et al. Efficacy and safety of palliative endobiliary radiofrequency ablation using a novel temperature-controlled catheter for malignant biliary stricture: a single-center prospective randomized phase II TRIAL. *Surg Endosc* 2021;35(01):63–73
  - 30 Gao DJ, Yang JF, Ma SR, et al. Endoscopic radiofrequency ablation plus plastic stent placement versus stent placement alone for unresectable extrahepatic biliary cancer: a multicenter randomized controlled trial. *Gastrointest Endosc* 2021;94(01):91–100.e2
  - 31 Armellini E, Crinò SF, Ballarè M, Occhipinti P. Endoscopic ultrasound-guided radiofrequency ablation of a pancreatic neuroendocrine tumor. *Endoscopy* 2015;47(1, Suppl 1 UCTN)E600–E601
  - 32 Pai M, Habib N, Senturk H, et al. Endoscopic ultrasound guided radiofrequency ablation, for pancreatic cystic neoplasms and neuroendocrine tumors. *World J Gastrointest Surg* 2015;7(04):52–59
  - 33 Lakhtakia S, Ramchandani M, Galasso D, et al. EUS-guided radiofrequency ablation for management of pancreatic insulinoma by using a novel needle electrode (with videos). *Gastrointest Endosc* 2016;83(01):234–239
  - 34 Waung JA, Todd JF, Keane MG, Pereira SP. Successful management of a sporadic pancreatic insulinoma by endoscopic ultrasound-guided radiofrequency ablation. *Endoscopy* 2016;48(Suppl 1):E144–E145
  - 35 Bas-Cutrina F, Bargalló D, Gornals JB. Small pancreatic insulinoma: successful endoscopic ultrasound-guided radiofrequency ablation in a single session using a 22-G fine needle. *Dig Endosc* 2017;29(05):636–638
  - 36 Choi JH, Seo DW, Song TJ, et al. Endoscopic ultrasound-guided radiofrequency ablation for management of benign solid pancreatic tumors. *Endoscopy* 2018;50(11):1099–1104
  - 37 Thosani N, Sharma NR, Raijman I, et al. Safety and efficacy of endoscopic ultrasound guided radiofrequency ablation (EUS-RFA) in the treatment of pancreatic lesions: a multi-center experience. *Gastrointest Endosc* 2018;87(06):AB84
  - 38 Lamine F, Godat S, Marino L, et al. A Case of Benign Insulinoma Successfully Treated with Endoscopic Ultrasound Guided Radiofrequency Ablation. *Bioscientifica*; 2018
  - 39 Oleinikov K, Dancour A, Epshtein J, et al. Endoscopic ultrasound-guided radiofrequency ablation: a new therapeutic approach for pancreatic neuroendocrine tumors. *J Clin Endocrinol Metab* 2019;104(07):2637–2647
  - 40 de Nucci G, Imperatore N, Mandelli ED, di Nuovo F, d'Urbano C, Manes G. Endoscopic ultrasound-guided radiofrequency ablation of pancreatic neuroendocrine tumors: a case series. *Endosc Int Open* 2020;8(12):E1754–E1758
  - 41 Matsui Y, Nakagawa A, Kamiyama Y, Yamamoto K, Kubo N, Nakase Y. Selective thermocoagulation of unresectable pancreatic cancers by using radiofrequency capacitive heating. *Pancreas* 2000;20(01):14–20
  - 42 Wu Y, Tang Z, Fang H, et al. High operative risk of cool-tip radiofrequency ablation for unresectable pancreatic head cancer. *J Surg Oncol* 2006;94(05):392–395
  - 43 Spiliotis JD, Datsis AC, Michalopoulos NV, et al. Radiofrequency ablation combined with palliative surgery may prolong survival of patients with advanced cancer of the pancreas. *Langenbecks Arch Surg* 2007;392(01):55–60
  - 44 Girelli R, Frigerio I, Salvia R, Barbi E, Tinazzi Martini P, Bassi C. Feasibility and safety of radiofrequency ablation for locally advanced pancreatic cancer. *Br J Surg* 2010;97(02):220–225
  - 45 Singh V, Varshney S, Sewkani A, et al. Radiofrequency ablation of unresectable pancreatic carcinoma: 10-year experience from single centre. *Pancreatol* 2011;11(Suppl 1):52
  - 46 Hadjicostas P, Malakounides N, Varianos C, Kitiiris E, Lerni F, Symeonides P. Radiofrequency ablation in pancreatic cancer. *HPB (Oxford)* 2006;8(01):61–64
  - 47 Varshney S, Sewkani A, Sharma S, et al. Radiofrequency ablation of unresectable pancreatic carcinoma: feasibility, efficacy and safety. *JOP* 2006;7(01):74–78
  - 48 Casadei R, Ricci C, Pezzilli R, et al. A prospective study on radiofrequency ablation locally advanced pancreatic cancer. *Hepatobiliary Pancreat Dis Int* 2010;9(03):306–311
  - 49 Zou YP, Li WM, Zheng F, et al. Intraoperative radiofrequency ablation combined with 125 iodine seed implantation for unresectable pancreatic cancer. *World J Gastroenterol* 2010;16(40):5104–5110
  - 50 Ikuta S, Kurimoto A, Iida H, et al. Optimal combination of radiofrequency ablation with chemoradiotherapy for locally advanced pancreatic cancer. *World J Clin Oncol* 2012;3(01):12–14
  - 51 Date RS, Siriwardena AK. Radiofrequency ablation of the pancreas. II: intra-operative ablation of non-resectable pancreatic cancer. A description of technique and initial outcome. *JOP* 2005;6(06):588–592