



Pure Red Cell Aplasia Encountered in a Tertiary Care Hematology Laboratory: A Series of Nine Distinctive Cases

Mansi Kala¹ Kunal Das² Avriti Baveja³ Manish Raturi⁴  Meghali Dhebane¹ Sohaib Ahmad⁵
Mansi Mehrotra¹

¹Department of Pathology, Himalayan Institute of Medical Sciences, Swami Rama Himalayan University, Jolly Grant Dehradun, Uttarakhand, India

²Division of Pediatric Oncology and Bone Marrow Transplantation, Department of Pediatrics, Himalayan Institute of Medical Sciences, Swami Rama Himalayan University, Dehradun, Uttarakhand, India

³Division of Hemato-oncology and Bone Marrow Transplantation, Department of Medicine, Himalayan Institute of Medical Sciences, Swami Rama Himalayan University, Dehradun, Uttarakhand, India

⁴Department of Immuno-hematology and Blood Transfusion, Himalayan Institute of Medical Sciences, Swami Rama Himalayan University, Jolly Grant Dehradun, Uttarakhand, India,

Address for correspondence Manish Raturi, MBBS, MD, Department of Immuno-hematology and Blood Transfusion, Himalayan Institute of Medical Sciences, Swami Rama Himalayan University, Swami Ram Nagar, Jolly Grant Dehradun, 248016, Uttarakhand, India (e-mail: manishraturi@srhu.edu.in).

⁵Department of Medicine, Himalayan Institute of Medical Sciences, Swami Rama Himalayan University, Jolly Grant Dehradun, Uttarakhand, India

J Lab Physicians 2023;15:316–320.

Abstract

Pure red cell aplasia (PRCA) is characterized by severe anemia with reticulocytopenia and bone marrow erythroblastopenia. The early erythroblasts are markedly decreased; however, in rare instances, they may be normal or raised in number. There are varied etiologies, namely congenital or acquired and primary or secondary. The congenital PRCA is known as “Diamond-Blackfan anemia.” Thymomas, autoimmune disease, lymphomas, infections, and drugs also may be familiar associates. However, the etiologies of PRCA are numerous, and many diseases/infections can be associated with PRCA. The diagnosis rests on clinical suspicion and appropriate laboratory workup. We evaluated nine cases of red cell aplasia, having severe anemia with reticulocytopenia. Nearly half of the cases showed adequate erythroid (> 5% of the differential count) but with a maturation arrest. The adequacy of the erythroid could confuse the hematologist and may even delay the diagnosis. Hence, it is empirical that PRCA could be considered a differential in every case of severe anemia with reticulocytopenia, even in the presence of adequate erythroid precursors in the bone marrow.

Keywords

- ▶ Diamond-Blackfan anemia
- ▶ red cell transfusion
- ▶ erythroblasts
- ▶ severe anemia

Introduction

Pure red cell aplasia (PRCA) is a hematological disorder characterized by markedly reduced erythropoiesis without affecting other cell lineages. PRCA affects all age groups.

Severe anemia with marked reticulocytopenia and 0.5% late erythroblasts characterize this problem. Sometimes, bone marrow shows the predominance of early proerythroblast and a complete absence of late erythroblasts. Bone marrow is usually normocellular showing no abnormality in other

article published online
October 20, 2022

DOI <https://doi.org/10.1055/s-0042-1757584>.
ISSN 0974-2727.

© 2022. The Indian Association of Laboratory Physicians. All rights reserved.

This is an open access article published by Thieme under the terms of the Creative Commons Attribution-NonDerivative-NonCommercial-License, permitting copying and reproduction so long as the original work is given appropriate credit. Contents may not be used for commercial purposes, or adapted, remixed, transformed or built upon. (<https://creativecommons.org/licenses/by-nc-nd/4.0/>)

Thieme Medical and Scientific Publishers Pvt. Ltd., A-12, 2nd Floor, Sector 2, Noida-201301 UP, India

lineages.¹ PRCA is primarily classified as genetic or acquired and further as primary and secondary. Of the genetic or congenital causes “Diamond-Blackfan anemia” (DBA) is well known. DBA is a sporadic heterogeneous disorder characterized by red cell aplasia and skeletal abnormalities soon after birth. It is often characterized by growth retardation and malformation of the head, heart, and lungs. The molecular mechanism behind this disorder is not clear; however, defective ribosomal biosynthesis signaled by the P53 gene has been implicated, which in turn causes apoptosis in erythroid progenitors. It is also important to know that all the DBA patients do not always show similar ribosomal protein mutation.² Rarely, Pearson syndrome, a congenital disorder affecting the mitochondria resulting in exocrine pancreatic defects, dyserythropoietic, and sideroblastic anemia may present with erythroblastopenia. Acquired PRCA can be further categorized as idiopathic and secondary to a variable number of disorders.³ The primary PRCA or the idiopathic forms are associated with autoimmune-mediated mechanisms mediated by T-cells and natural killer cells. In the pediatric population, transient decrease in erythroid precursors in the bone marrow is seen and is assumed to be secondary to autoimmune mechanisms. Secondary acquired PRCA may be associated with autoimmune diseases such as connective tissue disorders like systemic lupus erythematosus, rheumatoid arthritis, and viral infections including parvovirus B19 and human immunodeficiency virus commonly. Solid malignancy and sometimes pregnancy can very well contribute to secondary acquired PRCA. PRCA is reportedly seen in 1.6 to 4% of myelodysplastic syndrome (MDS) cases, especially MDS 5q deletion. The abnormal clonal stem cell differentiation and immune mechanism are known to cause this abnormality.⁴

For DBA, corticosteroid, blood transfusion, and stem cell transplantation are the current treatment options available.⁵ Myelodysplastic PRCA is treated with regimens appropriate for MDS. MDS associated with 5q deletion has a good prognosis and responds well to lenalidomide, provided additional clonal mutations or cytogenetic abnormalities are not present along with 5q deletion.⁶ Drug discontinuations can offer cure for medication-associated PRCA. Specific treatment of infection/s can relieve symptoms associated with PRCA.⁷ Similarly, chronic lymphocytic leukemia, T-cell large granular lymphocytic (T-LGL), Hodgkin's, Non-Hodgkin's lymphoma, solid tumors could cause red cell aplasia, and may be managed by addition of immunosuppressants or by treatment of the underlying disorders.⁸ Also, PRCA secondary to autoimmune disorders responds well to immunosuppression.⁹ Thymomas are complicated by PRCA and the treatment of choice is resection.¹⁰ The goal for PRCA management rests on attaining normal hemoglobin without requiring transfusion. Further, we wish to emphasize that a differential of PRCA could be thought of in every case of severe anemia with reticulocytopenia, even with adequate erythroid precursors in the bone marrow.

Materials and Methods

We are presenting the data of nine patients diagnosed with PRCA and treated at Himalayan Institute of Medical Sciences, SRHU Dehradun, Uttarakhand, over the past 4 years (2019–2022). The diagnosis was based on the peripheral blood findings and bone marrow examination demonstrating severe anemia with less than 1% reticulocyte count and selective erythroid suppression or maturation arrest (predominance of early erythroid precursors with < 0.5% of late normoblast) in a normocellular/hypercellular marrow with normal myeloid and megakaryocytic cell lineages, respectively.¹ Laboratory workup for acquired causes including autoimmune workup,¹ immunophenotyping to rule out hematolymphoid malignancy, cytogenetics for MDS, and molecular workup to look for defective ribosomal synthesis and was done as and when needed. The clinical data was obtained from patients' files and laboratory information system, respectively. Appropriate treatment was given to all the patients which included red cell transfusion and corticosteroids (prednisolone with 1–2 mg/kg/day with tapering dose).

Cyclosporine/methotrexate as immune-sparing agents were given and the response was assessed with respect to hemoglobin levels and transfusion dependence. Lenalidomide was given in MDS with 5q deletion. Good responders were defined as patients with more than 9 g/dL hemoglobin requiring no transfusion and partial responders with hemoglobin of (7–9) g/dL with either reduced requirement or having a long transfusion independent interval.¹¹

Results

During this study period, total of nine cases of red cell aplasia, where all of them presented with severe anemia and reticulocytopenia but with different etiologies, were noticed. Six out of nine cases were females. The clinical features, workup, diagnosis, and treatment are described (► **Table 1**). The age ranged from 3 months to 68 years. Most of them presented with shortness of breath and lethargy. B symptoms were observed in one case of T-LGL. There was hepatomegaly and direct hyperbilirubinemia in one case associated with brucellosis. Splenomegaly was present in one of the cases. Hemoglobin (g/dL) was 3 or less in all the cases. Reticulocyte count was less than 1% in all the cases. Bone Marrow was normocellular except for three cases. Erythroblastopenia was observed in four cases (► **Fig. 1**). The rest of the cases showed a predominance of immature erythroblast, suggesting a maturation arrest. Serum vitamin B12 /folic acid levels and iron studies were within normal limits, and autoimmune workup was negative in all but one case that was later diagnosed to be PRCA associated with mixed connective tissue disorder. A case of DBA with dysmorphic features and thumb and finger abnormalities was given immunosuppressive therapy and was offered bone marrow transplant. The patient with parvovirus B19 was given supportive treatment and was kept under follow-up. An elderly lady

Table 1 The clinical features, laboratory workup, suggested diagnosis, and management done

Parameters	Case 1	Case 2	Case 3	Case 4	Case 5	Case 6	Case 7	Case 8	Case 9
Age (years)/sex	0.8/F	24/F	26/F	1.3/M	0.25/M	34/M	65/F	68/F	60/F
Hepatomegaly	+	-	+	-	-	+	-	-	-
Splenomegaly	-	-	-	-	-	-	-	-	-
Hb (g/dL)	3.0	3.5	3.1	3.03	2.4	2.7	3.0	3.0	2.0
RC	< 1%	< 1%	< 1%	< 1%	< 1%	< 1%	< 1%	< 1%	< 1%
TLC	Normal	Normal	Normal	Normal	Normal	Normal	Normal	Lymphocytosis	Lymphocytosis
Platelets	Normal	Normal	Normal	Normal	Normal	Normal	Increased	Normal	Normal
BMC	NC	HC	NC	NC	NC	NC	NC	HC	HC
BME	10	6	1	4	1	14	12	3	14
Vit B12/Iron studies	Normal	Normal	Normal	Normal	Normal	Normal	Normal	Normal	Normal
DAT	Negative	Negative	Negative	Negative	Negative	Negative	Negative	Negative	Positive
IPT	Not done	Not done	Not done	Not done	Not done	Not done	Not done	T-cell expansion in marrow (CD 8)	T-cell expansion
Cytogenetics	Not done	Not done	Not done	Not done	Not done	Not done	5q deletion	Not done	Normal
Molecular Studies	Not done	Not done	Not done	Normal	Not done	Not done	Not done	Not done	Not done
Etiology	Idiopathic	Parvovirus	Idiopathic	Idiopathic	Suspected DBA	Brucella	MDS	T-LGL	Autoimmune
Treatment	CCS	CCS	CCS	CCS	CCS	Antibiotics	Lenalidomide	CTX/CCS	CCS
Responders	PR	R	PR	PR	PR	R	R	R	R

Abbreviations: BMC, bone marrow cellularity; BME, bone marrow erythroids; CCS, corticosteroids; CTX, chemotherapy; DAT, direct antiglobulin test; DBA, Diamond Blackfan anemia; HC, hypercellular; IPT, immunophenotyping with flow cytometry; NC, normocellular; PR, partial responders; R, responders; RC, reticulocyte count; T-LGL, T-cell large granular lymphocytic; TLC, total leucocyte count.

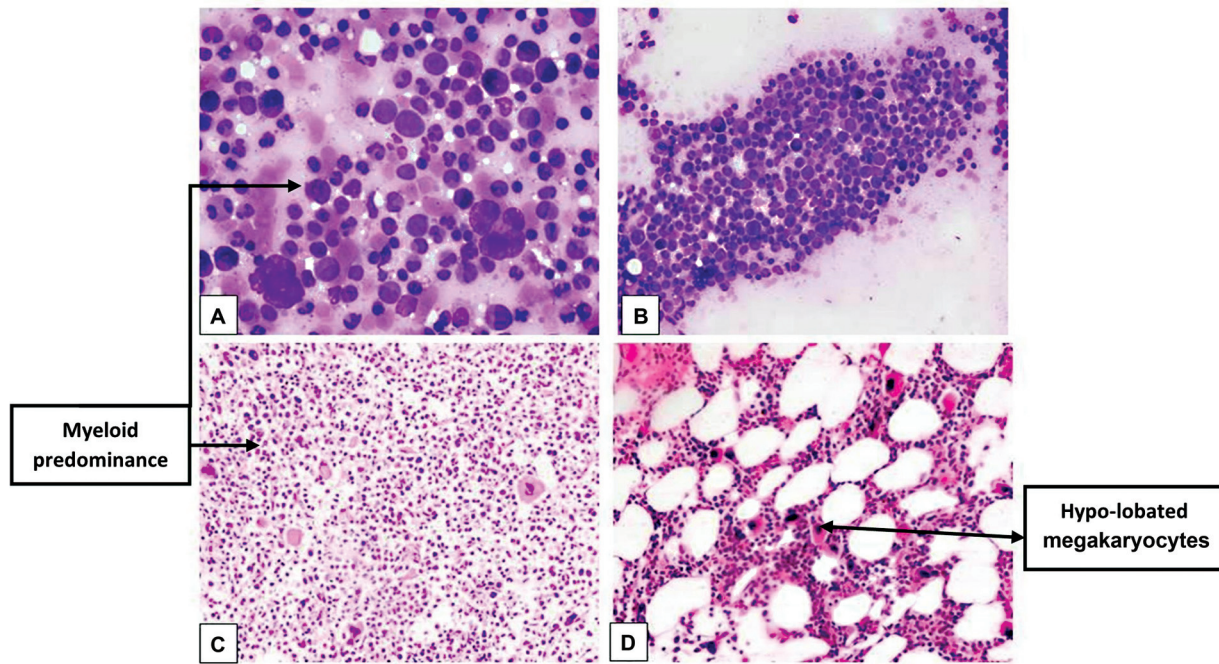


Fig. 1 (A, B) Bone marrow aspirate showing paucity of erythroids. (C) Bone marrow biopsy (BMB) depicting maturation arrest with paucity of erythroids and relative myeloid predominance. (D) BMB with reduced erythroids and increased hypolobated megakaryocytes (5q deletion).

with transfusion-dependent anemia and increased platelet counts was given lenalidomide. She was kept under follow-up and is presently stable. Patient with brucellosis was given antibiotic along with immunosuppressive therapy; however, the patient is lost to follow-up. Lastly, red cell aplasia with T-LGL was given immunosuppressive therapy and chemotherapy. Supportive therapy with packed red blood cell transfusions was given to all the patients. The first-line therapy offered was prednisone (1 mg/kg/day), with tapering of the dose when a response occurred. Cyclosporine-A was used as a second-line therapy to the steroid nonresponders who failed to show response within 8 weeks, as second-line therapy. All the pediatric cases were nonresponders, while in adults PRCA secondary to parvovirus, MDS, and T-LGL responded well.

Discussion

PRCA was first identified in the year 1922.³ It presents with normocytic normochromic and sometimes macrocytic anemia with a reticulocyte count less than 1%. There is often absence of late erythroblast or maturation arrest in the bone marrow.¹² PRCA can be secondary to the number of etiologies such as viral infections, autoimmune diseases, drugs, and toxins. Other causes of acquired PRCA include lymphoproliferative disorders, pregnancy, hematologic malignancies, and nonhematologic neoplasms, of which the association with thymoma is the best known in literature.¹³ Few studies in the past have suggested that 55% of cases in the adult group were secondary PRCA and in the pediatric group, the majority (59%) of patients were idiopathic in nature.¹⁴ This observation is in agreement with other large

oriental series that showed the secondary variety to be the commonest type found in adult patients.¹⁵ Our findings also suggested the same where all pediatric cases were found to be idiopathic and adult cases were secondary PRCA. In the majority of cases, the diagnosis of PRCA is straightforward as bone marrow examination typically shows less than 0.5% late erythroblasts. In some cases, enumeration of erythroblast in the bone marrow aspirate and biopsy may be normal or even increased with maturation arrest, hematogones, and lymphocytes.¹⁶ There will be a marked reduction in the late erythroblast and prominence of early erythroblast suggesting a maturation arrest. Maturation arrest in erythroid precursors, however, can also be seen in regenerating marrow; therefore, it is imperative that with such bone marrow findings to an extensive workup to rule out other etiologies should be performed. Nearly half the cases showed adequate erythroid precursors with a predominance of early form in the bone marrow examination; however, labeling them as PRCA was confusing and required an extensive workup.

Secondary PRCA must be ruled out by investigating underlying possible causes in all cases, as it has bearing on the treatment and outcome. Four of our cases were secondary to infection, lymphoma, and MDS. Appropriate therapy given in all these cases improved the hemoglobin and made them transfusion independent. Immunosuppressive therapies are beneficial in PRCA; hence, diagnosing them correctly and timely would add to the patient care. Few studies in the past such as Lacy et al have shown 34% response rates to corticosteroids.¹⁷ Furthermore, the pediatric cases on immunosuppressive therapy were partial responders on follow-up. One of the pediatric patients presented with skeletal abnormalities, wherein the molecular workup revealed a ribosomal

abnormality. The other pediatric case showed no ribosomal abnormality despite molecular workup. Bone marrow transplant was offered to both; however, both of them were lost to follow-up.

To sum up, patients with PRCA have severe anemia and reticulocyte count less than 1%. Bone marrow examination typically shows less than 0.5% late erythroblasts. It is important to note that a classical picture is not always seen; erythroid may be adequate or even increased with the predominance of early precursors suggesting a maturation arrest. It is also important to exclude other causes to fetch a timely diagnosis of PRCA.

Informed Consent

As per our hospital transfusion policy, an informed consent is obtained from all blood recipients prior to blood administration.

Ethical Approval

All procedures performed in studies involving human participants were in accordance with the ethical standards of the Institutional Ethics Committee [Ref No. SRHU/HIMS/RC/2022/156 dated 27/04/22] and with the 1964 Helsinki Declaration and its later amendments or comparable ethical standards. The article does not contain any regulated animal related research.

Authors' Contributions

M.K. and M.R. designed the concept. M.K., M.R., and K.D. did the literature search. M.K. and M.D. compiled the data. M.K., K.D., M.R., and A.B. prepared and edited and reviewed the manuscript. M.K., M.R., M.M., and S.A. reviewed the manuscript. M.R., as a guarantor, takes the responsibility of the integrity of the work, as a whole, right from its inception to being a published article.

Funding

None.

Conflict of Interest

None declared.

References

- Means RT Jr. Pure red cell aplasia. *Hematology (Am Soc Hematol Educ Program)* 2016;2016(01):51–56
- Engidaye G, Melku M, Enawgaw B. Diamond blackfan anemia: genetics, pathogenesis, diagnosis and treatment. *EJIFCC* 2019;30(01):67–81
- Alfaraj MM, Al Saeed HH. Pure red cell aplasia, a disease of a great diversity. *J Appl Hematol* 2020;11:1–6
- Cazzola M. Myelodysplastic syndromes. *N Engl J Med* 2020;383(14):1358–1374
- Ruggero D, Shimamura A. Marrow failure: a window into ribosome biology. *Blood* 2014;124(18):2784–2792
- Cerchione C, Catalano L, Cerciello G, et al. Role of lenalidomide in the management of myelodysplastic syndromes with del(5q) associated with pure red cell aplasia (PRCA). *Ann Hematol* 2015;94(03):531–534
- Ide T, Sata M, Nouno R, Yamashita F, Nakano H, Tanikawa K. Clinical evaluation of four cases of acute viral hepatitis complicated by pure red cell aplasia. *Am J Gastroenterol* 1994;89(02):257–262
- Vlachaki E, Diamantidis MD, Klonizakis P, Haralambidou-Vranitsa S, Ioannidou-Papagiannaki E, Klonizakis I. Pure red cell aplasia and lymphoproliferative disorders: an infrequent association. *ScientificWorldJournal* 2012;2012:475313
- Weerasinghe S, Karunathilake P, Ralapanawa U, Jayalath T, Abeygunawardena S, Rathnayaka M. Pure red cell aplasia secondary to rheumatoid arthritis: a case report. *J Med Case Reports* 2021;15(01):578
- Lesire B, Durieux V, Grigoriu B, Girard N, Berghmans T. Management of thymoma associated autoimmune pure red cell aplasia: case report and systematic review of the literature. *Lung Cancer* 2021;157:131–146
- Balasubramanian SK, Sadaps M, Thota S, et al. Rational management approach to pure red cell aplasia. *Haematologica* 2018;103(02):221–230
- Sawada K, Fujishima N, Hirokawa M. Acquired pure red cell aplasia: updated review of treatment. *Br J Haematol* 2008;142(04):505–514
- Means RT Jr. Pure red cell aplasia. *Blood* 2016;128(21):2504–2509
- Srinivas U, Mahapatra M, Saxena R, Pati HP. Thirty-nine cases of pure red cell aplasia: a single center experience from India. *Hematology* 2007;12(03):245–248
- Mamiya S, Itoh T, Miura AB. Acquired pure red cell aplasia in Japan. *Eur J Haematol* 1997;59(04):199–205
- Charles RJ, Sabo KM, Kidd PG, Abkowitz JL. The pathophysiology of pure red cell aplasia: implications for therapy. *Blood* 1996;87(11):4831–4838
- Lacy MQ, Kurtin PJ, Tefferi A. Pure red cell aplasia: association with large granular lymphocyte leukemia and the prognostic value of cytogenetic abnormalities. *Blood* 1996;87(07):3000–3006