



# Comparison of Pre- and Posttreatment Airway Volume in Patients with Temporomandibular Joint Disorders Treated with Ultra-Low Frequency Transcutaneous Electrical Nerve Stimulation Using Cone Beam Computed Tomography

Rhea Susan Verghese<sup>1</sup> Renju Jose<sup>1</sup> Anu Ramachandran<sup>1</sup> Aravind M. Shanmugham<sup>1</sup>   
Priya K. Nair<sup>1</sup> Krishna S. Kumar<sup>1</sup> Beena R. Varma<sup>1</sup>

<sup>1</sup>Department of Oral Medicine and Radiology, Amrita School of Dentistry, Amrita Vishwa Vidyapeetham, Amrita Institute of Medical Sciences and Research Centre, Kochi, Kerala, India.

Address for correspondence Dr. Renju Jose, BDS, MDS, PGCE, Department of Oral Medicine and Radiology, Amrita School of Dentistry, Amrita Vishwa Vidyapeetham, Amrita Institute of Medical Sciences and Research Centre, AIMS P.O., Ponekkara, Kochi, Kerala 682041, India (e-mail: renjudr@gmail.com).

Int Arch Otorhinolaryngol 2023;27(4):e593–e601.

## Abstract

### Keywords

- ▶ transcutaneous electrical nerve stimulation
- ▶ temporomandibular joint disorders
- ▶ cone beam computed tomography
- ▶ oropharyngeal airway volume

**Introduction** Temporomandibular joint disorders (TMD) present with a multitude of symptoms that can range from headaches to shoulder pain. Patients frequently present with pain in the ear, dizziness, and vertigo. It is noted that some patients who report TMDs also have a history of sleep disturbances, which is noted in cone beam computed tomography (CBCT) as a reduction in the oropharyngeal airway volume.

**Objective** To evaluate the airway volume in pre- and posttreatment of TMD with the use of neuromuscular orthotics made with ultra-low frequency transcutaneous electrical nerve stimulation (ULF-TENS).

**Methods** A total of 15 patients were evaluated for TMDs using the related criteria. Those included were treated with ULF-TENS with evaluation of the airway volume both pre- and posttreatment using CBCT and the Dolphin 3D volume analysis software.

**Results** While the symptoms were shown to be significantly reduced in patients who were treated with this particular modality, the airway volume varied in those who reported a reduction after a period of 3 months and those that reported after a period of 6 months.

**Conclusion** Posttreatment evaluation of the airway should be done after a period of 6 months for a more objective evaluation. A multidisciplinary evaluation of the patient is required in such cases.

## Introduction

Temporomandibular joint disorders (TMD) can cause pain in the temporomandibular joint (TMJ) or surrounding tissues as

well as functional limitations in the jaw and clicking in the TMJ during movements. It is also defined as conditions that cause aberrant, incomplete, or impaired function of the TMJ

received  
October 15, 2021  
accepted  
July 19, 2022

DOI <https://doi.org/10.1055/s-0042-1758207>.  
ISSN 1809-9777.

© 2023, Fundação Otorrinolaringologia. All rights reserved.  
This is an open access article published by Thieme under the terms of the Creative Commons Attribution-NonDerivative-NonCommercial-License, permitting copying and reproduction so long as the original work is given appropriate credit. Contents may not be used for commercial purposes, or adapted, remixed, transformed or built upon. (<https://creativecommons.org/licenses/by-nc-nd/4.0/>)  
Thieme Revinter Publicações Ltda., Rua do Matoso 170, Rio de Janeiro, RJ, CEP 20270-135, Brazil

or a collection of masticatory system symptoms recorded in diverse combinations. However, there is no definite definition until now. These disorders are fairly common and usually self-limiting in nature and mostly found in women, affecting from 75 to 84% of those affected by the disorder.<sup>1,2</sup>

James Costen first described it as symptoms located around the ear and TMJ, and it was dubbed “Costen syndrome” in 1934. In 1959, it was then termed “temporomandibular joint dysfunction syndrome,” and later renamed as “functional temporomandibular joint disturbances” by Ash and Ramfjord. Later, Bell reported that the problems related not only to the joints but the dysfunction of the masticatory system should it be considered, and the term “temporomandibular joint disorders” achieved popularity.<sup>3</sup>

Neuromuscular dentistry was first introduced by Dr. Bernard Jankelson in the year of 1967. It works on the concept that the masticatory system is three-dimensional, composed of teeth, TMJ, and muscles; furthermore, it is a dynamic system that follows anatomic and physiologic laws. While the technology for the measurement of masticatory function was not available, there was a universal consensus that approximately 90% of the TMDs are myogenous in nature.

The neuromuscular paradigm is based on the neurophysiologic principles that the biomechanics of occlusion follow the masticatory apparatus's three components. Furthermore, the occlusion proprioceptive information affects the musculoskeletal system, and dysfunction in other areas of the body can also affect occlusion. It also follows the universal principle of pathophysiology, in which pain and dysfunction of the affected structures occur when the need for accommodation exceeds the adaptive capacity of the affected structures. The neuromuscular paradigm is conducted in two stages, with the reversible phase bringing the dental occlusion to a myocentric occlusion, and the irreversible phase conducted by prosthetic or orthodontic management, as it states that TMDs occur due to reduced posterior occlusal support.<sup>4</sup> This is a noninvasive method of decompressing the joint, as its stability in the long run is primarily dependent on the expansion of joint space, and it can help control the processes of degenerative joint diseases, including disc displacements.<sup>5</sup>

Since the development of the nasomaxillary complex, mandible, TMJs, and occlusion are guided by the airway. It is noted that they have an inverse relationship, so narrowing of the facial features and malocclusion can happen to maintain the airway's patency.<sup>6</sup> The factors that can affect the airway include the size, shape, and position of the mandible, leading to the reduction of the airway in the oropharyngeal segment, which could lead to sleep-disordered breathing.<sup>7</sup> Harrell Jr. et al. reported a case of TMD and associated sleep-disordered breathing treated by use of a centric occlusion splint and followed by orthodontic treatment and orthognathic surgery. Though initially planned for the use of a splint in the centric relation, the reduction of the airway noted while assessing the cone beam computed tomography (CBCT) required the use of the splint in centric occlusion. It was noted that changes in the airway dimension can occur

from altered positions of the TMJs, so the clinician must evaluate the airway in both centric relation and centric occlusion.<sup>8</sup> Mummolo et al., in their study, found that the use of ultra-low frequency transcutaneous electrical nerve stimulation (ULF-TENS) system was effective in management of temporomandibular disorders.<sup>9</sup> The primary aim of this study was to evaluate the airway volume in pre- and post-treatment TMDs with neuromuscular orthotics made with ULF-TENS.

## Materials and Methods

This study was approved by the Institutional Review Board, under the ethical approval protocol number: IRB-AIMS-2019-154. Patients were told the objective and motive behind the study. An informed consent was obtained from those who agreed to take part in the research.

### Study Design and Setting

This is a single-institution pre- and posttreatment observational, pilot study. The study included 15 patients with TMD who satisfied the criteria of joint pain radiating to the head, neck, and arms, as well as joint sounds and trouble opening and closing the mouth.

The exclusion criteria were patients suffering from disorders of the TMJ satisfying the diagnostic criteria for TMDs, those who had previously been diagnosed with obstructive sleep apnoea and received dental orthotics, those with congenital abnormalities in the condyles, those wearing pacemakers, those suffering of epilepsy, and those under 12-years-old were excluded from the study.

Patients who presented to the department with signs and symptoms of TMD were evaluated and included if they met the diagnostic criteria. Pain on palpation of the muscles was evaluated on a 4-point scale ranging from 0 to 3. Mouth opening, and symptom severity score were also evaluated. Patients who agreed to participate in the study gave their informed consent, and a CBCT pretreatment was performed. The patients were asked to stand with their teeth in the maximal intercuspal position and their heads parallel to the floor with the Frankfort horizontal plane. The volume rendering CS 3D imaging (Carestream Dental LLC., Atlanta, GA, USA) software was used to recreate the views into 3D images.

Using the Dolphin 3D (Dolphin Imaging & Management Solutions, Chatsworth, CA, USA) software, the posterior nasal spine, dens, anteroinferior limit of the C3 vertebrae, anterior limit of the hyoid, and inferior point of the uvula were utilized to establish an area of interest in the midsagittal plane to measure the pharyngeal dimensions. This produced a polygon, which was then marked using a seed point tool, which automatically colored the area of interest and generated a 3D image with the volume's numerical values expressed in mm<sup>3</sup>.

The maxillary and mandibular impressions of the patient were taken. The J5 Myotronics ULF-TENS device (Myotronics-Noromed Inc., Kent, WA, USA) was applied for 60 minutes, after which a bite registration paste was used to register the neuromuscular position intraorally. The therapeutic occlusal

position was referenced by this bite registration, and the therapeutic mandibular orthotic device was created with it as base. This was then used to construct an anatomic orthotic, with an increase in the vertical dimension following the occlusal surface of the teeth, made of acetyl resin, which provides good functionality and strength for the maintenance of patients' normal physiological activities. These were worn 24 hours a day, seven days a week, and patients were evaluated for occlusal interferences at 1-week, 1-month, and 3-month intervals.

Symptom scores of the patients were taken at each of these visits, and a post treatment CBCT was taken when patients reported a drastic reduction of the symptoms to analyze the airway volume, as per the evaluation in the pretreatment scan. The symptom score was calculated from a self-reporting questionnaire of 45 symptoms. The two CBCT scans were taken with utmost care and adhering to ALADA guidelines, for evaluation posttreatment and for further prosthetic management.

### Statistical Analysis

The Statistical Package Social Sciences (SPSS, IBM Corp., Armonk, NY, USA) software, version 20.0, was used to conduct the statistical analysis. The median and interquartile range was used to depict numerical variables. The Wilcoxon signed rank test was used to determine the statistical significance of the difference in median airway volume and symptoms between pre- and posttreatment data. The McNemar chi-square test was used to determine the statistical significance of the difference in the proportion of the visual analog scale (VAS) for pain between pre- and posttreatment findings. Statistical significance was defined as  $p$ -values of less than 0.05.

### Results

A total of 15 patients, 14 females and 1 male, who were diagnosed with TMDs, ranging from myofascial pain to osteoarthritis, were assessed, and they constituted the study sample. The minimum age of the study population was found to be 19 and the maximum age 68, with the average being  $41.42 \pm 16.10$  years. It was found that 1 (6.66%) patient was diagnosed with degenerative joint disease, 11 (73.33%) with internal derangement, and 3 (20.0%) myofascial pain dysfunction syndrome.

This is a pilot study comparing the airway volume of the patients with TMDs pre- and posttreatment with a neuromuscular orthotic. It was noted that there was significant reduction in the symptoms in the patients treated with the neuromuscular orthotic, however, there was no significant increase in the airway volume in those who reported a reduction of the symptoms within 6 months. But with a  $p$ -value of 0.059, the difference in airway volume was very close to being statistically significant in those that reported a reduction of the symptoms after a period of 6 months. This could indicate that it would be beneficial for the posttreatment evaluation of the patient be done after 6 months to get

a more objective result regarding the change in airway volume measurements.

► **Figs. 1 and 2** elucidate the evaluation of the airway volume in patients pre and posttreatment.

► **Table 1** elaborates the results obtained during the study, with the varying time durations at which the patients had reported complete relief.

### Comparison of the Symptoms pre- and posttreatment

► **Fig. 3** shows comparison of the symptoms pre- and posttreatment. The median (Q1, Q3) at baseline is 12 (9, 23) and at the completion of treatment it is 0 (0, 1), which shows that there is a significant improvement in the posttreatment symptoms ( $p = 0.001$ ).

### Comparison of the Airway Volume Pre- and Posttreatment

► **Fig. 4** shows the comparison of the airway volume pre- and posttreatment. The median (Q1, Q3) at baseline is 11,936.0 mm<sup>3</sup> (10,288.0 mm<sup>3</sup>, 14,685.0 mm<sup>3</sup>) and at completion of treatment it is 12,867.0 mm<sup>3</sup> (11,733.0 mm<sup>3</sup>, 16,332.0 mm<sup>3</sup>), which demonstrates no significant improvement in the airway volume post intervention ( $p = 0.427$ ).

Taking into account the two varying time periods during which the patient reported significant reduction of the symptoms -

### Comparison of the Symptoms at Less than 6 months

► **Fig. 5** shows the comparison of the symptoms pre- and posttreatment. The median (Q1, Q3) at baseline is 13 (10, 17) and at the completion of treatment it is 0 (0, 0), which shows that there is significant improvement in the symptoms post intervention ( $p = 0.043$ ).

### Comparison of the Airway Volume at Less Than 6 Months

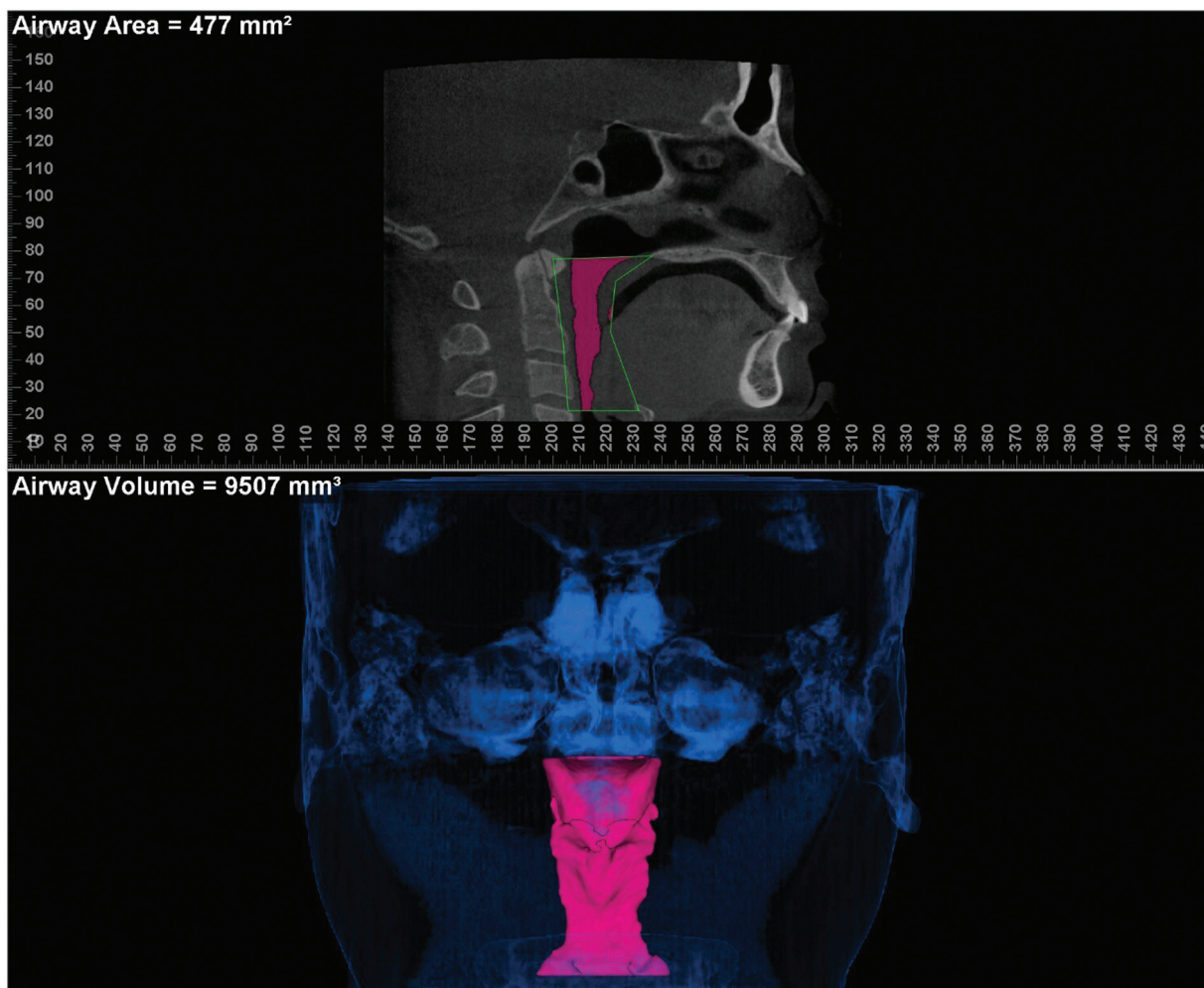
► **Fig. 6** shows the comparison of the airway volume pre- and posttreatment. The median (Q1, Q3) at baseline is 10,799.0 mm<sup>3</sup> (10,429.0 mm<sup>3</sup>, 29,596.0 mm<sup>3</sup>) and at completion of treatment it is 11,733.0 mm<sup>3</sup> (8,353.5 mm<sup>3</sup>, 26,333.0 mm<sup>3</sup>), which demonstrates no significant improvement in the airway volume post intervention ( $p = 0.138$ ).

### Comparison of the Symptoms at More Than 6 Months

► **Fig. 7** shows the comparison of the symptoms pre- and posttreatment. The median (Q1, Q3) at baseline is 9 (9, 27.5) and at the completion of treatment is 0 (0, 1), which shows that there is significant improvement in the symptoms post intervention ( $p = 0.008$ ).

### Comparison of the Airway Volume at More Than 6 Months

► **Fig. 8** shows the comparison of the airway volume pre- and posttreatment. The median (Q1, Q3) at baseline is 11,733.0 mm<sup>3</sup> (8,353.5 mm<sup>3</sup>, 15,372.75 mm<sup>3</sup>) and at completion of treatment interval is 13,215.5 mm<sup>3</sup> (12,647.0 mm<sup>3</sup>,



**Fig. 1** Evaluation of pretreatment airway volume.

17,327.0 mm<sup>3</sup>), which shows that, while clinically significant for each patient, there is no statistical significance ( $p = 0.059$ ).

## Discussion

There are many symptoms associated with TMDs, ranging from headaches to shoulder pain and numbness in the arms, and even aural symptoms like otalgia, tinnitus, vertigo, dizziness, fullness of the ear, hyper- or hypoacusia, with no auditory pathology. However, patients with ambiguous history and positive physical findings should get evaluated by an otorhinolaryngologist. It was reported that approximately 85% of patients who reported with symptoms of TMDs had ear symptomology as well.<sup>10,11</sup>

A study by Vasconcelos et al. in 2016 found that there was a significant correlation between severe TMDs and otalgia, ear fullness, and ear pruritis.<sup>12</sup> The presence of these symptoms could be attributed to the embryonic origins of the TMJ and the middle ear from the Meckel cartilage.

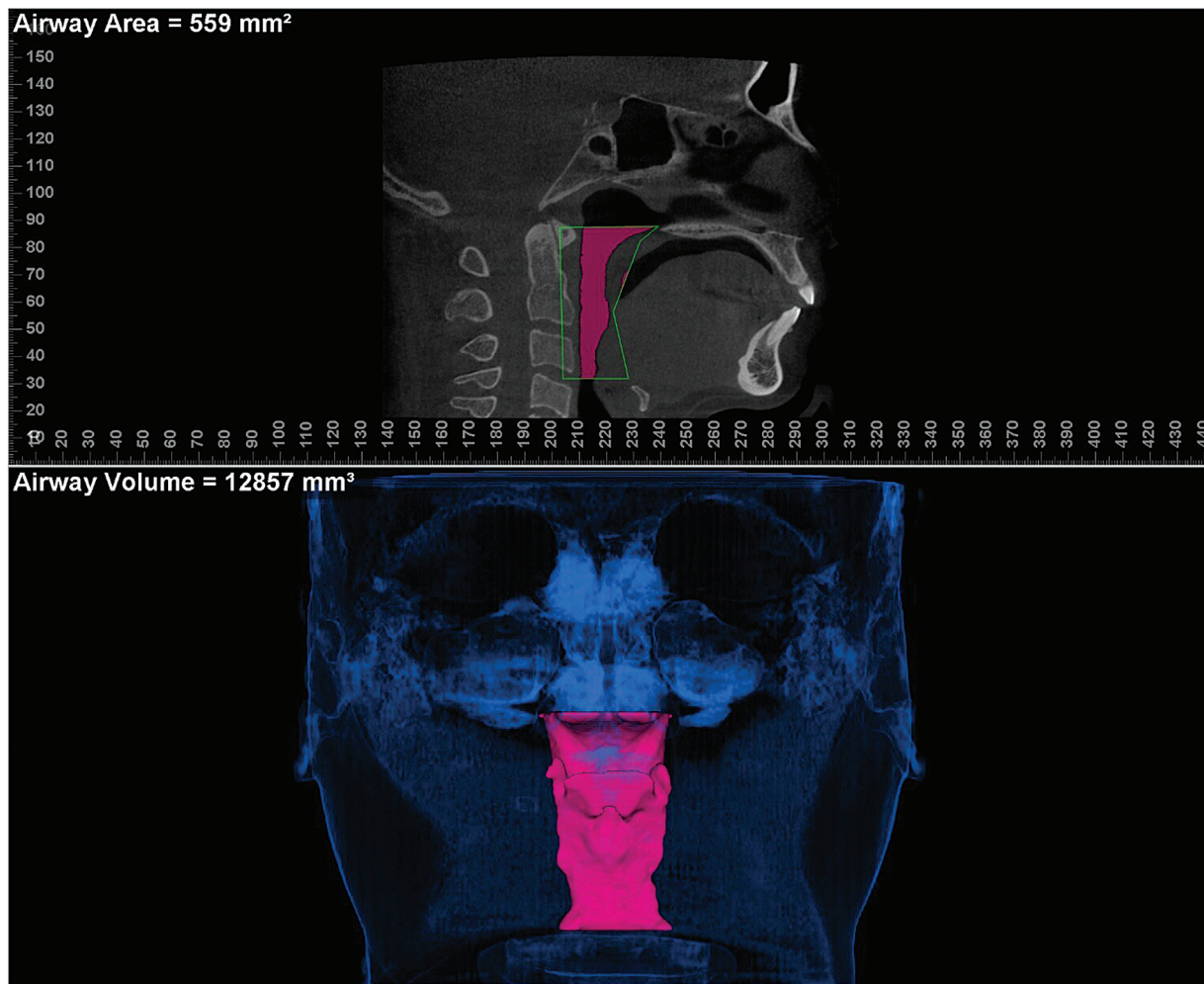
The development of the nasomaxillary complex, mandible, and TMJ are guided by the airway, which implies the physiopathology of sleep-disordered breathing and the TMJ are connected.<sup>6</sup> Furthermore, TMDs are considered to be multifactorial diseases with the three main components

being the masticatory muscles, occlusion, and joint. The dysfunction in the occlusion can cause disharmony in the masticatory muscles and vice versa. These diseases are noted to affect the female population more than the male population, especially in the age range of 20 to 40-years-old. It was also mentioned that there was a decreasing distribution of the disease with age, which could indicate the limiting feature of the disease. The present study highlighted the presence of a higher female predilection, which is similar to the studies reported by Bagis et al., Ferreira et al., and Jo et al.<sup>13-15</sup> Furthermore, the average age of the population is  $41 \pm 16$  years, with the minimum age being 19 and the maximum being 68, similar to a study by Ferreira et al.<sup>14</sup>

The most common symptoms among the study population being the presence of headaches, joint noises, pain while opening and closing the mouth, and the presence of discomfort in the ear, which were similar to those reported in the studies by Cooper and Kleinberg, Campbell et al., Raman, and List et al.<sup>16-19</sup>

Since the presence of TMDs is multifactorial, there are several ways used to treat patients, with the most common ones including the use of splints. Appliances with an increased vertical dimension were noted to have a significant improvement in the function of the patients and a reduction





**Fig. 2** Evaluation of posttreatment airway volume.

in symptoms reported by patients within a period of 3 and 6 months. The increased vertical dimension aids in the reduction of the joint loading, which helps in the reduction of the symptoms.<sup>20–23</sup> The use of neuromuscular orthotics as management was considered due to the substantial amount of evidence showing that TMDs have a high prevalence of muscle tension headaches.

The use of neural stimulation in pain relief helps to bring the mandible into a physiologically acceptable position, as well as having a significant improvement of the physiological state of the masticatory system.<sup>24</sup> This was demonstrated to be similar to our study with the use of an orthotics for the treatment of TMD. The patients reported a significant reduction in the symptoms in two particular time periods, be-

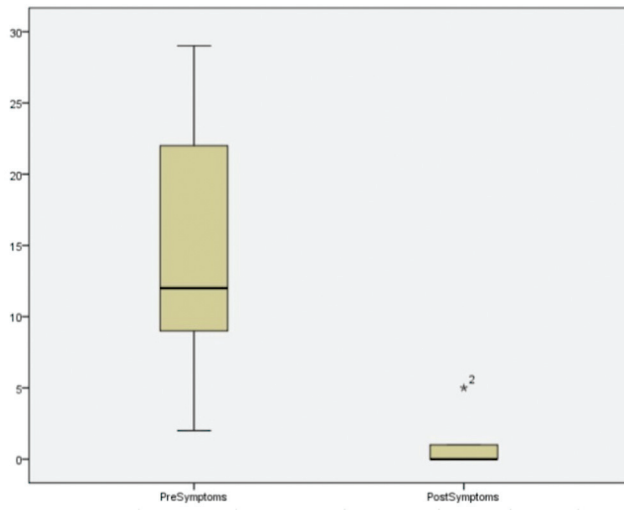
tween 3 and 6 months and over 6 months. This could be explained by central sensitization, which occurs in patients with TMJ abnormalities and generates an overresponsiveness of nociceptive receptors, hence depressing the central opioid pathway. The stimulus may have originated in the deep fascia, but as it becomes more chronic, it tends to have an effect on the autonomic nervous system, indicating a longer time period for patients' subjective reaction to suggest symptom decrease.<sup>25</sup>

Another method that is now becoming popular in the treatment of TMDs is the use of ULF-TENS, as it has no side effects and can reduce pain and EMG activity. The mechanism of action of this treatment is by blocking of the nociceptive stimulus by the neural stimulation, and keeping

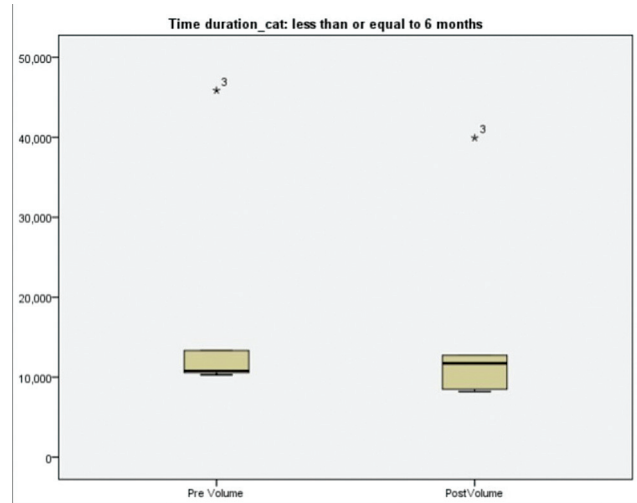
**Table 1** Results – Number of Symptoms and Airway Volume

Patient	Pretreatment Airway Volume (Mean ± SD)	Posttreatment Airway Volume (Mean ± SD)	p-value	Pretreatment Symptoms (Mean ± SD)	Posttreatment Symptoms (Mean ± SD)	p-value
> 6 months	12,788 ± 3,875.24	14,483.5 ± 3,849	0.059	15.3 ± 9.5	0.6 ± 1.4	0.008
< 6 months	18,170 ± 13,887	16,221 ± 11,986	0.138	13.4 ± 3.2	0 ± 0	0.043

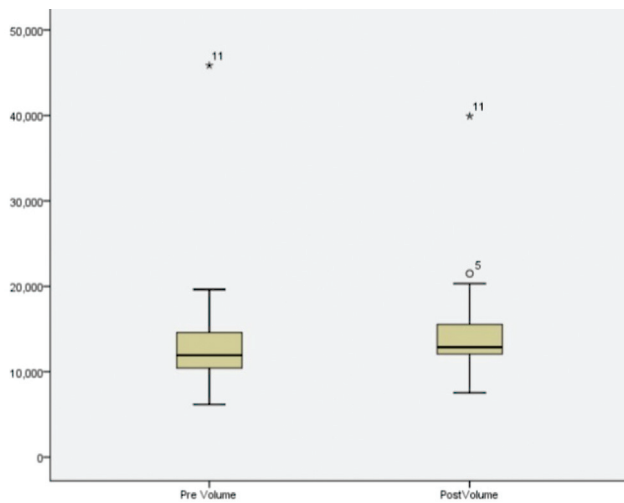
Abbreviation: SD, standard deviation.



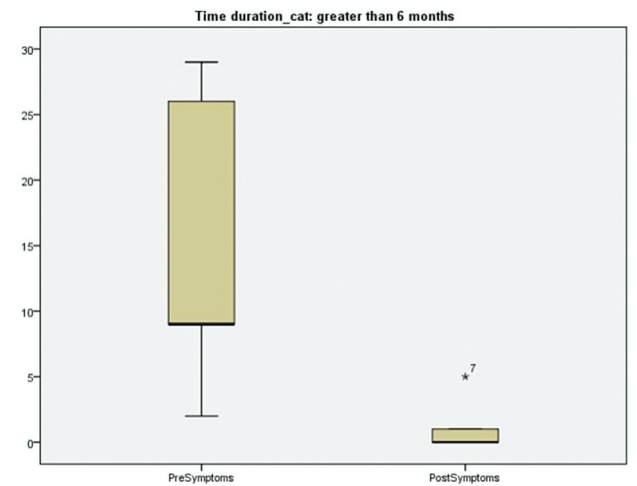
**Fig. 3** Comparison of symptoms pre- and posttreatment.



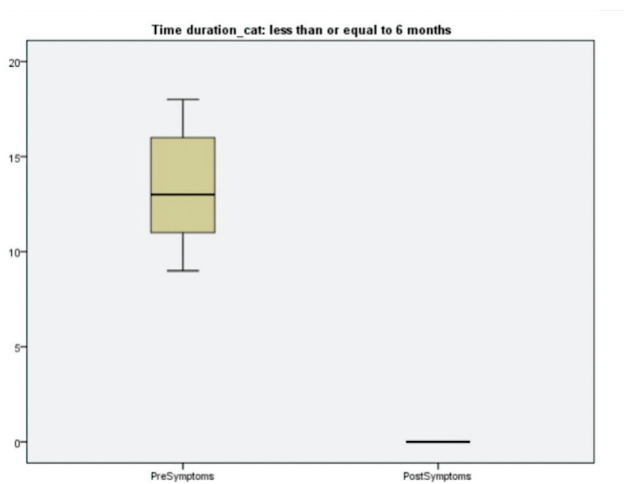
**Fig. 6** Comparison of airway volume at less than 6 months.



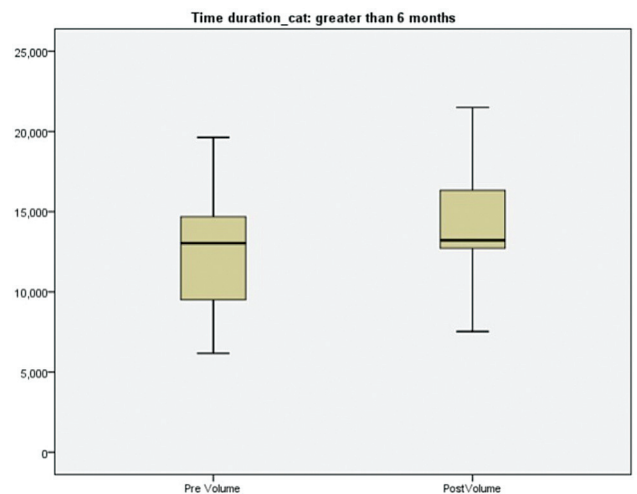
**Fig. 4** Pre- and posttreatment evaluation of airway volume.



**Fig. 7** Comparison of symptoms at more than 6 months.



**Fig. 5** Comparison of symptoms at less than 6 months.



**Fig. 8** Comparison of airway volume at more than 6 months.

the muscles under constant contraction at equal intervals of 1.5 s. It aids in bringing the mandible into a structurally more physiologically acceptable position, which could be considered as an anterior position of the condyle. Furthermore, there is a significant reduction in the resting muscle activity of the patient.<sup>26</sup> Most patients report a reduction in the pain immediately after the treatment, though this only lasts for a period of 4 to 5 hours. This position is stabilized by the use of the orthotic fabricated in the neuromuscular functional position for a period of 3 months.<sup>20</sup>

This was similar to our study, in which the patients reported a statistically significant reduction in symptoms after a period of 3 to 6 months ( $p = 0.043$ ) and over 6 months ( $p = 0.008$ ).

In this study, patients were subjectively evaluated regarding the pain on palpation of the mastication muscles and the number of symptoms they presented with. All patients reported moderate and severe pain intensity on palpation, and the number of symptoms ranged from 29 in the patient with the most symptoms to 2 in the patients with the least number of symptoms. Posttreatment, all but one patient reported a significant reduction of symptoms and intensity of pain.

Imaging is an important part of the evaluation of the patient. The use of CBCT has been well demonstrated in the literature, and this study corroborates its use in the evaluation of the airway and TMJ. While there are studies which evaluate the use of a lateral cephalogram versus the CBCT, they both have been found to be reliable in the use of evaluation of the airway. Furthermore, the CBCT provides a good adjunct to the clinical diagnosis and in the identification of any immediate obstructions in the airway.<sup>27-29</sup> There are case studies which use magnetic resonance imaging (MRI) to evaluate the airway and TMDs, which observe that it does give an objective data in the pre- and posttreatment radiological assessment.<sup>30-32</sup> reported that MRI and CBCT in patients with TMDs are complementary to each other, however, it would be indicated more in a younger patient. In a systematic review conducted by Veerappan et al.,<sup>33</sup> regarding the reliability of the CBCT versus MDCT in the assessment of TMDs such as erosions, osteophyte formation, sclerosis, and pseudocysts, both techniques were found to be reliable. In the present study, we used a full FOV CBCT for the evaluation of the TMJ and airway, since it is a newer imaging modality that allows for lower radiation exposure, as well as being more cost effective for the patient, which led to higher patient compliance. Our study population had a mean age of 41, which could be considered as middle aged and more compliant for evaluation using CBCT.

The correlation of symptoms and intensity of the pain was found in our study, where most of the patients presented with the posterior positioning of the condyle. This was found to be similar to the study conducted by Paknahad et al.<sup>34</sup> where they evaluated the clinical dysfunction index against the radiographic evaluation of the condyle, and it was noted that in patients with the severe dysfunction index the condyle was posteriorly positioned, and in those with mild to moderate dysfunction the condyle was anteriorly posi-

tioned. It was also noted that of the 15 patients in this study, 11 were diagnosed with internal derangement, 3 with myofascial pain, and 1 with degenerative joint disease. When evaluated radiographically, it was noted that 10 patients had the features of osteoarthritis – flattening, erosions, and the presence of Ely cysts. In a literature review, in cases of osteoarthritis, it was noted that the changes appear to happen to the soft tissue before they begin to occur in the hard tissue. These effects can be noted in the condyle and airway as well. The presence of a posteriorly positioned condyle added to arthritic changes are shown to cause a reduction in the airway.<sup>7,35-37</sup> The same criteria were corroborated in our study, as all patients had posteriorly positioned condyle on CBCT evaluation.

In the present study, it was noted that in patients who had reported the reduction of symptoms after a period of 6 months had a clinically significant increase of the airway ( $p = 0.059$ ), while those who reported a decrease in the symptoms within a period of 3 to 6 months didn't ( $p = 0.138$ ), which indicated that it was nearing statistical significance. It has been reported that the stimulation by ULF-TENS affects the mastication muscles, the pharyngeal muscles, and the superficial fibers of the facial expression muscles.<sup>20</sup> The stimulation provided also enables an increase in the blood flow to these areas, which could explain the increase in the airway posttreatment with a neuromuscular orthotic. The change in the position and posture of the mandible, supported by the mandibular muscles, as well the change in the craniocervical posture posttreatment with ULF-TENS, could also be other factors.<sup>26,38</sup> This appears to be similar to case report by Haze, who reported the fabrication of a neuromuscular guided-sleep appliance called the equalizer, which was found to have a favorable result.<sup>39</sup>

The results of the study by Liang and Auvenshine were corroborated in our study as well, when one of the patients who was diagnosed with myofascial pain syndrome was found not to have an increase in the airway posttreatment, even after significant reduction of subjective signs and symptoms.<sup>40</sup>

This study was conducted due to lack of literature regarding the effects of neuromuscular orthotics on the effect of TMD management and its effect on the airway. Airway, TMJ, and occlusion have a synergistic relationship, where impairment of one can lead to compensatory loss in either of the other two. Therefore, it is important to maintain the balance between these three components.

It had been noted that sleep-disordered breathing, which presents as narrowing of the airway, can lead to changes in the craniofacial morphology, like presence of a retruded maxilla, retrognathic mandible, and crowding of the teeth in the arch. The most common treatment method for patients who report mild to moderate sleep apnea is the mandibular advancement device, which over a long period of time does tend to have a negative effect on the TMJ. Other treatments include the use of oral appliances like the functional activator and mandibular orthopaedic repositioning appliances, which also help maintain the patency of the airway.

The link between the anatomic features and the neuromuscular dynamics of the airway's soft tissue was then explored. In the present study, the use of neuromuscular orthotics fabricated using ULF-TENS to treat the TMDs was noted to result in a significant improvement for patients suffering from TMD, as well as a clinically significant increase in the airway in patients who reported a reduction in symptoms after a period of 6 months, thus proving that repositioning of the mandible, increased blood flow to the areas stimulated by the isotonic contraction of the muscles, and increased vertical dimension had a positive effect on the airway volume.<sup>6,41-44</sup> The following enumerates the limitations of the study where 15 patients were evaluated, the *p*-value of the airway volume in the patients who were reported over a period of 6 months was seen to be approaching statistical significance. This could be proven to be significant by use of a larger sample population evenly distributed among the various diagnoses of the TMDs, and with patient centric variations. Furthermore, the positioning of patients during a radiographic evaluation using CBCT is difficult to standardize, and there may be difficulty in the reproduction of the patients' posture pre- and posttreatment evaluation, which could lead to alterations in the airway volume.

## Conclusion

The present study emphasizes the role of attaining a physiologically acceptable position of the TMJ in patients who suffer from TMDs. It was noted during this study that the repositioning of the mandible aided in the reduction of the symptoms ranging from 3 months to more than 6 months. The stabilization of the new physiologic position was brought about by use of orthotics.

The literature reports that the use of lateral cephalogram and CBCT in the analysis of the airway volume showed a reliability of using either modality. However, many had noted that the use of the CBCT was better for the diagnosis of reduction in the airway volume compared with that of the lateral cephalogram. This study proves the synergistic relationship between the TMJ and the airway volume, where alteration in one could lead to harmful effects on the other. It also took into account the anatomic factors and neuromuscular dynamics, which play a role in the maintenance of the airway's patency. The use of neuromuscular orthotics in the treatment of the TMJ was seen to have a favorable effect on the airway after a period of 6 months. This study highlights the multidisciplinary approach required in the treatment of TMDs, as well the effective resolution of multiple symptoms that patients present with.

### Conflict of Interest

None.

## References

- Buescher JJ. Temporomandibular joint disorders. *Am Fam Physician* 2007;76(10):1477-1482
- Mackie A, Lyons K. The role of occlusion in temporomandibular disorders—a review of the literature. *N Z Dent J* 2008;104(02):54-59
- Chang C-L, Wang D-H, Yang M-C, Hsu W-E, Hsu M-L. Functional disorders of the temporomandibular joints: Internal derangement of the temporomandibular joint. *Kaohsiung J Med Sci* 2018;34(04):223-230
- Jankelson R. The Genesis of Neuromuscular Dentistry [Internet]. . <https://iccmo.org/neuromuscular-dentistry>. [cited 2021 Oct 10]. Available from: <https://iccmo.org/neuromuscular-dentistry>
- Catunda IS, Vasconcelos BC, Corrêa MV, Matos MF, Nogueira EF, Learreta JA. Non-invasive joint decompression: An important factor in the regeneration of the bone marrow and disc recapture in temporomandibular arthropathies. *Med Oral Patol Oral Cir Bucal* 2018;23(05):e506-e510
- Gelb ML. Airway centric TMJ philosophy. *J Calif Dent Assoc* 2014;42(08):551-562, discussion 560-562
- Truong L, Reher P, Doan N. Correlation between upper airway dimension and TMJ position in patients with sleep disordered breathing. *Cranio* 2020;38:1-9
- Harrell WE Jr, Tatum T, Koslin M. Is Centric Relation Always the Position of Choice for TMDs? Case Report of How TMD and Airway Dimension May Be Associated. *Compend Contin Educ Dent* 2017;38(04):e9-e12
- Mummolo S, Nota A, Tecco S, et al. Ultra-low-frequency transcutaneous electric nerve stimulation (ULF-TENS) in subjects with craniofacial pain: A retrospective study. *Cranio* 2020;38(06):396-401
- Porto De Toledo I, Stefani FM, Porporatti AL, et al. Prevalence of otologic signs and symptoms in adult patients with temporomandibular disorders: a systematic review and meta-analysis. *Clin Oral Investig* 2017;21(02):597-605
- Kitsoulis P, Marini A, Iliou K, et al. Signs and symptoms of temporomandibular joint disorders related to the degree of mouth opening and hearing loss. *BMC Ear Nose Throat Disord* 2011;11:5
- Vasconcelos BC, Barbosa LM, Barbalho JC, Araújo GM, Melo AR, Santos LA. Ear pruritus: a new otologic finding related to temporomandibular disorder. *Gen Dent* 2016;64(05):39-43
- Bagis B, Ayaz EA, Turgut S, Durkan R, Özcan M. Gender difference in prevalence of signs and symptoms of temporomandibular joint disorders: a retrospective study on 243 consecutive patients. *Int J Med Sci* 2012;9(07):539-544
- Ferreira CLP, da Silva MAMR, de Felício CM. Signs and symptoms of temporomandibular disorders in women and men. *CoDAS* 2016;28(01):17-21Portuguese.
- Jo J-H, Chung J-W. Gender Differences in Clinical Characteristics of Korean Temporomandibular Disorder Patients. *Appl Sci (Basel)* 2021;11(3583):1-10
- Cooper BC, Kleinberg I. Examination of a large patient population for the presence of symptoms and signs of temporomandibular disorders. *Cranio* 2007;25(02):114-126
- Campbell CD, Loft GH, Davis H, Hart DL. TMJ symptoms and referred pain patterns. *J Prosthet Dent* 1982;47(04):430-433
- Raman P. Physiologic neuromuscular dental paradigm for the diagnosis and treatment of temporomandibular disorders. *J Calif Dent Assoc* 2014;42(08):563-571
- List T, Jensen RH. Temporomandibular disorders: Old ideas and new concepts. *Cephalalgia* 2017;37(07):692-704
- Cooper BC, Kleinberg I. Establishment of a temporomandibular physiological state with neuromuscular orthosis treatment affects reduction of TMD symptoms in 313 patients. *Cranio* 2008;26(02):104-117
- Nitzan DW. Intraarticular pressure in the functioning human temporomandibular joint and its alteration by uniform elevation of the occlusal plane. *J Oral Maxillofac Surg* 1994;52(07):671-679, discussion 679-680
- Akbulut N, Altan A, Akbulut S, Atakan C. Evaluation of the 3 mm Thickness Splint Therapy on Temporomandibular Joint Disorders (TMDs). *Pain Res Manag* 2018;2018:3756587



- 23 Johansson A, Unell L, Carlsson GE, Söderfeldt B, Halling A. Gender difference in symptoms related to temporomandibular disorders in a population of 50-year-old subjects. *J Orofac Pain* 2003;17(01):29–35
- 24 Cooper BC, Kleinberg I. Relationship of temporomandibular disorders to muscle tension-type headaches and a neuromuscular orthosis approach to treatment. *Cranio* 2009;27(02):101–108
- 25 Monaco A, Cattaneo R, Marci MC, Pietropaoli D, Ortu E. Central Sensitization-Based Classification for Temporomandibular Disorders: A Pathogenetic Hypothesis. *Pain Res Manag* 2017;2017:5957076
- 26 Mummolo S, Nota A, Tecco S, et al. Ultra-low-frequency transcutaneous electric nerve stimulation (ULF-TENS) in subjects with craniofacial pain: A retrospective study. *Cranio* 2020;38(06):396–401
- 27 Vizzotto MB, Liedke GS, Delamare EL, Silveira HD, Dutra V, Silveira HE. A comparative study of lateral cephalograms and cone-beam computed tomographic images in upper airway assessment. *Eur J Orthod* 2012;34(03):390–393
- 28 Bronoosh P, Khojastepour L. Analysis of Pharyngeal Airway Using Lateral Cephalogram vs CBCT Images: A Cross-sectional Retrospective Study. *Open Dent J* 2015;9:263–266
- 29 Ghoneima A, Kula K. Accuracy and reliability of cone-beam computed tomography for airway volume analysis. *Eur J Orthod* 2013;35(02):256–261
- 30 Hiyama S, Suda N, Ishii-Suzuki M, et al. Effects of maxillary protraction on craniofacial structures and upper-airway dimension. *Angle Orthod* 2002;72(01):43–47
- 31 Summa S, Ursini R, Manicone PF, Molinari F, Deli R. MRI assessment of temporomandibular disorders: an approach to diagnostic and therapeutic setting. *Cranio* 2014;32(02):131–138
- 32 Jeon KJ, Lee C, Choi YJ, Han S-S. Comparison of the Usefulness of CBCT and MRI in TMD Patients According to Clinical Symptoms and Age. *Appl Sci (Basel)* 2020;10(10):3599
- 33 Veerappan RR, Gopal M. Comparison of the diagnostic accuracy of CBCT and conventional CT in detecting degenerative osseous changes of the TMJ: A systematic review. *J Indian Acad Oral Med Radiol* 2015;27:81–84
- 34 Paknahad M, Shahidi S. Association between mandibular condylar position and clinical dysfunction index. *J Craniomaxillofac Surg* 2015;43(04):432–436
- 35 Hatcher DC. Cone beam computed tomography: craniofacial and airway analysis. *Dent Clin North Am* 2012;56(02):343–357
- 36 Reardon GJT. The relationship between volumetric airway dimension and temporomandibular joint integrity [Internet]. . <https://iro.uiowa.edu/esploro/outputs/graduate/The-relationship-between-volumetric-airway-dimension/9983777032302771>. [cited 2021 Oct 10]. Available from: <https://iro.uiowa.edu/esploro/outputs/graduate/The-relationship-between-volumetric-airway-dimension/9983777032302771>
- 37 Dadgar-Yeganeh A, Hatcher DC, Oberoi S. Association between degenerative temporomandibular joint disorders, vertical facial growth, and airway dimension. *J World Fed Orthod* 2021;10(01):20–28
- 38 Andrighetto AR, de Fantini SM. Effects of neuromuscular deprogramming on the head position. *Cranio* 2015;33(03):183–188
- 39 Haze JJ. Overview of sleep disorders and the implication on dental practice. *Funct Orthod* 1987;4(05):15–17
- 40 Liang Q, Auvenshine R. Pharyngeal airway dimension in patients before and after treatment of myofascial pain syndrome [Internet]. *Cranio*; 2019 [cited 2021 Oct 15]. Available from: <https://ur.booksc.eu/book/75195025/713507>
- 41 Sam K, Lam B, Ooi CG, Cooke M, Ip MS. Effect of a non-adjustable oral appliance on upper airway morphology in obstructive sleep apnoea. *Respir Med* 2006;100(05):897–902
- 42 Singh GD, Callister JD. Effect of a maxillary appliance in an adult with obstructive sleep apnea: a case report. *Cranio* 2013;31(03):171–175
- 43 Maddalone M, Bianco E, Nanussi A, Costa G, Baldoni M. Treatment of Temporomandibular Disorders of Muscular Origin with a Silicon Oral Device (Alifix®): Electromyographic Analysis. *J Contemp Dent Pract* 2019;20(12):1367–1374
- 44 Doff MHJ, Veldhuis SKB, Hoekema A, et al. Long-term oral appliance therapy in obstructive sleep apnea syndrome: a controlled study on temporomandibular side effects. *Clin Oral Investig* 2012;16(03):689–697