



Rational Evaluation and Treatment of Prolactinomas: A Concise Review

Moeber M. Mahzari^{1,2,3}

¹ College of Medicine, King Saud Bin Abdulaziz University for Health Sciences, Riyadh, Saudi Arabia

² King Abdullah International Medical Research Center, Riyadh, Saudi Arabia

³ Department of Medicine, Ministry of the National Guard-Health Affairs, Riyadh, Saudi Arabia

Address for correspondence Moeber M. Mahzari, MBBS, College of Medicine, King Saud Bin Abdulaziz University for Health Sciences, Riyadh, Saudi Arabia (e-mail: moeber60@gmail.com).

J Diabetes Endocrine Practice 2022;5:54–60.

Abstract

Prolactinoma is the most common pituitary tumor. It arises from the lactotroph cells and leads to a hyperprolactinemia state. The clinical presentation of prolactinomas is either due to the high prolactin state or the adenoma mass effect. Diagnosis of prolactinomas starts with the confirmation of persistent pathologic hyperprolactinemia. Subsequently, pituitary MRI is required to characterize the prolactinoma size and extension within the sella turcica. Further investigation may include visual field assessment and laboratory investigations for hypopituitarism. Prolactinoma management is mainly medical with dopamine agonists as most of these tumors are responsive. Surgical intervention is rarely required with specific indications.

Keywords

- prolactinoma
- hyperprolactinemia
- dopamine agonist
- pregnancy

Introduction

Prolactin is secreted by the lactotroph cells of the pituitary gland. Its primary function is the induction and maintenance of lactation in primed breast tissue. Although not a significant effect, prolactin may also physiologically impact metabolism and sexual functions.¹ Prolactin secretion is regulated through hypothalamic dopamine inhibition that is counteracted with stimulatory effects by thyrotropin-releasing hormone (TRH), estrogen, and breast/chest wall irritation. The prolactin is continuously maintained within the normal physiologic range; however, it could be transiently elevated beyond the normal level as a normal physiological response. Pathological elevation of prolactin is relatively common. Many causes lead to prolactin elevation, with prolactinoma being a common cause (►Table 1).^{1–3} Prolactinomas are lactotroph adenomas that account for around

40% of all pituitary tumors. The reported population prevalence varies from 6 to 50 patients per 100,000 population. Generally, prolactinomas are more common in females than males, with a ratio of 10:1. Most prolactinomas are sporadic, while around 5% are hereditary with genetic underpinning. Hereditary prolactinomas are frequently encountered in the setting of familial isolated pituitary adenomas or multiple endocrine neoplasia type 1.^{2–4} The prevalence of prolactinoma in the Arab countries is mainly unknown, with very scarce data. There are global and regional variations in management practices, perhaps imposed by limited access to resources.⁵

Prolactinomas are categorized in terms of their size into microprolactinoma if they measure < 1 cm in their largest diameter. On the contrary, prolactinomas with ≥ 1 cm diameter are considered macroprolactinomas. Microprolactinomas account for 90% of the cases of prolactinomas, while

DOI <https://doi.org/10.1055/s-0042-1758381>.
ISSN 2772-7653.

© 2022. Gulf Association of Endocrinology and Diabetes (GAED). All rights reserved.

This is an open access article published by Thieme under the terms of the Creative Commons Attribution-NonDerivative-NonCommercial-License, permitting copying and reproduction so long as the original work is given appropriate credit. Contents may not be used for commercial purposes, or adapted, remixed, transformed or built upon. (<https://creativecommons.org/licenses/by-nc-nd/4.0/>)

Thieme Medical and Scientific Publishers Pvt. Ltd., A-12, 2nd Floor, Sector 2, Noida-201301 UP, India

Table 1 Causes of hyperprolactinemia

Prolactinomas
Growth hormone-producing adenoma with prolactin co-secretion
Hypothalamic dopamine deficiency
Defective transport mechanisms of dopamine (such as stalk effect, empty sell)
Lactotrophs insensitivity to dopamine due to medications such as antipsychotics
Chest wall/nipple trauma
Chronic kidney disease
Hypothyroidism
Polycystic ovarian syndrome
Idiopathic

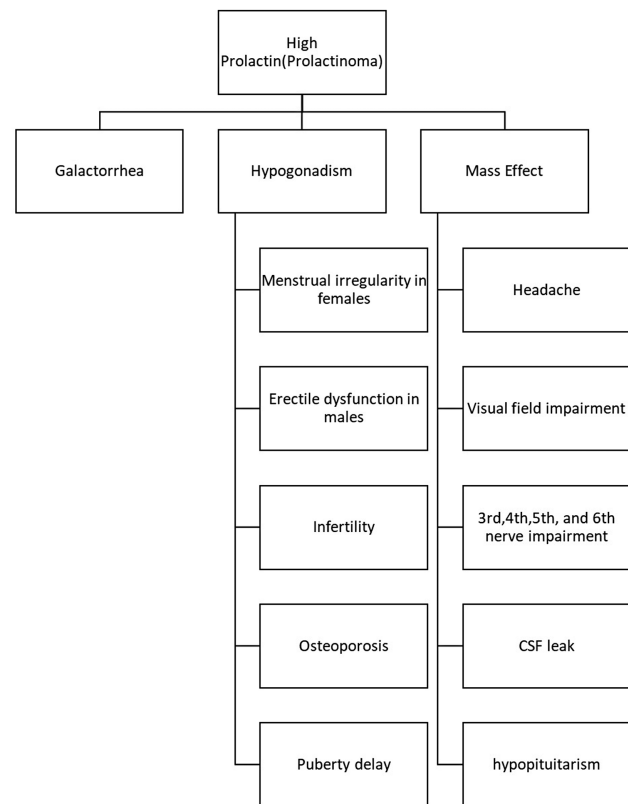
macroprolactinomas represent around 10% of the cases. Macroprolactinomas with a diameter of more than 4 cm are called giant prolactinomas, which are relatively rare.^{2,4}

A different classification of prolactinomas is based on their behavior. Most prolactinomas are confined to the sella turcica. Less frequently, prolactinomas could be invasive and aggressive, extending outside the sella turcica borders and invading the surrounding structures. Generally, prolactinomas are dopamine agonist responsive, but some prolactinomas might be dopamine agonist resistant. Rarely prolactin-producing tumors could be malignant, where they could metastasize to local and distant areas in the body.⁶⁻⁸ This review will discuss clinical presentation, diagnostic approach, and management of suspected or confirmed prolactinomas.

Clinical Presentation

Patients with prolactinomas present with symptoms related to the high prolactin level or symptoms associated with the mass effect of the adenoma (►Fig. 1). Symptoms related to the increased prolactin included galactorrhea, which is reported in up to 80% of female patients. Galactorrhea and gynecomastia are relatively rare in males and reported in around 10% of the patients. Other symptoms related to high prolactin levels are usually secondary to a relative state of hypogonadism. High prolactin induces a relative hypogonadism state due to its inhibitory effect on the gonadotropin-releasing hormone (GnRH). This relative hypogonadal state leads to amenorrhea and, more commonly, oligomenorrhea in up to 90% of patients. In contrast, male patients usually present with erectile dysfunctions. Both male and female patients could present with infertility as the sole clinical presentation of hyperprolactinemia-induced hypogonadism. Younger patients could have pubertal delay if the hyperprolactinemia-induced hypogonadism starts before puberty. Moreover, prolonged high prolactin-induced hypogonadism could lead to osteoporosis with fractures.^{1,2,4,7}

Patients with macroprolactinomas could develop symptoms due to the adenoma mass effect. Headache is the most

**Fig. 1** Clinical features of hyperprolactinemia/prolactinoma.

common symptom in such patients. Visual impairment, typically bi-temporal hemianopia, could result from optic chiasm compression by the macroadenoma. If the tumor mass extends to the cavernous sinuses, it may compress the third, fourth, fifth, and sixth cranial nerves, leading to ophthalmoplegia, which presents with double vision. Aggressive prolactinomas that invade through the roof of the sphenoid sinus could present with a CSF leak in the form of rhinorrhea. Rarely, a giant prolactinoma that extends intracranially compress the cerebral cortex may cause a clinical presentation similar to stroke and brain tumors such as hemiparesis. Macroprolactinomas could destroy other pituitary cells, which results in variable degrees of hypopituitarism.^{1,2,4,5,7}

Diagnostic Evaluation

The diagnosis of prolactinoma starts with the confirmation of hyperprolactinemia suggested by the patient's clinical presentation. A single measurement of serum prolactin is usually enough to establish the diagnosis of hyperprolactinemia. However, physiological causes of transient prolactin elevation should be sought, particularly in patients with high prolactin but no symptoms.^{2,4} This is essential because many patients may get referred for evaluation based on laboratory evidence of prolactin elevation without concerning clinical symptoms. Of note, the transient physiological elevation of prolactin is usually mild compared with pathologic causes in general. In such patients, repetition of prolactin level measurement in a morning fasting sample with no physiologic

stimuli of prolactin, such as sleep disturbance and nipple stimulation, will be necessary.^{9,10} Moreover, in such patients, special attention should be paid to the possibility of macroprolactinemia, where the prolactin level is elevated due to multimeric prolactin, which usually has no clinical consequences. Macroprolactinemia has been reported in up to 40% of all patients with hyperprolactinemia without symptoms.^{11,12} On the contrary, pregnancy is a physiologic cause of significant prolactin elevation that must be excluded in young females with hyperprolactinemia. Renal and liver impairment may elevate the prolactin due to subnormal prolactin elimination from the circulation. Therefore, baseline laboratory works for kidney and liver function is also advisable in patients with hyperprolactinemia.^{2,4}

Upon confirmation of persistent pathologic elevation of prolactin, which is usually at least three times the upper end of the normal range, further investigation is necessary to establish the cause and assess for possible complications. A baseline blood work, including a full pituitary panel, is suggested, especially in patients suspected to harbor macroprolactinoma or large sellar masses that could lead to hypopituitarism.^{2,4,6,13} Because prolactinomas are the most common cause of hyperprolactinemia, all patients with confirmed pathologically high prolactin should undergo a pituitary MRI, preferably with contrast. If the MRI confirms macroadenoma, formal visual field testing is needed to evaluate any compression of the optic chiasm (► Fig. 2).^{2,4}

There is a correlation between the prolactin level and the prolactinoma size. Patients with prolactinomas, in general, will usually have prolactin levels more than three to four times the upper end of the normal range of the assay. On the contrary, pathologic prolactin elevation due to the stalk effect in the setting of a sellar mass on the MRI will have persistent prolactin elevation but less than triple or quadruple the upper end of the assay. The stalk effect results from the interference of a sellar tumor with dopamine trafficking in the pituitary stalk, leading to loss of inhibition of prolactin secretion leading to hyperprolactinemia.^{14,15}

However, in patients with a confirmed sellar mass on MRI and relatively mild prolactin elevation, special attention must be paid to the possibility of the hook effect. The hook effect should be suspected when there are specific clinical symptoms of high prolactin and a macroadenoma on the pituitary MRI. In contrast, the prolactin level does not match the adenoma size and the clinical presentation.⁶ The hook effect is an inherent pitfall of immunoassay when the measured antigen level is significantly elevated. The very high level of the measured antigen leads to independent saturation of the trapping and detecting antibodies that interfere with the needed antigen sandwiching to detect its actual level in correlation to the test measured signal. Lack of sandwiching effect leads to sudden drop out in the assay signal and loss of the correlation between the actual measured antigen level and the test signal. In such patients, the measurement of the prolactin level after sample dilution is needed and enough to exclude the possibility of the hook effect. Although the hook effect is rare with newer assays, it

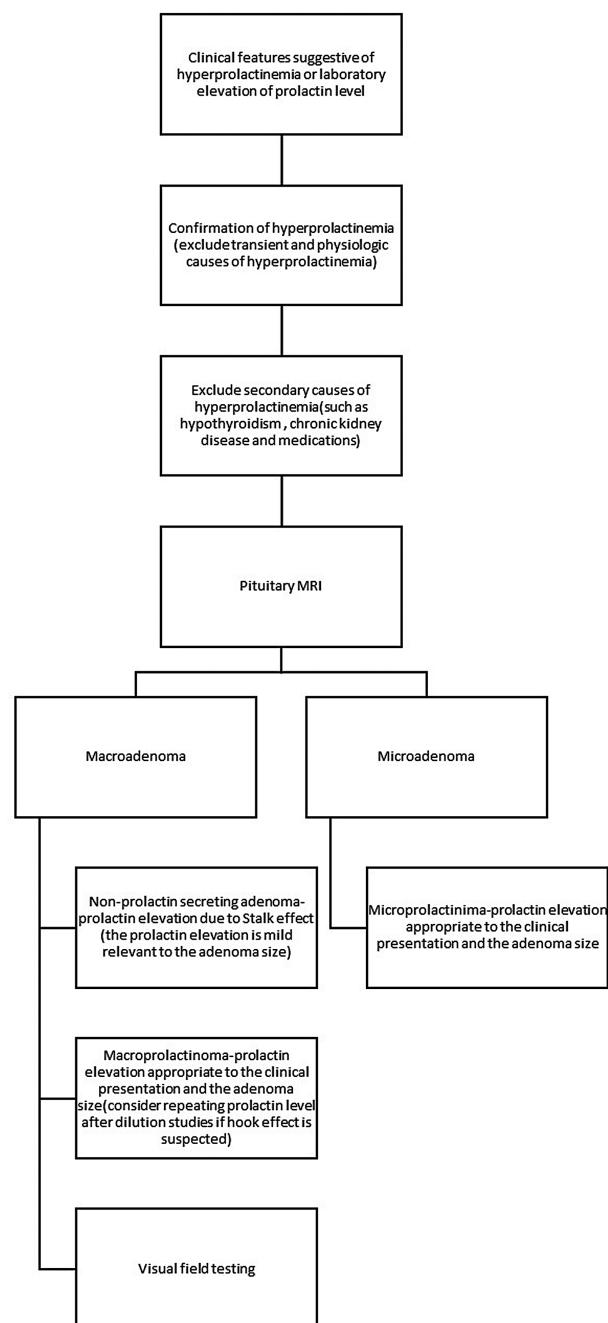


Fig. 2 Diagnostic approach to hyperprolactinemia.

should always be kept in mind and excluded confidently if suspected.^{6,16,17}

Management

Management Strategy

The management of prolactinomas depends mainly on the patient's clinical presentation and the prolactinoma size. The preferred treatment option for all types of prolactinomas is medical therapy, in particular with dopamine agonists (DA) (► Fig. 3).^{2,4,6,10}

Patients with hyperprolactinemia due to microprolactinoma do not need treatment if asymptomatic.

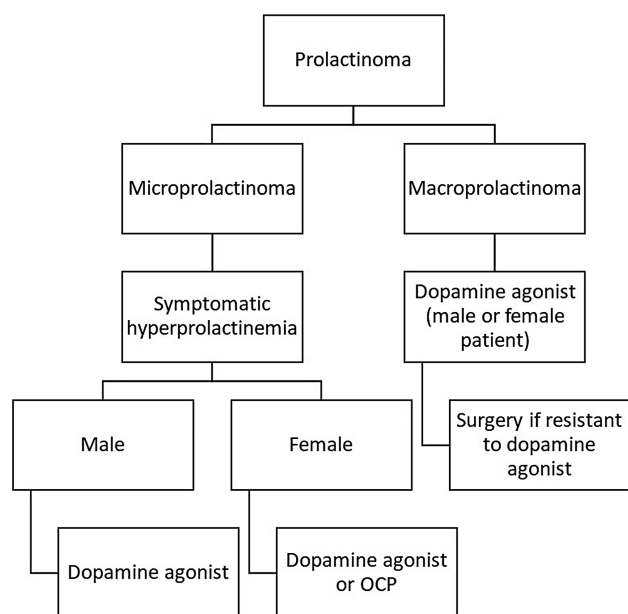


Fig. 3 Management of prolactinoma.

Microprolactinomas are confined to the sella turcica and usually do not cause any complications in terms of mass effect. However, in a symptomatic patient with microprolactinoma, treatment with a dopamine agonist is indicated to normalize the prolactin level and improve the patient's symptoms. Alternatively, patients with amenorrhea or oligomenorrhea due to high prolactin from microprolactinomas could be treated with oral contraceptive pills as a symptomatic treatment instead of dopamine agonists.⁶

In contrast, all patients with macroprolactinomas should receive treatment with dopamine agonists to improve their clinical symptoms from the prolactin elevation and induce prolactinoma size reduction to prevent complications in terms of mass effect.^{2,4}

Dopamine Agonist Therapy

The two widely used dopamine agonists are cabergoline and bromocriptine. Bromocriptine is reported to be effective in up to 80% of patients. In comparison, cabergoline is effective in up to 90% of the patients in normalizing the prolactin level and tumor reduction. Moreover, around 70% of patients who were unresponsive to bromocriptine will usually respond to cabergoline. Therefore, cabergoline is the recommended first-line therapy in most patients with prolactinoma.^{2,4,6,18–20} The usual starting dose of cabergoline is 0.5 mg once weekly with titration every 8 to 12 weeks until the prolactin level normalizes and the prolactinoma size starts to reduce. Dopamine agonists are generally safe with mild side effects that are usually tolerable.⁴

Dopamine agonists are usually continued for at least 2 years to induce significant prolactinoma size reduction or complete tumor resolution. Up to 30% of such patients will have sustainable long-term normal prolactin levels. Patients with considerable size reduction or disappearance of the adenoma on the follow-up MRI are more likely to achieve a

sustainable prolactin level normalization after discontinuation of the dopamine agonists.^{2,21,22}

However, some patients may require long-term treatment. Patients with relapsed hyperprolactinemia after DA discontinuation should be restarted on dopamine agonist if symptomatic with the possibility of long-term treatment.^{19,23} In females, DA could be discontinued safely upon menopause if the adenoma size is not a concern to cause a mass effect. High prolactin levels in postmenopausal women are usually of no clinical significance.^{24,25} However, male patients with persistent symptomatic prolactin elevation likely require long-term treatment with DA to prevent the hypogonadism state and its complications.^{26,27}

Role of Surgery

Trans-sphenoidal pituitary surgery (TSS) as a treatment modality for prolactinoma is rarely required, as most cases respond very well to DA. However, TSS is an option in patients with resistant prolactinomas or intolerance to DA. Resistant prolactinoma is defined as failure to achieve normal prolactin level and prolactinoma size reduction by at least 50% on a maximally tolerated DA dose. Another indication for surgical treatment of prolactinoma is in patients with acute apoplexy if they have neurological complications requiring urgent de-compressive surgery.^{2,4,28,29}

Challenges in Prolactinoma Management

Managing prolactinoma could be challenging. Giant and invasive prolactinomas present with severe symptoms that require timely intervention. DA remains the first-line treatment option in such patients as a significant number of them will show an improvement within a few weeks of DA initiation. Surgical intervention alone is unlikely to cure such tumors. Nonetheless, de-compressive debulking surgery could be an option if DA is ineffective after a few weeks or if the patient's clinical condition requires immediate surgical intervention. Radiotherapy could be of value in some patients after surgery as a means of loco-regional control of the tumor.^{2,4,30,31} Another challenging prolactinoma subtype is malignant prolactinoma. Albeit rare, it constitutes a challenging disease as the experience in its management is limited. Generally, malignant prolactinoma requires a multimodal treatment approach, including surgery and radiotherapy; chemotherapeutic agents such as temozolomide, tyrosine kinase inhibitors, and DA.^{2,4,30,31} Management of patients with giant, invasive, and malignant prolactinomas is better at centers of excellence in pituitary tumor management. In such centers, a multidisciplinary team approach involving experts from different specialties is vital in patients' care.³⁰

Management during Pregnancy

Management of prolactinomas during pregnancy requires proper preconception evaluation and close follow-ups. High estrogen levels during pregnancy usually increase in the prolactinoma size. However, women with microprolactinomas could conceive safely without expected complications, as the adenoma size will increase in less than 10% of cases. In

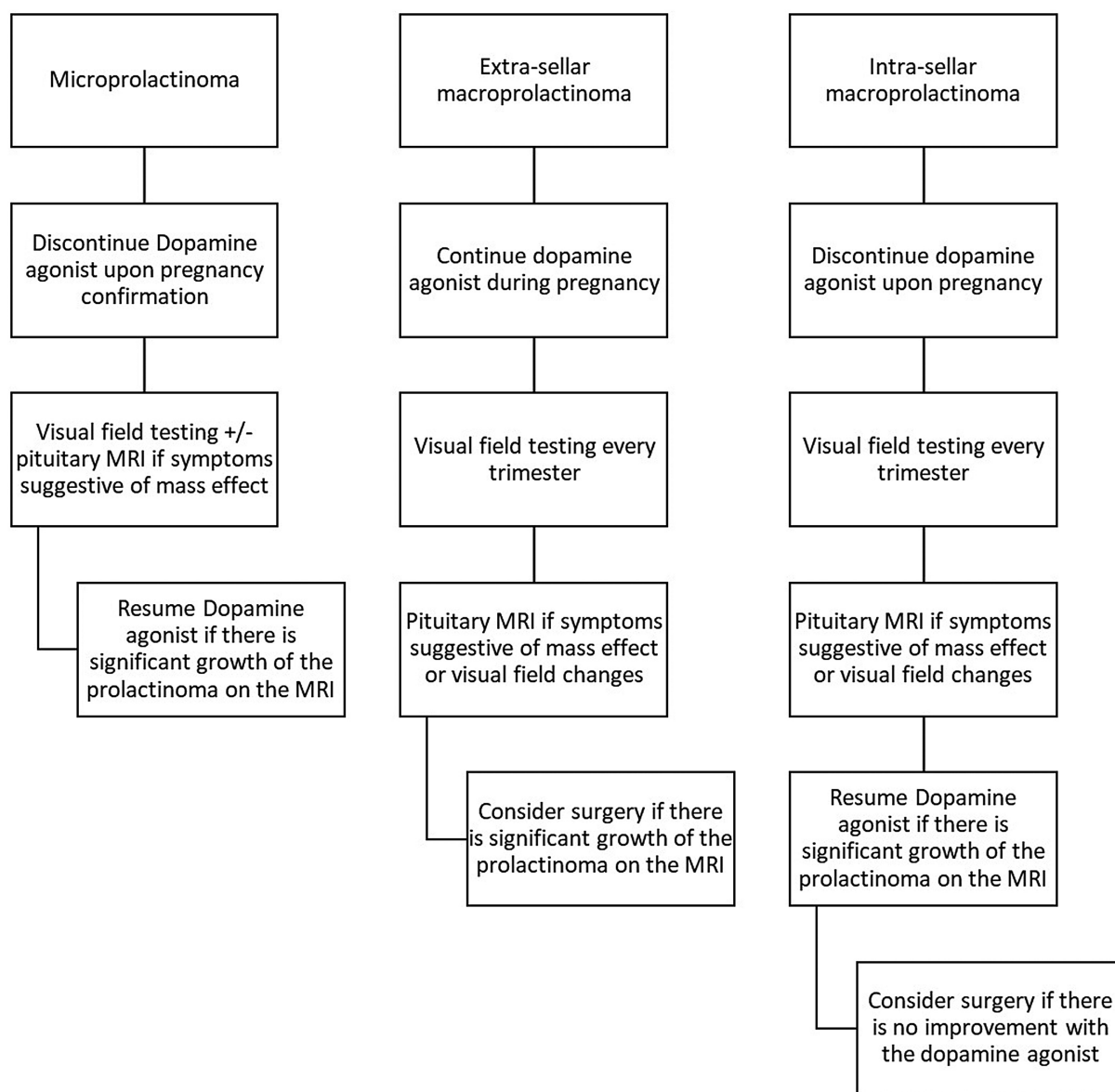


Fig. 4 Management of prolactinoma during pregnancy.

such patients, the DA is usually discontinued upon pregnancy confirmation. Visual field assessment and MRI evaluation may be needed if the patient develops symptoms suggestive of mass effect.^{2,4,32,33}

In contrast, up to 20% of the women with macroprolactinomas will have significant size growth of the adenoma during pregnancy. The growth of macroprolactinomas that extend outside the sella turcica may lead to a substantial mass effect. Generally, in such patients, it is advisable to delay pregnancy until prolactinoma regresses in size with DA and becomes confined to the sella turcica. Alternatively, transsphenoidal surgery could be an option for such patients before they conceive.^{2,4,32,33} Patients with intrasellar macroprolactinomas, such as microprolactinomas, could conceive safely without needing DA. Such patients are followed by visual field testing every trimester, and a pituitary MRI is to

be done if any symptoms suggest a mass effect from the adenoma. The resumption of DA will be necessary for some patients. Surgical intervention during pregnancy is reserved for apoplexy or macroadenomas unresponsive to dopamine agonists (► **Fig. 4**).^{2,4,32,33}

If for any reason, a patient with macroprolactinoma with extra sellar extension becomes pregnant without proper planning, then such patients should continue dopamine agonists during pregnancy. Both cabergoline and bromocriptine are safe, with more robust data for bromocriptine than cabergoline.^{5,32,34}

Conclusions

Prolactinoma is the most common pituitary tumor. The clinical presentation of prolactinomas is either due to the

high prolactin state or the adenoma mass effect. Diagnosis of prolactinomas is established with the confirmation of persistent pathologic hyperprolactinemia and exclusion of other causes of high prolactin levels. Subsequently, a pituitary MRI is required to characterize the prolactinoma size and extension within the sella turcica. Further investigation may include visual field assessment and laboratory investigations for hypopituitarism. Prolactinoma management is mainly medical with dopamine agonists, as most of these tumors are responsive. Surgical intervention is rarely required with specific indications. Patients with resistant, invasive, and malignant prolactinomas achieve better outcomes in specialized institutions and should be referred to centers with good patients' volume and multidisciplinary teams.

Author's Contribution

Single author.

Compliance with Ethical Principles

Ethical approval was not required for the review article type of study.

Funding

None.

Conflict of Interest

None declared.

References

- Bronstein MD. Disorders of prolactin secretion and prolactinomas. *Endocrinology*. United States: Elsevier; 2010:333–357
- Melmed S, Casanueva FF, Hoffman AR, et al; Endocrine Society. Diagnosis and treatment of hyperprolactinemia: an Endocrine Society clinical practice guideline. *J Clin Endocrinol Metab* 2011; 96(02):273–288
- Fernandez A, Karavitaki N, Wass JA. Prevalence of pituitary adenomas: a community-based, cross-sectional study in Banbury (Oxfordshire, UK). *Clin Endocrinol (Oxf)* 2010;72(03):377–382
- Casanueva FF, Molitch ME, Schlechte JA, et al. Guidelines of the Pituitary Society for the diagnosis and management of prolactinomas. *Clin Endocrinol (Oxf)* 2006;65(02):265–273
- Beshyah SA, Sherif IH, Chentli F, et al. Management of prolactinomas: a survey of physicians from the Middle East and North Africa. *Pituitary* 2017;20(02):231–240
- Aldahmani KM, AlMalki MH, Beshyah SA. A rational approach to the evaluation and management of patients with hyperprolactinemia. *Ibnosina J Med Biomed Sci* 2020;12:90–97
- Glezer ABM In: Feingold KR, Anawalt B, Boyce A, et al., eds. *Hyperprolactinemia*. 2022
- Maiter D, Delgrange E. Therapy of endocrine disease: the challenges in managing giant prolactinomas. *Eur J Endocrinol* 2014; 170(06):R213–R227
- Ignacak A, Kasztelnik M, Sliwa T, Korbut RA, Rajda K, Guzik TJ. Prolactin—not only lactotrophin. A “new” view of the “old” hormone. *J Physiol Pharmacol* 2012;63(05):435–443
- Vilar L, Fleseriu M, Bronstein MD. Challenges and pitfalls in the diagnosis of hyperprolactinemia. *Arq Bras Endocrinol Metabol* 2014;58(01):9–22
- Al Nuaimi A, Almazrouei R, Othman Y, Beshyah S, Aldahmani KM. Prevalence of Macroprolactinemia in patients with hyperprolactinemia using Roche Elecsys platform in a large tertiary referral center in UAE. *Dubai Diab Endocrinol J* 2021;27(04):126–130
- Che Soh NAA, Yaacob NM, Omar J, et al. Global prevalence of macroprolactinemia among patients with hyperprolactinemia: a systematic review and meta-analysis. *Int J Environ Res Public Health* 2020;17(21):8199
- Vilar L, Freitas MC, Naves LA, et al. Diagnosis and management of hyperprolactinemia: results of a Brazilian multicenter study with 1234 patients. *J Endocrinol Invest* 2008;31(05):436–444
- Kim JH, Hur KY, Hong SD, et al. Serum prolactin level to tumor size ratio as a potential parameter for preoperative differentiation of prolactinomas from hyperprolactinemia-causing non-functional pituitary adenomas. *World Neurosurg* 2022;159:e488–e496
- Leca BM, Mytilinaiou M, Tsoli M, et al. Identification of an optimal prolactin threshold to determine prolactinoma size using receiver operating characteristic analysis. *Sci Rep* 2021;11(01):9801
- Raverot V, Perrin P, Chanson P, Jouanneau E, Brue T, Raverot G. Prolactin immunoassay: does the high-dose hook effect still exist? *Pituitary* 2022;25(04):653–657
- Petakov MS, Damjanović SS, Nikolić-Durović MM, et al. Pituitary adenomas secreting large amounts of prolactin may give false low values in immunoradiometric assays. The hook effect. *J Endocrinol Invest* 1998;21(03):184–188
- Webster J, Piscitelli G, Polli A, Ferrari CI, Ismail I, Scanlon MFCabergoline Comparative Study Group. A comparison of cabergoline and bromocriptine in the treatment of hyperprolactinemic amenorrhea. *N Engl J Med* 1994;331(14):904–909
- dos Santos Nunes V, El Dib R, Boguszewski CL, Nogueira CR. Cabergoline versus bromocriptine in the treatment of hyperprolactinemia: a systematic review of randomized controlled trials and meta-analysis. *Pituitary* 2011;14(03):259–265
- Huang HY, Lin SJ, Zhao WG, Wu ZB. Cabergoline versus bromocriptine for the treatment of giant prolactinomas: a quantitative and systematic review. *Metab Brain Dis* 2018;33(03):969–976
- Ma Q, Su J, Li Y, et al. The chance of permanent cure for micro-and macroprolactinomas, medication or surgery? A systematic review and meta-analysis. *Front Endocrinol (Lausanne)* 2018;9:636
- Paepegay AC, Salenave S, Kamenicky P, et al. Cabergoline tapering is almost always successful in patients with macroprolactinomas. *J Endocr Soc* 2017;1(03):221–230
- Souteiro P, Belo S, Carvalho D. Dopamine agonists in prolactinomas: when to withdraw? *Pituitary* 2020;23(01):38–44
- Mallea-Gil MS, Manavela M, Alfieri A, et al. Prolactinomas: evolution after menopause. *Arch Endocrinol Metab* 2016;60(01):42–46
- Santharam S, Fountas A, Tampourlou M, et al. Impact of menopause on outcomes in prolactinomas after dopamine agonist treatment withdrawal. *Clin Endocrinol (Oxf)* 2018;89(03):346–353
- Zou Y, Li D, Gu J, et al. The recurrence of prolactinoma after withdrawal of dopamine agonist: a systematic review and meta-analysis. *BMC Endocr Disord* 2021;21(01):225
- Espinosa-Cárdenas E, Sánchez-García M, Ramírez-Rentería C, Mendoza-Zubieta V, Sosa-Eroza E, Mercado M. High biochemical recurrence rate after withdrawal of cabergoline in prolactinomas: is it necessary to restart treatment? *Endocrine* 2020;70(01):143–149
- Buchfelder M, Zhao Y, Schlaffer SM. Surgery for prolactinomas to date. *Neuroendocrinology* 2019;109(01):77–81
- Kreutzer J, Buslei R, Wallaschofski H, et al. Operative treatment of prolactinomas: indications and results in a current consecutive series of 212 patients. *Eur J Endocrinol* 2008;158(01):11–18
- Frara S, Rodriguez-Carnero G, Formenti AM, Martinez-Olmos MA, Giustina A, Casanueva FF. Pituitary tumors centers of excellence. *Endocrinol Metab Clin North Am* 2020;49(03):553–564
- Raverot G, Burman P, McCormack A, et al; European Society of Endocrinology. European Society of Endocrinology Clinical Practice Guidelines for the management of aggressive pituitary tumours and carcinomas. *Eur J Endocrinol* 2018;178(01):G1–G24

- 32 Huang W, Molitch ME. Pituitary tumors in pregnancy. *Endocrinol Metab Clin North Am* 2019;48(03):569–581
- 33 Lebbe M, Hubinont C, Bernard P, Maiter D. Outcome of 100 pregnancies initiated under treatment with cabergoline in hyperprolactinaemic women. *Clin Endocrinol (Oxf)* 2010;73(02):236–242
- 34 Hurault-Delarue C, Montastruc JL, Beau AB, Lacroix I, Damase-Michel C. Pregnancy outcome in women exposed to dopamine agonists during pregnancy: a pharmacoepidemiology study in EFEMERIS database. *Arch Gynecol Obstet* 2014;290(02):263–270