



Repair of an Isolated Traumatic Cranial Luxation of the Radial Head Using a TightRope System in a Cat

Megane Richard¹ Rosario Vallefuoco¹

¹Department of Small Animal Surgical, Pride Veterinary Centre, Derby, United Kingdom of Great Britain and Northern Ireland

Address for correspondence Megane Richard, DVM, MRCVS, Department of Small Animal Surgery, Pride Veterinary Centre, Riverside Road, Derby DE24 8HX, United Kingdom of Great Britain and Northern Ireland (e-mail: megane.richard2992@gmail.com).

VCOT Open 2022;5:e131–e135.

Abstract

A 4.4 kg, a 6-year-old Domestic Shorthair male neutered outdoor cat was diagnosed with an isolated traumatic cranial luxation of the left radial head. Surgical stabilization was achieved using a mini TightRope system (Arthrex Vet Systems, Naples, Florida, United States) to hold the radial head to the ulna without attempting to reconstruct the annular ligament. A range of motion within the normal range was achieved after reduction. At 7-week follow-up after surgery, the cat was walking without lameness; at follow-up by telephone 3 years postoperatively, the owner described the overall quality of life as excellent with good mobility in everyday activities such as jumping, running, and playing. Many publications in veterinary medicine detail congenital radial head luxation, Monteggia lesions, or complete elbow luxation, but traumatic radial head luxation is barely cited as the occurrence is rare. To our knowledge, this is the first reported case of a feline isolated traumatic radial head luxation managed with this technique.

Keywords

- ▶ cat
- ▶ radial head luxation
- ▶ elbow
- ▶ mini TightRope

Introduction

Isolated luxation of the radial head is usually described as an uncommon congenital anomaly in small animals.¹ Mostly reported in dogs,¹ cases of congenital radial head luxation have been rarely described in cats.^{2,3} Traumatic luxation of the radial head is more frequently associated with an ulnar fracture.⁴ However, isolated traumatic luxation of the radial head can also occur,⁴ even if very limited information is available. Traumatic radial head luxation in association with an ulnar fracture is usually classified as Monteggia lesions (or fracture) (ML).^{1,5,6} Monteggia lesions have been classified into four types, according to the direction of luxation of the radial head^{4,7} and angulation of the ulna fracture^{8,9}: cranial luxation (type I), caudal luxation (type II), lateral luxation (type III) and cranial luxation associated with an additional fracture of the proximal radial diaphysis (type IV). Type I ML, associated with cranial luxation of the radial head, has been the most frequently observed in small animals^{8,9} and has

generally occurred after road traffic accidents or falls.¹⁰ A cranial luxation of the radial head has been recently reported in a dog in association with divergent elbow dislocation.¹¹ Four anatomical structures contribute to the humeroradial and radioulnar stability: (1) the joint capsule, (2) the lateral and medial collateral ligaments, (3) the annular ligament, and (4) the interosseous ligament.^{1,11} Although canine and feline elbows have similar gross anatomy, differences exist between cats and dogs.⁴ In particular a strong interosseous ligament between the radius and ulna is absent in the cat.^{4,12} In ML, the annular ligament can be disrupted or may remain intact depending on the level of the ulnar fracture.⁵ When the ulna fracture is distal to the radial head,⁵ the radioulnar joint is also luxated and consequently the annular ligament and at least the proximal portion of the interosseous membrane and ligaments are disrupted, adding instability to the condition and complexity to the repair.⁸ Anatomically, the annular ligament attaches to the lateral and medial coronoid processes of the ulna and runs in a transverse plane around

received
April 2, 2022
accepted after revision
September 19, 2022

DOI <https://doi.org/10.1055/s-0042-1758677>.
ISSN 2625-2325.

© 2022. The Author(s).

This is an open access article published by Thieme under the terms of the Creative Commons Attribution License, permitting unrestricted use, distribution, and reproduction so long as the original work is properly cited. (<https://creativecommons.org/licenses/by/4.0/>)
Georg Thieme Verlag KG, Rüdigerstraße 14, 70469 Stuttgart, Germany

the radius.¹² Reconstruction of the annular ligament has been described in dogs, but in most cases is not feasible.^{5,8} Furthermore, relaxation commonly occurs when annular ligament repair is the sole method of reduction,¹³ making it imperative to immobilize the radial head on the ulna. This fixation may be achieved by either a Kirschner wire (K-wire) or preferably a screw, placed between the radial neck and proximal ulna.⁵ A radioulna TightRope system with an ulna plating has been successfully used for repair of a ML in a dog and a cat.¹³ The purpose of our case report is to describe the clinical presentation and surgical management of an isolated traumatic cranial luxation of the radial head in an adult cat and its treatment with a mini TightRope system. This condition is only occasionally mentioned in veterinary textbooks,⁴ and only 30 cases have been reported in human medical literature over the past 30 years.¹⁴

Case Description

A 4.4 kg, 6-year-old Domestic Shorthair male neutered outdoor cat was referred as an emergency immediately after a road traffic accident. Medical stabilization and emergency work-up (T-FAST and A-FAST, complete blood count and biochemistry) were provided at admission. The cat was ambulatory with a non-weight bearing lameness on the left thoracic limb, with the left elbow maintained in flexion and slight supination. Manipulation of the left elbow revealed abnormal anatomical landmarks and moderate swelling of the periarticular soft tissues. There was also reduced range of motion (ROM) in both flexion and extension associated with crepitus on palpation. Intravenous fluid therapy (Hartmann's: 4ml/kg/h; Hartmann's; Vetivex; Dechra, Skipton, United Kingdom), methadone (0.2mg/kg intravenously [IV] q4h; Methadone, Comfortan; Dechra, Skipton, United Kingdom) and oxygen administration via oxygen cage with constant monitoring of vital parameters was continued and the cat's clinical condition improved progressively over the first 24 hours of intensive care. Radiographic examination under sedation was postponed until the day after the trauma. Orthogonal views of the left antebrachium revealed a cranial displacement of the proximal radius associated with complete loss of contact between the radial head and the lateral humeral condyle. The caudal aspect of the radial head was indeed misshapen and a small, well-defined osseous fragment superimposed over the cranioproximal aspect of the ulna was identified on the lateral radiographic view. The left humerus, the ulna and the humeroulnar joint were unremarkable (►Fig. 1A). Due to the periarticular soft tissue swelling, Campbell's test was challenging to perform, but overall medial and lateral normal stability was noticed in pronation and supination respectively. A left-sided isolated cranial luxation of the radial head associated with a simple intra-articular fracture was diagnosed. Closed reduction in the luxation was not attempted due to the articular fracture and surgical stabilization of the left elbow was performed. Surgery was scheduled 4 days after the initial trauma. The cat was premedicated with methadone (0.2 mg/kg IV), and induction of anaesthesia

was obtained with propofol (6.25 mg/kg IV; Propofol, Propoflo Plus; Zoetis, Leatherhead, United Kingdom) and midazolam (0.25 mg/kg IV; Midazolam, midazolam; Hameln Pharma, Gloucester, United Kingdom). Anaesthesia was maintained with isoflurane in 100% oxygen. A radioulnar stabilization was performed according to the technique described by Vallone and Schulz. A cranial approach to the left radial head¹⁵ provided access to the cranial compartment of the elbow and a direct view of the dislocated radial head. A tear in the cranial aspect of the joint capsule and disruption of the annular ligament were found. The collateral ligaments appeared intact. The small articular fragment in the cranio-lateral aspect of the elbow joint was identified and removed. A temporary reduction in the radioulnar luxation was achieved using pointed reduction bone forceps, and a 1.4 mm K-wire was inserted into the centre of the proximal diaphysis of the radius and oriented caudomedially towards the ridge of the ulna. A 2.7 mm cannulated drill bit was then inserted over the K-wire to obtain a radioulnar tunnel. The bone tunnel created within the proximal radius was 35% of the width of the proximal diaphysis. A mini TightRope (Arthrex Vet Systems, Naples, Florida, United States) composed of a single strand 2-0 FiberWire Suture, a 2.6 mm stainless-steel oblong button and a 5.5 mm stainless-steel round button was used. A 1.6 mm guide pin was inserted through the hole from the cranial to caudal aspect to pull the 2.6 mm toggle through the caudal cortex of the ulna. The toggle was placed parallel to the long axis of the ulna by manipulation of the FiberWire, then the 5.5 mm button was compressed against the cranial radial surface and secured in position by five throws of the FiberWire. Intraoperatively, good ROM and good stability in supination and pronation with the elbow held at 90 degrees was achieved after reduction. The approach was closed in three layers without attempting to reconstruct the annular ligament. The post-operative radiographs showed an appropriate reduction of the radius and an appropriate positioning of the tunnel and the implants (►Fig. 1B). A modified Robert-Jones dressing was applied to reduce oedema for the first 10 days postoperatively. The cat was discharged from the hospital with a course of cefalexin (15 mg/kg per os [PO] q12h for 7 days; cefalexin, Therios; Cefa, Amersham, United Kingdom) and meloxicam (0.1 mg/kg PO q24h for 7 days; Meloxicam, Loxicom; Norbrook, Oakley Way East, United Kingdom). Strict cage-rest was advised for 6 weeks. On re-examination at 10 days, the surgical wound had healed uneventfully and the elbow had a good ROM on manipulation. At follow-up by telephone 20 days after the surgery, the owners reported that the cat was using the operated limb relatively well but was occasionally holding it up. At 7 weeks postoperative orthopaedic follow-up, the cat was walking without lameness. The ROM of the operated elbow was reduced by 20 degrees in flexion compared with the contralateral side and Campbell's test was negative. Radiographs at that time showed maintained reduction in the radioulnar joint, static implant position but mild uniform widening of the radial and ulnar bone tunnels (►Fig. 1C). These radiographic changes did not have clinical consequences for the overall stability of

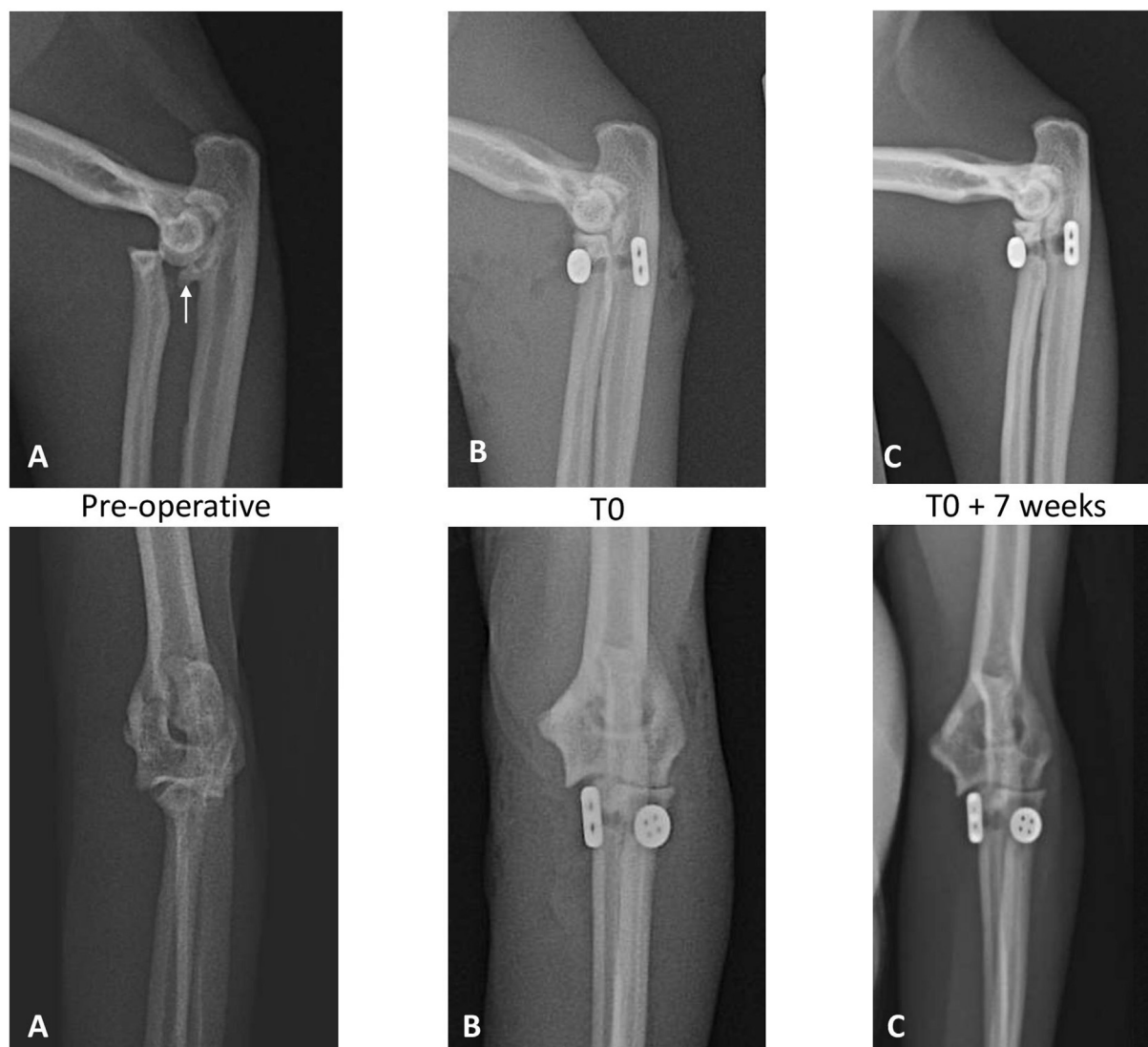


Fig. 1 (A) Preoperative orthogonal radiographic views of the left elbow, revealing an isolated cranial radial head luxation with presence of an articular well-defined fracture fragment (*white arrow*); the left humerus, ulna and humeroulnar joint are unremarkable. (B) Immediate postoperative orthogonal radiographs showing the reduction in the radioulna luxation by a mini TightRope (Arthrex Vet Systems, Naples, Florida, United States). (C) Seven weeks postoperative radiographic follow-up examination showing maintained radioulnar joint reduction, static implant position but discrete widening of the radial and ulnar bone tunnels.

the elbow or the functional outcome. Rest was advised for two further weeks. A final follow-up by telephone 3 years after surgery was obtained by completion of a 'feline musculoskeletal pain index' questionnaire¹⁶ by the owner, giving a score of 7/70 (0 = no sign of pain or mobility detriment, and 70 = severe pain, detriment). The owner described the overall quality of life as excellent with good mobility in everyday activities such as jumping, running and playing.

Discussion

Isolated luxation of the radial head is a rare condition, commonly congenital and often associated with developmental abnormalities of the radius and ulna.^{1,17} Feline congenital radial head luxation has been described in only two cases,^{2,3} confirming that the incidence of the pathology in this species is very rare. Traumatic complete elbow luxation

in cats is more frequent,^{18,19} which is generally associated with complete rupture of both medial and lateral collateral ligaments as demonstrated in a feline cadaveric study.¹⁸ Isolated traumatic radial head luxation has been briefly reported in veterinary orthopaedic textbooks,⁴ but details of the injury, treatment options and prognosis are lacking.

This condition is also relatively rare in humans¹⁴ and the exact mechanism of the isolated radial head luxation remains unclear. A common cause involves a trauma, such as a fall, with a fully extended arm in pronation.^{14,20} In human cadaveric models, the luxation occurs instead with the forearm in extreme supination, with a force applied in an anterior direction to the caudal aspect of the radial head, resulting in rupture of the anterior capsule and annular ligament leading to an anterior dislocation of the radius.²⁰ In humans, the annular ligament and the joint capsule play a

key role in stabilization of the radial head.²⁰ Descriptions of isolated traumatic radial head luxation seem to be consistent between human cases and only differ slightly from the clinical signs observed with a congenital radial head luxation.¹⁴ After the traumatic event in humans, the forearm is maintained in slight supination, the elbow ROM is normal in extension but reduced in flexion and the displaced radial head is palpable.²⁰ A similar clinical presentation has also been observed in our case, even though the dynamic of the trauma remains unknown. In human medicine, closed reduction is successful in 50% of cases when the luxation is cranial, but unsuccessful when the luxation is caudal, lateral or chronic.¹⁴ Open reduction is indicated when the luxation is unreducible or recurrent after closed reduction. In our case, open reduction was elected due to the intra-articular radial fracture. Many surgical techniques have been reported to reduce a traumatic radiohumeral luxation in humans. In a literature review by Obert and colleagues, only 7 out of 20 cases required open reduction for annular ligament reconstruction of radial head luxation. Prosthetic replacement or muscle aponeurosis strips are usually chosen over a primary repair due to the friability of the damaged ligament.^{1,20} In Obert's review, the elbow was immobilized at 90 degrees flexion after reduction; however, the position of the forearm, supination versus pronation and the duration of immobilization were variable.¹⁴ In veterinary medicine, several techniques have been employed for reduction and stabilization of a traumatic radiohumeral luxation in Monteggia lesions. Stabilization of the radial head with a cortical screw across the radius and ulna immediately distal to the elbow with concurrent annular ligament repair achieved a good outcome.^{1,9,10} However, implant removal after 4 to 6 weeks has been advised to avoid complications such as radioulnar synostosis, implant failure and reduction in ROM.^{1,8,10} In our case, the decision to use the TightRope system to maintain the radial head in position was based on the successful experience reported by Vallone and Schulz in one dog and one cat. Indeed, the application of a toggle system instead of the cortical screw should have guaranteed more physiological pronation and supination movements in the cat and no need to remove the implant, decreasing the risk of implant failure.¹³ The use of the TightRope system has been described for numerous other conditions in both human (calcaneal fracture, syndesmotic disruptions, acromioclavicular joint dislocations and hallux varus [bunion deformity]²¹⁻²³) and in veterinary medicine (canine cranial cruciate ligament deficiency,^{24,25} canine and feline hip luxation,^{26,27} medial shoulder instability,²⁸ elbow stabilization¹¹). The treatment goal in our case was achieved by rapidly restoring reliable and durable stabilization with limited long-term complications. In the two cases described by Vallone and Schulz for the treatment of an ML, the elbow ROM was good to excellent and no radiographic changes were observed at 4 and 8 weeks after surgery for the dog and cat respectively. In our case, mild uniform widening of the radial and ulnar bone tunnels was observed at 7 weeks after surgery. However, these radiographic changes did not affect the overall stability of the elbow nor the functional outcome.

When the TightRope system was used for coxofemoral luxation repair,²⁶ mild symmetrical femoral bone tunnel widening was seen in all dogs on postoperative radiographs at the 1 month re-examinations. This widening was persistent, but not progressive, for more than 4 months re-evaluation. The authors speculated that these radiographic changes could be attributed to the implant reaction and subsequent bone response, micromotion of the implant, or infection. Whereas traditionally braided non-absorbable suture has been reported to have a higher rate of infection than monofilament material, infection associated with the TightRope system in veterinary medicine²⁵⁻²⁸ has been reported only in 1 dog in one series.²⁵ In our case, no clinical signs of infection were found. It is possible that the increased range of supination and pronation motion in cats could have induced more friction of the FiberWire within the bone tunnels, causing widening of the tunnel. Bone tunnel enlargement has also been described in human surgery after reconstruction of the anterior cruciate ligament with an autograft.²⁹ Stolarz and colleagues explained the widening by a multifactorial aetiology, caused by mechanical forces and biological processes: drilling, necrosis, inflammatory mediator reaction.²⁹ Metacarpal and metatarsal stress fracture at level of the tunnel bone have been reported in humans, when interosseous sutures with mini TightRope were used for suspensionplasty for the management of thumb carpometacarpal arthritis³⁰ and for hallux valgus deformity correction.²³ However, in our case and in the case previously described by Vallone and Schulz, this complication was not identified. In both cases, a 2.7 mm cannulated drill bit was used allowing the 2.6 mm stainless-steel oblong button to pass through the radius and the ulna tunnels along with the guide pin. When the TightRope system is used for canine and feline coxofemoral luxation repair, it has been recommended to obtain a femoral tunnel between 20 and 33% of the diameter of the femoral neck.^{26,27} In our case, the radial tunnel was 35% of the width of the proximal diaphysis of the radius.

The bone tunnel itself and the postoperative tunnel widening are stress risers and can predispose to a radial fracture. To decrease this potential risk, in particular for the smaller radius, a 2 mm cannulated drill bit could be used and the mini TightRope could be placed in a reverse order,²⁶ since the oblong button would not fit in the bone tunnel. Briefly, once the radius and ulna tunnels are obtained, the blunt end of a nitinol loop is introduced from the radius through the radial and ulna tunnels to pull the suture strands. A 1.1 mm mini TightRope tapered suture passing K-wire (Arthrex Vet Systems, Naples, Florida, United States) is also available, allowing the set of 2-0 FiberWire suture strands to pass through an even smaller bone tunnel.

In our case, a preoperative computed tomographic scan of the elbow would have given more details about the articular fragment fracture. However, even if the articular fracture could have affected the prognosis, the long positive follow-up in our case showed a durable stabilization of the elbow by this technique. In conclusion, this report describes a case of isolated traumatic radial head luxation in a cat successfully managed using a TightRope system and adds information on long-term outcome of this relatively uncommon lesion.

Acknowledgement

This work was supported by the IVC Evidensia Research Community.

Conflict of Interest

None declared.

References

- 1 Krotscheck U, Böttcher P. Surgical diseases of the elbow. In: Johnston SA, and Tobias KM, eds. *Veterinary Surgery Small Animal*. 2nd ed. St. Louis: Elsevier; 2018:838–848
- 2 Valastro C, Di Bello A, Crovace A. Congenital elbow subluxation in a cat. *Vet Radiol Ultrasound* 2005;46(01):63–64
- 3 Rossi F, Vignoli M, Terragni R, Pozzi L, Impallomeni C, Magnani M. Bilateral elbow malformation in a cat caused by radio-ulnar synostosis. *Vet Radiol Ultrasound* 2003;44(03):283–286
- 4 Voss K, Langley-Hobbs SJ, Montavon PM. Elbow joint. In: *Feline Orthopaedic Surgery and Musculoskeletal Disease*. 1st ed. Philadelphia: W.B. Saunders; 2009:359–370
- 5 Aufefage A. Fracture of the ulna. In: Johnson AL, Houlton JEF, Vannini R, eds. *AO Principles of Fracture Management in the Dog and Cat*. New York: Thieme; 2005:260–272
- 6 Bado JL. The Monteggia lesion. *Clin Orthop Relat Res* 1967;50(50):71–86
- 7 Bruce WJ. Radius and ulna. In: Cough- lan A, Miller A, eds. *Manual of Small Animal Fracture Repair and Management*. Cheltenham: BSAVA; 1998:197–215
- 8 Fox D. Radius and ulna. In: Johnston SA, Tobias KM, eds. *Veterinary Surgery Small Animal*. 2nd ed. St. Louis: Elsevier; 2018:896–920
- 9 Schwarz PD, Schrader SC. Ulnar fracture and dislocation of the proximal radial epiphysis (Monteggia lesion) in the dog and cat: a review of 28 cases. *J Am Vet Med Assoc* 1984;185(02):190–194
- 10 Bush M, Owen M. Type-IV variant Monteggia fracture with concurrent proximal radial physeal fracture in a Domestic Shorthaired Cat. *Vet Comp Orthop Traumatol* 2009;22(03):225–228
- 11 Garcia M, Bismuth C, Derooy-Bordenave C. Repair of a divergent elbow dislocation with distal ulnar fracture in a dog using TightRope and external skeletal fixation. *Vet Comp Orthop Traumatol Open* 2021;4:e58–e64
- 12 Evans HE, de Lahunta A. *Miller's Anatomy of the Dog*. 4th ed. St. Louis: Elsevier; 2013:190–193
- 13 Vallone L, Schulz K. Repair of Monteggia fractures using an Arthrex Tightrope system and ulnar plating. *Vet Surg* 2011;40(06):734–737
- 14 Obert L, Huot D, Lepage D, Garbuio P, Tropet Y. [Isolated traumatic luxation of the radial head in adults: report of a case and review of the literature]. *Chir Main* 2003;22(04):216–219
- 15 Johnson K. *Piermattei's Atlas of Surgical Approaches to the Bones and Joints of the Dog and Cat*. 5th ed. St Louis: Elsevier Saunders; 2014:240–242
- 16 Lancelles D. *Feline musculoskeletal pain index. Secondary feline musculoskeletal pain index 2015*. Accessed October 21, 2022, at: <https://painfreecats.org/pain-scale/>
- 17 Harasen G. Congenital radial head luxation in a bulldog puppy. *Can Vet J* 2012;53(04):439–441
- 18 Farrell M, Thomson DG, Carmichael S. Surgical management of traumatic elbow luxation in two cats using circumferential suture prostheses. *Vet Comp Orthop Traumatol* 2009;22(01):66–69
- 19 Williams H, Calvo I, Gaines A, et al. Multi-centre retrospective study of the long-term outcome following suspected traumatic elbow luxation in 32 cats. *J Small Anim Pract* 2020;61(06):354–362
- 20 Gupta V, Kundu Z, Sangwan S, Lamba D. Isolated post-traumatic radial head dislocation, a rare and easily missed injury—a case report. *Malays Orthop J* 2013;7(01):74–78
- 21 Naqvi GA, Shafqat A, Awan N. Tightrope fixation of ankle syndesmosis injuries: clinical outcome, complications and technique modification. *Injury* 2012;43(06):838–842
- 22 Flinkkilä TE, Ihanainen E. Results of arthroscopy-assisted tightrope repair of acromioclavicular dislocations. *Shoulder Elbow* 2014;6(01):18–22
- 23 Kayiaros S, Blankenhorn BD, Dehaven J, et al. Correction of metatarsus primus varus associated with hallux valgus deformity using the Arthrex mini tightrope: a report of 44 cases. *Foot Ankle Spec* 2011;4(04):212–217
- 24 Pinna S, Lanzi F, Tassani C, Mian G. Intra-articular replacement of a ruptured cranial cruciate ligament using the mini-TightRope in the dog: a preliminary study. *J Vet Sci* 2020;21(05):e53
- 25 Cook JL, Luther JK, Beetem J, Karnes J, Cook CR. Clinical comparison of a novel extracapsular stabilization procedure and tibial plateau leveling osteotomy for treatment of cranial cruciate ligament deficiency in dogs. *Vet Surg* 2010;39(03):315–323
- 26 Kieves NR, Lotsikas PJ, Schulz KS, Canapp SO. Hip toggle stabilization using the TightRope® system in 17 dogs: technique and long-term outcome. *Vet Surg* 2014;43(05):515–522
- 27 Ash K, Rosselli D, Danielski A, Farrell M, Hamilton M, Fitzpatrick N. Correction of craniodorsal coxofemoral luxation in cats and small breed dogs using a modified Knowles technique with the braided polyblend TightRope systems. *Vet Comp Orthop Traumatol* 2012;25(01):54–60
- 28 O'Donnell EM, Canapp SO Jr, Cook JL, Pike F. Treatment of medial shoulder joint instability in dogs by extracapsular stabilization with a prosthetic ligament: 39 cases (2008–2013). *J Am Vet Med Assoc* 2017;251(09):1042–1052
- 29 Stolarz M, Ficek K, Binkowski M, Wróbel Z. Bone tunnel enlargement following hamstring anterior cruciate ligament reconstruction: a comprehensive review. *Phys Sportsmed* 2017;45(01):31–40
- 30 Yao J, Song Y. Suture-button suspensionplasty for thumb carpo-metacarpal arthritis: a minimum 2-year follow-up. *J Hand Surg Am* 2013;38(06):1161–1165