



# Anal Cancer in Systemic Lupus Erythematosus Patients is a Neglected Condition

## *Câncer anal em pacientes com lúpus eritematoso sistêmico é uma condição negligenciada*

Maruska Dib lamut<sup>1</sup> Marcela Ignacchiti Lacerda<sup>1</sup> Mário Araújo Júnior<sup>2</sup>  
Jacara Maria Brito Macedo<sup>3</sup> Evandro Mendes Klumb<sup>1</sup>

<sup>1</sup>Rheumatology Department, Universidade do Estado do Rio de Janeiro, Rio de Janeiro, RJ, Brazil

<sup>2</sup>Pathology Department, Instituto Nacional do Câncer, Rio de Janeiro, RJ Brasil

<sup>3</sup>Biochemistry Department, Instituto de Biologia Roberto Alcântara Gomes, Rio de Janeiro, RJ, Brasil

Address for correspondence Maruska Dib lamut, MD, Coloproctologist at the Universidade do Estado do Rio de Janeiro (UERJ), Rua das Laranjeiras 280, apto 304, 22240-003, Rio de Janeiro, RJ Brazil (e-mail: mdiamut@gmail.com).

J Coloproctol 2023;43(1):52–55.

### Abstract

#### Keywords

- ▶ anal canal
- ▶ anus neoplasms
- ▶ anal cancer
- ▶ squamous cell carcinoma
- ▶ systemic lupus erythematosus
- ▶ human papillomavirus infection

#### Resumo

Patients with systemic lupus erythematosus have a higher incidence of neoplasms associated with human papillomavirus infections, such as those that affect the vulva, the vagina, and the cervix; however, little is known about the frequency of anal cancer among these patients. Although there are recommendations for screening for this cancer in immunosuppressed individuals, it is possible that this procedure is not strictly followed. We describe the case of a 47-year-old woman with systemic lupus erythematosus who was treated with immunosuppressants and developed advanced anal squamous cell carcinoma after adequate treatment and healing of a high-grade cervical squamous intraepithelial lesion. Five years after the completion of the anal cancer treatment, the patient presented with cystic hepatic lesions that were histopathologically confirmed to be metastatic squamous cell carcinoma. This report aimed to highlight the need for anal cancer screening in patients with lupus, particularly if there was a history of cervical cytopathological alterations.

Pacientes com lúpus eritematoso sistêmico apresentam maior incidência de neoplasias associadas a infecções por HPV, como aquelas que acometem a vulva, a vagina e o colo do útero, mas pouco se sabe sobre a frequência de câncer anal entre essas pacientes.

*This manuscript belongs to the Department of Rheumatology at the State University of Rio de Janeiro (UERJ), Rio de Janeiro, RJ, Brazil.*

received  
July 21, 2022  
accepted  
November 18, 2022

DOI <https://doi.org/10.1055/s-0042-1760220>  
ISSN 2237-9363.

© 2023. Sociedade Brasileira de Coloproctologia. All rights reserved.

This is an open access article published by Thieme under the terms of the Creative Commons Attribution-NonDerivative-NonCommercial-License, permitting copying and reproduction so long as the original work is given appropriate credit. Contents may not be used for commercial purposes, or adapted, remixed, transformed or built upon. (<https://creativecommons.org/licenses/by-nc-nd/4.0/>)

Thieme Revinter Publicações Ltda., Rua do Matoso 170, Rio de Janeiro, RJ, CEP 20270-135, Brazil

**Palavras-chave**

- ▶ canal anal
- ▶ neoplasias do ânus
- ▶ câncer anal
- ▶ carcinoma de células escamosas
- ▶ lúpus eritematoso sistêmico
- ▶ infecção por papilomavírus humano

Embora existam recomendações para o rastreamento desse câncer em indivíduos imunossuprimidos, é possível que esse procedimento não esteja sendo rigorosamente seguido. Descrevemos uma mulher de 47 anos com lúpus eritematoso sistêmico, tratada com imunossuppressores, que desenvolveu um carcinoma escamocelular anal avançado após tratamento adequado e cicatrização de lesão intraepitelial escamosa cervical de alto grau. Cinco anos após o término do tratamento do câncer anal, a paciente apresentou lesões císticas hepáticas cujo resultado citopatológico confirmou ser carcinoma escamocelular metastático. O presente relato teve como objetivo chamar atenção para a necessidade do rastreamento do câncer anal em pacientes com lúpus, principalmente se houver história prévia de alterações citopatológicas cervicais.

**Introduction**

There is a higher incidence of malignancies among patients with systemic lupus erythematosus (SLE) than among the general population, with hematological malignancies, such as non-Hodgkin's lymphoma, being the most frequent.<sup>1</sup> In addition, the prevalence of human papillomavirus (HPV) cervical infection in patients with SLE is trippled<sup>2</sup>; thus, there is an increased risk of HPV-associated neoplasia, such as vulvar, vaginal, and cervical cancer.<sup>3</sup> Cervical high-grade squamous intraepithelial lesions (HSIL) have been described nine times more frequently in women with SLE than in those without SLE,<sup>4</sup> particularly in low-income countries. Notwithstanding these concepts, there is insufficient data on the frequency of anal cancer among these patients, despite sharing pathophysiologic mechanisms similar to those of cervical origin.

**Presentation of the Clinical Case**

A 30-year-old white woman who presented with malar rash, polyarthrititis, serositis, pleural effusion, hemolytic anemia, nephrotic syndrome, and positive antinuclear antibody (1:1280, nuclear homogeneous) was diagnosed with SLE. She also presented antiphospholipid syndrome characterized by fetal loss at the 24<sup>th</sup> week of pregnancy, mesenteric thrombosis, positive lupus anticoagulant, and anticardiolipin antibodies. During treatment, she received methylprednisolone pulse therapy followed by oral prednisone and several immunosuppressive drugs, including intravenous cyclophosphamide (cumulative dose [CD] 13.8 g), azathioprine (CD 5,210 g), and mycophenolate mofetil (CD 360 g), in addition to hydroxychloroquine. Ten years after the diagnosis of SLE, a routine gynecological examination revealed cervical HSIL. Total deoxyribonucleic acid (DNA) extracted from cervical cells was used for HPV detection using polymerase chain reaction (PCR)-based assays with 2 primer sets (MY09/11 and GP05 +/06 + 2), which identified two different HPV types (62 and 83). In 2009, the patient was treated with curative cervical conization and subsequent cytopathological examination results remained negative until 2021. In 2014, at 47 years old, the patient presented with anal pain, bleeding, and changes in bowel habits. Proctological exami-

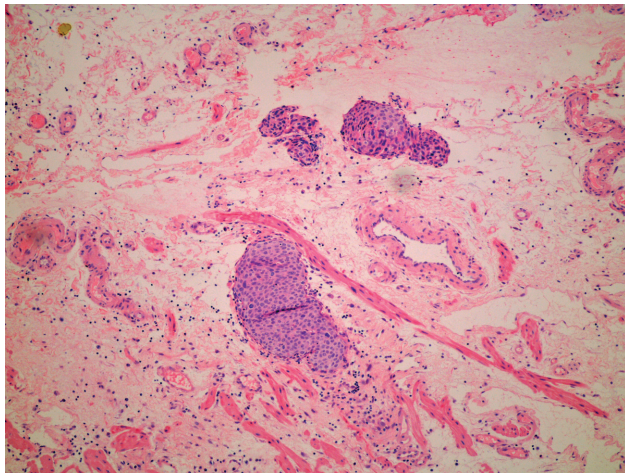
nation revealed a small lump around the anus. Histopathological analysis confirmed the diagnosis of advanced-stage anal squamous cell carcinoma (ASCC) (▶**Fig. 1**) based on magnetic resonance staging (IIIB-T2N3M0). Anal cancer was treated with chemotherapy and radiation with a complete local response, with no indication for surgery. One year later, the patient developed liver metastasis, requiring additional treatment with capecitabine, and she presented with a complete response to treatment. In 2022, five years after the last chemotherapy, despite having no further anal and/or cervical lesions and her control colonoscopies being normal except for actinic retitis, she was admitted because of poor general condition, fever, and abdominal pain. Abdominal computed tomography (CT) and magnetic resonance imaging (MRI) confirmed the presence of liver lesions with cystic features. Cytopathological and immunohistochemical studies performed after percutaneous puncture of these lesions confirmed the diagnosis of metastatic squamous cell carcinoma.

The present case report was approved by the Ethics and Research Committee of the Pedro Ernesto University Hospital/Universidade do Estado do Rio de Janeiro. An informed consent form was signed by the patient and is under our responsibility in case it is requested.

**Discussion**

In the present case report, we present the case of a patient with SLE who developed HSIL in the cervix and subsequently ASCC, despite adequate treatment with cervical conization. Notably, anal cancer was diagnosed at an advanced stage despite cervical Papanicolaou tests within this interval not showing any new significant cervical lesions.

Anal cancer is rare in the general population and accounts for ~ 0.5% of all neoplasms. It is mainly squamous cell carcinoma (85% of all cases) and has a mortality rate of ~ 32% over 5 years.<sup>5,6</sup> A striking feature of this specific cancer is its association with HPV infection, particularly high-risk HPV types, wherein DNA is found in 88.3 to 90% of cases, and is considered a necessary etiologic factor.<sup>7,8</sup> Other risk factors for ASCC include cervical premalignant and malignant lesions, anal intercourse, a high number of sexual partners, genital warts, cigarette smoking, human immunodeficiency



**Fig. 1** Island of atypical basoloid cells infiltrating connective tissue consistent with squamous cell carcinoma.

virus (HIV) infection, and men who have sex with men independently of HIV infection.<sup>9,10</sup>

Although high-risk HPV types 16 and 18 are the most commonly associated with cervical cancer and ASCC, low-risk HPV has also been described.<sup>7</sup> Curiously, in the present case, HPV types 62 and 83, which belong to the *Alphapapillomavirus* genus, were classified as low-risk.<sup>11</sup> In a study that analyzed cervical samples in Mexico, DNA derived from HPV type 62 was found in 4.6% of cervical cancer samples, and among these cases, 90.5% were coinfecting with other types, frequently including HPV type 83.<sup>12</sup> In the present case, it was not possible to perform a molecular study of HPV in the ASCC sample; however, the high agreement between cervical and anal HPV types, as reported in previous studies, suggests that the HPV types found in the cervix of the patient are probably the same in the anal canal.<sup>13</sup> There is a higher frequency of ASCC among patients with previous vulvar, vaginal, and cervical cancer; however, little is known about the relationship between cervical lesions and anal cancer in patients with lupus, despite a recently published meta-analysis that described an anal cancer incidence rate of 10/100,000 person-years.<sup>9</sup> Immunosuppressants are the standard of care for lupus nephritis and other complications of the disease. The continuous use of these agents, as reported in the present case, may be one of the most important risk factors associated with the higher frequency of ASCC observed in patients who underwent solid organ transplantation.<sup>14</sup> The use of immunosuppressants may further enhance immune disturbances and the risk of virus persistence, since patients with SLE treated with these agents have an even higher risk of presenting with HPV infection and/or HPV-related cervical lesions.<sup>2</sup>

Screening for anal intraepithelial lesions and anal cancer is imperative in HIV-positive populations. However, little is known about the cost-benefit balance of implementing this guideline in other high-risk populations, such as patients with autoimmune diseases or chronic immunosuppressant use. Given that the patients with lupus and severe clinical manifestations, including nephritis, may be maintained un-

der therapeutic immunosuppression for long periods, they may be considered a high-risk population for ASCC. It is important to emphasize that women with SLE have a 7 times greater risk of having some type of dysplasia and an 11 times greater risk of having premalignant cervical lesions than women without SLE.<sup>15</sup>

The primary prevention of anal cancer is vaccination, which covers the most common types of high- and low-risk HPV involved in oncogenesis.<sup>16</sup> However, patients with SLE may present with other types of high-risk HPV that are not covered by the currently available vaccines.<sup>2</sup> Secondary prevention of anal cancer is based on the model used for cervical cancer screening, in which anal cytology is performed. When abnormalities are detected, the patient is referred for anal colposcopy, known as high-resolution anoscopy, which allows for biopsy and treatment of anal canal premalignant lesions.<sup>17</sup> The vaccine alone would not have protected the patient, since the HPV type detected in the cervix was different from that commonly covered by the vaccine. However, knowledge about cancer prevention through anal cytology, particularly in immunosuppressed patients and in those with a history of premalignant cervical lesions, could have prevented the evolution of anal dysplasia into advanced cancer in this patient.

In summary, the present case report aims to draw attention to the fact that patients with SLE, particularly those receiving immunosuppressive drugs, should be referred not only for cervical Papanicolaou smears but also for anal cytology analyses to promptly identify and treat malignant and premalignant lesions and prevent progression to invasive cancer.

#### Conflict of interests

The authors have no conflict of interests to declare.

#### References

- Bernatsky S, Boivin JF, Joseph L, et al. An international cohort study of cancer in systemic lupus erythematosus. *Arthritis Rheum* 2005;52(05):1481–1490
- Klumb EM, Pinto AC, Jesus GR, et al. Are women with lupus at higher risk of HPV infection? *Lupus* 2010;19(13):1485–1491
- Song L, Wang Y, Zhang J, Song N, Xu X, Lu Y. The risks of cancer development in systemic lupus erythematosus (SLE) patients: a systematic review and meta-analysis. *Arthritis Res Ther* 2018;20(01):270
- Zard E, Arnaud L, Mathian A, et al. Increased risk of high grade cervical squamous intraepithelial lesions in systemic lupus erythematosus: A meta-analysis of the literature. *Autoimmun Rev* 2014;13(07):730–735
- Howlander N, Noone A, Krapcho M, et al. SEER Cancer Statistics Review, 1975–2018 [Internet]. National Cancer Institute. Bethesda, MD. 2021. Available at: <https://seer.cancer.gov/statfacts/html/anus.html>
- Nelson VM, Benson AB III. Epidemiology of Anal Canal Cancer. *Surg Oncol Clin N Am* 2017;26(01):9–15
- Alemanly L, Saunier M, Alvarado-Cabrero I, et al; HPV VVAP Study Group. Human papillomavirus DNA prevalence and type distribution in anal carcinomas worldwide. *Int J Cancer* 2015;136(01):98–107
- Lin C, Franceschi S, Clifford GM. Human papillomavirus types from infection to cancer in the anus, according to sex and HIV

- status: a systematic review and meta-analysis. *Lancet Infect Dis* 2018;18(02):198–206
- 9 Clifford GM, Georges D, Shiels MS, et al. A meta-analysis of anal cancer incidence by risk group: Toward a unified anal cancer risk scale. *Int J Cancer* 2021;148(01):38–47
  - 10 Daling JR, Madeleine MM, Johnson LG, et al. Human papillomavirus, smoking, and sexual practices in the etiology of anal cancer. *Cancer* 2004;101(02):270–280
  - 11 International Agency for Research on Cancer Human papillomaviruses: this publication represents the views and expert opinions of an IARC Working Group on the Evaluation of Carcinogenic Risks to Humans, which met in Lyon, 15 - 22 February 2005. Lyon: IARC; 2007. 670 p. (IARC monographs on the evaluation of carcinogenic risks to humans)
  - 12 Artaza-Irigaray C, Flores-Miramontes MG, Olszewski D, et al. Genetic variability in E6, E7 and L1 genes of Human Papillomavirus 62 and its prevalence in Mexico. *Infect Agent Cancer* 2017; 12:15
  - 13 Nasioutziki M, Chatzistamatiou K, Loufopoulos PD, et al. Cervical, anal and oral HPV detection and HPV type concordance among women referred for colposcopy. *Infect Agent Cancer* 2020;15:22
  - 14 Patel HS, Silver ARJ, Northover JMA. Anal cancer in renal transplant patients. *Int J Colorectal Dis* 2007;22(01):1–5
  - 15 Klumb EM, Araújo ML Jr, Jesus GR, et al. Is higher prevalence of cervical intraepithelial neoplasia in women with lupus due to immunosuppression? *J Clin Rheumatol* 2010;16(04):153–157
  - 16 Joura EA, Giuliano AR, Iversen OE, et al; Broad Spectrum HPV Vaccine Study. A 9-valent HPV vaccine against infection and intraepithelial neoplasia in women. *N Engl J Med* 2015;372(08):711–723
  - 17 Palefsky JM. Practising high-resolution anoscopy. *Sex Health* 2012;9(06):580–586