Article published online: 2023-02-07

Acute Retropharyngeal Abscess in Libyan Children: Case Series and Literature Review

Shirin Alougly[1,2] Alia Alhsony[1,2] Aisha Elarwah[1,2] Suliman Elbragathy[1,2]

[1] Pediatrics Intensive Care Unit, Benghazi Children's Hospital, Benghazi, Libya
[2] Pediatric Department, Faculty of Medicine, Benghazi University, Benghazi, Libya

Address for correspondence Shirin Idriss Alougly, MD, Pediatric Intensive Care Unit, Benghazi Children's Hospital, Benghazi, Libya (e-mail: dr.tabs6@gmail.com).

Ibnosina J Med Biomed Sci 2022;14:152–156.

Abstract

Background A retropharyngeal abscess (RPA) is a deep neck infection that considers a medical emergency because of the possibility of serious complications including life-threatening upper airway obstruction, mediastinitis, and sepsis.

Materials and Methods We present our experience in Benghazi Children's Hospital, describing the clinical presentations, diagnostic workup, management, and the outcome of four children presented during the time period between November 2017 and November 2021 as cases of RPA secondary to penetrating trauma to the posterior pharyngeal wall either due to ingestion of a foreign body or due to manipulation of tonsils by the traditional therapist.

Results All cases presented with fever, poor feeding, and hyperextension of the neck. All were diagnosed by ultrasound and they needed surgical drainage of RPA, as they did not improve with medical treatment alone.

Conclusion A high index of suspicion is necessary for the early diagnosis and treatment of RPA. Two of our cases were presented following the manipulation of tonsils by a traditional therapist, so we attempted to emphasize this life-threatening consequence after traditional therapy, as well as the unnecessary morbidity and mortality associated with this ongoing traditional treatment in our country.

Keywords
- retropharyngeal abscess
- children

Introduction

The retropharyngeal space is defined as the area between the posterior pharyngeal wall and the deep prevertebral fascia.[1] A retropharyngeal abscess (RPA) is a deep neck infection that is considered a surgical emergency due to the accompanying or attending complications including life-threatening upper airway obstruction, mediastinitis, and sepsis.[2] RPA is a disease that affects both children and adolescents; however, it is more commoner among young children aged between 6 months and 6 years; this is probably due to atrophy of retropharyngeal lymph nodes later in life.[2,3] RPA develops either due to the extension of an upper respiratory tract infection to the retropharyngeal lymph nodes or due to direct trauma to the posterior pharyngeal wall.[4] Trauma is the most common cause of RPA in adolescents and adults, and it can be caused by the ingestion of a foreign body (FB, most likely a piece of bone) or by procedures.[2]

DOI https://doi.org/10.1055/s-0042-1760303.
ISSN 1947-489X.

Thieme Medical and Scientific Publishers Pvt. Ltd., A-12, 2nd Floor, Sector 2, Noida-201301 UP, India

Sore throat, fever, neck swelling, pain with neck extension, drooling, stridor, and respiratory distress are all symptoms of a RPA.[2]

The widespread use of antibiotics has significantly reduced the prevalence of RPA and other deep neck abscesses. However, deep neck abscesses if untreated or poorly managed could lead to complications such as necrotizing mediastinitis and airway obstruction.[5]

RPA is more in males, according to the majority of studies.[6–9] Gram-positive, gram-negative, and anaerobe organisms are the most common causes of RPA.[6]

For children with deep neck abscesses, the diagnostic options include ultrasound (US), plain X-ray soft tissue neck, computed tomography (CT) scan, and magnetic resonance imaging while CT scan is the best choice.[2]

Doppler US is noninvasive, rapid, cheap, and has no radiation. It helps to determine a mass's form, size, vascularity, and location. Furthermore, negative US results should not rule out the diagnosis of RPA.[7] The optimal management of RPA includes controlling the airway, administering intravenous (IV) antibiotics, and surgical drainage, while some cases are managed with antibiotics alone.[2,8,9]

Materials and Methods

Four patients with clinical and radiological features suggestive of RPA who were hospitalized in the pediatric intensive care unit (PICU) at Benghazi Children's Hospital (BCH) between November 2017 and November 2021 were prospectively studied.

Two boys and two girls were included in this study. The patients varied in age from 2 months to 11 years. RPA occurred in our patients because of injury to the posterior pharyngeal wall by either FB ingestion or injury to the pharyngeal wall by a traditional therapist. Details of the patient characteristics, clinical presentations, and management were described.

The PubMed database was used for our literature review throughout the period from 1991 to 2019.

To the best of our knowledge, this is the first case series of RPA in Libyan children.

Case 1

A 9-month-old Libyan girl was presented to BCH with a history of fever, cough, poor feeding, lethargy, vomiting blood, and frequent chocking a few days after ingesting a piece of glass accidentally. The patient was sick, febrile, with inspiratory stridor and respiratory distress. Chest examination showed reduced air entry and crepitations on the right side of the chest. A bronchoscopy was performed on the day of admission and revealed no FB. She was discharged after 10 days of IV cefotaxime. A few days later, she was readmitted to our PICU at BCH because of fever, lethargy, persisting cough, recurrent choking, and vomiting. On examination, she was sick, febrile, drooling saliva, inspiratory stridor, submandibular tender swelling, and cervical lymphadenopathy, but no respiratory compromise. Complete blood count (CBC) on the day of admission showed hemoglobin of 11.2 g/dL, platelet count of 782,000/mL, white blood cell (WBC) of 10,100/mL. Erythrocyte sedimentation rate (ESR) was 20. Prothrombin time (PT), partial thromboplastin time (PTT), arterial blood gas (ABG), sodium (Na), potassium (K), blood urea nitrogen (BUN), creatinine, and liver enzymes all were normal. Blood cultures were negative. The clinical suspicion of a RPA was confirmed by US of the neck. A CT scan of the neck was advised; however, the CT scan was out of commission in our hospital, and the patient's overall condition made it unsafe to undergo CT outside the hospital. RPA was drained through fine-needle aspiration, and no FB was found. Meropenem, vancomycin, and metronidazole were used and continued for 2 weeks. Follow-up US revealed no evidence of collection, and the patient was discharged in good general condition after 10 days at the PICU followed by a 5-days inpatient stay.

Case 2

A 2-month-old boy was admitted to our PICU at BCH with 3 days history of fever, cough, breathlessness, and poor feeding. His symptoms began 4 days after the manipulation of his tonsils by a traditional therapist. On examination, the child was sick, febrile, drooling saliva, tachypnic, multiple left cervical lymph node enlargements, inspiratory stridor with suprasternal and subcostal retraction with constant neck hyperextension, and deviation to the right side. Abdominal examination revealed hepatosplenomegaly and chest examination showed bilateral reduced air entry and crepitations. US of the neck showed evidence of fluid collection seen at retropharyngeal and left parapharyngeal region measured approximately 3cm X 1.5cm and bilateral multiple L N enlarged seen at submandibular, upper cervical, and posterior auricular. CBC showed hemoglobin of 9.9 g/dL, platelet count of 855,000/mL, WBC of 25,100/mL. ESR was 61. PT, PTT, ABG, S. Na, S. K, BUN, creatinine, and liver enzymes all were normal. Blood cultures were negative. The patient was treated with IV ceftriaxone, flucloxacillin, metronidazole, and gentamycin. The abscess was drained through fine-needle aspiration and the patient improved. After 7 days of PICU stay followed by 13 days of inward stay, the patient was discharged in a good general condition.

Case 3

A 1-year-old male was referred to PICU at BCH as a case of fever, stridor, inability to extend the neck, inability to swallow saliva, and neck swelling all of these were noted 3 days after manual manipulation of tonsils by the traditional therapist. On examination, the child was sick, febrile, tachypnic, inspiratory stridor with suprasternal and subcostal retraction with constant neck hyperextension, drooling of saliva, and continuous worsening of respiratory distress. Abdominal and chest examinations were normal. CBC on the day of admission showed hemoglobin of 9.5 g/dL, platelet count of 190,000/mL, WBC of 7.500/mL. C-reactive protein (CRP) was 111. PT, PTT, ABG, Na, K, BUN, creatinine, and liver

enzymes all were normal. Blood cultures were negative. The patient was started on IV ceftriaxone, metronidazole, and gentamycin.

Lateral neck X-ray showed widening of the prevertebral space; US of the neck confirmed the diagnosis of RPA. Abscess was drained on the day of the admission by fine-needle aspiration. On the ninth day of hospitalization, the patient was discharged on oral cephalexin and was in good general condition.

Case 4

A 11-year-old female was referred to our PICU in BCH with fever, throat pain, and dysphagia for 11 days, following ingestion of a piece of bone while eating. Her complaints of throat pain and dysphagia increased in severity 3 days before her admission to our unit and were accompanied by left neck swelling, muffled voice, inability to move the neck, and drooling of saliva, which became severe on the day of admission to the PICU. On examination, she was sick, febrile, drooling saliva, left neck swelling, and in respiratory distress. She was vitally stable and her systemic examination was normal, apart from worsening respiratory distress. The lateral radiograph of the neck showed widening of the prevertebral space with a radio-opaque FB and air-fluid level (►**Fig. 1**). The full blood count showed a hemoglobin level of 13 g/dL, a WBC count of 24.8 × 109/L, and a normal platelet count of 301 × 109/L. Urea and electrolytes were normal, and

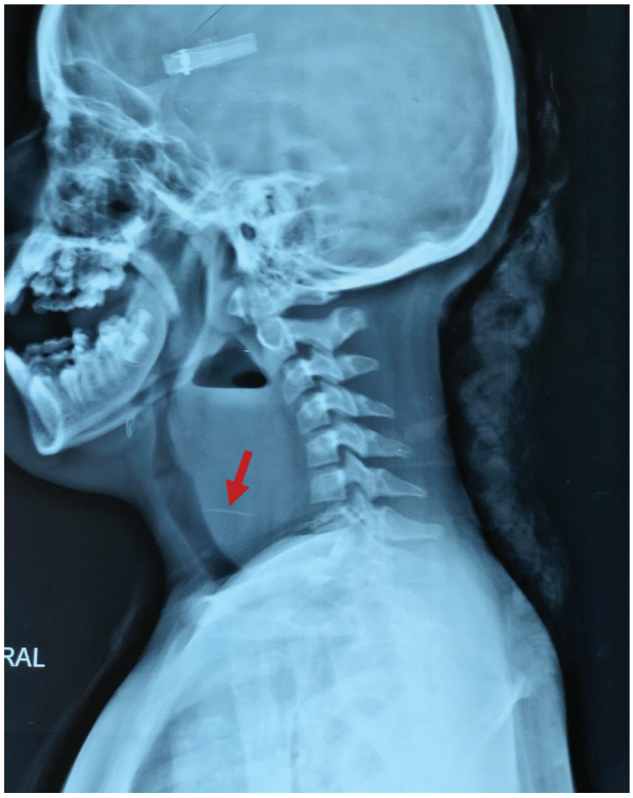

Fig. 1 Lateral neck radiograph of fourth case showing widened prevertebral soft tissues, presence of air-fluid levels within the retropharyngeal space, loss of the normal cervical lordosis, and presence of foreign body within the retropharyngeal space (arrow).

Fig. 2 Lateral neck radiograph of fourth case showing widened prevertebral soft tissues and presence foreign body within the retropharyngeal space (arrow).

the CRP and ESR were raised (127 mg/L and 87, respectively). She was treated with IV antibiotics (ceftriaxone, gentamicin, and cloxacillin). ENT team was consulted for urgent drainage of the abscess, which was done on the day of admission but the FB could not be removed. On the second day after the first drainage, patient complained of throat pain, drooling and fever. The lateral radiograph of the neck showed widening of the prevertebral space with a radio-opaque FB but no air-fluid level (►**Fig. 2**); US of the neck confirmed the presence of a RPA. A CT scan also confirmed the presence of RPA and FB. The second drainage of the abscess was performed through a transcervical incision on the fifth day of the PICU admission and finally, FB was removed and symptoms resolved. The patient was discharged home on the fourth postoperative day with oral antibiotics and was well.

Discussion

A RPA is a rare deep neck infection that usually affects young children. It is the most common deep neck infection in children. RPA abscess is twice more common than parapharyngeal abscess.[8]

The four cases described in this study were presented to BCH during the time period between November 2017 and November 2021 as cases of RPA secondary to penetrating trauma to the posterior pharyngeal wall either due to ingestion of a FB (first and fourth patients) or due to

manipulation of tonsils by a traditional therapist (second and third patients).

Nazir et al[6] reported that only 15% of 40 patients with RPA had a history of penetrating injury to the posterior pharyngeal wall either due to trauma to the pharyngeal wall or a FB.

Many studies have found that RPA is more prevalent among males.[8,10] Lander et al[10] noticed that 63% of 1,322 RPA patients were male. Woods et al[8] found that the incidence of RPA was greater among boys than girls in all age groups and that the incidence of RPA increased from 2.98 per 1,00,000 population among children less 20 years old in 2003 to 4.10 per 1,00,000 population in 2012.

Our patients were three infants and one adolescent. RPA is more common in young children than in adolescents. In a study of 40 children with RPA, Nazir et al[6] reported that 42.2% of patients were under the age of 3, and only 15% of patients were adolescents between the ages of 10 and 15. In another study, 55% of RPA cases were in children under the age of 5.[8]

Fever, poor feeding, and cervical swelling were all reported in all of our patients, but stridor was only seen in infants, which is consistent with the findings of other authors Coulthard and Isaacs[11] who reported stridor in 71% of children under the age of 1 year and none over the age of 3.

Despite the fact that all of our patients had negative blood cultures, previous research suggests that RPAs are most commonly caused by *Streptococcus pneumoniae* and *Staphylococcus aureus* infections.[4] Nazir et al[6] discovered that 15% of cases had negative pus cultures and only one patient had a positive blood culture.

A definitive diagnosis of RPA usually requires imaging, such as lateral neck radiography, US, and CT scan. All of our patients were diagnosed by US, and only two patients (the third and fourth patients) had typical X-ray findings on lateral neck radiography including widening of the retropharyngeal soft tissues (in third and fourth patients), air fluid level, and straightening of normal cervical lordosis (in the fourth patient), whereas a CT scan was performed only in the fourth patient after the first drainage to confirm the presence of a residual abscess.

US has been regarded useful in the diagnosis of deep neck infections due to the lack of radiation exposure. In the hands of a skilled operator, US can detect the presence and location of an abscess as well as differentiate an abscess from cellulitis, in addition to guiding a small needle during RPA draining.[12]

Nazir et al[6] found that 93% of 40 patients studied by them had widening of the retropharyngeal soft tissues, 75% had straightening of normal cervical lordosis, and 55% had air-fluid level within an abscess cavity. Nazir et al[6] also noted that the false-positive rate of the contrast-enhanced CT scan was 17%, while the false-positive rate of the X-ray was 30%.

In this current study, surgical drainage was necessary in all cases since medical therapy alone did not succeed for our patients. According to a retrospective study conducted by Kosko and Casey[13] when a RPA is greater than 2 cm in diameter, IV antibiotic treatment alone is more likely to fail and surgical drainage is more likely to be required.

For patients with RPA who do not show improvements over 48 hours of antibiotic therapy, an incision and drainage procedure should be performed. Surgical drainage mainly involves two approaches intraoral and transcervical. Needle aspiration of the RPA is likely to result in recurrence and incomplete drainage as seen in patient 4 that lead to an external approach, but literature has described the best approach and safe treatment as intraoral incision and drainage using the cruciate incision and breaking of all loculi.[14]

Several other authors have suggested using surgery only when patients do not respond to medical treatment.[15,16]

Page et al[17] reviewed 162 pediatric patients with RPA and found that the initial treatment was surgery in 126 and IV antibiotics in 36, of which 17 required surgery and they tried to identify several predictive factors that may be useful in identifying those children with RPAs who should be treated with surgical drainage; these factors included duration of symptoms for more than 2 days, prior antibiotic treatment, and CT lesion cross-sectional area more than 2.0 cm.

Lander et al[10] reviewed 1,321 children with RPA and found that 43% required surgical drainage, and usually stay in the hospital for a longer time than other patients who were treated with antibiotics without drainage. Furthermore, in a study conducted by Woods et al[8] 46.7% of 6233 children with RPA required surgical drainage, and they reported that the proportion of RPA patients requiring surgical drainage had reduced slightly from 2003 to 2012 (49.6–44.3%).

According to Johnston et al,[18] nine out of 22 patients with RPA had been successfully treated by medical therapy alone, with a hospital stay similar to that of surgical therapy.

In all of our cases, the length of hospital stay (LOS) varied between 7 and 20 days.

According to Woods et al,[8] the average hospital stay for children with RPA decreased from 4.26 to 3.90 days from 2003 to 2012. The median LOS was one day longer for children with RPA with surgical drainage.

In 71% of the cases of RPA, the first surgical intervention is usually undertaken on the day of admission or the day after admission.[8] All of our patients' surgical drainage procedures were performed within the first 24 hours of admission.

No death was reported in our study, matching what another investigator has described.[19]

The mortality rate was reported to be very low by Woods et al[8] one death (0.02%) out of 6,233 cases of RPA. Another author reported two deaths in a study of ten cases of RPA in a developing country.[5]

Conclusion

A high index of suspicion, early recognition, and aggressive management of RPA are essential as the delay in the diagnosis and management has a negative impact on the outcome in children. When correctly managed, RPA has low morbidity and mortality.

The presence of fever and neck mass should increase the suspicion of RPA.

The use of traditional medicine could have serious consequences for some patients. Two of our patients follow

tonsil manipulation by a traditional therapist, so we aim to emphasize this life-threatening consequence as well as the avoidable morbidity and mortality linked with this ongoing style of therapy in our country.

Authors' Contributions

Shirin Alougly helped in conceptualizing the study, writing, reviewing, editing, revising it critically for important intellectual content, and final approval of the version to be published. Alia Alhsony and Aisha Elarwah drafted, revised, and finalized the manuscript. Suliman Elbragathy helped in supervising and reviewing for final approval.

Compliance with Ethical Principles

The study was approved by the Benghazi Children Hospital committee for scientific research and the Research and Consulting Department at the Faculty of the Medicine University of Benghazi.

Informed Consent

Permission was obtained from the families and all are agreed to share their children data and publishing it.

Sponsorship and Funding

None.

Conflict of Interest

None declared.

Acknowledgments

The authors would like to thank our participating patients and their families.

References

1 Vieira F, Allen SM, Stocks RMS, Thompson JW. Deep neck infection. Otolaryngol Clin North Am 2008;41(03):459–483, vii
2 Gould JM. Pharyngitis, stomatitis, peritonsillar and retropharyngeal abscess. Paediatr Infect Dis 2008:96–107
3 LeRiger MM, Miler V, Tobias JD, Raman VT, Elmaraghy CA, Jatana KR. Potential for severe airway obstruction from pediatric retropharyngeal abscess. Int Med Case Rep J 2017;10:381–384
4 Mydam J, Thiagarajan P. A nine month old child with retropharyngeal abscess secondary to mastoid abscess presenting as torticollis: a case report. Cases J 2009;2:6460. Doi: 10.4076/1757-1626-2-6460
5 Ameh EA. Acute retropharyngeal abscess in children. Ann Trop Paediatr 1999;19(01):109–112
6 Nazir KA, Fozia PA, Ul Islam M, Shakil A, Patigaroo SA. Paediatric acute retropharyngeal abscesses: an experience. Afr J Paediatr Surg 2013;10(04):327–335
7 Poonit ND, Zhou YY, Xu DF, et al. Retropharyngeal Abscess in Children: A Retrospective Study. Ann Pediatr Res 2019;3(03):1027
8 Woods CR, Cash ED, Smith AM, et al. Retropharyngeal and parapharyngeal abscesses among children and adolescents in the United States: epidemiology and management trends, 2003–2012. J Pediatric Infect Dis Soc 2016;5(03):259–268
9 Craig FW, Schunk JE. Retropharyngeal abscess in children: clinical presentation, utility of imaging, and current management. Pediatrics 2003;111(6 Pt 1):1394–1398
10 Lander L, Lu S, Shah RK. Pediatric retropharyngeal abscesses: a national perspective. Int J Pediatr Otorhinolaryngol 2008;72(12):1837–1843
11 Coulthard M, Isaacs D. Retropharyngeal abscess. Arch Dis Child 1991;66(10):1227–1230
12 Glasier CM, Stark JE, Jacobs RF, et al. CT and ultrasound imaging of retropharyngeal abscesses in children. AJNR Am J Neuroradiol 1992;13(04):1191–1195
13 Kosko J, Casey J. Retropharyngeal and parapharyngeal abscesses: factors in medical management failure. Ear Nose Throat J 2017;96(01):E12–E15
14 Sharma SB, Hong P. Ingestion and pharyngeal trauma causing secondary retropharyngeal abscess in five adult patients. Case Rep Emerg Med 2012;2012:943090. Doi: 10.1155/2012/943090
15 Courtney MJ, Mahadevan M, Miteff A. Management of paediatric retropharyngeal infections: non-surgical versus surgical. ANZ J Surg 2007;77(11):985–987
16 Oh JH, Kim Y, Kim CH. Parapharyngeal abscess: comprehensive management protocol. ORL J Otorhinolaryngol Relat Spec 2007;69(01):37–42
17 Page NC, Bauer EM, Lieu JEC. Clinical features and treatment of retropharyngeal abscess in children. Otolaryngol Head Neck Surg 2008;138(03):300–306
18 Johnston D, Schmidt R, Barth P. Parapharyngeal and retropharyngeal infections in children: argument for a trial of medical therapy and intraoral drainage for medical treatment failures. Int J Pediatr Otorhinolaryngol 2009;73(05):761–765
19 Zahraa JN, Al-Boukai AA, Boukai A. Acute retropharyngeal and parapharyngeal abscesses in children. Saudi Med J 2002;23(08):899–903

