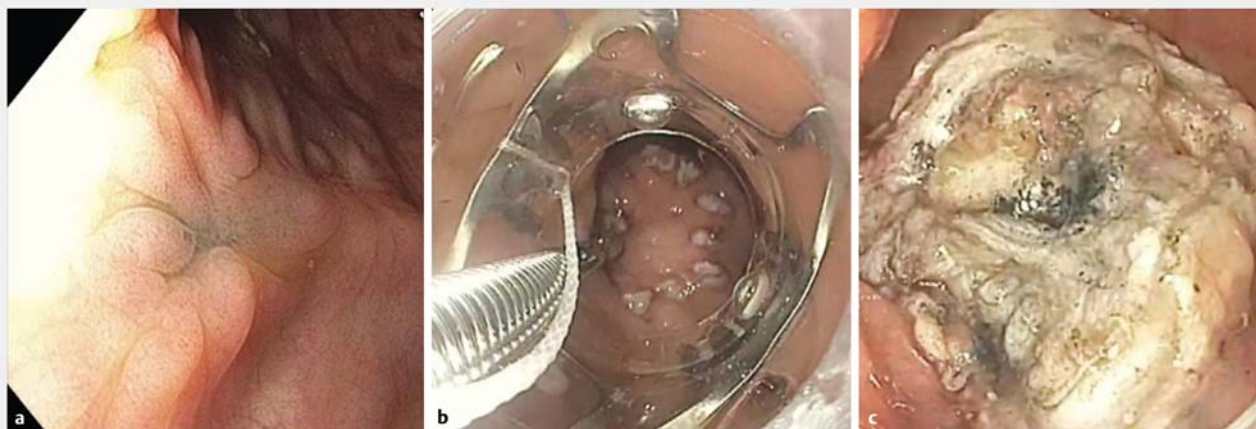
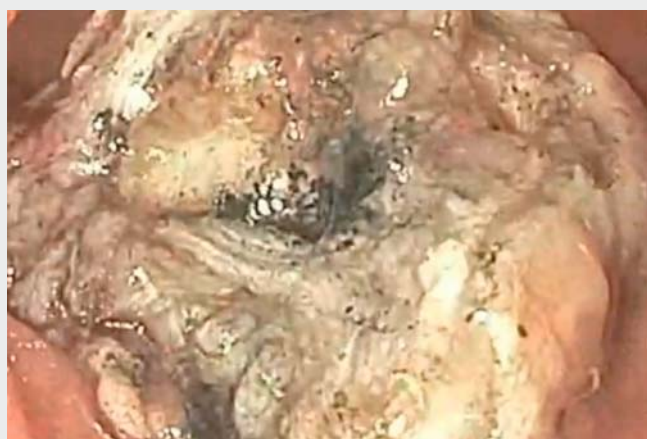

Full-thickness resection of a rectal scar using a modified over-the-scope clip after piecemeal resection of intramucosal cancer



► Fig. 1 Full-thickness resection using a modified over-the-scope clip (OTSC). **a** Endoscopic view of the rectal scar above the first valve of Houston. **b** Visualization of the argon plasma coagulation marks on the lesion margins as the lesion is being pulled into the cap. **c** Full-thickness resection site after removal of the specimen.



► Video 1: Full-thickness resection of a rectal scar using a modified over-the-scope clip.

A 51-year-old woman presented with rectal bleeding. Colonoscopy revealed a 2.5 cm rectal polyp at 15 cm from the anus, which was successfully removed via piecemeal endoscopic mucosal resection (EMR). Histopathology showed traditional serrated adenoma with high grade dysplasia and a focus that was suspicious for intramucosal adenocarcinoma. Posi-

tron emission tomography obtained 1 month later was notable for increased uptake in the rectum. She was referred to a colorectal surgeon for transanal minimally invasive surgery for excision of the scar and surrounding tissue.

Flexible sigmoidoscopy showed a scar and tattoo at the site of the previous EMR in the anterior wall of the rec-

tum, just above the first valve of Houston (**► Fig. 1 a**); biopsies revealed scarring but no neoplasia. Given the location of the EMR scar, transanal excision was deemed difficult. Thus, we performed endoscopic full-thickness resection of the rectal scar using a telescoping cap and over-the-scope clip (OTSC) (**► Video 1**).

The scar was 20×15 mm in size, and its margin was marked using argon plasma coagulation (APC). Ex vivo, a 4 mm distal clear cap was placed at the tip of an upper endoscope, followed by a 14 mm OTSC (14/6t) mounted over the cap. A rat tooth forceps was used to grasp the EMR scar and pull it into the cap (**► Fig. 1 b**). Once the APC markers were seen within the cap, the OTSC clip was deployed, capturing the entire margin of the EMR scar above the clip. The tissue above the OTSC was then resected using a needle-knife, leaving a well-circumscribed resection site (**► Fig. 1 c**). Muscle tissue and perirectal fat were seen at the resection site, confirming a full-thickness resection. Histopathology also demonstrated a full-thickness specimen with scarring and no dysplasia or neoplasm.

This case demonstrates that endoscopic resection of a difficult-to-access scar can be achieved by use of a telescoping cap and OTSC, averting the need for surgical resection.

Endoscopy_UCTN_Code_TTT_1AQ_2AC

Competing interests

Dr. Mouen A. Khashab serves as a consultant for Boston Scientific.

Dr. Vivek Kumbhari is a consultant for Boston Scientific and Apollo Endosurgery. Drs. Agarwal, Fang, Pezhouh and Ngamruengphong do not have any financial disclosures.

The Authors

Amol Agarwal¹, Sandy Fang², Maryam K. Pezhouh³, Vivek Kumbhari¹, Mouen A. Khashab¹, Saowanee Ngamruengphong¹

- 1 Department of Medicine, Division of Gastroenterology and Hepatology, Johns Hopkins Hospital, Baltimore, Maryland, United States
- 2 Department of Surgery, Johns Hopkins Hospital, Baltimore, Maryland, United States

- 3 Department of Pathology, Johns Hopkins Hospital, Baltimore, Maryland, United States

Corresponding author

Saowanee Ngamruengphong, MD

Division of Gastroenterology and Hepatology, Johns Hopkins Medicine, 4940 Eastern Avenue, A Building, 5th Floor, Baltimore, MD 21224, United States
 Fax: +1-410-550-7861
 sngamru1@jhmi.edu

Bibliography

DOI <https://doi.org/10.1055/s-0043-106045>

Endoscopy 2017; 49: E151–E152

© Georg Thieme Verlag KG

Stuttgart · New York

ISSN 0013-726X

ENDOSCOPY E-VIDEOS

<https://eref.thieme.de/e-videos>



Endoscopy E-Videos is a free access section, reporting on interesting cases and new techniques in gastroenterological endoscopy. All papers include a high quality video and all contributions are freely accessible online.

This section has its own submission website at

<https://mc.manuscriptcentral.com/e-videos>