

Clinical Value of Contrast Enema Prior to Ileostomy Closure

Klinische Wertigkeit der Durchleuchtungsuntersuchung des aboralen Stomaschenkels mittels Kontrasteinlauf

Authors

Andrea Goetz¹, Natascha Platz Batista da Silva¹, Christian Moser², Ayman Agha², Lena-Marie Dendl¹, Christian Stroszczynski¹, Andreas G. Schreyer¹

Affiliation

- 1 University Hospital Regensburg, Department of Radiology, Regensburg, Germany
- 2 Clinic Bogenhausen, Munich, Department of General, Visceral, Endocrine and Minimally-Invasive Surgery, Munich, Germany

Key words

ileostomy, ileostomy closure, contrast enema

received 27.12.2016

accepted 24.04.2017

Bibliography

DOI <https://doi.org/10.1055/s-0043-111598>

Published online: 2017 | Fortschr Röntgenstr 2017; 189: 855–863 © Georg Thieme Verlag KG, Stuttgart · New York, ISSN 1438-9029

Correspondence

Prof. Andreas G. Schreyer
Department of Radiology, University Hospital Regensburg, Germany, Franz-Josef-Strauss-Allee 11, 93051 Regensburg, Germany
Tel.: ++49/941/944 74 01
Fax: ++49/941/944 74 02
andreas.schreyer@klinik.uni-regensburg.de

ABSTRACT

Purpose To determine the value of routine contrast enema of loop ileostomy before elective ileostomy closure regarding the influence on the clinical decision-making.

Materials and Methods Retrospective analysis of contrast enemas at a tertiary care center between 2005 und 2011. Patients were divided into two groups: Group I with ileostomy reversal, group II without ileostomy closure. Patient-related parameters (underlying disease, operation method) and parameters based on the findings (stenosis, leakage of anastomosis, incontinence) were evaluated.

Results Analyzing a total of 252 patients in 89% (group I, n = 225) ileostomy closure was performed. In 15% the radiologic report was the only diagnostic modality needed for therapy decision; in 36% the contrast enema and one or more other diagnostic methods were decisive. In 36% the radiological report of the contrast imaging was not relevant for deci-

sion at all. In 11% (group II, n = 27) no ileostomy closure was performed. In this group in 11% the radiological report of the contrast enema was the only decision factor for not performing the ileostomy reversal. In 26% one or more examination was necessary. In 26% the result of the contrast examination was not relevant.

Conclusion The radiologic contrast imaging of loop ileostomy solely plays a minor role in complex surgical decision-making before planned reversal, but is important as first imaging method in detecting complications and often leads to additional examinations.

Key points

- Contrast enema of loop ileostomy before planned ileostomy closure is a frequently performed examination.
- There exist no general guidelines that give further recommendations on decision-making planning ileostomy closure.
- The radiologic contrast imaging of loop ileostomy solely plays a minor role in decision-making before planned reversal, but is important as first imaging method.

Citation Format

- Goetz A, da Silva NP, Moser C et al. Clinical Value of Contrast Enema Prior to Ileostomy Closure. Fortschr Röntgenstr 2017; 189: 855–863

ZUSAMMENFASSUNG

Ziel Die radiologische Darstellung des abführenden Stomaschenkels im Monokontrast vor geplanter chirurgischer Rückverlagerung ist eine in der klinischen Routine häufig durchgeführte Untersuchung. In unserer Studie soll evaluiert werden, wie weit sie die klinische Entscheidungsfindung bezüglich einer Rückverlagerungsoperation beeinflusst.

Material und Methoden Retrospektive Analyse aller zwischen 2005 und 2011 durchgeführten Monokontrastuntersuchungen des abführenden Stomaschenkels an einem Universitätsklinikum. Dabei erfolgte die Unterteilung in Patienten, bei denen eine Rückverlagerung durchgeführt wurde (Gruppe I) oder nicht (Gruppe II). Beide Gruppen wurden bezüglich patientenbezogener (Grunderkrankung, Operationsmethode) sowie Parameter bezogen auf den radiologischen Befund (Stenose, Anastomoseninsuffizienz, Inkontinenz) analysiert und bezüglich der therapeutischen Konsequenz ausgewertet.

Ergebnisse Von den 252 untersuchten Patienten erfolgte bei 89 % (Gruppe I, n = 225) eine Rückverlagerungsoperation. Die Durchleuchtungsuntersuchung war dabei in 15 % als alleinige diagnostische Maßnahme zur Indikationsstellung ausreichend; in 36 % waren für die Entscheidung zur Rückverlagerung weitere Zusatzuntersuchungen notwendig. Bei 36 % war der radiologische Befund irrelevant für die Therapieentscheidung. Bei 11 % (Gruppe II, n = 27) erfolgte keine Rückverlagerung. Dabei war in 19 % der radiologische Befund allein ausschlaggebend für die Ablehnung der Rückverlagerung und

in 26 % war mindestens eine weitere Untersuchung nötig. In 26 % waren ausschließlich andere Untersuchungen entscheidend.

Schlussfolgerung Die radiologische Darstellung des abführenden Schenkels spielt als alleinige Untersuchung für die Entscheidung für oder gegen eine Stomarückverlagerung im chirurgischen Gesamtkonzept lediglich eine untergeordnete Rolle. Sie hat aber ihre Bedeutung als bildgebende Basisuntersuchung, welche bei unklaren Befunden weitere Diagnostik nach sich zieht.

Introduction

The display of the aboral segment of a double-barrelled ileostomy using a contrast enema is a conventional radiological examination carried out within the scope of the preoperative planned surgical ileostomy loop closure [1]. Here, on the one hand, the passage of the contrast medium applied via the aboral segment is tracked for the assessment of potential pathological changes such as intestinal stenosis or suture insufficiencies in the region of a loop ileostomy; on the other hand, a check is made of the continence of liquid contrast media with sphincter resting pressure and in the Valsalva maneuver. Although several studies have questioned the usefulness of a routine fluoroscopy examination of the aboral stoma, and postulate a limitation of the indication to specific issues [2–5], this examination is performed regularly in the clinical routine. Although guidelines on pathologies that often require an ileostomy, such as Crohn's disease or the treatment of colorectal carcinoma suggest ileostomy; however, there is no detailed recommendation regarding preoperative diagnostics prior to ileostomy closure in the guidelines. For example the S3 guideline "Diagnosis and therapy of Crohn's disease" only indicates that "in general, the desire to avoid a permanent stoma is more important than the risk of relapse" [6]; the guideline provides no exact indications or contraindications for reversal. Since, in the context of preoperative preparation for planned reversal, modern imaging methods, sonography, endoscopy and comprehensive clinical examination, including a digital rectal examination are performed, this retrospective study will evaluate the clinical value of a radiological examination of the loop ileostomy using monocontrast based on a large cohort of a large-scale university hospital. In particular the study will review the extent to which this method as the sole diagnostic measure actually influences the surgical procedure in the context of other examinations.

Materials and Methods

Patient Selection

A retrospective analysis was performed of all monocontrast studies carried out at a clinic of offering greatest extent of care (University Hospital Regensburg) between January 2005 and February 2011; the study focused on monocontrast to display the diverting loop of patients with an artificial anus. Compilation of the cohort

was based on the RIS (Radiological Information System; MEDOS 7.42; NEXUS/DIS GmbH Frankfurt/ Main, Germany) and included all patients who underwent a monocontrast examination during the above-mentioned time period. Monocontrast studies of non-double-barreled stomata and premature termination of the examination were excluded.

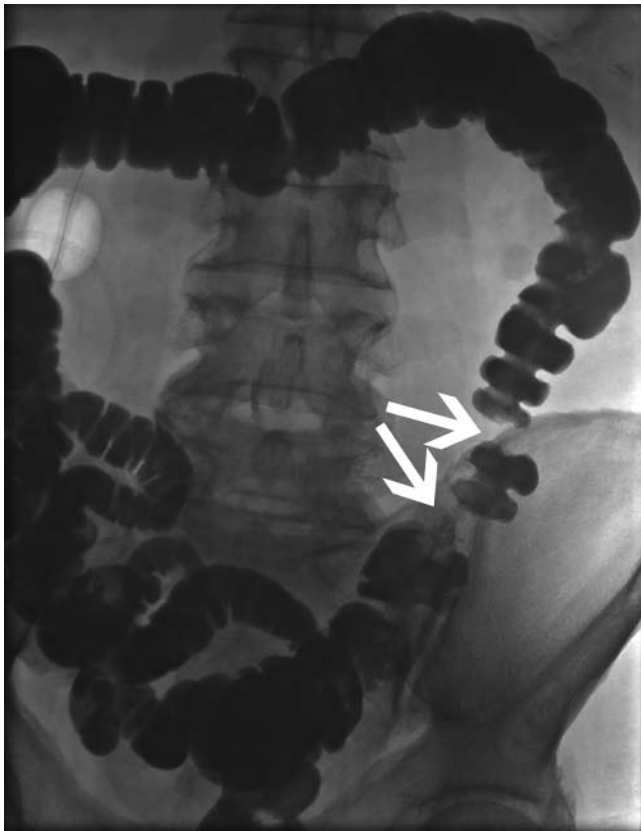
Examinations

From January 2005 to July 2007 all examinations were carried out on a Sireskop 5/45 type Polydoros 80S (Siemens AG, Erlangen, Germany). Until July 2007a Polystar unit (Siemens AG, Erlangen, Germany) was available on an interim basis. An AXIOM Artis dMP device (Siemens AG, Erlangen, Germany) with a flat detector system has been used since August 2007. Under-table devices were used for all examinations which were carried out by a physician with a radiological fellowship in conjunction with a specialist in radiology. A written radiological finding was prepared after the examination and documented in the RIS.

First, control images were acquired prior to administration of contrast. After probing the aboral segment of the ileostomy with a 14F bladder catheter, the application of 0.5 to 2 liters of a radiopaque iodine-based hyperosmolar contrast agent (Gastro-lux®RE, 180 mg / ml iodine-based solution, Sanochemia Diagnostics, Neuss, Germany). The contrast medium flow in the colon was shown under fluoroscopy and documented using conventional radiographs. Colon flexures and the sigma were freely projected in the usual technique (► Fig. 1). If a constriction was detected, after ruling out contraindications (cardiac arrhythmia, glaucoma, prostate hyperplasia for butylscopolamine or pheochromocytoma, hypersensitivity to glucagon or lactose), 40 mg of butylscopolamine or 1–2 mg glucagon was administered. ► Fig. 2 shows an example of a real stenosis also verified by computed tomography. Finally, continence behavior was examined by fluoroscopy using a Valsalva maneuver.

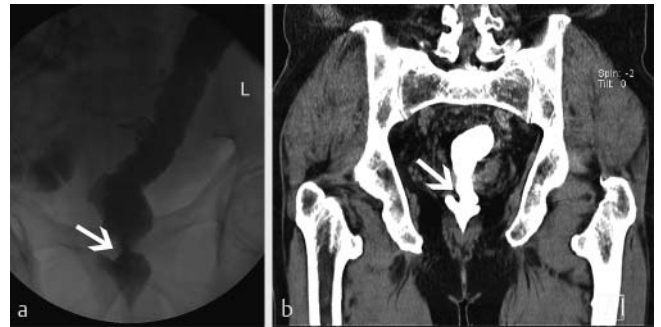
Data Collection

Approval of the ethics committee was obtained for the retrospective data analysis. The patients provided their written consent. Patient-related parameters were extracted from radiological findings in the RIS as well as the documents in the hospital information system. These included demographic data, primary diseases and related operations. In addition, parameters related to



► **Fig. 1** After the contrast application using the aboral segment of the ileostomy the complete colon is distended. The white arrows mark a true stenosis.

the radiological findings of the monocontrast study were recorded as technical data (dose area product, fluoroscopy time). The radiological findings documented in writing were examined with regard to the presence of constrictions in the examined intestinal section. Any intravenous spasmolysis as well as the evaluation of the constriction after spasmolysis were likewise documented. A constriction was considered functional if the drug spasmolysis led to distension. If the stenosis did not open under spasmolysis, the narrowing was evaluated as a real stenosis. In order to assess the therapeutic consequences of the radiological findings, an analysis was performed based on medical patient documentation in the hospital information system to determine whether reversal surgery could be foregone due to the stenosis, or whether further studies were needed to verify or rule out the stenosis. Rectal continence or incontinence was classified as follows: 0 – retained continence, 1 – limited to moderate incontinence, 2 – complete incontinence. Here as well, the existence of a therapeutic effect based on the documentation in the hospital information system was analyzed to determine whether reversal surgery was ruled out due to radiologically documented incontinence of fluid contrast agent. In addition, the presence of anastomotic leakage was reviewed and the consequences for further therapy analyzed. ► **Fig. 3** shows an example of anastomotic leakage verified by computed tomography. Adjunctive pathological changes, e. g. diverticula or fistulas were additionally documented in the find-



► **Fig. 2** a A true stenosis revealed in the monocontrast colonic examination. b Verification of this true stenosis by CT: the white arrow marks the stenosis in the same patient within the coronary reconstruction of the pelvis.

ings. The date of surgery and the time span between the fluoroscopic examination and reversal operation were documented. Finally, the individual indication or contraindication for the ileostomy reversal was recorded for each patient.

The acquired data were grouped qualitatively using a spreadsheet (Excel 2013, Microsoft, Redmond, WA, USA) and evaluated with descriptive statistics.

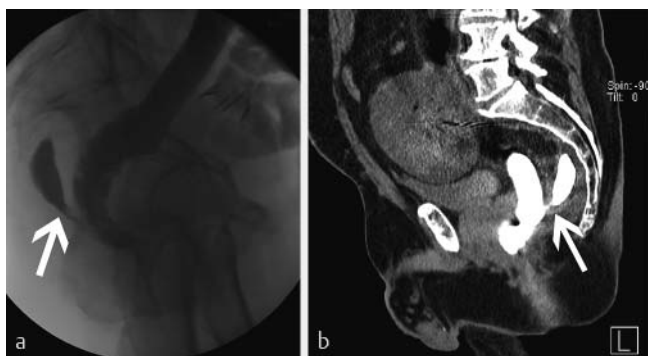
Results

Extraction of data from the RIS yielded a total of 364 patients and 413 examinations. Evaluation of physician reports in the hospital information system (SAP-R/ 3 IS-H/ i.s.h.med) resulted in the cohort exclusion of 84 colon examinations using a rectal contrast agent application, evidence of 40 Hartmann's stumps and ten end-stage colostomies as well as one evidence of fistula. The examination was terminated in four cases and consequently could not be included in the assessment. The reasons for this were a premature termination of the examination by the patient, incorrect intubation of the oral segment of the stoma, and the technical failure of probing as well as pronounced incontinence resulting in the end of the examination. This resulted in a final cohort with 252 patients and 274 examinations. The study group was divided into two subgroups for further evaluation based on physician's letters in the hospital information system: Group I with 225 (89%) patients and 244 examinations in which an artificial anus reversal was performed after images were acquired of the loop ileostomy, and Group II with 27 patients (11%) and 30 examinations without subsequent artificial anus reversal (► **Table 1**).

► **Fig. 4** presents an overview of the patient selection.

The patient population included 95 women (38%) and 157 men (62%) with a median age of 59.5 years (18–83 years). Analysis of the age distribution of the study cohort showed a gender-independent age peak in the seventh decade of life (n = 73, 29%, ► **Fig. 5**).

Analysis of the underlying diseases, leading to the initial operation with a double-barrelled ileostomy, demonstrated a broad spectrum of benign and malignant entities. As a number of primary diseases were present in some patients, the total number of underlying diseases exceeded that of the patients. Two patients



► **Fig. 3** Contrast enema in a lateral view **a** and a CT of the same patients (sagittal reconstruction) after a low anterior resection after rectum carcinoma. The white arrow marks a contrast depot representing a cavity after insufficiency of the anastomosis.

had, in addition to ulcerative colitis, colon cancer; one patient also had cervical cancer. In 184 patients (72%) there was malignant primary disease, most frequently rectal cancer ($n = 132$), followed by colon cancer ($n = 30$). ► **Table 2** contains a list of the individual malignant primary diseases. At the time of the examination, 71 patients had a benign primary disease (28%). The most common type of benign disease was chronic inflammatory disease ($n = 35$), namely ulcerative colitis in 26 patients and Crohn's disease in nine patients. The second most common benign disease was diverticulitis or diverticulosis of the sigmoid in nine patients, with seven patients having already experienced the complication of a perforation. The entire range of benign primary diseases is presented in ► **Table 3**.

Likewise, the type of surgery performed to treat the underlying disease requiring the ileostomy was analyzed (► **Fig. 6**). Rectal resection was the most frequent operation ($n = 140$), colorectal resections were performed in 35 patients, and 26 patients had undergone proctocolectomy. In 20 patients only a double-barrelled ileostomy was performed without organ resection. In this case the ileostomy was protective, for example in the case of multiple abscesses and fistulas, in the occurrence of an ileus, in the case of inadequate wound healing in the pelvis, prior to planned radiochemotherapy, because of unexplained GI hemorrhage with mucus lining ulceration.

An analysis of the type of anastomosis indicated a rectal anastomosis in 63% of cases ($n = 158$); 22% demonstrated colon anastomosis ($n = 56$), and there were multiple intestinal anastomoses in 7% of cases ($n = 18$). In 8% of patients ($n = 20$) no anastomosis was performed, the ileostomy was protective.

Evaluation of the technical data showed a median dose area product (DAP) of $2067 \mu\text{Gy} \times \text{m}^2$ (range $12.5 - 75\,637 \mu\text{Gy} \times \text{m}^2$) and a median fluoroscopy time of 234 seconds (range $1 - 1386$ s). The mean was $2994.7 \mu\text{Gy} \times \text{m}^2$. Using a conversion factor of $0.26 \text{ mSv} / \text{cGy} \times \text{cm}^2$ for gastrointestinal fluoroscopic examinations results in a mean value of 7.8 mSv (SD $\pm 13 \text{ mSv}$) for monocontrast images of the loop ileostomy with a median of 5.4 mSv [7].

Stenosis

In 74 of 274 examinations (27%), narrowing of the aboral stoma was documented before administration of a spasmolytic. 200 examinations (73%) were unremarkable with respect to the presence of stenosis. Intravenous spasmolysis was performed in 59 of the 74 examinations (80%) with documented stenosis. After spasmolysis, stenosis persisted in 20 of the 59 patients (34%) and was evaluated as a real stenosis. In 39 examinations (66%) no stenosis was visible after spasmolysis, so that the constriction was considered functional. In 15 examinations (20%) spasmolysis was ruled out due to contraindications. In these examinations, the constrictions were evaluated by the examiners as real in 13 cases (87%) and twice (13%) as functional stenosis. This resulted in a total of 241 findings (88%) without radiologically detectable constriction and 33 examinations (12%) with imaged stenosis.

A therapeutic effect was found in 15 of the 33 examinations with real stenosis. In 13 patients the ileostomy reversal was not initially performed. In two patients, resection of the stenosis in the region of the anastomosis in the course of ileostomy reversal. In the remaining 18 studies, the radiologically diagnosed stenosis had no therapeutic relevance to the surgical procedure.

Anastomotic Leakage

Suspicion of anastomotic leakage was described in 15 of 274 examinations. Computed tomography of the abdomen was additionally performed on all these patients. Leakage was confirmed in eight of the 15 patients. In the remaining seven patients, the findings of CT and proctoscopy were summarized postoperatively. Thus there were eight cases of anastomotic leakage and 266 examinations without evidence of leakage.

In seven of the eight positive findings (88%), the diagnosed anastomotic leakage had immediate therapeutic consequences: in six patients, closure of the existing stoma was dispensed with, and in another patient the double-barrelled ileostomy was converted into a terminal colostomy.

In one patient, the radiological suspicion of anastomotic leakage could not be confirmed in the proctoscopy so that closure of the ileostomy was performed.

Incontinence

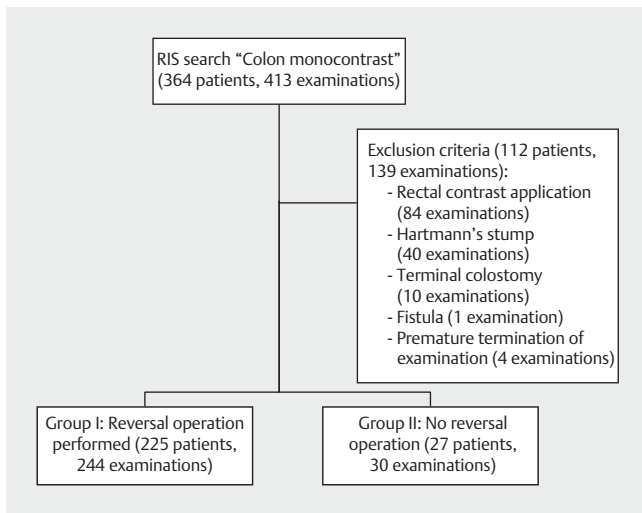
The analysis of 274 examinations with respect to rectal incontinence for liquid contrast agent revealed that continence was completely maintained in 194 examinations (71%). Incontinence was documented in 80 examinations (29%). A therapeutic consequence could be derived in seven examinations (9%); in these patients, closure was initially ruled out. In 73 studies (91%) the radiologically documented incontinence did not have any therapeutic consequences, and closure surgery was performed.

Secondary Findings

Diverticula were the most frequently documented secondary findings ($n = 54$). An intraluminal contrast media recess was described five times: the causes were air pockets ($n = 2$) or scybala ($n = 1$); in two patients the etiology could not be definitively explained even after a second review of the images. Fistulas were

► **Table 1** Patient cohort overview.

total patients	total cases	patient group	description of group	number of patients	number of cases
252	274	I	patients with artificial anus closure	225	244
		II	patients without artificial anus closure	27	30



► **Fig. 4** Flow chart of patients' selection and subgroup definition.

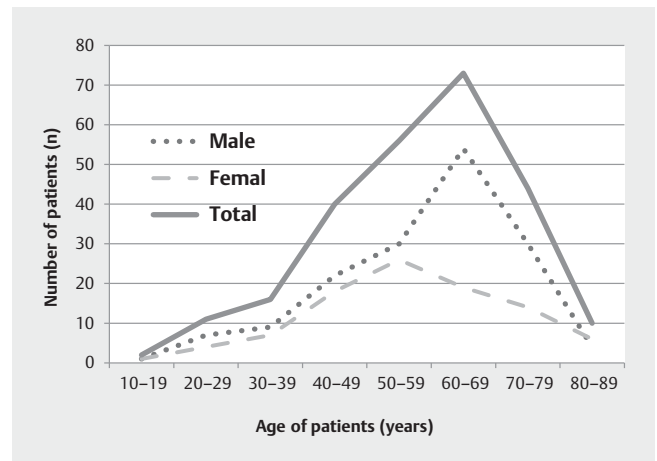
described in four examinations. Post-inflammatory changes were described for one patient. The documented secondary findings were not relevant to therapy in any case.

Further Therapy and Patient Progress

Closure surgery was performed in 225 patients of the cohort (89 %) after monocontrast imaging of the aboral stoma or later; these patients are summarized on Group I. In 27 patients (11 %), the stoma was not reversed; these patients were assigned to Group II.

The median time interval between the imaging of the loop ileostomy and the reversal operation was 4 days (range 0–332 days, mean value 18 days).

In the group of 225 patients with ileostomy closure (Group I), the indication for the reversing operation was based on radiographic fluoroscopic examination in 34 of the 225 patients (15 %). In 63 patients (28 %) the radiological findings and a further examination (e. g. manometry, proctological examination) led to a decision. In 16 patients (7 %) the indication for surgery was determined by colonic monocontrast and two to three additional examinations. In 20 patients (13 %) it was not possible to determine retrospectively which examinations were instrumental in establishing the indication for surgery. A reversal operation was performed in 92 patients (36 %), although the examination showed stenosis, leakage or incontinence; the radiological find-



► **Fig. 5** Age distribution of evaluated patients.

ings were not considered in the decision-making process. The results are shown in ► **Fig. 7**.

In the group without artificial anus closure (Group II), reversal surgery was not performed in five of 27 patients (19 %) due to radiological findings. In four patients (15 %) the radiological findings and a further examination contributed to a decision. For three patients (11 %), the decision to forgo reversal surgery was based on the findings of three examinations (rectoscopy, manometry and monocontrast). Findings of fluoroscopic examinations had no influence of the decisions made for seven patients (26 %). Based on written documentation, it was not possible to determine retrospectively which examinations influenced clinical decisions in the cases of eight patients (30 %).

Discussion

In our study, we analyzed 252 patients with protective ileostomy who between January 2005 and February 2011 were examined using contrast-enhanced fluoroscopic examinations of the aboral segment of the ileostomy. The aim of the study was to describe a typical patient collective in which this examination was performed at a full-service hospital, while evaluating the clinical relevance and value of this fluoroscopic examination prior to surgical reversal. In particular, the extent to which surgical decision-making is influenced by radiological findings should be evaluated.

There are already several studies which discuss the importance of conventional radiographic examination of the diverting

► **Table 2** Overview of malignant primary diseases.

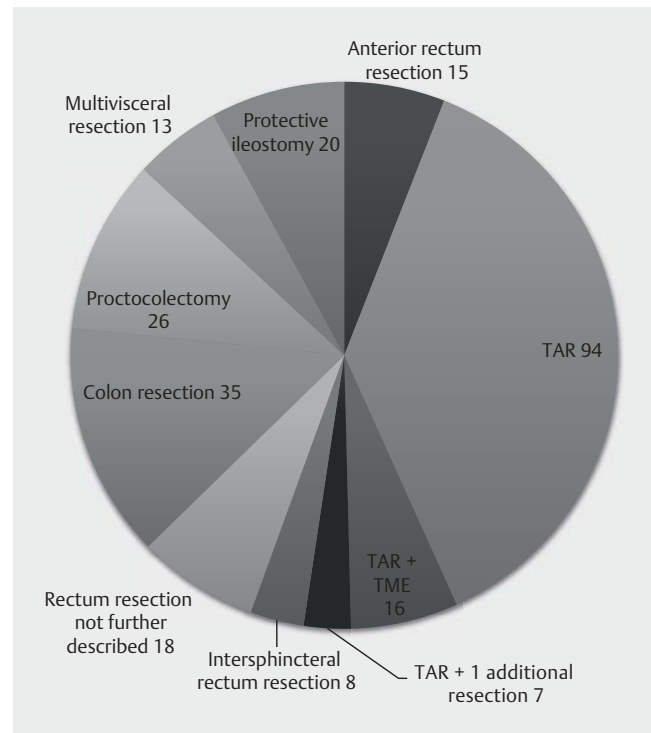

malignant primary disease	number of patients
rectal cancer	132
colon cancer	30
pseudomyxoma, mesothelioma	6
ovarian cancer	5
cancer of appendix	5
stomach cancer	2
pancreatic cancer	1
other	3

► **Table 3** Overview of benign primary diseases.

benign primary disease	number of patients
ulcerative colitis	26
Crohn's disease	9
diverticulosis(-itis)	9
adenoma	7
FAP	4
ileus	4
fistula, abscess	4
polytrauma	3
colon ischemia	2
other	3

segment or other intestinal sections using monocontrast as part of routine diagnosis compared to other examinations methods.

As early as 1990, Thoeni et al. [8] demonstrated that in the special case of the ileo-anal pouch, monocontrast-based fluoroscopic examination did not offer any clear advantage compared to computed tomography and scintigraphy in the detection of postoperative complications. In a group of 57 patients with an ileo-anal pouch, the investigators showed that fluoroscopic examination did not lead to diagnostic gains with respect to complications such as pouchitis, abscess, or fistula formation. Hong et al. in 2012 [3] reported similar results in an investigation of 145 patients with protective ileostomy performed after deep anterior resection whose anastomosis was examined clinically, endoscopically and using contrast enema. It was found that the fluoroscopic examination in patients with colorectal or colo-anal anastomosis did not provide any additional information in preoperative diagnosis compared to clinical examination and proctoscopy. The investigators did not consider monocontrast imaging of the aboral stoma as a routine necessity, especially since the radiological findings of the pouchogram of the three patients of the group who developed postoperative complications were unremarkable in all cases. Da Silva et al. [2] evaluated the fluoroscopy of 84 pa-

► **Fig. 6** Overview of applied surgical techniques for ileostomy.► **Fig. 7** Decision making for further procedures within group 1.

tients with a colon pouch and protective ileostomy prior to planned closure surgery. They found a low sensitivity in the prediction of postoperative complications. This sensitivity was 0% for anastomotic leakage, 33% for stenosis and 50% for predicting fistula formation. The course of therapy was influenced in only one case. An 2007 additional study by Khair et al. [5]. showed a similar result. They retrospectively evaluated the data of 81 patients with deep anterior rectal resection and placement of an ileostomy prior to planned closure surgery. A preoperative monocontrast examination was performed on 69 of the 81 patients. Their results also show that routine imaging of the aboral segment or anastomosis using monocontrast plays a subordinate role in the absence of clinical suspicion of leakage. In their study Cowan et al. [9] eval-

uated the data of patients with anterior rectal resection and ileostomy without postoperative complications and colo-anal/rectal anastomosis accessible to a clinical examination; fluoroscopy was performed on only 35 of 59 patients. An operation to close the ileostomy was planned for all patients. The investigators concluded that contrast imaging prior to a reversal operation is not necessary in cases of complication-free progress and a deep anastomosis allowing accessible clinical examination. In a group of 211 patients, Kalady et al. [3] demonstrated that contrast-enhanced imaging of deep anastomoses before ileostomy closure surgery was often used for confirmation in clinical suspicion of leakage, but the study did not detect any anastomotic leakage that had not already been clinically suspected. Thus the examination did not provide any diagnostic benefit to planning therapy for the patient. Lawal et al. [10] investigated the utility of routinely performed ileostomy imaging prior to closure in a cohort of 26 children and adolescents. They also found no diagnostic gain in comparison to clinical examination or after consideration of the individual medical history and postulated that fluoroscopic examination of ileostomies should be restricted to patients with suspected leakage, especially since children should be subjected to as limited radiation exposure as possible. Only Hrungrung et al. in their study published in 1997 [11] demonstrated a good detection rate of leakage not previously detected clinically. They retrospectively evaluated 59 contrast studies of 40 patients after proctocolectomy and placement of an ileoanal pouch and an ileostomy. Routine postoperative contrast imaging of the stoma was performed in 37 patients. Three clinically unsuspected anastomotic leakages were detected.

To our knowledge, the present study is the first attempt to evaluate the direct impact of study results on clinical decision-making regarding planned reversal surgery. This issue was examined using a large retrospective study cohort. Thus, not only patients with colon or rectal resections were included, but also patients in which a protective ileostomy was performed without intestinal resection such as after trauma or to protect an irradiation region.

The decision for or against ileostomy closure was reviewed. Of 225 patients who had surgery to close the ileostomy, fluoroscopic examination was decisive in the decision for 34 of them (15%). In 80 patients (36%) the radiological findings and at least one further examination (e. g. manometry, proctological examination) led to a decision. The examination was irrelevant for 92 patients (41%); the reversal operation was performed even though the examination yielded findings such as anastomotic leakage, stenosis or leakage of liquid contrast. Although the monocontrast examination was the sole basis for decision-making in only 15% of the examinations, it was a contributing factor in a total of 50% of cases and not taken into account in 41%. It is not possible to retrospectively evaluate the significance of the fluoroscopic examination when several other examination modalities contributed to decision-making.

In patient Group II (in whom reversal surgery was not performed), the radiological findings, together with at least one additional examination were decisive with respect to seven patients (26%). The findings had no influence of the decisions made for seven patients (26%). In summary, it can be noted that the radio-

logical findings of the fluoroscopic examination was significant for the decision not to perform stoma closure in 35% of patients, and had no impact in 26% of cases.

The result of the fluoroscopic examination played a subordinate role with respect to radiologically detected incontinence, since this leakage had therapeutic consequences in only 9% of examinations. Here the patient's desire appears to be crucial for decision-making, especially if the patient is compliant and can improve the continence function through Kegel exercises, for example. Stadelmaier et al. [12] also showed that there was no significant correlation between postoperative continence and continence for liquid contrast media in a monocontrast study of a cohort that had undergone ileostomy reversal after rectal carcinoma. Likewise regarding these results, the authors of this study, when describing a radiologically-detected anastomotic leak, ascribe a rather subordinate role to the examination in the evaluation of the clinical decision-making.

Fluoroscopic examination of the loop of the ileostomy appears to be significant primarily in the case of anastomotic leakage. In 15 examinations there was suspicion of anastomotic leakage which in all cases was confirmed by computed tomography. A comparison of the two radiological examinations showed suspicion of anastomotic leakage in eight cases (53%); the remaining findings showed postoperative changes. However in all eight of the cases, the findings were consequential. In 7 patients closure surgery was not performed. A proctoscopy performed on one patient could not confirm the finding, and the surgery was performed.

Stenosis detected in the fluoroscopic examination exhibited a therapeutic consequence in 45% of cases, and none in 55%. These results neither proved nor disproved the importance of radiological examination. In summary, the results of the monocontrast examination of the diverting segment of the ileostomy is important in the context of routine clinical diagnostics, possibly because of rapid and universal availability as an initial exploratory method to determine any contraindications would result in further diagnosis in the case of indistinct findings and additional examinations to clarify special issues.

In addition, radiation exposure for both patient and examiner in the course of monocontrast examination is a factor to be considered. An effective dose of an average of 7.8 mSv in our cohort is only slightly lower than, for example, computer tomography of the abdomen and pelvis, which taking into account the DLP values specified by the Federal Office for Radiation Protection [13] and a conversion factor of approx. 0.015 according to Deak et al. [14] is at about 10 mSv. Hirofuji et al. [15] evaluated the dosage of fluoroscopic examinations of the lower GI tract. They found an effective dose of 10.7 mSv for an analog fluoroscopic examination, and about 9.4 mSv using a digital system. These values were not exceeded in our study.

Its retrospective design was a limitation of our study. There were numerous documentation discrepancies between the different electronic patient documentation systems (RIS and PACS) as well as documentation gaps, the cause of which could not be determined retrospectively. Nevertheless, we consider the evaluation of 252 consecutive patients over a more than 5-year observation period as sufficiently representative in order to be able to

adequately classify the significance of this radiological fluoroscopic examination clinically.

Conclusions

The evaluation of the clinical therapeutic consequences of radiological imaging of the loop ileostomy using monocontrast at a full-service hospital demonstrated that a single conventional radiological examination of this segment does not generally appear to have a direct influence on decision-making regarding ileostomy reversal, and in many instances supplementary examinations are called for. However in the course of routine diagnosis it is useful as an initial exploratory method to ascertain any contraindications which would result in further diagnosis in the case of indistinct findings and additional examinations to clarify special issues.

CLINICAL RELEVANCE OF THE STUDY

- Frequently used as an exploratory procedure in the course routine diagnosis.
- Generally few therapeutic consequences of fluoroscopic examination
- Application with respect to special clinical issues, particularly anastomotic leakage.

Conflict of Interest

The authors declare that they have no conflict of interest.

References

- [1] Dimitriou N, Panteleimonitis S, Dhillon A et al. Is the routine use of a water-soluble contrast enema prior to closure of a loop ileostomy necessary? A review of a single institution experience. *World J Surg Oncol* 2015; 13: 331
- [2] da Silva GM, Wexner SD, Gurland B et al. Is routine pouchogram prior to ileostomy closure in colonic J-pouch really necessary? *Colorectal disease: the official journal of the Association of Coloproctology of Great Britain and Ireland* 2004; 6: 117–120
- [3] Hong SY, Kim do Y, Oh SY et al. Routine barium enema prior to closure of defunctioning ileostomy is not necessary. *Journal of the Korean Surgical Society* 2012; 83: 88–91
- [4] Kalady MF, Mantyh CR, Petrofski J et al. Routine contrast imaging of low pelvic anastomosis prior to closure of defunctioning ileostomy: is it necessary? *Journal of gastrointestinal surgery: official journal of the Society for Surgery of the Alimentary Tract* 2008; 12: 1227–1231
- [5] Khair G, Alhamarneh O, Avery J et al. Routine use of gastrograffin enema prior to the reversal of a loop ileostomy. *Digestive surgery* 2007; 24: 338–341
- [6] Hoffmann JC, Zeitz M. Standard therapy of Crohn disease. Consensus-based recommendations. *Der Internist* 2002; 43: 1379–1385
- [7] Hart D, Wall BF. UK population dose from medical X-ray examinations. *Eur J Radiol* 2004; 50: 285–291
- [8] Thoeni RF, Fell SC, Engelstad B et al. Ileoanal pouches: comparison of CT, scintigraphy, and contrast enemas for diagnosing postsurgical complications. *Am J Roentgenol American journal of roentgenology* 1990; 154: 73–78
- [9] Cowan T, Hill AG. Ileostomy closure without contrast study is safe in selected patients. *ANZ journal of surgery* 2005; 75: 218–219
- [10] Lawal TA, Falcone RA, von Allmen D et al. The utility of routine pouchogram before ileostomy reversal in children and adolescents following ileal pouch anal anastomosis. *Journal of pediatric surgery* 2011; 46: 1222–1225
- [11] Hrung JM, Levine MS, Rombeau JL et al. Total proctocolectomy and ileoanal pouch: the role of contrast studies for evaluating postoperative leaks. *Abdominal imaging* 1998; 23: 375–379
- [12] Stadelmaier U, Bittorf R, Meyer M et al. Can continence function after rectal resection be prognostically estimated? *Chirurg* 2000; 71: 932–938
- [13] Bundesamt für Strahlenschutz. Diagnostische Referenzwerte für CT-Untersuchungen an Erwachsenen. Juli. 2015
- [14] Deak PD, Smal Y, Kalender WA. Multisection CT protocols: sex- and age-specific conversion factors used to determine effective dose from dose-length product. *Radiology* 2010; 257: 158–166
- [15] Hirofuji Y, Aoyama T, Koyama S et al. Evaluation of patient dose for barium enemas and CT colonography in Japan. *Br J Radiol* 2009; 82: 219–227

