

Preservation of Fertility or Ovarian Function in Patients with Breast Cancer or Gynecologic and Internal Malignancies

Erhalt der Fertilität bzw. Ovarialfunktion beim Mammakarzinom sowie bei gynäkologischen und internistischen Malignomen

Authors

Angrit Stachs, Steffi Hartmann, Bernd Gerber

Affiliation

Universitätsfrauenklinik Rostock, Rostock, Germany

Key words

breast cancer, premature ovarian failure, chemotherapy, gynecologic malignancies, irradiation, infertility

Schlüsselwörter

Fertilitätserhalt, Mammakarzinom, chemotherapieinduzierte Amenorrhö, vorzeitige Ovarialinsuffizienz, gynäkologische Malignome

received 26.5.2017

revised 8.7.2017

accepted 9.7.2017


Bibliography

DOI <https://doi.org/10.1055/s-0043-116222>

Geburtsh Frauenheilk 2017; 77: 861–869 © Georg Thieme Verlag KG Stuttgart · New York | ISSN 0016-5751

Correspondence

Dr. Angrit Stachs
Universitätsfrauenklinik Rostock
Südring 81, 18059 Rostock, Germany
angrit.stachs@uni-rostock.de

 Deutsche Version unter:
<https://doi.org/10.1055/s-0043-116222>

ABSTRACT

Because of the efficacy of systemic therapies, neoplasias which occur in pediatric and adolescent patients and in young adults have high cure rates. This means that fulfilling their wish to have children has become a more pressing concern, particularly among young women with malignant tumors. Premature ovarian failure is also a not insignificant problem as it has a lasting detrimental effect on quality of life. Every oncology patient who may potentially wish to have children should be informed about their options for preserving fertility prior to starting treatment. The rates of patient who received detailed briefing on this point remain low. This review

presents the effects of different chemotherapeutic drugs on gonadal function together with an overview of currently valid recommendations on fertility preservation. Risk groups are defined and the specific approaches for malignancies of various organ systems are described. Cryopreservation of oocytes, fertilized embryos and ovarian tissue are fertility-preserving options for girls/young women. The data on the benefits of administering GnRH analogs for ovarian protection prior to starting chemotherapy are not clear. In postpubertal boys or male cancer patients, the standard approach is to cryopreserve sperm before starting therapy. The cryopreservation of testicular tissue is possible for prepubertal boys, however in-vitro sperm maturation is still in its experimental stages. This review also presents existing drug options for the preservation of ovarian function in oncology patients prior to chemotherapy, particularly for patients with (hormone-sensitive) breast cancer, and looks at the special issues of fertility-preserving surgery and radiation therapy in patients with gynecologic malignancies.

ZUSAMMENFASSUNG

Neoplasien des Kindes- und Jugendalters sowie junger Erwachsener gehen heute dank effektiver Systemtherapien mit einer hohen Heilungschance einher. Demzufolge rückt das Thema „Kinderwunsch“ insbesondere bei jungen Frauen mit Malignom zunehmend in den Vordergrund. Ein nicht unwesentliches Problem ist auch die vorzeitige Ovarialinsuffizienz mit ihren die Lebensqualität nachhaltig beeinträchtigenden Folgen. Jede(r) onkologische Patient(in) mit potenziellem Kinderwunsch sollte vor Therapiebeginn über die Möglichkeiten des Fertilitätserhaltes informiert werden. Die Aufklärungsrate ist diesbezüglich nach wie vor gering. In dieser Übersichtsarbeit wird der Effekt verschiedener Chemotherapeutika auf die Gonadenfunktion dargestellt sowie ein Überblick über die aktuell gültigen Empfehlungen zum Fertilitätserhalt gegeben. Dabei werden Risikokollektive definiert und das spezifische Vorgehen bei Malignomen der verschiedenen Organsysteme beschrieben. Bei Mädchen/jungen Frauen ist die Kryokonservierung von Eizellen, befruchteten Embryonen und Ovargewebe möglich. Zum Nutzen der GnRH-Analoga-Applikation zum Ovarschutz vor Chemotherapie ist die Studienlage uneinheitlich. Bei postpubertären Jungen bzw. männlichen Krebs-

patienten ist die Kryokonservierung von Spermien vor Therapiebeginn Standard. Bei Jungen im vorpubertären Alter ist die Kryokonservierung von Hodengewebe möglich, jedoch ist die In-vitro-Spermienreifung noch im experimentellen Stadium. Des Weiteren werden in der vorliegenden Arbeit medikamentöse Möglichkeiten des Erhaltes der Ovarfunktion bei onkolo-

gischen Patienten vor Chemotherapien, insbesondere bei (hormonabhängigem) Mammakarzinom sowie die speziellen Fragestellungen der Planung von fertilitätserhaltender Operation und Radiatio bei gynäkologischen Malignomen dargestellt.

Introduction

Cure rates for oncologic disease in children, teenagers and premenopausal patients have improved significantly in recent years with the increasing administration of chemotherapy. With many women postponing having a family until later in life and because of the long-term consequences of premature ovarian failure there is now a legitimate interest in maintaining ovarian function, irrespective of the type of tumor. It is important to differentiate between maintaining ovarian function (hormone production) and preserving fertility (the opportunity to have children). Affected women with premature ovarian failure can suffer from concomitant subjective symptoms (hot flushes, attacks of sweating, sleep disturbance, loss of libido, etc.) and objective symptoms (osteoporosis, cardiovascular events, genital atrophy, drop in mental performance, cognitive dysfunction, mental instability, vaginal atrophy, dyspareunia, loss of vitality, etc.), which can irreversibly impair their quality of life over the long term [1, 2].

Histologically verifiable changes to the ovary following chemotherapy range from a lower number of follicles to their complete absence and fibrosis.

According to the WHO definition, the absence of menstruation for more than one year is defined as amenorrhea or menopause. Synonyms for ovarian insufficiency include chemotherapy-induced amenorrhea (CIA), premature ovarian failure (POF) and amenorrhea. The following methods can be used to preserve fertility: drug-induced ovarian suppression prior to oncologic systemic therapy, cryopreservation of oocytes and ovarian tissue, or the surgical relocation of the ovaries out of the radiation field prior to the planned radiation of the pelvis. Depending on the stage of disease, an organ-preserving approach may be possible during surgery of the gynecologic malignancy in patients who may wish to have children. This review focuses on the importance of a carefully differentiated approach, according to the affected organ and stage of disease. All premenopausal women, particularly very young women and women without children should be informed as early as possible about the options of preserving fertility and ovarian function. Associated networks of oncology centers and centers of reproductive medicine such as the Fertiprotekt network in Germany (<http://fertiprotekt.com>) can offer additional counselling and advice.

Prevalence and Risk Factors

The prevalence of permanent gonadal injury (infertility) for various therapy regimens is [3–6]:

- High (> 80%) for:
 - pelvic radiotherapy (dose per ovary > 10 Gy, dose per testis > 4 Gy)
 - whole body irradiation [7]
 - high-dose chemotherapy with stem cell transplants and cyclophosphamide/busulfan
 - CMF, FEC, FAC (6 cycles respectively in women aged > 40 years)
- Intermediate for:
 - CMF, FEC, FAC (6 cycles respectively in women aged 30–39 years)
 - AC, EC (4 cycles respectively in women aged > 40 years)
 - taxane-based combinations
- Low (< 20%) for:
 - ABVD (doxorubicin, bleomycin, vinblastine, dacarbazine)
 - CHOP (cyclophosphamide, doxorubicin, vincristine, prednisolone)
 - treatment for acute myeloid leukemia
 - treatment for acute lymphocytic leukemia
 - CMF, FEC, FAC (6 cycles respectively in women aged < 30 years)
 - AC, EC (4 cycles respectively in women aged < 40 years)
- Unknown/doubtful for:
 - taxane, vincristine, MTX, 5-FU, oxaliplatin, irinotecan, capecitabine

The therapy reported to have the highest cure rate in the guidelines should always be used, irrespective of the potential ovarian damage. It is important to avoid any relevant delay of oncologic therapy, even if the delay is for fertility-preserving measures [8].

Preservation of Ovarian Function in Patients with Breast Cancer

Around 25% of all cases of breast cancer develop in premenopausal patients and 12% of cases are women under the age of 40 years [18, 19].

Does ovarian function recover?

Estrogens play a very important role in the tumorigenesis of breast cancer. Conversely, the suppression of hormone production (= ovarian function suppression, OFS) is therapeutically very effective to treat hormone-sensitive tumors [1]. For hormone receptor-positive women with high-risk breast cancer, chemother-

► **Table 1** Randomized clinical studies on the use of GnRHa to protect ovarian function during chemotherapy.

Author	Patients (n)	Mean age (years)	Hormone receptor-positive (%)	% POF* GnRH/no GnRH	Pregnancies (n)
Badawy [42]	78	30	Not specified	10/67 p < 0.001	Not specified
Sverrisdottir [43]	285	45	45	64/90 p = 0.006	Not specified
Del Mastro [44]	281	39	81	9/26 p < 0.001	3/1
Gerber [45]	60	37	0	30/43 n.s.	1/1
Munster [46]	49	39	73	12/10 n.s.	1/1
Elgindy [47]	100	33	0	24/48 n.s.	2/1
Moore [38]	218	38	0 (≤ 10%)	8/22 p = 0.02	22/12

* POF = premature ovarian failure

apy with additional OFS can significantly improve breast cancer-specific survival by 5–10% [20, 21]. Studies have shown that disease-free 10-year survival rates (78.4 vs. 67%, p = 0.022) and overall survival (90.8 vs. 79.7%, p = 0.041) were significantly higher for women who had CIA compared to women without CIA [22]. The existing data indicate that amenorrhea (CIA, GnRH therapy) after chemotherapy improves prognosis. At present it is not clear how long the amenorrhea should be maintained.

Depending on the patient's age and the administered cytostatic drugs and their dosages, CIA occurs after administration of the standard chemotherapy combinations currently in use in 50–60% of cases; CIA can be reversible or irreversible [5]. For patients aged < 35, 35–40 and > 40 years the CIA rate was 26% (95% CI: 12–43%), 39% (95% CI: 31–58%) and 77% (95% CI: 71–83%), respectively [23]. Older age (> 40 years) and tamoxifen intake have been confirmed as independent risk factors for CIA.

There are no concerns about the return of menstruation in women with hormone receptor-negative tumors.

Are there parameters which predict chemotherapy-induced amenorrhea (CIA)?

Generally speaking, the younger the patient, the lower the risk of CIA. Although the data are not conclusive, predicting the risk of CIA is possible using anti-Mullerian hormone (AMH), inhibin and follicle-stimulating hormone (FSH) [24–27]. Determining the number of follicles and their size can be helpful but is subjective [28]. AMH, number of follicles and levels of other hormones are strongly age-dependent.

Anthracycline-taxane-based chemotherapy regimens are currently the standard therapy. Although taxane-based regimens tend to have somewhat higher amenorrhea rates, their CIA rates do not differ significantly from those for FAC/FEC regimens [29, 30]. In all studies age was the decisive predictor for the occurrence of CIA. Recently, genetic polymorphisms have been discussed as possible causes for CIA [31–33]. According to the study by Reimer et al. published in 2016, women with a heterozygote variant of the drug metabolism enzyme SLCO1B1*5 had significantly lower CIA rates.

Before starting chemotherapy the indications for chemotherapy must be critically assessed using multigene assays, where necessary [34–36]. Endocrine therapy alone may be sufficient.

GnRH analogs for functional protection of the ovary during chemotherapy?

It is still not clear how cytostatic drugs exert their harmful effect on the ovaries. As follicular development from primordial follicle to small preantral follicle is independent of GnRH, the cytotoxic effect on proliferating cells should only play a subordinate role. While the Ataya hypothesis assumes that the primary harmful effect is exerted on the proliferating granulosa cells, the Meiwow hypothesis postulates that alkylating substances primarily destroy the dormant pregranulosa cells and the oocytes surrounding them through the induction of apoptosis [37].

Several randomized studies have investigated the effect of chemotherapy on ovarian function with and without GnRH analogs (► **Table 1**). Four studies reported a benefit from the administration of GnRHa on the CIA rate, while three studies found no benefit. The biggest study (POEMS [38]) reported an inexplicable but significant improvement in the disease-free survival of hormone receptor-negative patients and in overall survival following the additional administration of GnRHa. Because of bias during follow-up (only 135 of 218 patients), the unclear definition of hormone receptors, and the different effects of chemotherapy, this study must be viewed critically [39]. ► **Table 1** additionally shows that the overall pregnancy rate was very low.

Recent meta-analyses came to the conclusion that the administration of GnRHa can be recommended for premenopausal patients for whom chemotherapy is indicated and who wish to preserve ovarian function [40, 41]. The additional administration of GnRHa resulted in a significantly higher rate of menstruation recovery after 6 (OR: 2.41; 95% CI: 1.40–4.15; p = 0.002) and 12 months (OR: 1.85; 95% CI: 1.33–2.59; p = 0.0003) and a higher pregnancy rate (OR: 1.85; 95% CI: 1.02–3.36; p = 0.04) [2].

Other options for fertility preservation

Advances in reproductive medicine (ART) have led to a change in thinking about fertility preservation prior to chemotherapy. At present, cryopreservation of fertilized oocytes and mature oocytes is a well-established procedure, while the cryopreservation of immature oocytes is still considered to be in its experimental stages [48, 49]. Cryopreservation of ovarian tissue is another procedure for preserving fertility [17, 50]. All ART procedures cost

more than € 2000, and health insurance companies usually do not fund the procedures.

Cryopreservation of embryos or pronuclear fertilized oocytes (2PN) has the highest success rates in terms of healthy live births [51]. But this requires the woman to have a partner.

For women without a partner, the options are cryopreserving mature oocytes or ovarian tissue. Follicular stimulation with gonadotropins can be done at the same time as administering tamoxifen or an aromatase inhibitor (letrozole). The time to follicle puncture from the start of stimulation treatment in the luteal phase with recombinant FSH and the simultaneous administration of GnRH antagonists has decreased to a maximum of 14 days. This period is considered oncologically acceptable. By using GnRH agonists to induce ovulation prior to egg collection (“agonist trigger”) it is usually possible to avoid ovarian hyperstimulation (OHSS). The administration of a GnRH depot preparation on the day of egg collection quickly achieves the desired ovarian insufficiency required for chemotherapy.

Vitrification is currently the standard method to cryopreserve unfertilized oocytes, as it achieves very high survival rates even though the spindle apparatus is vulnerable to ice crystal formation. The formerly used slow freezing protocol is no longer used because of the low cryo survival rates of approximately 30% of unfertilized oocytes. Although survival rates of >85% have been achieved for 2PN and embryos after slow freezing, this method is also being replaced by vitrification.

The laparoscopic extraction of ovarian tissue (up to and including an entire ovary) and the subsequent cryopreservation of this tissue is becoming increasingly important. To date, more than 86 successful term pregnancies following the transplantation of previously cryopreserved ovarian tissue have been reported worldwide [49, 52, 53]. Slow freezing of ovarian tissue appears to offer superior results compared to vitrification. After chemotherapy has been completed, the ovarian cortex chips are transplanted either orthotopically into perforations in the (contralateral) ovary, subperitoneally into the pelvic wall or heterotopically, e.g. into subcutaneous fat tissue [54]. The short duration between the procedure and the start of therapy is an advantage. The encouraging results reported by different working groups show that cryopreservation of ovarian tissue with subsequent transplantation is well on the way to becoming an established procedure for fertility preservation. Associated problems include the risk of tumor cell dissemination, e.g. in patients with leukemia, and the retransplantation of ovarian tissue in women with BRCA 1/2 mutations [8, 55, 56].

Preservation of Ovarian Function in Patients with Cervical, Ovarian and Uterine Tumors

Ovarian tumors

In unilateral borderline tumors of the ovary (BTO) and even in very early ovarian cancer (EOC, FIGO I) fertility-preserving surgery can be an option after adequate staging (rinse cytology, omentectomy, appendectomy and, where necessary, peritoneal sampling) [55, 57–60]. An unremarkable uterus and unremarkable contra-

lateral ovary are the preconditions for organ-sparing procedures. Ovarian biopsy is only recommended for macroscopic anomalies. However, cohort studies for both pathologies have reported an increased risk of recurrence after fertility preservation.

After treatment of BTO and a median follow-up of 88 months (range: 14–205) studies report invasive recurrence in 16% of cases, with recurrence developing after a median of 22 months (range: 3–74) [61]. Independent prognostic factors for recurrence include invasive implants, FIGO Ic, G3 and young patient age. Currently the risk of recurrence is reported to be 12–29%, depending on FIGO stage, inclusion criteria, systemic therapy and follow-up, and the reported pregnancy rates are 30% [60, 62, 63]. But no difference with regard to survival was found between patients with FIGO stage 1 disease who had fertility-preserving surgery and patients with FIGO stage 1 disease who underwent radical surgery [63, 64]. In two thirds of cases, recurrence after fertility preservation developed at extraovarian sites and was usually lethal. Patients therefore need to be informed in detail about their individual risk of recurrence.

80% of germ cell tumors (malignant müllerian mixed tumor, MMMT) are diagnosed in women under the age of 30 years, and 70–75% of these tumors are stage 1. A conservative approach is appropriate in most cases and has a good prognosis [65]. The risk of recurrence reported in the literature ranges from 9.8 to 27.4% [66].

It is not clear whether there are differences in the risk of recurrence between carriers of BRCA 1/2 gene mutations and non-mutation carriers. In Scandinavia, cryopreservation with retransplantation of ovarian tissue instead of fertility-preserving surgery is already considered “safe” [50, 67].

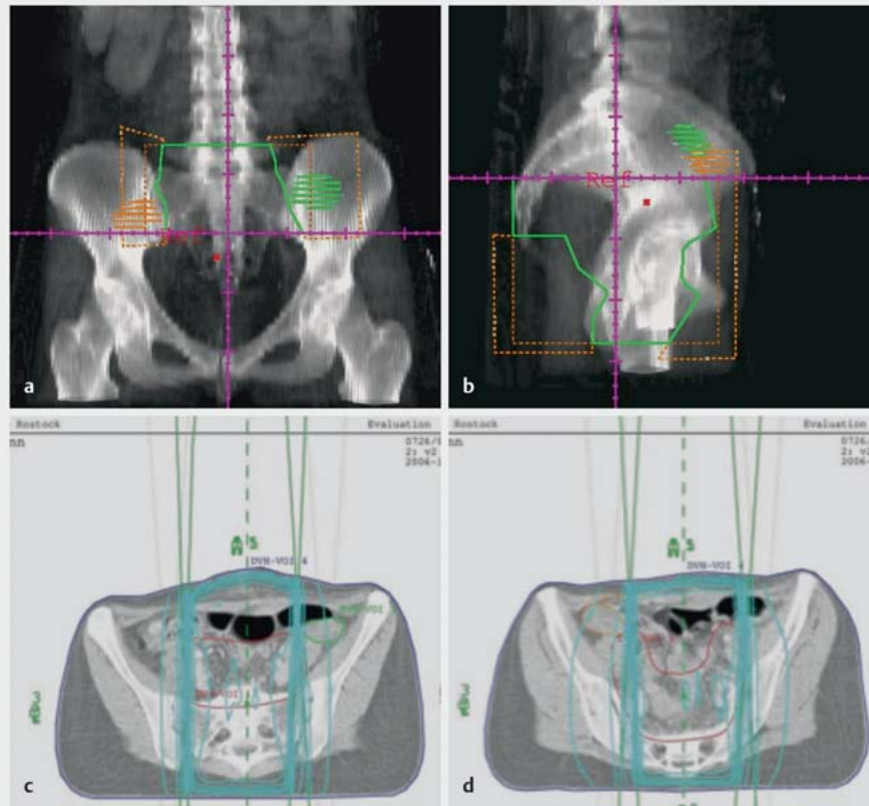
At present there are no confirmed data on a possible connection between ovulation induction and recurrence. Rates of spontaneous pregnancies of between 33–100% have been reported after fertility-sparing adnexal-preserving surgery [68].

Definitive removal of the adnexa with or without hysterectomy can be always be carried out for “safety reasons” after patients have completed their reproductive planning. However, it is currently not clear whether this improves overall survival.

Cervical cancer

Early detection and appropriate treatment of cervical dysplasias is the best way to preserve fertility. As described in the S3 guideline “Cervical Cancer”, conization is sufficient to treat patients with stage IA cervical cancer (synonym: early stromal invasion, microcarcinoma) with up to one risk factor (L1, V1, G3) who wish to preserve their fertility (in patients with L1, conization may be supplemented by laparoscopic pelvic lymphadenectomy).

A number of different techniques for fertility preservation are currently used. Radical vaginal trachelectomy (RVT) as described by Dargent – a combination of laparoscopic lymphadenectomy and vaginal resection of the cervix together with the proximal part of the vagina and the parametrium/paracolpium – is used to treat patients with FIGO stage IB1 cervical carcinoma (tumor size ≤ 4.0 cm) who wish to preserve their fertility [69]. A German multicenter study with 100 patients reported a recurrence-free survival of 90% after a median follow-up of 29 months for patients with early cervical cancer (≤ 2 cm) [70]. The results for 379 pa-



► **Fig. 1** Radiotherapy planning for a 29-year-old patient with cervical cancer for whom radio-chemotherapy was indicated. CT of the abdomen in the (a) frontal plane and (b) sagittal plane shows the new location of the ovaries outside the lesser pelvis. c, d Ovaries outside the irradiated area, inside the 10% isodoses (images were kindly provided by Prof. Dr. G. Hildebrandt, Director of the Department of Radiation Therapy of Rostock Medical University).

tients presented by 6 working groups showed a 4% rate of pelvic recurrence [71, 72]. Recent meta-analyses on RVT confirm the reported recurrence and mortality rates of 5 and 2%, respectively (tumor size ≤ 2 cm) and 11 and 4%, respectively (tumor size > 2 cm) [73–75]. In patients with adenocarcinoma, the risk of recurrence is 13% and mortality is also higher compared to mortality rates for squamous cell carcinoma [76].

Radical trachelectomy can also be carried out using an abdominal approach (RAT) [77].

As tumor size (≤ 2 cm vs. > 2 cm), lymph node involvement and lymphatic invasion are the most significant factors which affect the decision for or against a fertility-sparing approach, the first step should consist of pelvic and paraaortal lymphadenectomy [78].

Early closure of the cervical os is recommended to prevent very early premature births, which have a reported incidence of up to 50% after RVT/RAT [79]. However, a high percentage of infertile women ($> 15\%$) has been reported because of cervical stenosis following trachelectomy [80].

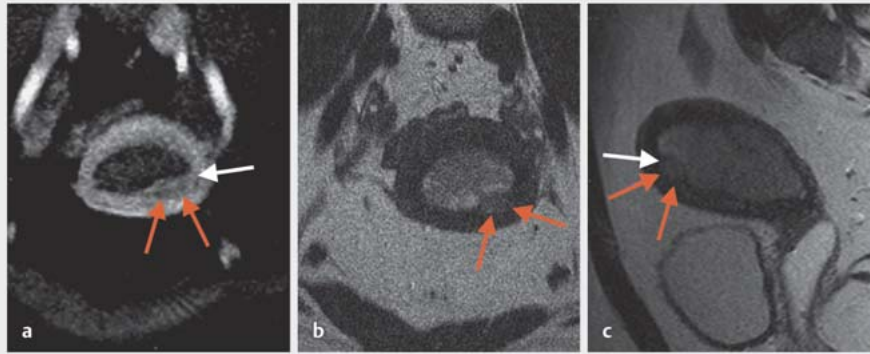
Laparoscopic lymphadenectomy followed by neoadjuvant (radio-)chemotherapy with administration of GnRH analogs for ovarian protection and subsequent conization is a less well established fertility-preserving option for women with cervical cancer. This

option can be expanded by the additional cryopreservation of ovarian tissue or oocytes [73].

The ovaries can be preserved in patients with advanced disease requiring radical surgery. If the ovaries are retained, they should be marked with metal clips, moved cranially and fixed outside the lesser pelvis ► **Fig. 1**. This will protect them if radiochemotherapy is indicated. The risk of ovarian failure increases significantly when the radiation dose is higher than 10 Gy. More than 70% of patients who received radiation doses of more than 20 Gy developed ovarian failure [81]. There is insufficient data on the benefits of administering GnRH for ovarian protection, and GnRH administration is therefore not an established procedure.

Uterine cancer

The option of organ preservation is rare for histologically confirmed complex hyperplasia (CHP) or early endometrial cancer (EEMC). In most cases, the patients are obese. Progestational therapy (e.g. 400–600 mg/d medroxyprogesterone acetate or 160 mg/d megestrol acetate for 3–6 months) may be indicated in young premenopausal patients with CHP/well differentiated EEMC and no infiltration of the myometrium. The remission rates are reported to be comparable for levonorgestrel-containing IUDs but the weight gain is significantly lower [82]. The remission rates



► **Fig. 2** MRI in a 27-year-old patient with a well differentiated endometrioid adenocarcinoma and infiltration of the myometrium. After histologic confirmation of the diagnosis following hysteroscopy and fractionated curettage, preoperative staging was done with MRI to assess the possibility of preserving the uterus.

for progestational therapy are high with reported rates of 81% and a remission duration of 6 months, but recurrence occurs in up to 50% of cases [83]. Because of these high rates of recurrence, women wishing to have children should have children as soon as possible after pathological remission (hysteroscopy and curettage). In addition, they should optimize lifestyle factors (diet, control of diabetes, weight loss). MRI (► **Fig. 2**) can be useful in addition to ultrasound to determine the extent of myometrium infiltration by EMC.

Hysteroscopic resection of EMC together with the underlying myometrium and adjacent endometrium followed by 6 months of progestational therapy resulted in complete pathological regression in 89% of cases. There were two (8%) cases of recurrence, and the median duration of response was 95 (8–175) months. 87% of the women who wanted to have children gave birth to healthy children [84]. These data are encouraging but are not yet the standard.

Retention of Ovarian Function in Children, Adolescents, and Young Adults (CAYAs) with Oncologic Disease

CAYAs treated with chemotherapy for lymphoma, leukemia, myeloma, Wilms tumor, sarcoma, etc. have a higher risk (RR: 1.48 [95% CI: 1.23–1.78]; $p < 0.0001$) of infertility once they reach the age of fertility and are more likely to be treated for sterility compared to persons who did not have chemotherapy [10]. Pelvic irradiation, therapy with alkylating agents, and high-dose chemotherapy were particularly strong predictors of infertility [11]. It is difficult to make proper recommendations for fertility preservation. A comparison of 25 different recommendations for fertility preservation in CAYAs showed a wide range of sometimes divergent recommendations, which suggests a lack of evidence [12, 13]. The current recommendations are cryopreservation of ovarian tissue and oocytes, depending on patient age and the planned type of chemotherapy [14–17].

Fertility-preserving Measures in Male Cancer Patients

Before starting therapy, cryopreservation of sperm is possible in postpubertal adolescents aged 13 and above, who are Tanner stage ≥ 3 and have a testis volume of 10 ml or above. Sperm cells can be obtained by ejaculation, electrostimulation or microsurgical testicular sperm extraction (TESE). Cryopreservation of mature testicular tissue is also possible although, because of the potential for testicular metastasis, this is associated with a risk of retransplanting malignant cells [9].

After completing therapy, the extraction of vital sperm from patients with persisting azoospermia with TESE has been reported to be successful in up to 50% of patients. However, patients should wait at least 2 years after completing treatment to see whether spermatogenesis recovers, unless they have additional pathologies such as hypogonadism or ejaculation disorders. Hormone replacement therapy with testosterone is indicated in patients with hypogonadism [6].

Summary

With the significant improvement in cure rates for oncologic disease in children, teenagers and young adults, preserving fertility and gonadal function has become a central aspect of therapy planning.

Developments in reproductive medicine which can preserve fertility in postpubertal women and men with oncologic disease include the cryopreservation of oocytes and sperm and the cryopreservation of ovarian tissue (even from prepubertal girls) and testicular tissue. The highest pregnancy rates are achieved by the cryopreservation of embryos, but this assumes that the patient has a partner.

For premenopausal patients with hormone receptor-positive breast cancer, (temporary) chemotherapy-induced amenorrhea is associated with an improved prognosis. Depending on patient age, CIA is reversible; the administration of a GnRHa prior to start-

ing chemotherapy is recommended if the patient wishes to retain ovarian function [40, 41].

Women of reproductive age with a primary diagnosis of cervical cancer, endometrial cancer or ovarian cancer who wish to have children can opt for a fertility-sparing surgical approach, depending on their cancer stage.

All patients should be informed about the consequences for reproduction before they start therapy and be informed about the options of preserving their fertility, e.g. through the Fertiprotekt network.

Conflict of Interest

The authors declare that they have no conflict of interest.

References

- [1] Park WC. Role of ovarian function suppression in premenopausal women with early breast cancer. *J Breast Cancer* 2016; 19: 341–348
- [2] Munhoz RR, Pereira AA, Sasse AD et al. Gonadotropin-releasing hormone agonists for ovarian function preservation in premenopausal women undergoing chemotherapy for early-stage breast cancer: a systematic review and meta-analysis. *JAMA Oncol* 2016; 2: 65–73
- [3] Petrek JA, Naughton MJ, Case LD et al. Incidence, time course, and determinants of menstrual bleeding after breast cancer treatment: a prospective study. *J Clin Oncol* 2006; 24: 1045–1051
- [4] Müller H. [Effects of adjuvant chemotherapy of breast cancer on gonadal function]. *Zentralbl Gynakol* 1990; 112: 795–801
- [5] Overbeek A, van den Berg MH, van Leeuwen FE et al. Chemotherapy-related late adverse effects on ovarian function in female survivors of childhood and young adult cancer: a systematic review. *Cancer Treat Rev* 2016; 53: 10–24
- [6] Borgmann-Staudt ABN, Jantke A, Hinz S. AWMF S1-Leitlinie (025/034) Beeinträchtigung der Gonadenfunktion nach Krebs im Kindes- und Jugendalter: Risiken, Diagnostik, Prophylaxe- und Behandlungsmöglichkeiten. AWMF-Register Nr. 025-034. 2015. Online, last access: 03.05.2017
- [7] Wallace WH, Anderson RA, Irvine DS. Fertility preservation for young patients with cancer: who is at risk and what can be offered? *Lancet Oncol* 2005; 6: 209–218
- [8] Revelli A, Salvagno F, Delle Piane L et al. Fertility preservation in BRCA mutation carriers. *Minerva Ginecol* 2016; 68: 587–601
- [9] Nielsen CT, Skakkebaek NE, Richardson DW et al. Onset of the release of spermatozoa (spermarche) in boys in relation to age, testicular growth, pubic hair, and height. *J Clin Endocrinol Metab* 1986; 62: 532–535
- [10] Barton SE, Najita JS, Ginsburg ES et al. Infertility, infertility treatment, and achievement of pregnancy in female survivors of childhood cancer: a report from the Childhood Cancer Survivor Study cohort. *Lancet Oncol* 2013; 14: 873–881
- [11] Metzger ML, Meacham LR, Patterson B et al. Female reproductive health after childhood, adolescent, and young adult cancers: guidelines for the assessment and management of female reproductive complications. *J Clin Oncol* 2013; 31: 1239–1247
- [12] Sklar CA, Mertens AC, Mitby P et al. Premature menopause in survivors of childhood cancer: a report from the childhood cancer survivor study. *J Natl Cancer Inst* 2006; 98: 890–896
- [13] Font-Gonzalez A, Mulder RL, Loeffen EA et al. Fertility preservation in children, adolescents, and young adults with cancer: quality of clinical practice guidelines and variations in recommendations. *Cancer* 2016; 122: 2216–2223
- [14] Filippi F, Meazza C, Paffoni A et al. Egg freezing in childhood and young adult cancer survivors. *Pediatrics* 2016. doi:10.1542/peds.2016-0291
- [15] Long CJ, Ginsberg JP, Kolon TF. Fertility preservation in children and adolescents with cancer. *Urology* 2016; 91: 190–196
- [16] Salama M, Isachenko V, Isachenko E et al. Updates in preserving reproductive potential of prepubertal girls with cancer: systematic review. *Crit Rev Oncol Hematol* 2016; 103: 10–21
- [17] Jensen AK, Rechnitzer C, Macklon KT et al. Cryopreservation of ovarian tissue for fertility preservation in a large cohort of young girls: focus on pubertal development. *Hum Reprod* 2017; 32: 154–164
- [18] Trivers KF, Fink AK, Partridge AH et al. Estimates of young breast cancer survivors at risk for infertility in the U.S. *Oncologist* 2014; 19: 814–822
- [19] Robert Koch-Institut. Evaluation of cancer incidence in Germany (2007–2010). 2012. Online, last access: 03.05.2017
- [20] Regan MM, Francis PA, Pagani O et al. Absolute benefit of adjuvant endocrine therapies for premenopausal women with hormone receptor-positive, human epidermal growth factor receptor 2-negative early breast cancer: TEXT and SOFT trials. *J Clin Oncol* 2016; 34: 2221–2231
- [21] Mathew A, Davidson NE. Adjuvant endocrine therapy for premenopausal women with hormone-responsive breast cancer. *Breast* 2015; 24 (Suppl. 2): S120–S125
- [22] Jung M, Shin HJ, Rha SY et al. The clinical outcome of chemotherapy-induced amenorrhea in premenopausal young patients with breast cancer with long-term follow-up. *Ann Surg Oncol* 2010; 17: 3259–3268
- [23] Zavos A, Valachis A. Risk of chemotherapy-induced amenorrhea in patients with breast cancer: a systematic review and meta-analysis. *Acta Oncol* 2016; 55: 664–670
- [24] Chai J, Howie AF, Cameron DA et al. A highly-sensitive anti-Mullerian hormone assay improves analysis of ovarian function following chemotherapy for early breast cancer. *Eur J Cancer* 2014; 50: 2367–2374
- [25] Bozza C, Puglisi F, Lambertini M et al. Anti-Mullerian hormone: determination of ovarian reserve in early breast cancer patients. *Endocr Relat Cancer* 2014; 21: R51–R65
- [26] Henry NL, Xia R, Schott AF et al. Prediction of postchemotherapy ovarian function using markers of ovarian reserve. *Oncologist* 2014; 19: 68–74
- [27] Anderson RA, Rosendahl M, Kelsey TW et al. Pretreatment anti-Mullerian hormone predicts for loss of ovarian function after chemotherapy for early breast cancer. *Eur J Cancer* 2013; 49: 3404–3411
- [28] Khairy M, Clough A, El-Toukhy T et al. Antral follicle count at down-regulation and prediction of poor ovarian response. *Reprod Biomed Online* 2008; 17: 508–514
- [29] Okanami Y, Ito Y, Watanabe C et al. Incidence of chemotherapy-induced amenorrhea in premenopausal patients with breast cancer following adjuvant anthracycline and taxane. *Breast Cancer* 2011; 18: 182–188
- [30] Pourali L, Taghizadeh Kermani A, Ghavamnasiri MR et al. Incidence of chemotherapy-induced amenorrhea after adjuvant chemotherapy with taxane and anthracyclines in young patients with breast cancer. *Iran J Cancer Prev* 2013; 6: 147–150
- [31] Chapman C, Cree L, Shelling AN. The genetics of premature ovarian failure: current perspectives. *Int J Womens Health* 2015; 7: 799–810
- [32] Reimer T, Kempert S, Gerber B et al. SLC01B1*5 polymorphism (rs4149056) is associated with chemotherapy-induced amenorrhea in premenopausal women with breast cancer: a prospective cohort study. *BMC Cancer* 2016; 16: 337
- [33] Stearns V, Schneider B, Henry NL et al. Breast cancer treatment and ovarian failure: risk factors and emerging genetic determinants. *Nat Rev Cancer* 2006; 6: 886–893
- [34] Cardoso F, van't Veer LJ, Bogaerts J et al. 70-gene signature as an aid to treatment decisions in early-stage breast cancer. *N Engl J Med* 2016; 375: 717–729

- [35] Nitz U, Gluz O, Christgen M et al. Reducing chemotherapy use in clinically high-risk, genomically low-risk pN0 and pN1 early breast cancer patients: five-year data from the prospective, randomised phase 3 West German Study Group (WSG) PlanB trial. *Breast Cancer Res Treat* 2017. doi:10.1007/s10549-017-4358-6
- [36] Duffy MJ, Harbeck N, Nap M et al. Clinical use of biomarkers in breast cancer: updated guidelines from the European Group on Tumor Markers (EGTM). *Eur J Cancer* 2017; 75: 284–298
- [37] Morgan S, Anderson RA, Gourley C et al. How do chemotherapeutic agents damage the ovary? *Hum Reprod Update* 2012; 18: 525–535
- [38] Moore HC, Unger JM, Phillips KA et al. Goserelin for ovarian protection during breast-cancer adjuvant chemotherapy. *N Engl J Med* 2015; 372: 923–932
- [39] Gerber B, Ortman O. Prevention of Early Menopause Study (POEMS): is it possible to preserve ovarian function by gonadotropin releasing hormone analogs (GnRHa)? *Arch Gynecol Obstet* 2014; 290: 1051–1053
- [40] Lambertini M, Ceppi M, Poggio F et al. Ovarian suppression using luteinizing hormone-releasing hormone agonists during chemotherapy to preserve ovarian function and fertility of breast cancer patients: a meta-analysis of randomized studies. *Ann Oncol* 2015; 26: 2408–2419
- [41] Lambertini M, Cinquini M, Moschetti I et al. Temporary ovarian suppression during chemotherapy to preserve ovarian function and fertility in breast cancer patients: A GRADE approach for evidence evaluation and recommendations by the Italian Association of Medical Oncology. *Eur J Cancer* 2017; 71: 25–33
- [42] Badawy A, Elnashar A, El Ashry M et al. Gonadotropin-releasing hormone agonists for prevention of chemotherapy-induced ovarian damage: prospective randomized study. *Fertil Steril* 2009; 91: 694–697
- [43] Sverrisdottir A, Nystedt M, Johansson H et al. Adjuvant goserelin and ovarian preservation in chemotherapy treated patients with early breast cancer: results from a randomized trial. *Breast Cancer Res Treat* 2009; 117: 561–567
- [44] Del Mastro L, Boni L, Michelotti A et al. Effect of the gonadotropin-releasing hormone analogue triptorelin on the occurrence of chemotherapy-induced early menopause in premenopausal women with breast cancer: a randomized trial. *JAMA* 2011; 306: 269–276
- [45] Gerber B, von Minckwitz G, Stehle H et al. Effect of luteinizing hormone-releasing hormone agonist on ovarian function after modern adjuvant breast cancer chemotherapy: the GBG 37 ZORO study. *J Clin Oncol* 2011; 29: 2334–2341
- [46] Munster PN, Moore AP, Ismail-Khan R et al. Randomized trial using gonadotropin-releasing hormone agonist triptorelin for the preservation of ovarian function during (neo)adjuvant chemotherapy for breast cancer. *J Clin Oncol* 2012; 30: 533–538
- [47] Elgindy EA, El Haieg DO, Khorshid OM et al. Gonadotrophin suppression to prevent chemotherapy-induced ovarian damage: a randomized controlled trial. *Obstet Gynecol* 2013; 121: 78–86
- [48] Ronn R, Holzer H. Breast cancer and fertility: an update. *Curr Opin Support Palliat Care* 2015; 9: 285–293
- [49] Loren AW, Mangu PB, Beck LN et al. Fertility preservation for patients with cancer: American Society of Clinical Oncology clinical practice guideline update. *J Clin Oncol* 2013; 31: 2500–2510
- [50] Rodriguez-Wallberg KA, Tanbo T, Tinkanen H et al. Ovarian tissue cryopreservation and transplantation among alternatives for fertility preservation in the Nordic countries – compilation of 20 years of multicenter experience. *Acta Obstet Gynecol Scand* 2016; 95: 1015–1026
- [51] Shapira M, Raanani H, Meirou D. IVF for fertility preservation in breast cancer patients—efficacy and safety issues. *J Assist Reprod Genet* 2015; 32: 1171–1178
- [52] Van der Ven H, Liebenthron J, Beckmann M et al. Ninety-five orthotopic transplantations in 74 women of ovarian tissue after cytotoxic treatment in a fertility preservation network: tissue activity, pregnancy and delivery rates. *Hum Reprod* 2016; 31: 2031–2041
- [53] Beckmann MW, Dittrich R, Lotz L et al. Operative techniques and complications of extraction and transplantation of ovarian tissue: the Erlangen experience. *Arch Gynecol Obstet* 2017; 295: 1033–1039
- [54] Beckmann MW, Dittrich R, Findeklee S et al. Surgical aspects of ovarian tissue removal and ovarian tissue transplantation for fertility preservation. *Geburtsh Frauenheilk* 2016; 76: 1057–1064
- [55] Findeklee S, Lotz L, Heusinger K et al. Fertility protection in female oncology patients: how should patients be counseled? *Geburtsh Frauenheilk* 2015; 75: 1243–1249
- [56] Rosendahl M, Andersen MT, Ralfkiaer E et al. Evidence of residual disease in cryopreserved ovarian cortex from female patients with leukemia. *Fertil Steril* 2010; 94: 2186–2190
- [57] du Bois A, Trillsch F, Mahner S et al. Management of borderline ovarian tumors. *Ann Oncol* 2016; 27 (Suppl. 1): i20–i22
- [58] Gershenson DM. Management of borderline ovarian tumours. *Best Pract Res Clin Obstet Gynaecol* 2016. doi:10.1016/j.bpobgyn.2016.09.012
- [59] Karlsen NM, Karlsen MA, Hogdall E et al. Relapse and disease specific survival in 1143 Danish women diagnosed with borderline ovarian tumours (BOT). *Gynecol Oncol* 2016; 142: 50–53
- [60] Zapardiel I, Diestro MD, Aletti G. Conservative treatment of early stage ovarian cancer: oncological and fertility outcomes. *Eur J Surg Oncol* 2014; 40: 387–393
- [61] Demirkiran F, Sal V, Bese T et al. Risk factors for recurrence of borderline ovarian tumours: a tertiary centre experience. *J Obstet Gynaecol* 2016; 36: 1036–1040
- [62] Bentivegna E, Fruscio R, Roussin S et al. Long-term follow-up of patients with an isolated ovarian recurrence after conservative treatment of epithelial ovarian cancer: review of the results of an international multicenter study comprising 545 patients. *Fertil Steril* 2015; 104: 1319–1324
- [63] Park JY, Suh DS, Kim JH et al. Outcomes of fertility-sparing surgery among young women with FIGO stage I clear cell carcinoma of the ovary. *Int J Gynaecol Obstet* 2016; 134: 49–52
- [64] Ghezzi F, Cromi A, Fanfani F et al. Laparoscopic fertility-sparing surgery for early ovarian epithelial cancer: a multi-institutional experience. *Gynecol Oncol* 2016; 141: 461–465
- [65] Parkinson CA, Hatcher HM, Ajithkumar TV. Management of malignant ovarian germ cell tumors. *Obstet Gynecol Surv* 2011; 66: 507–514
- [66] Iavazzo C, Gkegkes ID, Vrachnis N. Fertility sparing management and pregnancy in patients with granulosa cell tumour of the ovaries. *J Obstet Gynaecol* 2015; 35: 331–335
- [67] Zapardiel I, Cruz M, Diestro MD et al. Assisted reproductive techniques after fertility-sparing treatments in gynaecological cancers. *Hum Reprod Update* 2016. doi:10.1093/humupd/dmv066
- [68] Lian C, Chen X, Ni Y et al. Pregnancy after fertility-sparing surgery for borderline ovarian tumors. *Int J Gynaecol Obstet* 2016; 134: 282–285
- [69] Dargent D, Martin X, Sacchetoni A et al. Laparoscopic vaginal radical trachelectomy: a treatment to preserve the fertility of cervical carcinoma patients. *Cancer* 2000; 88: 1877–1882
- [70] Hertel H, Kohler C, Grund D et al. Radical vaginal trachelectomy (RVT) combined with laparoscopic pelvic lymphadenectomy: prospective multicenter study of 100 patients with early cervical cancer. *Gynecol Oncol* 2006; 103: 506–511
- [71] Shepherd JH, Spencer C, Herod J et al. Radical vaginal trachelectomy as a fertility-sparing procedure in women with early-stage cervical cancer—cumulative pregnancy rate in a series of 123 women. *BJOG* 2006; 113: 719–724
- [72] Hoeckel M. Die Post-Wertheim-Emanzipation und -Evolution der operativen Therapie des Zervixkarzinoms. *Geburtsh Frauenheilk* 2006; 66: 729–733
- [73] Willows K, Lennox G, Covens A. Fertility-sparing management in cervical cancer: balancing oncologic outcomes with reproductive success. *Gynecol Oncol Res Pract* 2016; 3: 9

- [74] Hauerberg L, Hogdall C, Loft A et al. Vaginal radical trachelectomy for early stage cervical cancer. Results of the Danish National Single Center Strategy. *Gynecol Oncol* 2015; 138: 304–310
- [75] Pareja R, Rendon GJ, Sanz-Lomana CM et al. Surgical, oncological, and obstetrical outcomes after abdominal radical trachelectomy – a systematic literature review. *Gynecol Oncol* 2013; 131: 77–82
- [76] Zusterzeel PL, Pol FJ, van Ham M et al. Vaginal radical trachelectomy for early-stage cervical cancer: increased recurrence risk for adenocarcinoma. *Int J Gynecol Cancer* 2016; 26: 1293–1299
- [77] Reimer T, Stachs A, Günzl N et al. Die radikale abdominale Trachelektomie: Zwei Kasuistiken zum fertilitätserhaltenden Vorgehen beim frühinvasiven Zervixkarzinom. *Geburtsh Frauenheilk* 2009; 69: 240–243
- [78] Bentivegna E, Gouy S, Maulard A et al. Oncological outcomes after fertility-sparing surgery for cervical cancer: a systematic review. *Lancet Oncol* 2016; 17: e240–e253
- [79] Mangler M, Lanowska M, Bartens A et al. Closure of the cervical os in patients after fertility preserving treatment for early cervical cancer – results of a prospective observational study. *J Perinat Med* 2016. doi:10.1515/jpm-2016-0231
- [80] Boss EA, van Golde RJ, Beerendonk CC et al. Pregnancy after radical trachelectomy: a real option? *Gynecol Oncol* 2005; 99: S152–S156
- [81] Chemaitilly W, Mertens AC, Mitby P et al. Acute ovarian failure in the childhood cancer survivor study. *J Clin Endocrinol Metab* 2006; 91: 1723–1728
- [82] Cholakian D, Hacker K, Fader AN et al. Effect of oral versus intrauterine progestins on weight in women undergoing fertility preserving therapy for complex atypical hyperplasia or endometrial cancer. *Gynecol Oncol* 2016; 140: 234–238
- [83] Wang CJ, Chao A, Yang LY et al. Fertility-preserving treatment in young women with endometrial adenocarcinoma: a long-term cohort study. *Int J Gynecol Cancer* 2014; 24: 718–728
- [84] Falcone F, Laurelli G, Losito S et al. Fertility preserving treatment with hysteroscopic resection followed by progestin therapy in young women with early endometrial cancer. *J Gynecol Oncol* 2017; 28: e2