



Antibiotic Protocols for Endophthalmitis Prophylaxis Following Open-Globe Repair: A Survey of U.S. Residency Programs

David Fell, MD¹ Preston H. Blomquist, MD¹ 

¹Department of Ophthalmology, The University of Texas Southwestern Medical Center, Dallas, Texas

J Acad Ophthalmol 2023;15:e86–e90.

Address for correspondence Preston H. Blomquist, MD, Department of Ophthalmology, University of Texas Southwestern Medical Center, 5323 Harry Hines Blvd, Dallas, TX 75390-9057 (e-mail: preston.blomquist@utsouthwestern.edu).

Abstract

Purpose To assess the various approaches to endophthalmitis prevention following traumatic open-globe injury (OGI) repair.

Methods A research electronic data capture (REDCap) questionnaire evaluating the usage of antibiotics and steroids in patients with OGI was distributed to program directors of all U.S. ophthalmology residency programs using the Association of University Professors of Ophthalmology program directors' listserv. Completed questionnaires were analyzed for treatment patterns.

Results The REDCap questionnaire was distributed to 111 programs, with 32 residency programs responding. Two responses were excluded. Ninety percent (27/30) of included programs used perioperative intravenous (IV) antibiotics, with 78% (21/27) of those giving one dose only. At the time of surgery, 27% (8/30) of programs gave intravitreal antibiotics and 60% (18/30) gave subconjunctival antibiotics. Postoperatively, 100% (30/30) gave topical antibiotics and 97% (29/30) gave topical steroids. Only 53% of responders discharged patients on oral antibiotics. Of the three programs who did not use IV antibiotics, all three gave intravitreal therapy and one also discharged patients on oral antibiotics.

Conclusion There is a large variation in practice patterns for endophthalmitis prophylaxis among residency programs. Further investigation is needed to compare rates of endophthalmitis between these protocols and establish a safe and minimally burdensome standard of care.

Keywords

- ▶ endophthalmitis
- ▶ antibiotic prophylaxis
- ▶ open-globe injury

Traumatic open-globe injuries (OGIs) are a common cause of severe vision loss in the United States.¹ Among these patients, bacterial endophthalmitis following surgical repair remains a potential complication that can significantly worsen visual outcomes. Perioperative and postoperative antibiotics are routinely given to limit this risk and, in doing so, optimize postoperative vision.^{2,3} There are several risk factors that

complicate OGI and increase the risk of postoperative endophthalmitis, including delayed time to repair, retained intraocular foreign bodies (IOFB), and lens capsule rupture.⁴ Several retrospective studies have examined different antibiotic regimens that have maintained variable rates of postoperative endophthalmitis in patients with OGI, with more recent studies demonstrating very low rates of endophthalmitis

received
August 24, 2022
accepted after revision
March 1, 2023

DOI <https://doi.org/10.1055/s-0043-1768024>.
ISSN 2475-4757.

© 2023. The Author(s).

This is an open access article published by Thieme under the terms of the Creative Commons Attribution-NonDerivative-NonCommercial-License, permitting copying and reproduction so long as the original work is given appropriate credit. Contents may not be used for commercial purposes, or adapted, remixed, transformed or built upon. (<https://creativecommons.org/licenses/by-nc-nd/4.0/>)

Thieme Medical Publishers, Inc., 333 Seventh Avenue, 18th Floor, New York, NY 10001, USA

with 48 hours of broad-spectrum antibiotics.⁵⁻⁷ Studies from outside of the United States have demonstrated similar rates of postoperative endophthalmitis when comparing systemic intravenous (IV) and oral antibiotic regimens.^{8,9}

In the United States, many OGI are repaired and followed at hospitals with level 1 trauma centers and ophthalmology training programs. Despite extensive literature on the epidemiology of OGI and posttraumatic endophthalmitis, there continues to be scant data on postrepair antibiotic protocols and their associated endophthalmitis rates. Because of this, there is currently no standard protocol for antibiotic management in these patients, leaving each individual residency program to choose its own regimens based on anecdotes, physician experience, and the limited published data that exist.

The purpose of this study is to gather survey data across ophthalmology residencies in the United States regarding the specific protocols that they employ to maintain low rates of endophthalmitis in uncomplicated OGI. This is the first study to compare the variation among protocols in these academic hospitals, with the goal of developing a safe and effective standard of care that limits the burden placed on these hospitals and the patients for whom they care.

Methods

An online questionnaire was developed using research electronic data capture (REDCap) software and distributed in September 2021 to 111 ophthalmology residency programs using the listserv of residency program directors of the Association of University Professors of Ophthalmology (AUPO).¹⁰ The study adhered to the tenets of the Declaration of Helsinki,¹¹ and approval was obtained from The University of Texas Southwestern Medical Center Institutional Review Board. A second request was sent via listserv of residency program directors in December 2021 as a reminder. Finally, the survey with the link to the questionnaire was listed in the AUPO May 2022 Program Directors Council Update, sent to residency program directors via email, as a currently open AUPO facilitated survey. Responses were not anonymous. The programs were surveyed about their preferred/primary treatment regimen for OGI in adults without an IOFB. Responses were then evaluated based on protocols for primary endophthalmitis prophylaxis (perioperative IV, intraoperative intravitreal, postoperative oral antibiotics) and secondary prophylaxis (intraoperative subconjunctival, postoperative topical antibiotics), as well as use of adjunctive steroids.

Results

Survey responses were received from representatives of 32 ophthalmology programs (response rate = 28.8%). One response was excluded as it pertained mainly to a protocol in pediatric patients. Another response was excluded because it described multiple protocols for different approaches without clear explanation for which patients received each protocol. Overall, 30 responses from as many U.S. programs were included for analysis. Twenty-seven of responding programs

(90%) were level 1 trauma centers. The average number of OGI repairs done across programs was 60.6 annually.

Primary Endophthalmitis Prophylaxis

Perioperative Intravenous Antibiotics

Twenty-seven programs (90%) gave at least one dose of preoperative IV antibiotics. Of these 27 programs, 21 (77.8%) gave one preoperative dose only and do not hospitalize patients postoperatively (►Fig. 1). Of the remaining 6 programs that hospitalized patients for postoperative IV antibiotics, 1 (3.7%) did so for 24 hours, 4 (14.8%) for 48 hours, and 1 (3.7%) for 72 hours. Of the seven different IV regimens reported, the most frequently used was fluoroquinolone monotherapy by 14 of the 27 programs (51.9%) (►Fig. 2). Six programs (22.2%) used vancomycin in combination with either ceftazidime or cefepime (and one of those programs added a fluoroquinolone as well).

Intraoperative Intravitreal Antibiotics

Eight of the 30 responding programs (26.7%) gave intravitreal antibiotics at the time of surgery. Of these 8 programs, all (100%) used ceftazidime and 7 (87.5%) added vancomycin (►Fig. 2). Of note, all 3 programs who did not give any perioperative IV antibiotics injected intravitreal antibiotics at the time of surgery.

Postoperative Oral Antibiotics

Sixteen of the 30 responding programs (53.3%) discharged patients postoperatively on oral antibiotics. Eight of these programs (50%) used levofloxacin, 7 (38.9%) used moxifloxacin, and 1 (5.6%) used oral cephalexin (►Fig. 2). Interestingly, among these 18 programs, 4 of them also hospitalized patients for IV antibiotics, with 1 (5.6%) of them giving 24 hours, 2 (11.1%) giving 48 hours, and 1 (5.6%) giving 72 hours. Eleven of these programs (61.1%) gave one dose of preoperative IV antibiotics. Only one of these programs (5.6%) did not give IV antibiotics but they gave intraoperative intravitreal therapy.

Overall, the most common protocols used were a single dose of IV antibiotics with (9/30, 30.0%) and without (7/30, 23.3%) postoperative oral therapy.

Secondary Endophthalmitis Prophylaxis

Intraoperative Subconjunctival Antibiotics

Eighteen of 30 responding programs (60%) gave subconjunctival antibiotics at the time of surgery. Of these 18 programs, 10 (55.6%) used cefazolin, 7 (38.9%) used ceftazidime, and 1 (5.6%) used tobramycin. Three of the programs that used ceftazidime and one of the programs that used cefazolin also injected subconjunctival vancomycin (22.2%).

Postoperative Topical Antibiotics

All 30 of the responding programs (100%) discharged patients on topical antibiotics. Twenty-nine of these programs (96.7%) used moxifloxacin and 1 (3.3%) used neomycin/polymyxin B/dexamethasone. Three of these programs

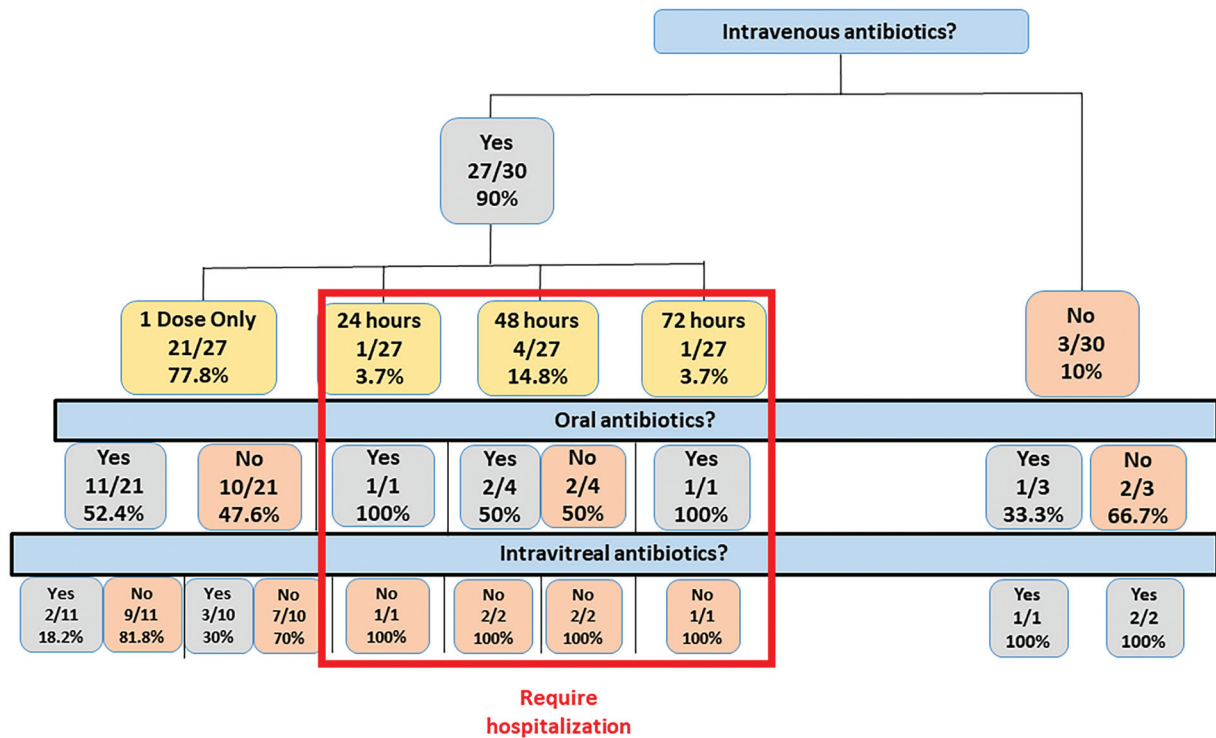


Fig. 1 Breakdown of use of intravenous, oral, and intravitreal antibiotics.

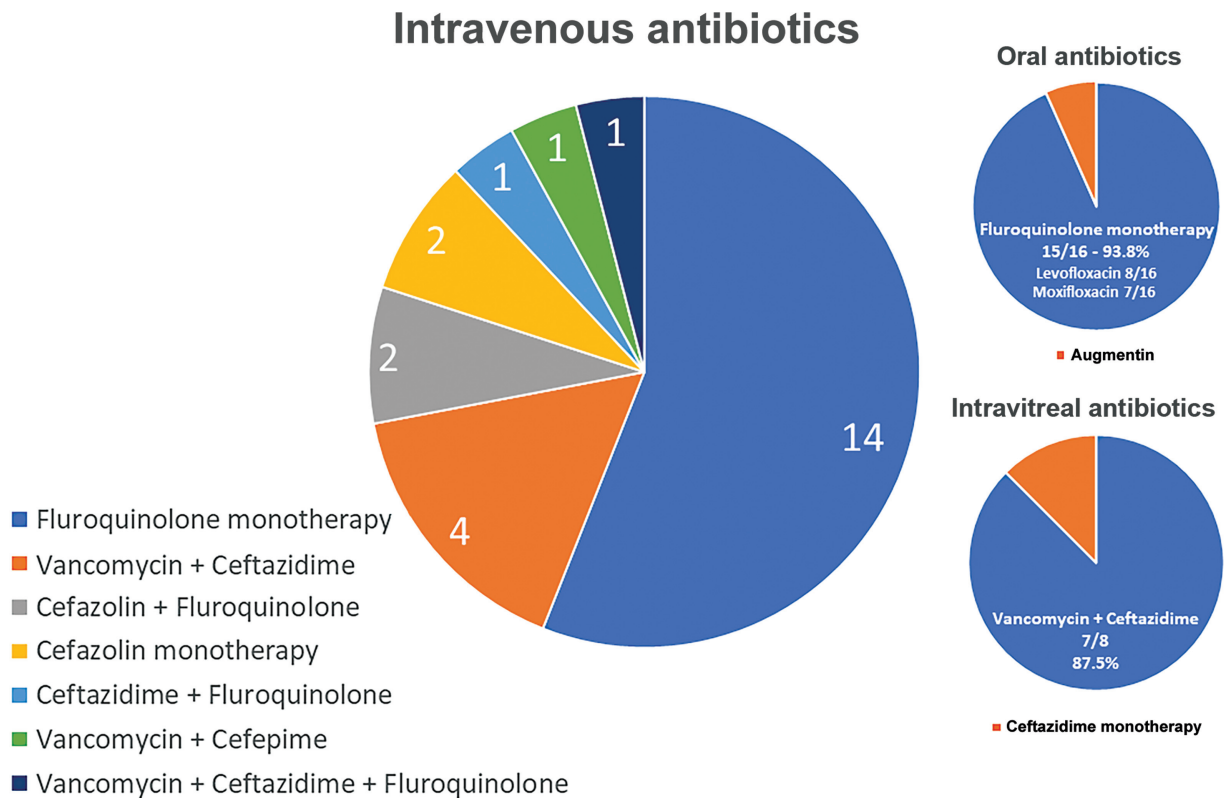


Fig. 2 Breakdown by antibiotic regimen for intravenous, intravitreal, and postoperative oral antibiotic use.

(10%) also gave bacitracin/polymixin B in combination with moxifloxacin. Most programs (73.3%) only have patients use antibiotic drops for 1 week postoperatively, with the average duration of topical therapy being 1.2 weeks.

Perioperative Steroids

Two programs (6.7%) utilized perioperative IV steroids, whereas two other programs (6.7%) injected intravitreal steroids, but no programs discharged patients home on

adjunctive oral steroids. Ten programs (33.3%) injected subconjunctival steroids and all but one program (96.7%) gave postoperative topical steroids.

Discussion

The survey data collected from ophthalmology residencies across the United States and compiled here demonstrate that there is significant variation in endophthalmitis prophylaxis protocols among programs, with most programs using one dose of IV antibiotics with or without the use of postoperative oral antibiotics. If the assumption is made that programs are not continuing with protocols that allow for high rates of endophthalmitis, then this highlights that, in conjunction with early repair, there are multiple effective antibiotic regimens maintaining low rates of endophthalmitis following OGI repair. The focus then must be on comparing these various approaches to determine if the burden they place on hospital systems and on patients is worth any superiority in terms of efficacy. It is important to note that the majority of responding programs in this study (80%) did not routinely hospitalize patients for IV antibiotics following OGI repair.

Published case series of various prophylactic antibiotic regimens have yielded endophthalmitis rates of 0.9 to 5.6%.^{6,7,12-15} The lowest rate of 0.9% was achieved with use of IV vancomycin in combination with either IV ceftazidime or cefepime for 48 hours.^{6,7} However, there is published work that suggests that the antibiotic itself matters more in terms of vitreous penetration and that some oral antibiotics reach much higher concentrations than many that are given IV. A recent review of the available literature concluded that the three antibiotics that, when given systemically, reach the highest concentrations in the vitreous are meropenem, linezolid, and moxifloxacin, two of which are given orally.¹⁶

Two randomized control studies performed outside of the United States have found similar rates between those treated with IV and oral antibiotics as primary endophthalmitis prophylaxis. One study, which looked at a total of 1,255 patients, compared a group that received 72 hours of IV vancomycin and ceftazidime with 72 hours of oral ciprofloxacin. They found no difference between endophthalmitis rates (2.1 vs. 2.2%, $p = 0.978$).⁹ However, the only cases of *Bacillus cereus* endophthalmitis occurred in the oral therapy group. A smaller randomized prospective study that compared oral ciprofloxacin and cefuroxime therapy with a combination of IV cefazolin and oral ciprofloxacin demonstrated no significant difference in endophthalmitis rates between groups (2.0 vs. 2.7%, $p = 0.703$).⁸ Of note, despite relatively good vitreous:serum ratios for fluoroquinolones, observed concentrations in vitreous are insufficient for ciprofloxacin, unlike for moxifloxacin.¹⁶

Although no study has thoroughly evaluated the utility of a single dose of specific IV antibiotics as monotherapy for posttraumatic endophthalmitis in uncomplicated OGI, researchers at the Kellogg Eye Institute have recently published a large 17-year retrospective study of endophthalmitis rates, using their protocol that was defined as one

dose of an unspecified IV antibiotic and some patients receiving postoperative oral treatment at discharge. The rate of endophthalmitis in this study was found to be 2.2%, excluding those patients that had endophthalmitis at presentation.¹⁷

The role of intravitreal antibiotics for endophthalmitis prophylaxis in OGI repair has not been well described and is often reserved for OGI with high-risk characteristics.¹⁸ Abouammoh et al analyzed and compared rates of posttraumatic endophthalmitis before and after their protocol was changed to include intravitreal antibiotics and found improvements in endophthalmitis rates (3.7 vs 1.7%) that did not reach statistical significance ($p = 0.077$).¹⁹

There is evidence to support the use of IV, oral, and intravitreal antibiotics as a primary or adjunct tool in the prevention of endophthalmitis and severe vision loss for patients with traumatic OGI. This survey of U.S. ophthalmology residency programs demonstrates wide variation in practice patterns across programs and the need for a standard of care that maintains low rates of endophthalmitis while considering the financial and social burden that hospitalization places on patients and hospital systems.

Study Limitations

This study has several limitations. The response rate to the survey was only 28.8% despite multiple reminder notifications. Importantly, there was no assessment of actual rates of endophthalmitis for these protocols, and therefore, the degree to which each program's antibiotic protocol limits endophthalmitis is unknown. As such, this study serves to report practice trends and cannot compare the efficacy of each protocol employed.

Future Directions

Future studies should randomize and compare common protocols to properly assess superiority of treatment with IV, oral, or intravitreal antibiotics, as well as compare the utility of one dose of preoperative IV antibiotics with multiple days of treatment. Additional work should examine the costs of management of these patients, based on the type of antibiotic administered and the need for hospitalization.

Conclusion

This study demonstrates the variation in practice patterns across ophthalmology residency programs for antibiotic protocols in patients who have undergone surgical repair for uncomplicated OGI repair. A majority use one preoperative dose of IV antibiotic(s), a variety of combinations of intraoperative intravitreal and subconjunctival and postoperative oral antibiotics, and a consensus for postoperative topical antibiotics. The range of responses highlights the need for a randomized comparative study that aims to establish an optimal standard of care for management of these patients.

Funding

None.

Conflict of Interest

None declared.

References

- 1 May DR, Kuhn FP, Morris RE, et al. The epidemiology of serious eye injuries from the United States Eye Injury Registry. *Graefes Arch Clin Exp Ophthalmol* 2000;238(02):153–157
- 2 Essex RW, Yi Q, Charles PG, Allen PJ. Post-traumatic endophthalmitis. *Ophthalmology* 2004;111(11):2015–2022
- 3 Bhagat N, Nagori S, Zarbin M. Post-traumatic infectious endophthalmitis. *Surv Ophthalmol* 2011;56(03):214–251
- 4 Ahmed Y, Schimel AM, Pathengay A, Colyer MH, Flynn HW Jr. Endophthalmitis following open-globe injuries. *Eye (Lond)* 2012;26(02):212–217
- 5 Zhang Y, Zhang MN, Jiang CH, Yao Y, Zhang K. Endophthalmitis following open globe injury. *Br J Ophthalmol* 2010;94(01):111–114
- 6 Huang JM, Pansick AD, Blomquist PH. Use of intravenous vancomycin and cefepime in preventing endophthalmitis after open globe injury. *J Ocul Pharmacol Ther* 2016;32(07):437–441
- 7 Andreoli CM, Andreoli MT, Kloek CE, Ahuero AE, Vavvas D, Durand ML. Low rate of endophthalmitis in a large series of open globe injuries. *Am J Ophthalmol* 2009;147(04):601–608.e2
- 8 Du Toit N, Mustak S, Cook C. Randomised controlled trial of prophylactic antibiotic treatment for the prevention of endophthalmitis after open globe injury at Groote Schuur Hospital. *Br J Ophthalmol* 2017;101(07):862–867
- 9 Tabatabaei SA, Soleimani M, Behrooz MJ, Sheibani K. Systemic oral antibiotics as a prophylactic measure to prevent endophthalmitis in patients with open globe injuries in comparison with intravenous antibiotics. *Retina* 2016;36(02):360–365
- 10 Harris PA, Taylor R, Thielke R, Payne J, Gonzalez N, Conde JG. Research electronic data capture (REDCap)—a metadata-driven methodology and workflow process for providing translational research informatics support. *J Biomed Inform* 2009;42(02):377–381
- 11 Shrestha B, Dunn L. The Declaration of Helsinki on medical research involving human subjects: a review of seventh revision. *J Nepal Health Res Counc* 2020;17(04):548–552
- 12 Verbraeken H, Rysseleere M. Post-traumatic endophthalmitis. *Eur J Ophthalmol* 1994;4(01):1–5
- 13 Duch-Samper AM, Menezo JL, Hurtado-Sarrió M. Endophthalmitis following penetrating eye injuries. *Acta Ophthalmol Scand* 1997;75(01):104–106
- 14 Jonas JB, Knorr HL, Budde WM. Prognostic factors in ocular injuries caused by intraocular or retrobulbar foreign bodies. *Ophthalmology* 2000;107(05):823–828
- 15 Soheilian M, Rafati N, Mohebbi MR, et al; Traumatic Endophthalmitis Trial Research Group. Prophylaxis of acute posttraumatic bacterial endophthalmitis: a multicenter, randomized clinical trial of intraocular antibiotic injection, report 2. *Arch Ophthalmol* 2007;125(04):460–465
- 16 Brockhaus L, Goldblum D, Eggenschwiler L, Zimmerli S, Marzolini C. Revisiting systemic treatment of bacterial endophthalmitis: a review of intravitreal penetration of systemic antibiotics. *Clin Microbiol Infect* 2019;25(11):1364–1369
- 17 Durrani AF, Zhao PY, Zhou Y, et al. Risk factors for endophthalmitis following open globe injuries: a 17-year analysis. *Clin Ophthalmol* 2021;15:2077–2087
- 18 Narang S, Gupta V, Gupta A, Dogra MR, Pandav SS, Das S. Role of prophylactic intravitreal antibiotics in open globe injuries. *Indian J Ophthalmol* 2003;51(01):39–44
- 19 Abouammoh MA, Al-Mousa A, Gogandi M, et al. Prophylactic intravitreal antibiotics reduce the risk of post-traumatic endophthalmitis after repair of open globe injuries. *Acta Ophthalmol* 2018;96(03):e361–e365