



# Isolated Cerebral Cyst Hydatid Removal with Dowling's Technique in a 6-Year-Old Pediatric Patient: Case Report

Yigit Can Senol<sup>1,2</sup> Naime Dilara Ozkan<sup>1</sup> Servet Guresci<sup>2</sup> Ergun Daglioglu<sup>1</sup> Ahmet Deniz Belen<sup>1</sup>

<sup>1</sup>Department of Neurosurgery, Ankara Bilkent City Hospital, Ankara, Turkey

<sup>2</sup>Department of Pathology, Ankara Bilkent City Hospital, Ankara, Turkey

Address for correspondence Yigit Can Senol, MD, Department of Neurological Surgery, Ankara Bilkent City Hospital, Ankara, Bilkent, 06800, Turkey (e-mail: ygtsenol@gmail.com).

AJNS 2023;18:372–376.

## Abstract

Hydatid disease, caused by the *Echinococcus* parasite, is a worldwide zoonosis produced by the larval stage of the tapeworm. In urban living patients with cerebral abscesses, hydatid cysts should not be excluded from the differential diagnosis. We report an exceptional primary cerebral hydatid cyst in which imaging showed a large, round, contrast-enhancing lesion with a mass effect. The patient presented with a dull headache for over a year and progressively worsened left hemiparesis. The magnetic resonance imaging showed a huge intracranial mass, and the pathology was corrected with cyst hydatid. Surgery was performed via Dowling's technique, and the patient recovered without neurologic deficits. Echinococcosis should be considered a differential diagnosis for single or multiple cerebral abscesses, even in the absence of liver infections. The history of living in rural areas does not exclude cerebral hydatid cysts and *Echinococcus*.

## Keywords

- ▶ hydatid cyst
- ▶ *Echinococcus*
- ▶ cerebral abscess
- ▶ pediatric
- ▶ Dowling's technique

## Introduction

Hydatid disease, caused by the *Echinococcus* parasite, is a worldwide zoonosis produced by the larval stage of the tapeworm. *E. granulosus* and *E. multilocularis* cause two main types of hydatid disease affecting humans. The parasite becomes lodged through the hematogenous route at various body sites, especially in the liver, rarely including the brain. An intracranial hydatid cyst is a relatively rare entity. It accounts for only 1 to 2% of all intracranial space-occupying lesions.<sup>1,2</sup> They are commonly seen in children and young adults (50–75%).<sup>3</sup> Their rare nature, coupled with nonspecific symptoms, necessitates a high degree of clinical suspicion and thus

presents a diagnostic difficulty. Surgery remains the treatment of choice, but recently some new modalities have been described. Beginning in the 1970s, benzimidazoles, mebendazole, and albendazole have been used to treat hydatid disease. The most feared complication is anaphylactic shock due to cyst rupture. Such a situation may occur spontaneously or during surgical removal. The Dowling technique is a surgical technique that has been used since 1975 to prevent perioperative cyst rupture and to avoid anaphylactic shock.

Looking at past publications, the disease, which is more frequently seen in rural areas, has recently started to be seen in urban areas.<sup>4</sup>

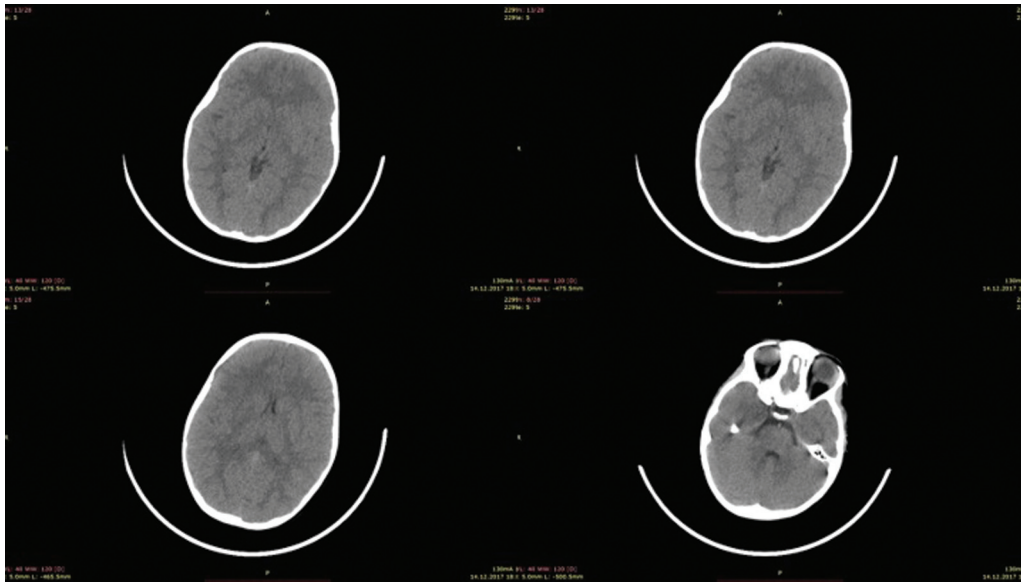
article published online  
June 7, 2023

DOI <https://doi.org/10.1055/s-0043-1768600>.  
ISSN 2248-9614.

© 2023. Asian Congress of Neurological Surgeons. All rights reserved.

This is an open access article published by Thieme under the terms of the Creative Commons Attribution-NonDerivative-NonCommercial-License, permitting copying and reproduction so long as the original work is given appropriate credit. Contents may not be used for commercial purposes, or adapted, remixed, transformed or built upon. (<https://creativecommons.org/licenses/by-nc-nd/4.0/>)

Thieme Medical and Scientific Publishers Pvt. Ltd., A-12, 2nd Floor, Sector 2, Noida-201301 UP, India



**Fig. 1** The cranial computed tomography images of the patient from 2017. No cranial pathology was evaluated.

## Case Report

A 6-year-old girl presents with complaint of a dull headache in the frontal region for over a year. Her pain is revealed with nonsteroidal anti-inflammatory drugs. In 2017 because of her dull headache, she had a cranial computed tomography (CT) scan, and no cranial pathology was seen. Therefore, her family did not attach importance to her complaints. She describes her pain and aggravation in traveling in a car, and she has photophobia and phonophobia when she has a headache. She had also lost balance for 2 months and was evaluated by orthopaedics for developmental hip dysplasia and leg shortness. Yet none of the orthopaedic pathologies were seen. Her cranial magnetic resonance imaging (MRI) revealed a huge intracranial mass that extraordinarily gives no more symptoms than a headache for a year with under control nonsteroidal anti-inflammatory drug medication. She was in a good general state of health, fully conscious and oriented, and her neurological examination progressively worsened in 2 weeks with left hemiparesis. She was intact in speech but had symptoms of increased intracranial pressure, such as nausea or vomiting, for 2 months. Fundoscopic examination on the lesion side showed only a minor degree of papilledema. No evaluation of direct contact with dogs or other animals is also unavailable, and she was living with her family in an urban area.

### Preoperative Evaluation

The preoperative evaluation was done in the pediatric service, and the patient was investigated for other organ involvement. Her echocardiogram showed no involvement of other organs. She had no respiratory signs and no participation in her lung X-ray. She had slightly elevated acute phase reactants and white blood counts in her blood tests. She had neither parasite signs from her blood smear nor indirect hemagglutination test and immunoassay blood tests.

CT image revealed a simple cyst hydatid. In light of the literature, this is the most common type, usually solitary and fertile.<sup>5</sup> The simple cyst appears as a well-defined, smooth thin-walled, spherical homogenous cystic lesion (► **Fig. 1**). The cyst wall may be isodense to hyperdense on CT having low signal intensity on T1-weighted and high signal intensity on T2-weighted MRI (► **Fig. 2**). A prophylactic albendazole was started due to high risk of cyst hydatid disease from radiological evaluation.

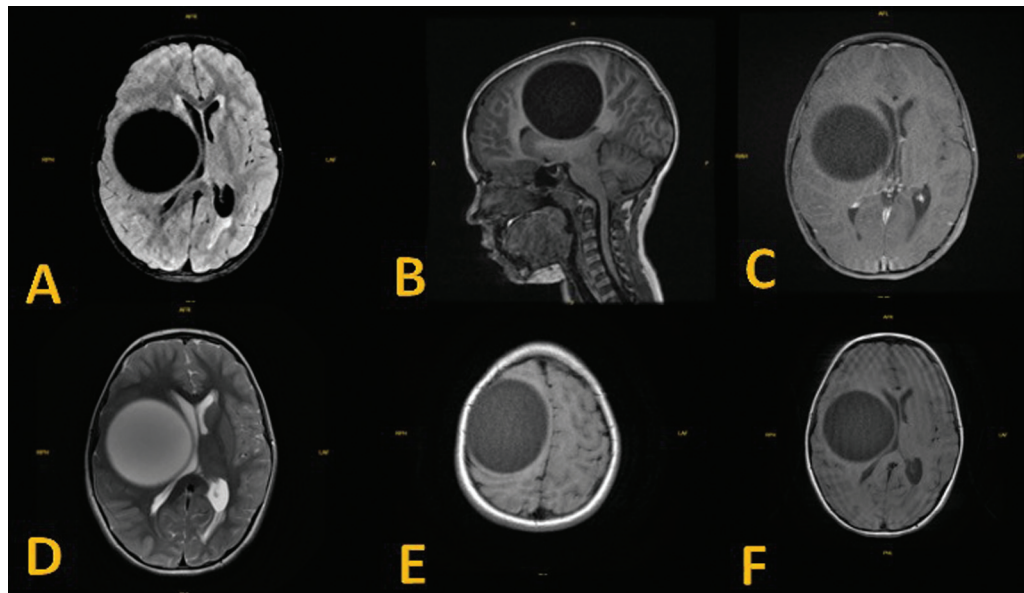
### Surgical Management and Postoperative Evaluation

Because the mass effect and her neurologic deficits were compatible with the lesion, we decided to operate on her and used the right frontotemporal craniotomy (► **Video 1**). The dura was opened in a "C" shape and excised the cyst with Dowling's technique.<sup>6</sup> The method is based on creating a levitational force by the injected water itself to push the cyst smoothly out of its pocket without perforating it. The levitational power will be combined during the operation with gravitational force by tilting the operating table, allowing smooth ejection of the cyst. If the cyst ruptures at this stage, the patient may face severe perioperative anaphylaxis or even a fulminant death. The rupture rates of cysts in the literature have been reported as 28%.<sup>7</sup> The cyst was excised without an eruption in a single form (► **Fig. 3**), weighing approximately 500 mg. Total excision was completed, and the dura was sutured in a watertight fashion. The bone flap was put in its place, and the skin was correctly sutured. Postoperative CT imaging was revealed and showed total excision (► **Fig. 4**).

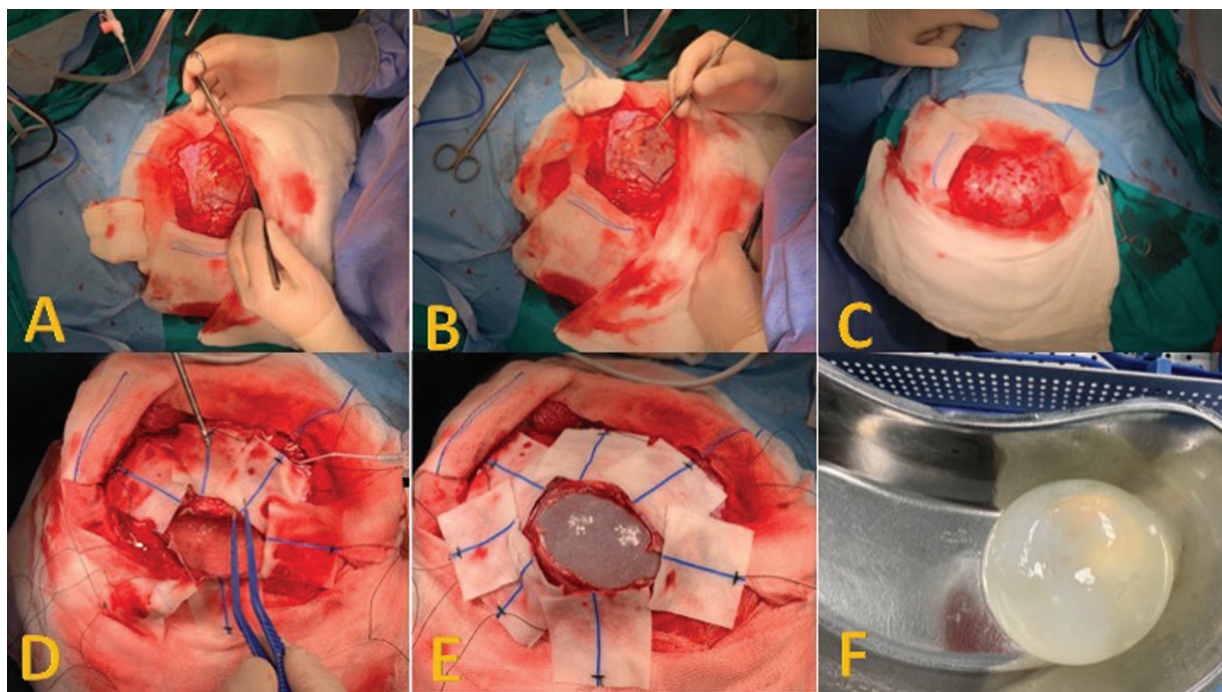
After the confirmation of diagnosis, anticonvulsant treatment was continued for a period of 1 month without any postoperative seizures. Albendazole was started postoperatively at 10 mg/kg twice daily for 3 months. No additional postoperative images were performed.

### Histopathology

A 10.5-cm, intact, nontransparent cyst with a severe content was sent to the pathology laboratory. On cross-sections,



**Fig. 2** (A) T2 flair imaging photograph with mass effect in the area of the right frontotemporal lobe. (B) Sagittal images of T1. (C) Contrasted T1 images of a lesion that has noncontrasted. (D) T2 imaging of the lesion. (E) T1 axial images of the lesion. (F) T1 images of the lesion. On the right side, a 10-mm shift is seen.



**Fig. 3** (A) Dural opening with a "C" shape. The lesion's cortical elongation is seen on the surgeon's side. (B) After the dural opening dissecting the cystic lesion from the border of the normal glial tissue. (C) The lesion's cortical edges are reached and ready for excision. (D) We used cotton paddies to dissect the cyst without injuring normal brain tissue. (E) The lesion is dissected from all borders. (F) The cyst is excised from the brain in a single piece without disintegration.

laminated, chitinous membranes containing daughter vesicles with hooked scolices were seen, consisting of hydatid cysts (→ Fig. 5).

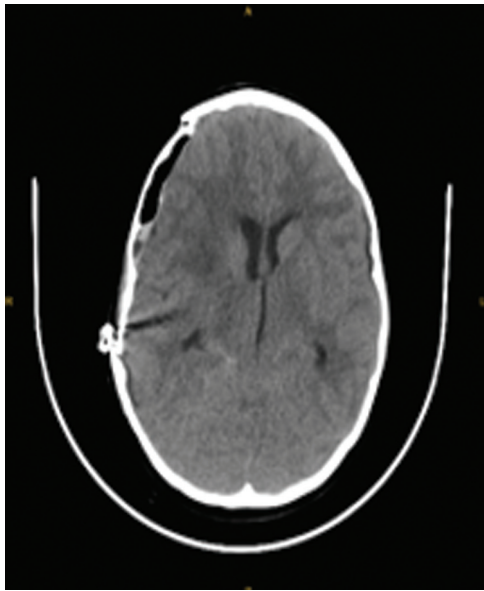## Discussion

Intracranial hydatid disease is rare, representing 1 to 2% of all cases of hydatid disease.<sup>8</sup> Also, it accounts for only 1

to 2% of all intracranial space-occupying lesions.<sup>9</sup> The incidence of intracranial hydatid in India is 0.2%.<sup>10</sup> Cerebral hydatid cysts are more common in the pediatric population, with 80% of the affected patients being children.<sup>11,12</sup>

Some articles showed that hydatid cyst is not as rare as in rural areas, just the opposite.<sup>13</sup> Primary extrahepatic involvement of *Echinococcus* is rare, and cerebral involvement





**Fig. 4** Postoperative computed tomography (CT) imaging of patients. The lesion is removed, and shifts are improved.

is unusual.<sup>14</sup> The history of living in rural areas does not exclude cerebral hydatid cysts and *Echinococcus*.

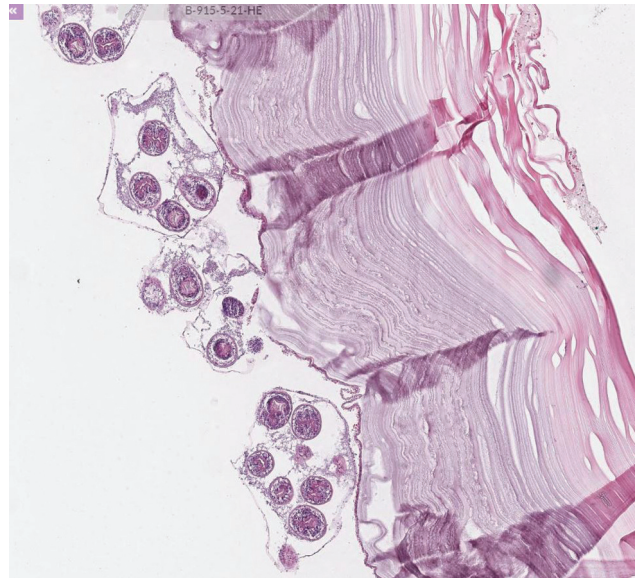
To avoid complications while doing Dowling's technique, it is essential to thoroughly examine images preoperatively with adequate planning to avoid major blood vessels and eloquent cortical areas. A sufficiently large craniotomy is very important for the removal of the cyst without fragmentation. Aspiration force should not be excessive during hydrodissection, and dissection should be continued at low pressure. We see that this procedure was done with a 60-mL syringe in the literature before,<sup>7,15</sup> but we used a low-pressure aspiration device in our case. Furthermore, even if we have those safety measures, the operator delivers the physiological saline at a steady slow rate.

## Conclusion

Dowling's technique has been an effective and safe surgical method in the treatment of cerebral cyst hydatid since 1975 when it was first described. The most important point to be considered in this technique is the removal of the cyst without fragmentation. Adjuvant antiparasitic therapy is required after surgical treatment. Cyst hydatid, which is frequently seen in rural areas, should be in the differential diagnosis list of surgery in intracranial cystic masses in children since it can also be seen in urban areas today.

### Video 1

Perioperative video of the removal of a hydatid cyst. Online content including video sequences viewable at: <https://www.thieme-connect.com/products/ejournals/html/10.1055/s-0043-1768600>.



**Fig. 5** Scolex and the germinative membrane were seen in pathology samples, and it was compatible with the hydatid cyst.

### Conflict of Interest

None declared.

### References

- 1 Braham E, Bellil S, Bellil K, et al. Hydatid cyst of the posterior fossa. *Med Mal Infect* 2007;37(05):281–283
- 2 Tlili-Graies K, El-Ouni F, Gharbi-Jemni H, et al. Cerebral hydatid disease: imaging features. *J Neuroradiol* 2006;33(05):304–318
- 3 Cavoşoğlu H, Tuncer C, Ozdilmaç A, Aydin Y. Multiple intracranial hydatid cysts in a boy. *Turk Neurosurg* 2009;19(02):203–207
- 4 Acosta-Jamett G, Hernández FA, Castro N, et al. Prevalence rate and risk factors of human cystic echinococcosis: a cross-sectional, community-based, abdominal ultrasound study in rural and urban north-central Chile. *PLoS Negl Trop Dis* 2022;16(03):e0010280
- 5 Koor JME, Thomas RD, Chandrashekhar HS, Jayakumar PN, Pillai S, Shankar SK. Neurohydatidosis. *Australas Radiol* 2007;51(05):406–411
- 6 Carrea R, Dowling E Jr, Guevara JA. Surgical treatment of hydatid cysts of the central nervous system in the pediatric age (Dowling's technique). *Childs Brain* 1975;1(01):4–21
- 7 Hage P, Salle H, Ibrahim I, Khalil W. Hydatid cyst excision using Dowling's technique of hydrodissection. *Acta Neurochir (Wien)* 2022;164(11):2851–2854
- 8 Gürler AT, Bölükbaş CS, Açıcı M, Umut Ş Overview of *Echinococcus multilocularis* in Turkey and in the world. *Türkiye Parazitoloj Derg* 2019;43(Suppl 1):18–35
- 9 Gupta S, Desai K, Goel A. Intracranial hydatid cyst: a report of five cases and review of literature. *Neurol India* 1999;47(03):214–217
- 10 Nurchi G, Floris F, Montaldo C, Mastio F, Peltz T, Coraddu M. Multiple cerebral hydatid disease: case report with magnetic resonance imaging study. *Neurosurgery* 1992;30(03):436–438
- 11 Kemalioğlu S, Ozkan U, Bükte Y, Acar M, Ceviz A. Growth rate of cerebral hydatid cyst, with a review of the literature. *Childs Nerv Syst* 2001;17(12):743–745

- 12 Onal C, Barlas O, Orakdögen M, Hepgül K, Izgi N, Unal F. Three unusual cases of intracranial hydatid cyst in the pediatric age group. *Pediatr Neurosurg* 1997;26(04):208–213
- 13 Tanki H, Singh H, Raswan US, Bhat AR, Kirmani AR, Ramzan AU. Pediatric intracranial hydatid cyst: a case series with literature review. *Pediatr Neurosurg* 2018;53(05):299–304
- 14 Kern P, Menezes da Silva A, Akhan O, et al. The echinococcoses: diagnosis, clinical management and burden of disease. *Adv Parasitol* 2017;96:259–369
- 15 Ciurea AV, Fountas KN, Coman TC, et al. Long-term surgical outcome in patients with intracranial hydatid cyst. *Acta Neurochir (Wien)* 2006;148(04):421–426