



# Adult Brainstem Astroblastoma: Unusual Presentation of a Rare Tumor

Ishu Bishnoi<sup>1</sup> Rahul Midha<sup>2</sup> Karandeep Singh<sup>3</sup> Swapnil Garg<sup>4</sup> Payal Jain<sup>2</sup>

<sup>1</sup>Neurosurgery Department, Maharaja Agrasen Medical College, Agroha, Haryana, India

<sup>2</sup>Anesthesia Department, Maharaja Agrasen Medical College, Agroha, Haryana, India

<sup>3</sup>Pathology Department, Maharaja Agrasen Medical College, Agroha, Haryana, India

<sup>4</sup>Surgery Department, Maharaja Agrasen Medical College, Agroha, Haryana, India

Address for correspondence Ishu Bishnoi, MCh, Neurosurgery Department, Maharaja Agrasen Medical College, Agroha, Haryana, 125052, India (e-mail: ishushinoi@gmail.com).

AJNS 2023;18:396–399.

## Abstract

Astroblastoma is a rare tumor, which is mostly found in pediatric population. Due to scarcity of literature, the data about treatment is lacking. We are reporting case of brainstem astroblastoma in an adult female. A 45-year-old lady presented with complaint of headache, vertigo, vomiting, and nasal regurgitation for 3 months. On examination, she had weak gag, left hemiparesis. Magnetic resonance imaging brain reported medulla oblongata mass, dorsally exophytic. She underwent suboccipital craniotomy and decompression of mass. Histopathology confirmed diagnosis of astroblastoma. She underwent radiotherapy and recovered well. Brainstem astroblastoma is an extremely rare entity. The surgical resection is possible due to well-defined plane. For best outcome, maximum resection and radiation are indicated.

## Keywords

- ▶ astroblastoma
- ▶ brainstem
- ▶ medulla oblongata
- ▶ telovelar approach
- ▶ Ki-67

## Introduction

Astroblastoma is a pediatric malignant brain tumor; incidence ranges from 0.4 to 2.8%.<sup>1</sup> Bimodal age distribution was reported.<sup>2</sup> Its most common location is frontoparietal region.<sup>1,2</sup> In searched literature, we found three case report of brainstem astroblastoma.<sup>3–5</sup> We are reporting our experience of brainstem astroblastoma.

## Case Report

A 45-year-old lady presented with headache for 6 months and vomiting, nasal regurgitation of food for 3 months. On examination, she had ataxia, hoarseness of voice, and weak

gag reflex. Magnetic resonance imaging brain confirmed medulla oblongata mass, reaching till cervicomedullary junction (▶ **Fig. 1A–C**). We kept differential diagnosis of fourth ventricular ependymoma, brainstem glioma, and medulloblastoma.

Patient underwent midline suboccipital craniotomy after informed consent. Tumor was approached via telovelar approach, found 5 mm below parenchyma, originating from medulla, friable, pinkish-gray, vascular, and had well-defined plane of cleavage (▶ **Fig. 2A,B**). The deep portion of tumor was left due to persistent bradycardia. Neuromonitoring was not used.

In postoperative period, external ventricular drain was kept for first 7 days and removed after giving complete block

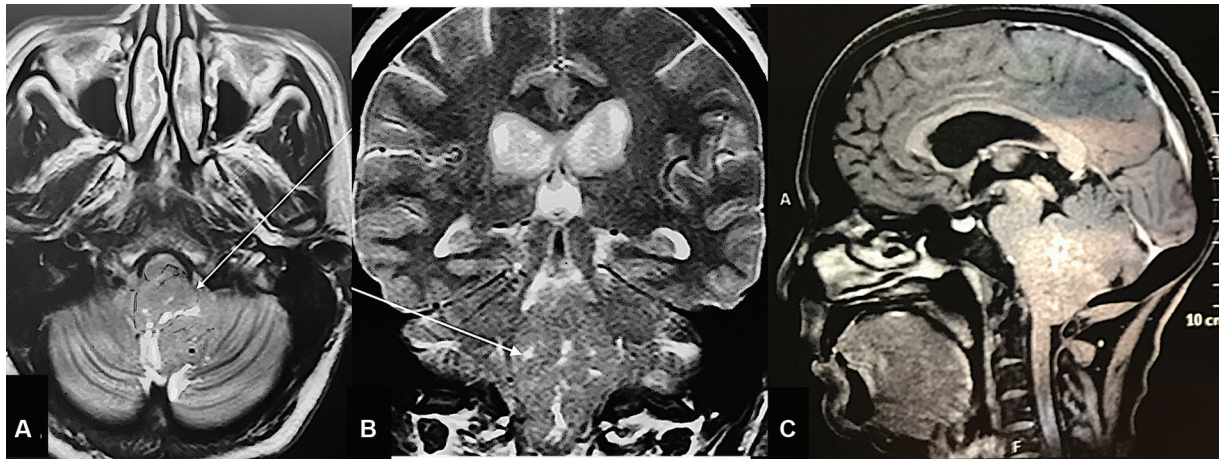
article published online  
June 16, 2023

DOI <https://doi.org/10.1055/s-0043-1769892>.  
ISSN 2248-9614.

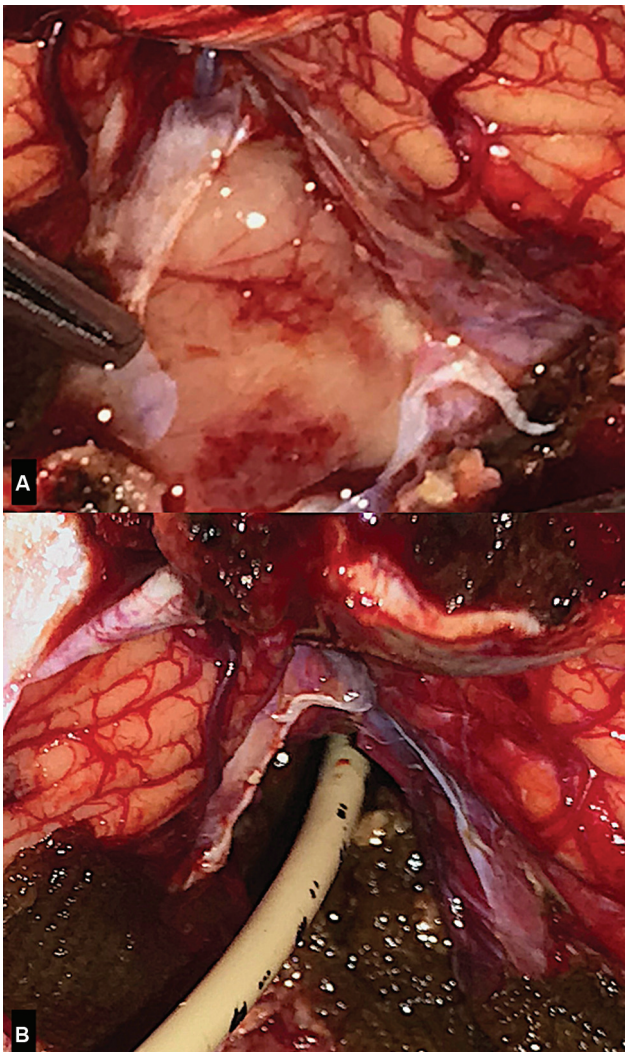
© 2023. Asian Congress of Neurological Surgeons. All rights reserved.

This is an open access article published by Thieme under the terms of the Creative Commons Attribution-NonDerivative-NonCommercial-License, permitting copying and reproduction so long as the original work is given appropriate credit. Contents may not be used for commercial purposes, or adapted, remixed, transformed or built upon. (<https://creativecommons.org/licenses/by-nc-nd/4.0/>)

Thieme Medical and Scientific Publishers Pvt. Ltd., A-12, 2nd Floor, Sector 2, Noida-201301 UP, India



**Fig. 1** (A) T2 axial image showing medulla oblongata mass (arrow) arising from dorsal aspect, compressing medulla anteriorly. (B) T2 coronal cut showing fourth ventricular mass (arrow) extent from lower medulla till pons. (C) T1 sagittal cut showing dorsally exophytic mass, protruding in fourth ventricle, herniating through foramen magnum and compressing cervicomedullary junction.



**Fig. 2** (A, B) Intraoperative image showing cream-yellow colored mass protruding through foramen of Magendie and displacing tonsils and external ventricular drain inside fourth ventricle after resection.

trial for 1 day. She tolerated well. She had absent cough and weak gag reflex. She underwent elective tracheostomy and was given nasogastric feed.

Histopathology report confirmed diagnosis of brainstem astroblastoma, high-grade variant (→**Fig. 3A–D**). The slides showed the typical vascular hyalinization with fibrous background and contained rosette formations composed of short cells. The cells were positive for glial fibrillary acidic protein, epithelial membrane antigen, S100 protein, and Olig-2. The Ki-67 index was 5%.

After 2 months, her cough and gag reflex became normal. Tracheostomy was removed. Her voice quality and swallowing were normal.

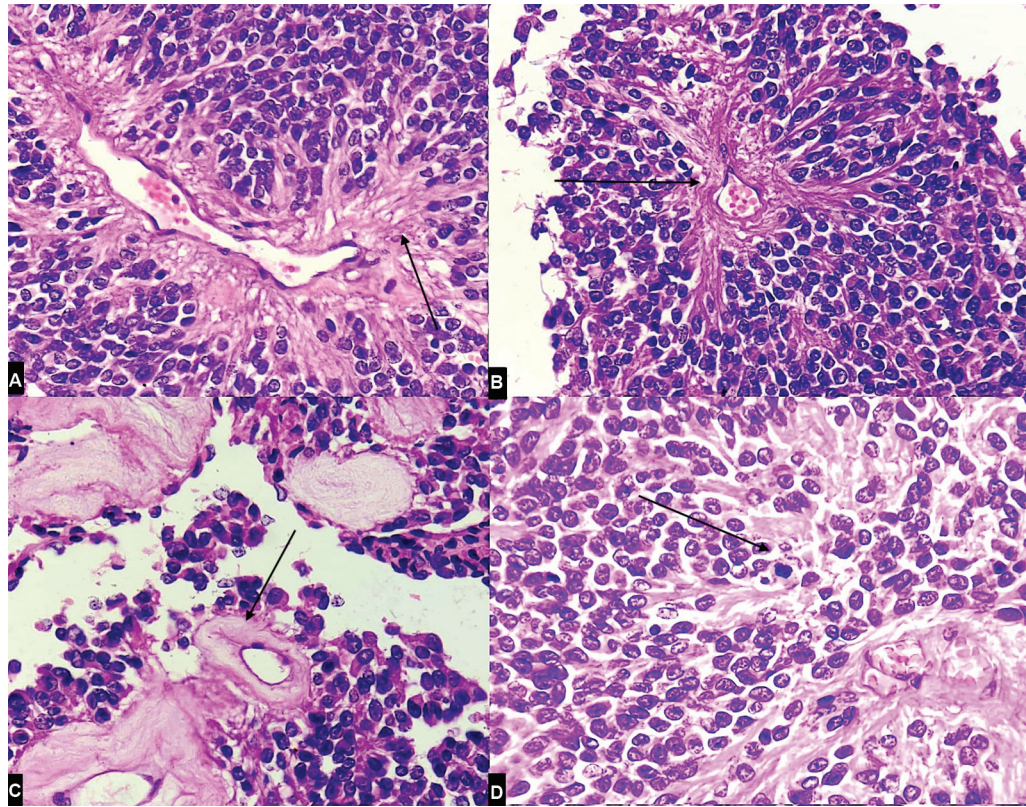
She received 30 days radiotherapy. After 1 year follow-up, she was asymptomatic.

## Discussion

Astroblastoma is a rare tumor of both low- and high-grade type.<sup>1,2,6</sup> Its behavior is unpredictable and not based on histopathological features.<sup>1,6,7</sup> Due to its rarity, its clinical behavior is not well studied. Till 2011, only 116 patients of brain astroblastoma were reported in literature.<sup>8</sup> And out of these 116 cases, only 3 cases of brainstem astroblastoma were reported till now.

Astroblastomas are classified under “other gliomas” category in World Health Organization classification of central nervous system tumors, 2016. Its characteristic histological features are glial neoplasm, broad pseudorosettes, which may demonstrate sclerosis.<sup>2</sup>

Both Notarianni et al and Kim et al reported astroblastoma of medulla oblongata.<sup>3,4</sup> They operated solid-cystic lesion in medulla oblongata with successful outcome. Similarly, we also found solid-cystic tumor in medulla oblongata with dorsal exophytic component. Similar to Notarianni et al, the postsurgical outcome was good. Our case developed



**Fig. 3** (A) Histopathology image showing pseudorosette, thick cytoplasmic processes toward vessel wall (400 ×) (arrow). (B) pseudorosette (400 ×) (arrow). (C) thick hyalinized blood vessels (400 ×) (arrow), and (D) mitotic figures (400 ×) (arrow).

temporary ninth and tenth nerve weakness, which resolved with time. Similar to other brainstem lesions, brainstem astroblastoma is a difficult tumor to manage. It is because of the high probability of postoperative neurological deficits, more chances of leaving residue, restricted manipulation of surrounding and accurate entry point to avoid damage of vital regions.

Babu et al reported median survival rate of high-grade brainstem glioma around 12.1 and 77 months for glioblastoma multiforme and anaplastic astrocytoma, respectively.<sup>9</sup> Overall, malignant gliomas carry mean survival rate up to 12 months.<sup>2,10</sup> There are no data about brainstem astroblastoma survival. After considering both case reports, it can be said that survival rate of brainstem astroblastoma is more than gliomas. The reported overall survival of cerebral astroblastoma at 5 years is around 80%.<sup>1,11</sup> Despite its unpredictable nature, astroblastoma carries better prognosis.

For high-grade astroblastoma, adjuvant radiation enhances survival.<sup>1,11</sup> Role of chemotherapy is controversial.<sup>1,11</sup> Our patient received adjuvant radiotherapy and symptom free after 1 year.

## Conclusion

Brainstem astroblastoma is extremely rare, mostly reported in medulla oblongata. For optimum results, maximal safe

resection and postoperative radiation should be given. Due to well-defined plane, a good amount of tumor can be resected.

## Funding

None.

## Conflict of Interest

None declared.

## Acknowledgment

We would like to express special thanks to staff Babli and technician Ramesh Kirori for assisting in surgery.

## References

- Ahmed KA, Allen PK, Mahajan A, Brown PD, Chia AJ. Astroblastomas: a surveillance, epidemiology, and end results (SEER)-based patterns of care analysis. *World Neurosurg* 2014;82(1-2): e291-e297
- Samples DC, Henry J, Yu FF, Bazan C, Tarasiewicz I. A case of astroblastoma: radiological and histopathological characteristics and a review of current treatment options. *Surg Neurol Int* 2016;7 (Suppl 40):S1008-S1012
- Kim BS, Kothbauer K, Jallo G. Brainstem astroblastoma. *Pediatr Neurosurg* 2004;40(03):145-146
- Notarianni C, Akin M, Fowler M, Nanda A. Brainstem astroblastoma: a case report and review of the literature. *Surg Neurol* 2008;69(02):201-205

- 5 Shin SA, Ahn B, Kim SK, et al. Brainstem astroblastoma with MN1 translocation. *Neuropathology* 2018;38(06):631–637
- 6 Wood MD, Tihan T, Perry A, et al. Multimodal molecular analysis of astroblastoma enables reclassification of most cases into more specific molecular entities. *Brain Pathol* 2018;28(02):192–202
- 7 Janz C, Buhl R. Astroblastoma: report of two cases with unexpected clinical behavior and review of the literature. *Clin Neurol Neurosurg* 2014;125:114–124
- 8 Sughrue ME, Choi J, Rutkowski MJ, et al. Clinical features and post-surgical outcome of patients with astroblastoma. *J Clin Neurosci* 2011;18(06):750–754
- 9 Babu R, Kranz PG, Agarwal V, et al. Malignant brainstem gliomas in adults: clinicopathological characteristics and prognostic factors. *J Neurooncol* 2014;119(01):177–185
- 10 Kesari S, Kim RS, Markos V, Drappatz J, Wen PY, Pruitt AA. Prognostic factors in adult brainstem gliomas: a multicenter, retrospective analysis of 101 cases. *J Neurooncol* 2008;88(02):175–183
- 11 Merfeld EC, Dahiya S, Perkins SM. Patterns of care and treatment outcomes of patients with astroblastoma: a National Cancer Database analysis. *CNS Oncol* 2018;7(02):CNS13. Doi: 10.2217/cns-2017-0038