



# An Unusual Complication of Transarterial Radioembolization: Hepatic Artery Pseudoaneurysm and its Treatment with Ultrasound-guided Thrombin Injection

Muhammet Arslan<sup>1</sup> Halil Serdar Aslan<sup>1</sup> Burak Sarılar<sup>1</sup> Aziz Gültekin<sup>2</sup>

<sup>1</sup>Department of Radiology, Pamukkale University Faculty of Medicine, Denizli, Turkey

<sup>2</sup>Department of Nuclear Medicine, Pamukkale University Faculty of Medicine, Denizli, Turkey

Address for correspondence Muhammet Arslan, MD, Associate Professor, Kınıklı mahallesi 20070 Pamukkale Üniversitesi Hastanesi Girişimsel Radyoloji Bölümü 20050, Pamukkale/Denizli/Turkey (e-mail: dr.marslan@hotmail.com).

Arab J Intervent Radiol 2023;7:114–116.

## Abstract

### Keywords

- ▶ radioembolization
- ▶ pseudoaneurysm
- ▶ ultrasound
- ▶ hepatic artery
- ▶ ultrasound-guided thrombin injection

Transarterial radioembolization (TARE) is a widely used treatment method for primary liver cancers and metastasis. Although TARE is relatively safe, it may cause liver abscess, failure, nontarget embolization, and vascular complications. Herein, we report a case of TARE-related hepatic artery pseudoaneurysm that was treated successfully with ultrasound-guided thrombin injection.

## Introduction

Transarterial radioembolization (TARE) is the delivery of radioactive microspheres to liver cancers, which are ineligible for curative surgery or ablation. The most common adverse events and complications of the TARE procedure are minor events, such as fatigue, pain, nausea, and/or vomiting. Vascular complications of TARE are infrequent and include puncture-site complications, injury to the hepatic artery, and nontarget embolization.<sup>1</sup> This report describes a case of post-TARE pseudoaneurysm of the hepatic artery, which was managed by ultrasound (US)-guided thrombin injection technique.

## Case Presentation

A 62-year-old woman presented with right upper quadrant pain and increased fatigue. She had a history of cholangiocarcinoma, breast malignancies, previous surgeries, and local

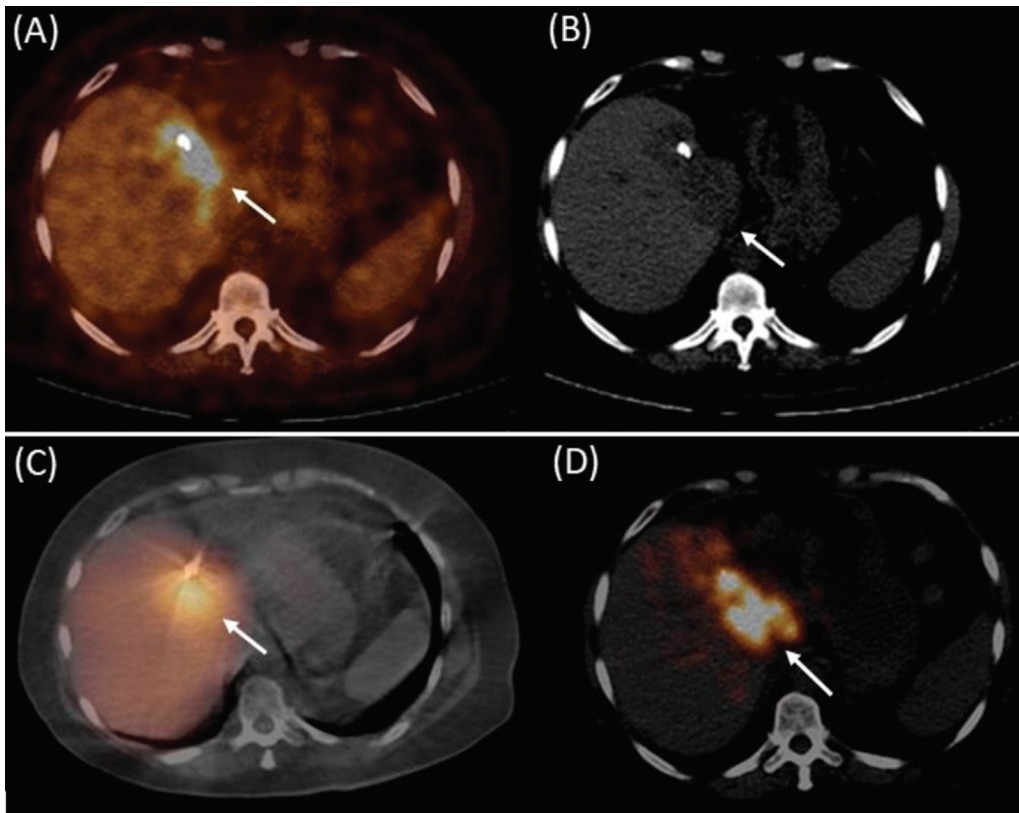
ablative therapies for treating a mass in the liver. She has not used chemotherapy for 2 years. Due to tumor recurrence and metastasis in the right lobe of the liver, she underwent TARE 4 months earlier (▶ Fig. 1). Laboratory results showed hemoglobin: 5.3 g/dL, hematocrit: 18.5%, total bilirubin: 2.71 mg/dL, and direct bilirubin: 2.51 mg/dL. She was hospitalized and received blood transfusion therapy. Control laboratory investigations revealed an acute increase in bilirubin values, with total bilirubin: 16.29 mg/dL and direct bilirubin: 13.36 mg/dL. Contrast-enhanced abdominal computed tomography showed a collection with gas pockets and lobulated contours, measuring 6 × 3.5 cm in segment 4 extending to the hilum and left lobe. A 20 × 19 mm pseudoaneurysm was observed at the level of the left hepatic artery branch (▶ Fig. 2A). Intrahepatic bile ducts were dilated due to the compression. The patient was referred to undergo US-guided thrombin injection of the pseudoaneurysm. Thereafter, about 0.5 mL thrombin solution was injected with a 21G needle into pseudoaneurysm under US guidance (▶ Fig. 3).

article published online  
September 4, 2023

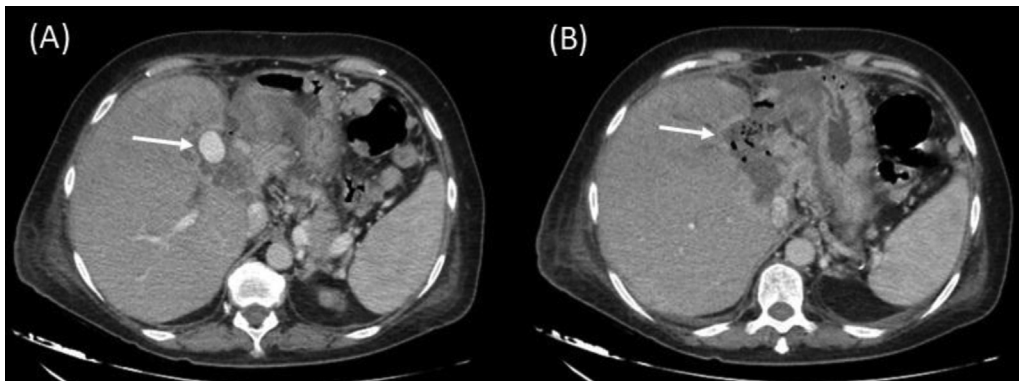
DOI <https://doi.org/10.1055/s-0043-1770914>.  
ISSN 2542-7075.

© 2023. The Author(s).

This is an open access article published by Thieme under the terms of the Creative Commons Attribution License, permitting unrestricted use, distribution, and reproduction so long as the original work is properly cited. (<https://creativecommons.org/licenses/by/4.0/>)  
Thieme Medical and Scientific Publishers Pvt. Ltd., A-12, 2nd Floor, Sector 2, Noida-201301 UP, India



**Fig. 1** The patient's metastatic lesion (arrows) in liver segment IV on pretreatment fluorine-18 fluorodeoxyglucose positron emission tomography/computed tomography (18FDG PET/CT) (A), CT (B), 99mTc-macroaggregated albumin single-photon emission computed tomography (SPECT/CT) (C), and posttreatment 90Y-PET/CT (D). Homogeneous and intense distribution of 90Y-microspheres adjacent to the hepatic artery region is demonstrated in 90Y-PET/CT (D) that exactly resembles the pretreatment 18FDG PET/CT (A).

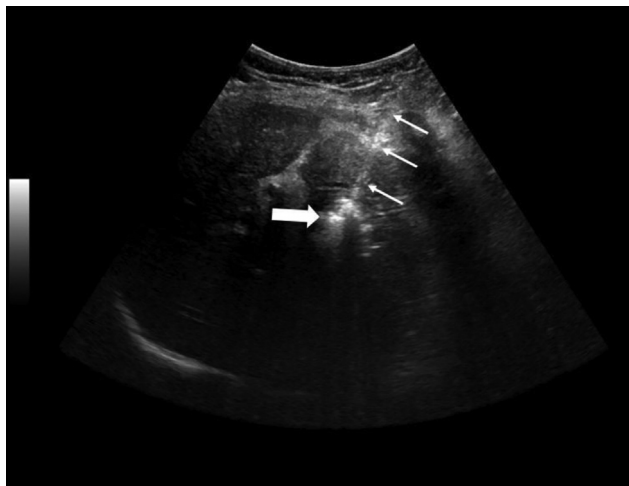


**Fig. 2** Axial postcontrast arterial phase computed tomographic images show a well-defined oval-shaped intensely enhancing small pseudoaneurysm (arrow) (A) and nonenhancing bubble containing thrombosed pseudoaneurysm (arrow) (B) arising from the hepatic artery noted at the porta hepatis.

The injection was administered slowly and continually until flow cessation as determined on duplex Doppler US monitoring, and the flow in the sac stopped within seconds. Final imaging revealed thrombosed pseudoaneurysm (► Fig. 2B). Bilirubin levels decreased in the follow-up over the next few days. Our patient was discharged on the 11th postoperative day and had no further gastrointestinal hemorrhage in 3 months.

## Discussion

TARE with yttrium-90 loaded microspheres is an important treatment method that is used increasingly in the management of unresectable primary or metastatic liver malignancies. Various complications related to yttrium and manipulation guidewire may occur during or after the procedure and are divided into pulmonary, gastrointestinal, liver-specific, and



**Fig. 3** Grayscale ultrasound image shows a 21G needle (thin arrows) and increased echogenicity within thrombosed pseudoaneurysm (thick arrow) after thrombin injection.

vascular events. Vascular complications of TARE are not uncommon and generally include puncture-site complications and injury to the hepatic artery. In the literature, pseudoaneurysm is reported as a complication of transarterial chemoembolization although not of TARE, it could happen to both of them.<sup>2</sup> Pseudoaneurysms can develop due to trauma (catheter manipulations and other iatrogenic or penetrating injury), pancreatitis, vasculitis, or the destructive effect of yttrium 90.<sup>3</sup> In addition, treatment with bevacizumab impairs tissue healing, has vasculopathy effects, and increases stasis; it is recommended to change the chemotherapy protocol before TARE.<sup>4</sup> In our patient, chemotherapy was not used and the absence of pseudoaneurysm in the angiographic images taken during the TARE procedure and rehospitalization with acute symptoms 4 months after the procedure suggested that the pseudoaneurysm was caused by the vascular damage induced by yttrium 90.

Symptomatic pseudoaneurysms should be treated. Treatment methods involve surgery, US-guided compression, US-

guided thrombin injection technique, and an endovascular approach. Endovascular therapeutic options include transcatheter embolization, percutaneous thrombin injection, stent-grafting, and combined treatments.<sup>5</sup> The US-guided thrombin injection technique is a safe and useful method in pseudoaneurysms. With a high rate of thrombosis success, this method is practical because of less pain as the compression and the procedure are less time-consuming. Before the injection, the pseudoaneurysm, the neck, and the adjacent structures are observed with US.

Pseudoaneurysms may occur as a late-onset complication after TARE and can be successfully treated with US-guided thrombin injection.

#### Authors' Contribution

The manuscript has been read and approved for submission by all the authors. We declare that this manuscript is original, has not been published before, and it is not currently being considered for publication elsewhere

#### Conflict of Interest

None declared.

#### References

- 1 Riaz A, Lewandowski RJ, Kulik LM, et al. Complications following radioembolization with yttrium-90 microspheres: a comprehensive literature review. *J Vasc Interv Radiol* 2009;20(09): 1121–1130, quiz 1131
- 2 Atay M, Ozdemir H. An unusual complication of transarterial chemoembolization of hepatocellular carcinoma; pseudoaneurysm: a case report. *Curr Med Imaging Rev* 2022;18(11): 1244–1247
- 3 Madhusudhan KS, Venkatesh HA, Gamanagatti S, Garg P, Srivastava DN. Interventional radiology in the management of visceral artery pseudoaneurysms: a review of techniques and embolic materials. *Korean J Radiol* 2016;17(03):351–363
- 4 Guney IB, Ballı HT. Radioembolization: Patient selection and planning 2019;5:107–116
- 5 Venturini M, Marra P, Colombo M, et al. Endovascular treatment of visceral artery aneurysms and pseudoaneurysms in 100 patients: covered stenting vs transcatheter embolization. *J Endovasc Ther* 2017;24(05):709–717