



# Recurrent Nasopharyngeal Carcinoma and the Role of Surgery

Anirudh Saraswathula<sup>1</sup> Nyall R. London Jr.<sup>1,2</sup>

<sup>1</sup>Department of Otolaryngology–Head and Neck Surgery, Johns Hopkins University School of Medicine, Baltimore, Maryland, United States

<sup>2</sup>Sinonasal and Skull Base Tumor Program, Surgical Oncology Program, Center for Cancer Research, National Cancer Institute, National Institutes of Health, Bethesda, Maryland, United States

**Address for correspondence** Nyall R. London, MD, PhD, 601 N Caroline St, Flr 6, Baltimore, MD 21287, United States (e-mail: nlon2@jhmi.edu).

J Neurol Surg Rep 2023;84:e68–e70.

## Abstract

### Keywords

- ▶ nasopharyngeal carcinoma
- ▶ nasopharyngectomy
- ▶ endoscopic endonasal skull base surgery

Recurrent nasopharyngeal carcinoma (rNPC) presents unique challenges as reirradiation comes with significant treatment-related morbidity in swallowing, middle ear function, and large-vessel integrity. Advances in endoscopic technology have made surgery for rNPC an increasingly viable option for select patients and may play a role in providing a better quality of life to patients with this challenging disease. In carefully selected patients, endoscopic and open surgical approaches may provide comparable disease control while mitigating long-term treatment-related morbidity.

## Introduction

Nasopharyngeal carcinoma (NPC) is an uncommon malignancy endemic to Southeast Asia, and its recurrent form (rNPC) presents unique treatment challenges. Although reirradiation for rNPC has traditionally been the mainstay of treatment, it comes with significant treatment-related morbidity in swallowing, middle ear function, and large-vessel integrity. In carefully selected patients, endoscopic and open surgical approaches may provide comparable disease control while mitigating long-term treatment-related morbidity.

## Case Presentation

A 65-year-old man presented 1 year after receiving definitive 70 Gy intensity-modulated radiation therapy (IMRT) in 35 fractions for a cT1N0 left NPC. A posttreatment positron emission tomography-computed tomography (PET-CT) at that time showed no residual fluorodeoxyglucose-avidity. The referring physician noticed a raised lesion in the left

nasopharynx, which biopsy revealed to be poorly differentiated human papillomavirus+ Epstein–Barr virus squamous cell carcinoma. PET-CT and magnetic resonance imaging were performed (▶**Fig. 1**), the patient was seen by the multidisciplinary team, and presented at tumor board who recommended surgical resection. An expanded endonasal approach was performed for tumor extirpation.

## Discussion

There are several treatment options for locally rNPC, including: reirradiation, proton beam therapy, endoscopic nasopharyngectomy, and open nasopharyngectomy.<sup>1</sup> For metastatic disease, systemic therapy is the mainstay. In the absence of metastatic disease, the 2019 International Consensus Statements on Allergy and Rhinology suggests that endoscopic nasopharyngectomy is a reasonable approach for rT1 and rT2 NPC.<sup>2</sup> A 2023 meta-analysis of salvage treatments for locally recurrent NPC showed in a pooled analysis that endoscopic nasopharyngectomy had improved 5-year survival to IMRT

received

May 22, 2023

accepted after revision

May 29, 2023

DOI <https://doi.org/>

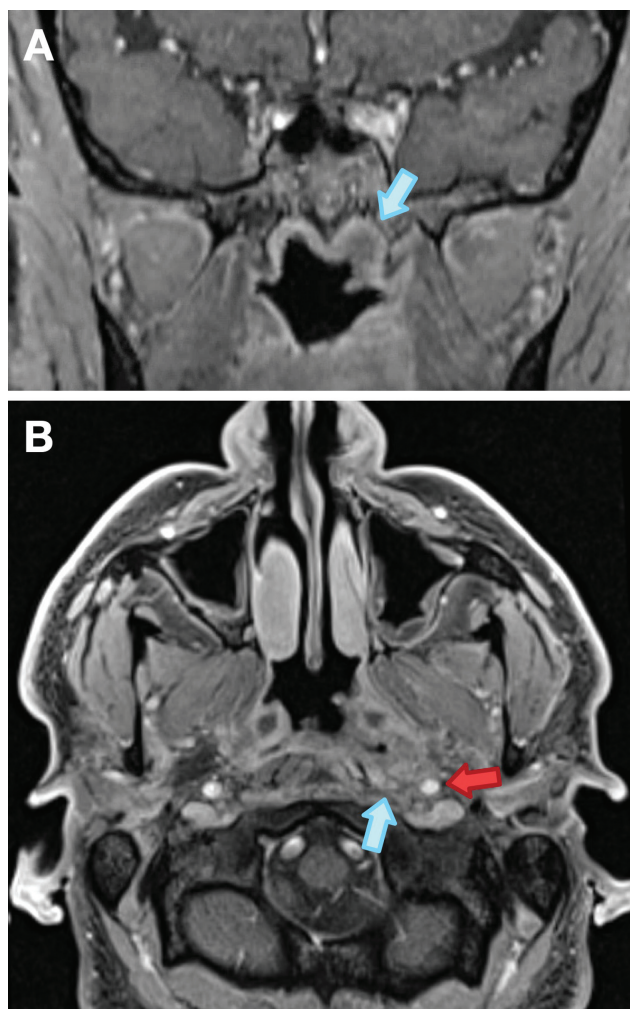
10.1055/s-0043-1770966.

ISSN 2193-6358.

© 2023. The Author(s).

This is an open access article published by Thieme under the terms of the Creative Commons Attribution-NonDerivative-NonCommercial-License, permitting copying and reproduction so long as the original work is given appropriate credit. Contents may not be used for commercial purposes, or adapted, remixed, transformed or built upon. (<https://creativecommons.org/licenses/by-nc-nd/4.0/>)

Georg Thieme Verlag KG, Rüdigerstraße 14, 70469 Stuttgart, Germany



**Fig. 1** Postcontrast (A) coronal and (B) axial T1-weighted magnetic resonance imaging of the skull base showed asymmetric soft tissue enhancement along the lateral wall of the left nasopharynx and along the anterior left fossa of Rosenmüller with indistinct muscle planes adjacent to the left medial pterygoid muscle belly. Blue arrow indicates tumor, red arrow indicates parapharyngeal segment of the internal carotid artery.

(61% vs. 41%). While selection bias is certainly a factor, this presented endoscopic surgery as a viable option for good candidates and with a better long-term safety profile (avoiding reirradiation to prevent swallowing dysfunction from radiation fibrosis, impaired middle ear ventilation, or carotid blowout syndrome).<sup>1</sup> The 2-year overall survival for rNPC patients is low, but comparable when examining endoscopic versus open surgery (rT2 [77% vs. 63%], rT3 [67% vs. 53%], rT4 [35% vs. 35%]). Complication rates are lower with endoscopic surgery, however.<sup>3</sup> Treatment-associated mortality from IMRT was 32% compared to 3% for either open or endoscopic surgery.<sup>1</sup>

While several approaches to endoscopic nasopharyngectomy have been described, the Castelnovo schema<sup>4</sup> is widely used. Type 1 and type 2 nasopharyngectomy are indicated for smaller nasopharyngeal tumors with dissection extending from the level of the superior nasopharynx

down to the level of C1. The Eustachian tube is preserved. Type 3 nasopharyngectomy is the most extensive and is indicated for more extensive and lateralized tumors. In addition to the exposure for type 2 (which involves bilateral sphenoidectomies), it also requires a medial maxillectomy and a transpterygoid dissection with mobilization of the pterygopalatine fossa contents, extending as far laterally as the parapharyngeal carotid artery. In this approach, the cartilaginous Eustachian tube is sacrificed. In this case presentation, the patient underwent a type 3 Castelnovo nasopharyngectomy and the defect was reconstructed with a Hadad-Bassagasteguy nasoseptal flap.<sup>5</sup> Alternately, open approaches have also been described, particularly for larger tumors. The maxillary swing is the most common open approach to the nasopharynx,<sup>6</sup> and if the carotid artery is involved, either a balloon occlusion test with carotid sacrifice or extracranial/intracranial vascular bypass from the internal carotid artery to the middle cerebral artery can be considered in select patients.<sup>7</sup>

## Conclusion

With the advantage of avoiding long-term morbidity and mortality from radiation complications, advances in endoscopic technology have made surgery for rNPC an increasingly viable option for select patients. The treatment of locally rNPC continues to evolve rapidly, and looking forward, surgery may increasingly play a role to provide a better quality of life to patients with this challenging disease entity.

## Informed Consent

Informed consent was obtained from the patient for images and video presented in this article.

## Funding

A.S. is supported by the National Institute on Deafness and Other Communication Disorders training grant T32DC000027. This research was supported (in part) by the Intramural Research Program of the Center for Cancer Research, National Cancer Institute.

## Conflict of Interest

Dr. London reported receiving grants from Merck Sharp & Dohme and holding stock in Navigen Pharmaceuticals

## References

- 1 Wang D, Liao M, Wu J, et al. Salvage treatments for locally recurrent nasopharyngeal cancer: systematic review and meta-analysis. *Head Neck* 2023;45(02):503–520
- 2 Wang EW, Zanation AM, Gardner PA, et al. ICAR: endoscopic skull-base surgery. *Int Forum Allergy Rhinol* 2019;9(S3):S145–S365
- 3 Li G, Wang J, Tang H, et al. Comparing endoscopic surgeries with open surgeries in terms of effectiveness and safety in salvaging residual or recurrent nasopharyngeal cancer: systematic review and meta-analysis. *Head Neck* 2020;42(11):3415–3426

- 4 Castelnuovo P, Dallan I, Bignami M, et al. Nasopharyngeal endoscopic resection in the management of selected malignancies: ten-year experience. *Rhinology* 2010;48(01):84–89
- 5 Hadad G, Bassagasteguy L, Carrau RL, et al. A novel reconstructive technique after endoscopic expanded endonasal approaches: vascular pedicle nasoseptal flap. *Laryngoscope* 2006;116(10):1882–1886
- 6 London NR Jr, Chan JYW, Carrau RL. Transpalatal approaches to the skull base and reconstruction: indications, technique, and associated morbidity. *Semin Plast Surg* 2020;34(02):99–105
- 7 Wu PA, Yuan GY, Zhou RM, et al. Extracranial/intracranial vascular bypass in the treatment of head and neck cancer - related carotid blowout syndrome. *Laryngoscope* 2021;131(07):1548–1556