





Chorea secondary to human immunodeficiency virus infection

Coreia secundária à infecção pelo vírus da imunodeficiência humana

André Eduardo de Almeida Franzoi¹  Amanda Maieski¹  Caio César Diniz Dissero¹ 
Helio Afonso Ghizoni Teive^{1,2} 

¹ Universidade Federal do Paraná, Hospital de Clínicas, Departamento de Medicina Interna, Serviço de Neurologia, Curitiba PR, Brazil.

² Universidade Federal do Paraná, Hospital de Clínicas, Setor de Distúrbios do Movimento, Curitiba PR, Brazil.

Address for correspondence André Eduardo de Almeida Franzoi (email: andrefranzoi@hotmail.com)

Arq. Neuropsiquiatr. 2023;81(9):857–858.

A 55-year-old woman presented with facial and cervical chorea for 3 months (video). She had a previous history of traumatic right facial nerve palsy but no comorbidities or current medication use. Brain magnetic resonance imaging (MRI) was performed (► **Figure 1**). Cerebrospinal fluid analysis was unremarkable. Serum tests were positive for human immunodeficiency virus (HIV) type 1 with 1.877.056 viral copies and T-CD4 lymphocyte count of 35/mm³. Darunavir, ritonavir, dolutegravir, and lamivudine were initiated. After 4 months, chorea showed resolution (► **Video 1**). Chorea is a rare manifestation of HIV infection.^{1,2} Differential diagnoses like neurosyphilis, Huntington disease, and Wilson disease should be ruled out.²

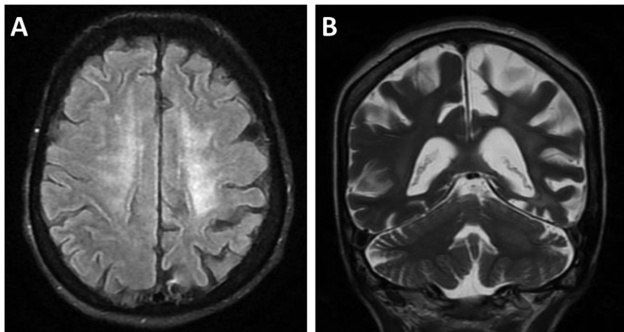


Figure 1 (A) Magnetic resonance imaging with axial T2/FLAIR sequence shows nonspecific hyperintensities in the white matter. (B) Coronal T2-weighted sequence shows brain volumetric reduction predominantly on the left parieto-occipital region, hyperintensities in the white matter, and moderate dilatation of supratentorial ventricular system with prominence of the cerebral sulci and basal cisterns.

received
December 11, 2022
received in its final form
March 3, 2023
accepted
March 15, 2023

DOI <https://doi.org/10.1055/s-0043-1771170>.
ISSN 0004-282X.

Video 1

Patient with chorea before treatment for HIV and without chorea after treatment with antiviral therapy. Online content including video sequences viewable at: <https://www.thieme-connect.com/products/ejournals/html/10.1055/s-0043-1771170>.



Authors' Contributions

AEAF: conceptualization, data curation, formal analysis, investigation, validation, writing – original draft; AM: investigation, writing – original draft; CCDD, HAGT: investigation, supervision. All authors read and approved the final manuscript.

Support

The authors did not receive support from any organization for the submitted work.

Conflict of Interest

The authors have no conflict of interest to declare.

References

- Cardoso F. HIV-related movement disorders: epidemiology, pathogenesis and management. *CNS Drugs* 2002;16(10):663–668. Doi: 10.2165/00023210-200216100-00002
- Rajan S, Kaas B, Moukheiber E. Movement Disorders Emergencies. *Semin Neurol* 2019;39(01):125–136. Doi: 10.1055/s-0038-1677050

© 2023. The Author(s).

This is an open access article published by Thieme under the terms of the Creative Commons Attribution 4.0 International License, permitting copying and reproduction so long as the original work is given appropriate credit (<https://creativecommons.org/licenses/by/4.0/>).

Thieme Revinter Publicações Ltda., Rua do Matoso 170, Rio de Janeiro, RJ, CEP 20270-135, Brazil