




Arthroplasty-Related Pseudotumor of the Scapula: Case Report and Review of the Literature

Irina Kapustina¹ Youssef Ali² Michael E. Kallen³ S. Ashfaq Hasan⁴ Derik L. Davis¹

¹Department of Diagnostic Radiology and Nuclear Medicine, University of Maryland Medical Center, Baltimore, Maryland, United States

²University of Maryland School of Medicine, Baltimore, Maryland, United States

³Department of Pathology, University of Maryland School of Medicine, Baltimore, Maryland, United States

⁴Department of Orthopaedics, University of Maryland School of Medicine, Baltimore, Maryland, United States

Address for correspondence Derik L. Davis, MD, Department of Diagnostic Radiology and Nuclear Medicine, University of Maryland School of Medicine, 22 S. Greene Street, Baltimore, Maryland 21201, United States (e-mail: ddavis@som.umaryland.edu).

Indian J Radiol Imaging 2024;34:163–166.

Abstract

Keywords

- ▶ arthroplasty
- ▶ CT
- ▶ metal
- ▶ metallosis
- ▶ pseudotumor
- ▶ radiograph
- ▶ shoulder

Arthroplasty-related pseudotumors are nonneoplastic and noninfectious inflammatory masses that are typically associated with adverse reaction to metal debris. Pseudotumors most commonly occur in the setting of metal-on-metal joint replacements at the hip. However, the presentation of pseudotumor at the shoulder is exceedingly rare. In this article, we reported a case of arthroplasty-related pseudotumor of the scapula. Clinical history, radiologic signs, and tissue analysis are described. Knowledge of this rare diagnosis will support clinical decision making for teams of radiologists, pathologists, oncologists, and orthopaedic surgeons who provide care for patients presenting with suspicious shoulder masses.

Introduction

Humeral hemiarthroplasty is commonly indicated for proximal humerus fracture, humeral avascular necrosis, and humeral osteochondral deformity.^{1–3} Common complications include progressive wear and osteoarthritis of the native scapular glenoid over time. Other well-known complications include humeral loosening, subsidence, stress shielding, and abnormal tilt.^{1,2,4–6}

Adverse reaction to metal debris (ARMD) is another potential complication of joint arthroplasty, although rarely described at the shoulder. Arthroplasty-related pseudotumor, a known sequela of ARMD defined as a solid or cystic nonneoplastic and noninfectious inflammatory mass, is commonly encountered at the hip.^{7–9} In this article, we

present a rare case of arthroplasty-related pseudotumor presenting at the scapula.

Case Report

A 71-year-old male patient with sickle cell disease and a right shoulder hemiarthroplasty more than 10 years presented to the orthopaedic clinic complaining of severe right shoulder pain and limited range of motion. He also reported a history of periprosthetic right humerus fracture treated by surgery 7 years ago and a right shoulder infection treated by antibiotics 5 years ago. Physical examination was precluded since the visit occurred via telemedicine, in compliance with the institution's policies that prohibited routine in-person outpatient clinic visits during the coronavirus

article published online
September 12, 2023

DOI <https://doi.org/10.1055/s-0043-1772692>.
ISSN 0971-3026.

© 2023. Indian Radiological Association. All rights reserved.
This is an open access article published by Thieme under the terms of the Creative Commons Attribution-NonDerivative-NonCommercial-License, permitting copying and reproduction so long as the original work is given appropriate credit. Contents may not be used for commercial purposes, or adapted, remixed, transformed or built upon. (<https://creativecommons.org/licenses/by-nc-nd/4.0/>)
Thieme Medical and Scientific Publishers Pvt. Ltd., A-12, 2nd Floor, Sector 2, Noida-201301 UP, India

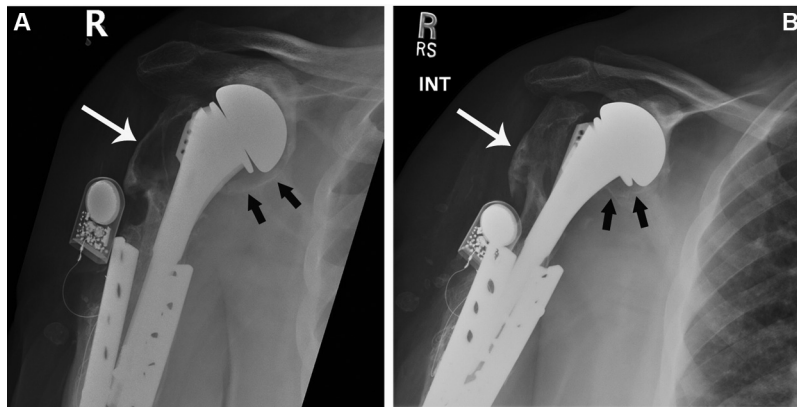


Fig. 1 Anteroposterior radiographs (A) at presentation and (B) 5 years earlier showing long-standing modular humeral hemiarthroplasty with standard-length stem in place with an adjacent old healed humeral shaft fracture status post-treatment with metallic double-plating and compression technique and direct current electrical bone stimulator placement. Worsening osteolysis at humeral greater tuberosity (long arrow) and scapular glenoid (short arrows) appears over time.

disease-2019 pandemic. His laboratory values showed a slightly elevated white blood cell count of $11.6 \times 10^3/\mu\text{L}$ (reference range: $4.0\text{--}10.0 \times 10^3/\mu\text{L}$) with a slightly low lymphocyte count of 18.8% (reference range: 22.0–44.0%) and a slightly high monocyte count of 9.1% (reference range: 0.0–9.0%); a slightly elevated C-reactive protein level of 3.6 mg/dL (reference range: 0.0–1.0 mg/dL); and a slightly elevated erythrocyte sedimentation rate of 30 mm/hr (reference range: 0–25 mm/h). Serum metal ion levels were not available. A fluoroscopy-guided right shoulder glenohumeral joint aspiration yielded no fluid, consistent with a dry tap.

Right shoulder radiographs showed a right hemiarthroplasty and a healed right proximal humerus periprosthetic fracture status post open reduction and internal fixation with a double-plating compression technique. Despite the internal fixation, the fracture had delayed healing so a direct current electrical bone stimulator was implanted subcutaneously and ultimately bony union was obtained (► Fig. 1). In comparison with a radiograph obtained 5 years earlier, increasing periprosthetic lucency was seen to replace the greater tuberosity of the proximal humerus, consistent with worsening particle disease and loosening over time. Addi-

tionally, increasing wear and lucency were seen to develop at the scapular glenoid fossa and neck over time. A new right shoulder computed tomography (CT) showed a large lytic mass centered in the scapular glenoid body and neck, measuring $6.5 \times 6.2 \times 5.8$ cm in maximum dimensions (► Fig. 2). A percutaneous CT-guided biopsy of the scapular mass was performed due to concern for malignancy. Cytologic and histologic analysis demonstrated no evidence of malignant cells. Aerobic bacterial, anaerobic bacterial, acid-fast bacillus, and fungus cultures were negative. No acid-fast bacilli were seen on smear. The tissue samples showed acellular foreign body material and a background of debris with spindle fibroblasts, fibrin, few histiocytes, and rare multinucleated giant cells (► Figs. 3 and 4). The tissue samples were consistent with a foreign body reaction, with no evidence of malignancy or infection, consistent with a final diagnosis of arthroplasty-related pseudotumor of the scapula. Treatment options, including operative versus nonoperative, were discussed with patient. Since there were significant underlying comorbidities, including sickle cell anemia that had resulted in multiple hospitalizations for vaso-occlusive crises, he was felt to be a high-risk candidate

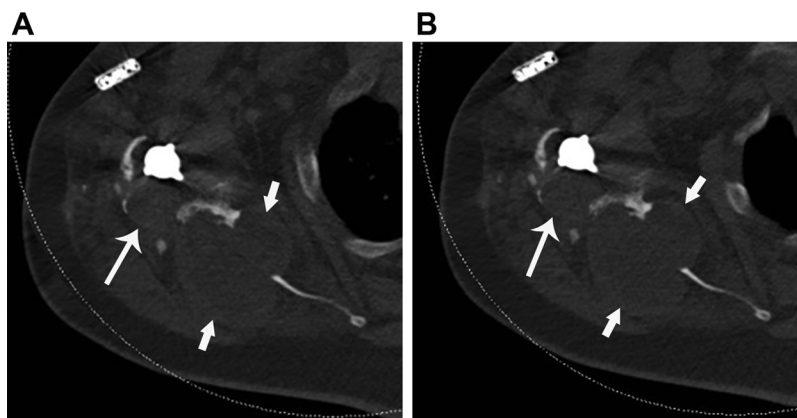


Fig. 2 Unenhanced (A) and enhanced (B) axial computed tomography images showing a large lytic ovoid mass centered in the scapular neck and body (short arrows), lacking internal enhancement and with periprosthetic osteolysis along the humeral prosthesis stem (long arrow).

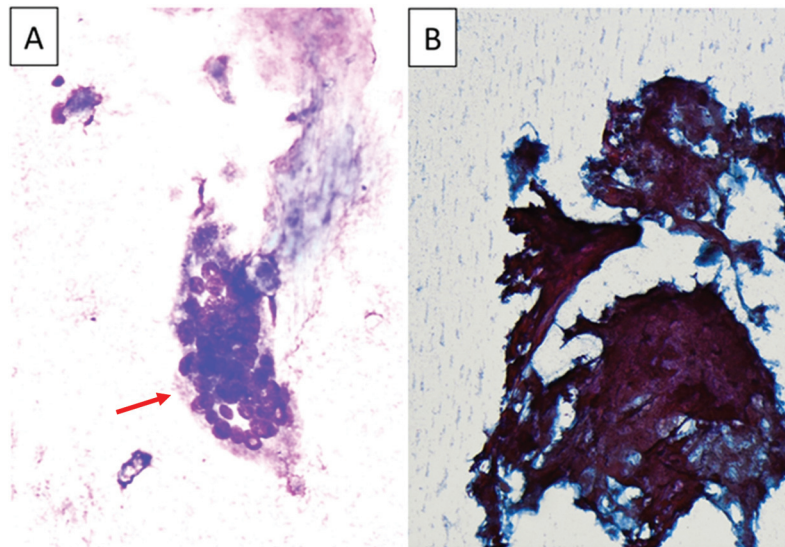


Fig. 3 Cytologic images (A) showing a rare multinucleated giant cell (red arrow), in a background of debris (Wright Giemsa Stain, 1000x magnification), and (B) a segment of dense acellular foreign material, in a background of debris (Papanicolaou stain, 1000x magnification). There is no evidence of malignant cells identified in this sample.

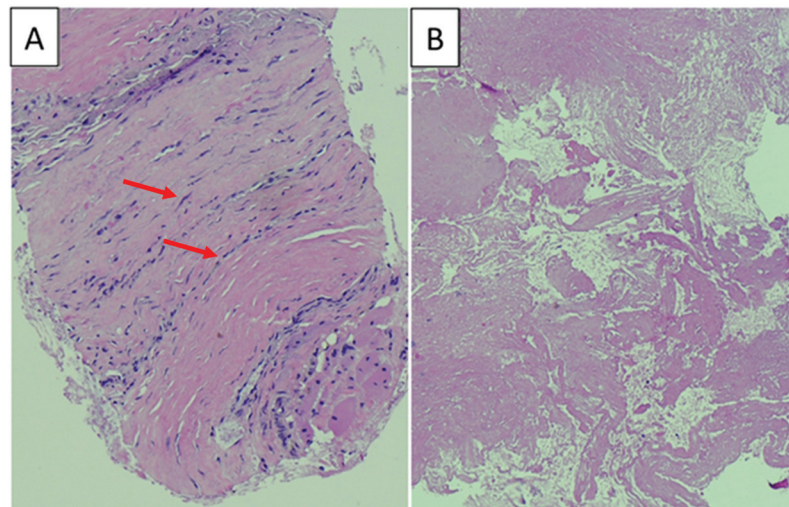


Fig. 4 Histologic sections (A) showing a segment of fibrous tissue with spindled fibroblasts (red arrows) and few histiocytes (hematoxylin and eosin [H&E] stain, 400x magnification) and (B) fibrin and acellular debris (H&E stain, 400x magnification). While the findings are nonspecific, they are compatible with the final diagnosis of arthroplasty-related pseudotumor, taken together with the clinical and radiologic context.

for surgery. Furthermore, since the result of any surgical intervention in terms of improved function and especially pain relief would be unpredictable, the patient elected for nonoperative management.

Discussion

Arthroplasty-related pseudotumor is common at the hip, but we are unaware of any prior case mimicking the radiologic appearance of a malignant bone tumor at the scapula. Particle disease is a foreign body inflammatory reaction precipitated by microscopic particles of polyethylene, metal, or ceramic in the setting of arthroplasty.^{10–12} ARMD is a subset of particle disease, often clinically presenting as metallosis or pseudotu-

mor. Most case reports about ARMD at the shoulder are based on clinical descriptions of intraoperative metallosis.^{13–21}

Our patient presented with a large pseudotumor centered in the scapula that simulated the CT appearance of a malignant bone tumor, a radiologic finding not previously reported in the literature. The emphasis of previously published cases of ARMD in the setting of shoulder arthroplasty has focused on reporting the features of metallosis that clinically feature dark metallic staining, macroscopic debris, and visible signs of hardware failure in the intracapsular and extracapsular tissues encountered at the time of surgery.^{13,15,16,20,21} Prior reports have not described imaging features of pseudotumor at the shoulder, but instead generally have described radiological signs of hardware fracture,

prosthesis mechanical wear, prosthesis malalignment, and periprosthetic osteolysis and erosion.^{13,17-19}

Particle disease was the underlying mechanism for pseudotumor formation at the scapula in our case. The long-standing presence of the humeral hemiarthroplasty, the worsening radiologic signs of osteolysis at the adjacent proximal humerus over time, and the tissue features of the scapular mass biopsy all support this hypothesis. Since the humeral hemiarthroplasty lacked a polyethylene or ceramic component, the most likely source of microscopic particles was from chronic wear and corrosion of the long-standing metallic humeral hemiarthroplasty device. Microscopic metallic particles migrating from the long-standing multiple metallic plate and screw fixation devices at the humeral shaft also may have contributed to the underlying particle disease.

High debris wear and metal hypersensitivity are two mechanisms of localized inflammatory adverse tissue reaction associated with pseudotumor formation. Macrophages and lymphocytes are both present in most cases. Patients with high wear debris more often show predominance of macrophages that phagocytose debris, while larger aggregates of lymphocytes are often present in cases of metal hypersensitivity.⁷⁻⁹ Other encountered histologic findings of pseudotumor include fibrin deposition, necrosis, fibrosis, granulation tissue, metallic debris, pigmented histiocytes, and giant cell formation.^{8,14,15} Several of these histologic findings are present in the current case. Macrophages and giant cells may contain numerous dark particles of debris on histologic inspection, although not evident in this case.¹⁴

Elevated serum metal ion levels have been linked to arthroplasty-related pseudotumors, most commonly in association with hip prostheses.⁷ However, the application of metal ion levels for clinical decision making is nonuniform in clinical practice.⁷ Given the rarity of pseudotumor at the shoulder, a serum metal ion level was not performed in this case, and final diagnosis was based on radiologic-pathologic correlation of the imaging, histologic, and cytologic findings.

We present a rare case describing the radiologic presentation of arthroplasty-related pseudotumor mimicking a malignant bone tumor at the scapula. Recognition of this rare presentation of ARMD will help guide teams of radiologists, pathologists, oncologists, and orthopaedic surgeons in clinical decision making for patients with bone masses in the setting of shoulder arthroplasty.

Funding

None.

Conflict of Interest

None declared.

References

- Combes D, Lancigu R, Desbordes de Cepoy P, et al. Imaging of shoulder arthroplasties and their complications: a pictorial review. *Insights Imaging* 2019;10(01):90
- Lin DJ, Wong TT, Kazam JK. Shoulder arthroplasty, from indications to complications: what the radiologist needs to know. *Radiographics* 2016;36(01):192-208
- Wiater JM, Fabing MH. Shoulder arthroplasty: prosthetic options and indications. *J Am Acad Orthop Surg* 2009;17(07):415-425
- Gustas-French C, Petscavage-Thomas J, Bernard SA. Imaging of shoulder arthroplasties. *Am J Roentgenol* 2018;211(03):485-495
- Gonzalez JF, Alami GB, Baque F, Walch G, Boileau P. Complications of unconstrained shoulder prostheses. *J Shoulder Elbow Surg* 2011;20(04):666-682
- Merolla G, Di Pietto F, Romano S, Paladini P, Campi F, Porcellini G. Radiographic analysis of shoulder anatomical arthroplasty. *Eur J Radiol* 2008;68(01):159-169
- Davis DL, Morrison JJ. Hip arthroplasty pseudotumors: pathogenesis, imaging, and clinical decision making. *J Clin Imaging Sci* 2016;6:17
- Campbell P, Ebramzadeh E, Nelson S, Takamura K, De Smet K, Amstutz HC. Histological features of pseudotumor-like tissues from metal-on-metal hips. *Clin Orthop Relat Res* 2010;468(09):2321-2327
- Kwon YM, Ostlere SJ, McLardy-Smith P, Athanasou NA, Gill HS, Murray DW. "Asymptomatic" pseudotumors after metal-on-metal hip resurfacing arthroplasty: prevalence and metal ion study. *J Arthroplasty* 2011;26(04):511-518
- Sukur E, Akman YE, Ozturkmen Y, Kucukdurmaz F. Particle disease: a current review of the biological mechanisms in periprosthetic osteolysis after hip arthroplasty. *Open Orthop J* 2016;10:241-251
- Goodman SB, Gallo J. Periprosthetic osteolysis: mechanisms, prevention and treatment. *J Clin Med* 2019;8(12):2091
- Miller TT. Imaging of hip arthroplasty. *Semin Musculoskelet Radiol* 2006;10(01):30-46
- Lederman ES, Nugent MT, Chhabra A. Metallosis after hemiarthroplasty as a result of glenoid erosion causing contact with retained metallic suture anchors: a case series. *J Shoulder Elbow Surg* 2011;20(06):e12-e15
- Khan WS, Agarwal M, Malik AA, Cox AG, Denton J, Holt EM. Chromium, cobalt and titanium metallosis involving a Nottingham shoulder replacement. *J Bone Joint Surg Br* 2008;90(04):502-505
- Wolfson M, Curtin P, Curry EJ, Cerda S, Li X. Giant cell tumor formation due to metallosis after open Latarjet and partial shoulder resurfacing. *Orthop Rev (Pavia)* 2020;12(02):8522
- Sochol KM, Charen DA, Andelman SM, Parsons BO. Cutaneous metallosis following reverse total shoulder arthroplasty. *J Shoulder Elbow Surg* 2018;27(07):e230-e233
- Pangaud C, Gonzalez JF, Galvin JW, Gauci MO, Boileau P. Fracture of pyrocarbon humeral head resurfacing implant: a case report. *J Shoulder Elbow Surg* 2020;29(08):e306-e312
- Matsoukis J, Billuart F, Houssam K, Dujardin F, Walch G. Conversion of total shoulder arthroplasty to reverse shoulder arthroplasty made possible by custom humeral adapter. *Orthop Traumatol Surg Res* 2015;101(06):759-761
- Fucetese SF, Costouros JG, Kühnel SP, Gerber C. Total shoulder arthroplasty with an uncemented soft-metal-backed glenoid component. *J Shoulder Elbow Surg* 2010;19(04):624-631
- Khan H, Hurworth M, Kop A. Metallosis following a dual coat porous hydroxyapatite shoulder hemiarthroplasty. *J Orthop* 2015;12(04):266-271
- Mitchell JJ, Tahal DS, Katthagen JC, Vap AR, Millett PJ. Glenoid erosion leading to contact with retained metallic suture anchors: bilateral metallosis after bilateral shoulder hemiarthroplasty: a case report. *JBJ Case Connect* 2017;7(02):e24