






# Aorto-Left Ventricular Tunnel—An Uncommon Entity

Vimal Chacko Mondy<sup>1</sup>  Anoop Ayyappan<sup>1</sup>  Jineesh Valakkada<sup>1</sup>  Deepanjan Bhattacharya<sup>2</sup>  
Bijulal Sasidharan<sup>2</sup>

<sup>1</sup>Department of Imaging Sciences and Interventional Radiology, Sree Chitra Tirunal Institute for Medical Sciences and Technology, Trivandrum, Kerala, India

<sup>2</sup>Department of Cardiology, Sree Chitra Tirunal Institute for Medical Sciences and Technology, Trivandrum, Kerala, India

Address for correspondence Anoop Ayyappan, MD, PDCC, Department of Imaging Sciences and Interventional Radiology, Sree Chitra Tirunal Institute for Medical Sciences and Technology, Trivandrum 695011, Kerala, India (e-mail: anoop123a@gmail.com).

Indian J Radiol Imaging 2024;34:160–162.

## Abstract

### Keywords

- ▶ aorto-left ventricular tunnel
- ▶ aortic regurgitation
- ▶ cardiac computed tomography
- ▶ congenital heart disease

The aorto-left ventricular tunnel is an extracardiac communication that has a specific morphological feature. It is important to differentiate this entity from other diagnoses because the treatment options differ significantly and better outcomes are obtained with this entity.

## Introduction

The aorto-left ventricular tunnel (ALVT) is a congenital extracardiac canal that connects the ascending aorta to the left ventricular cavity with the tunnel-opening aorta located above the sinotubular junction.<sup>1</sup> It is a rare anomaly that can be associated with other defects, usually involving the coronary arteries or the aortic or pulmonary valves, in up to 50% of cases.<sup>2</sup> Most often, this abnormality is discovered incidentally by echocardiography after examining for an asymptomatic murmur or cardiac enlargement. Cross-sectional imaging is helpful for treatment planning. The treatment of choice is surgery; in rare cases, percutaneous closure is performed.

## Case Report

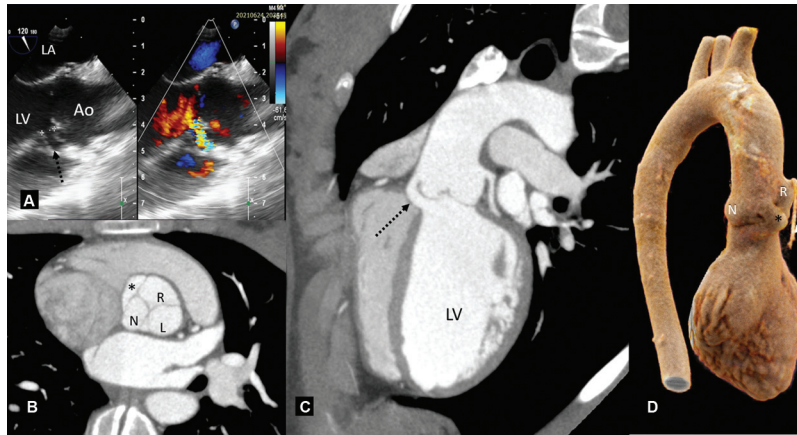
A 13-year-old girl presented with New York Heart Association Functional Class II dyspnea on exertion for the past 6 months. Physical examination revealed an end-systolic and end-diastolic murmur at the left upper sternal border. A transesophageal

echocardiogram showed abnormal paravalvular communication between the aorta and left ventricle (▶ Fig. 1A). Prospective gated cardiac computed tomography (CT) was performed in a 256-slice CT scanner (Brilliance iCT, Philips Healthcare, Cleveland, United States) after injection of 50 mL of iodixanol contrast at a rate of 4 mL/s, followed by 20 mL of contrast at 40% dilution at 2.5 ml/s as a contrast chaser using the bolus tracking technique with a threshold in the descending aorta at 140 Hounsfield Unit in a 38 kg child. Contrast-enhanced cardiac CT showed that the connection between the aorta is slit-shaped and arises just above the sinotubular junction and runs between the right and non-coronary sinuses of the aortic valve to connect with the left ventricular outflow tract, which was consistent with an ALVT (▶ Fig. 1B–D). The tunnel did not deform the aortic valves or the right ventricular outflow tract. There were no other anomalies of the coronary arteries or the aortic valve. Due to the simple tunnel-like morphology of ALVT, an option for percutaneous treatment was offered in the interdisciplinary meeting, which was preferred over surgery by the patient's

article published online  
September 5, 2023

DOI <https://doi.org/10.1055/s-0043-1772693>.  
ISSN 0971-3026.

© 2023. Indian Radiological Association. All rights reserved.  
This is an open access article published by Thieme under the terms of the Creative Commons Attribution-NonDerivative-NonCommercial-License, permitting copying and reproduction so long as the original work is given appropriate credit. Contents may not be used for commercial purposes, or adapted, remixed, transformed or built upon. (<https://creativecommons.org/licenses/by-nc-nd/4.0/>)  
Thieme Medical and Scientific Publishers Pvt. Ltd., A-12, 2nd Floor, Sector 2, Noida-201301 UP, India



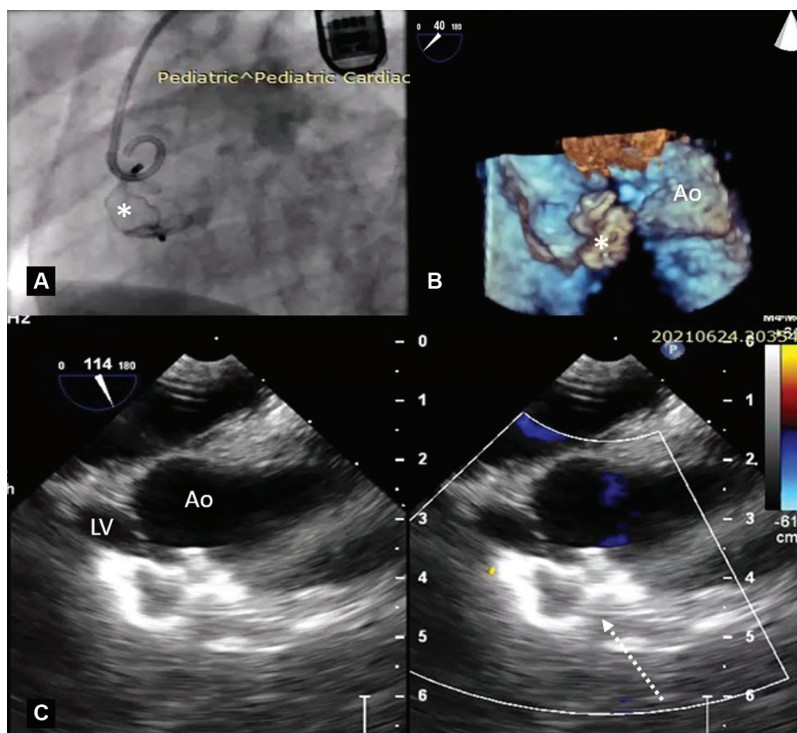
**Fig. 1** (A) Color compare TEE image in 120-degree angulation showing slit-like communication (black dotted arrow) between aorta and LV. A prospective gated cardiac CT in oblique axial (B), oblique coronal (C), and cinematic rendered RAO projections (D) show small slit-like paravalvular communication (\* in B and D; black dotted arrow in C) between the aorta just above the sinotubular junction and the left ventricular outflow tract, between the right and noncoronary sinuses. The left ventricle is dilated due to aortic regurgitation (C). The aortic valve shows a normal tricuspid morphology (B), and the right coronary artery (white arrow in D) has no anomalies. Ao, aorta; L, left coronary sinus; LA, left atrium; LV, left ventricle; N, noncoronary sinus; R, right coronary sinus; RAO, right anterior-oblique; TEE, transesophageal echocardiogram.

relatives. She successfully underwent an ALVT endovascular occlusion (→ Fig. 2A–C), with symptoms resolving at follow-up.

## Discussion

An ALVT is a rare anomaly, first reported by Levy et al, and has an estimated incidence of 0.03 to 0.46% among congenital heart diseases.<sup>3,4</sup> ALVT is more common compared

to its rarer counterpart of the aorto-right ventricular tunnel with an incidence of (9: 1).<sup>5</sup> ALVT is divided into four types, with type 1 ALVT being a slit-like opening at the end of the aorta without valve distortion. In types 2 and 3 of ALVT, the tunnel becomes aneurysmal at extracardiac and intracardiac locations, respectively. ALVT type 4 is a combination of types 2 and 3.<sup>5</sup> The embryology of ALVT is believed to result from maldevelopment or abnormal



**Fig. 2** Post-procedure images: (A) Fluoroscopy image in LAO projection of vascular plug (\*) deployed in ALVT with pigtail catheter positioned in ascending aorta. (B) Three-dimensional echo image of TEE in 40-degree angulation showing plug seen inside ALVT without distorting aortic root. (C) Color compare TEE image in 114-degree angulation showing complete obliteration of ALVT (white dotted arrow) between Aorta and LV. Insignificant aortic regurgitation was noted. ALVT, aorto-left ventricular tunnel; Ao, aorta; LAO, left anterior-oblique; LV, left ventricle; TEE, transesophageal echocardiogram.

separation of the endocardial cushions that give rise to the pulmonary and aortic roots.<sup>4</sup>

Bicuspid aortic valve, patent ductus arteriosus, pulmonary stenosis, left ventricular hypertrabeculations, and coronary artery anomalies are the few associations noted with ALVT.<sup>6</sup> The clinical presentation is highly variable and includes fetal death, congestive heart failure, or accidental discovery in an asymptomatic adult, although most of these cases are diagnosed before the age of five.<sup>7</sup>

The aortic end is most commonly positioned above the right coronary sinus, whereas aortic origin above the junction between the right and noncoronary sinuses as in this case is the extremely rare.<sup>6</sup>

It must be distinguished from a ruptured Valsalva sinus aneurysm, in which the aortic opening is usually below the sinotubular junction and remains entirely within the heart. A ruptured aortic root abscess is another diagnosis that must be distinguished when an irregularly circumscribed communication between the aortic sinus and ventricle is seen in the presence of significant inflammatory thickening of the aortic root.<sup>7</sup>

There is very limited literature describing the CT findings of ALVT. This case demonstrates how contrast-enhanced CT can aid in confirming the diagnosis, delineating the anatomical relationships, classifying the ALVT type, and ruling out associated coronary artery and valvular anomalies. These findings were critical in selecting percutaneous treatment and avoiding surgery.

Progression of aortic valve regurgitation has been reported in ALVT cases due to insufficient support of the aortic leaflets as the person grows. Surgery is the established treatment modality, particularly when associated with out-flow tract obstruction, coronary artery, and aortic valve anomalies. The operation consists of closing both ends of the tunnel with a patch and fixing the other anomalies.<sup>8</sup> A simple type 1 ALVT with no associated anomalies is amena-

ble for percutaneous closure with vascular plug or coils that was attempted in this case.

## Conclusion

Contrast-enhanced CT was critical in confirming the diagnosis and planning management of ALVT, a rare congenital heart disease.

### Funding

None.

### Conflict of Interest

None declared.

## References

- 1 McKay R. Aorto-ventricular tunnel. *Orphanet J Rare Dis* 2007;2:41
- 2 Chowdhury UK, Anderson RH, George N, et al. A review of the surgical management of aorto-ventricular tunnels. *World J Pediatr Congenit Heart Surg* 2021;12(01):103–115
- 3 Okoroma EO, Perry LW, Scott LP, McClenathan JE. Aortico-left ventricular tunnel. Clinical profile, diagnostic features, and surgical consideration. *J Thorac Cardiovasc Surg* 1976;71(02):238–244
- 4 Martins JD, Sherwood MC, Mayer JE Jr, Keane JF. Aortico-left ventricular tunnel: 35-year experience. *J Am Coll Cardiol* 2004;44(02):446–450
- 5 Hovaguimian H, Cobanoglu A, Starr A. Aortico-left ventricular tunnel: a clinical review and new surgical classification. *Ann Thorac Surg* 1988;45(01):106–112
- 6 McKay R, Anderson RH, Cook AC. The aorto-ventricular tunnels. *Cardiol Young* 2002;12(06):563–580
- 7 Diraneyya OM, Alhabshan F, Alghamdi A, Moafa H, Alnasef M, Kabbani MS. Aorto-left ventricular tunnel: case series of a rare disease. *Cardiol Young* 2021;31(01):47–51
- 8 Knott-Craig CJ, van der Merwe PL, Kalis NN, Hunter J. Repair of aortico-left ventricular tunnel associated with subpulmonary obstruction. *Ann Thorac Surg* 1992;54(03):557–559