





# Predicting Positive Radial Margin on Restaging MRI of Patients with Low Rectal Cancer: Can We Do Better?

Anurima Patra<sup>1</sup> Aisha Lakhani<sup>1</sup> Antony Augustine<sup>1</sup>  Priyanka Mohapatra<sup>1</sup> Anu Eapen<sup>1</sup>  
Ashish Singh<sup>2</sup> Dipti Masih<sup>3</sup> Thomas S. Ram<sup>4</sup> Mark R. Jesudason<sup>5</sup> Rohin Mittal<sup>5</sup>  
Anuradha Chandramohan<sup>1</sup> 

<sup>1</sup>Department of Radiology, Christian Medical College, Vellore, India

<sup>2</sup>Department of Medical Oncology, Christian Medical College, Vellore, India

<sup>3</sup>Department of Pathology, Christian Medical College, Vellore, India

<sup>4</sup>Department of Radiation Oncology, Christian Medical College, Vellore, India

Address for correspondence Anuradha Chandramohan, MD, FRCR, Department of Radiology, Christian Medical College, Vellore 632004, India (e-mail: anuradhachandramohan@gmail.com).

<sup>5</sup>Department of Colorectal Surgery, Christian Medical College, Vellore, India

Indian J Radiol Imaging 2024;34:85–94.

## Abstract

**Objective** The aim of this study was to characterize the tissue involving the margin and study if this information will affect margin prediction on restaging magnetic resonance imaging (MRI) in low rectal adenocarcinoma (LRC) patients treated with neoadjuvant long-course chemoradiotherapy (LCCRT).

**Methods** In this retrospective study of nonmetastatic LRC (distal margin <5 cm from the anal verge) treated with LCCRT followed by surgery, a radiologist blinded to outcome reread the restaging MRI and documented if the radial margin was involved by tumor, fibrosis, or mucin reaction using T2 high-resolution (HR) and diffusion-weighted imaging (DWI). The diagnostic performance of tumor-involving margin on restaging MRI was assessed using surgical histopathology as a reference. Interobserver agreement between three independent radiologists was assessed in a subset.

**Results** We included 133 patients (80 males and 53 females) with a mean (range) age of 44.7 (21–86) years and 82% of them had well or moderately differentiated adenocarcinoma. Baseline MRI showed T3 ( $n=58$ ) or T4 ( $n=60$ ) disease in 89% of the patients. The pathological margin was positive in 21% ( $n=28$ ) cases. In restaging MRI, the circumferential resection margin (CRM)  $\leq 1$  mm in 75.1% ( $n=100$ ) cases and MRI predicted tumor, fibrosis, and mucin reaction at the margin in 60, 34, and 6%, respectively, and histopathology showed tumor cells in 33, 14.7, and 16.6% of them, respectively. LRC with tumor-involving margin and bad response (MR tumor regression grade [mr-TRG] 3–5) on restaging MRI had fourfold increased risk of positive pathological circumferential resection margin (pCRM). There was moderate and fair inter-reader agreement for the tissue type involving the CRM ( $\kappa=0.471$ ) and mr-TRG ( $\kappa=0.266$ ),  $p < 0.05$ . The use of both distance criteria and tumor-involving margins improved the diagnostic accuracy for margin prediction from 39 to 66% on restaging MRI.

## Keywords

- ▶ restaging MRI
- ▶ low rectal cancer
- ▶ margins
- ▶ CRM
- ▶ DWI

article published online  
September 16, 2023

DOI <https://doi.org/10.1055/s-0043-1774300>.  
ISSN 0971-3026.

© 2023. Indian Radiological Association. All rights reserved.  
This is an open access article published by Thieme under the terms of the Creative Commons Attribution-NonDerivative-NonCommercial-License, permitting copying and reproduction so long as the original work is given appropriate credit. Contents may not be used for commercial purposes, or adapted, remixed, transformed or built upon. (<https://creativecommons.org/licenses/by-nc-nd/4.0/>)  
Thieme Medical and Scientific Publishers Pvt. Ltd., A-12, 2nd Floor, Sector 2, Noida-201301 UP, India

**Conclusions** Margin prediction on restaging MRI can be improved by characterizing the tissue type involving the margin in low rectal cancer patients. The inter-reader agreement was moderate for determining the tissue type.

## Introduction

Total mesorectal excision (TME) decreased the rates of local recurrence from 30 to 10%, and this was further reduced to 6% with the use of preoperative neoadjuvant chemoradiotherapy (CRT).<sup>1</sup> However, low rectal adenocarcinomas (LRCs), defined as tumors within 5 to 6 cm of the anal verge, have a higher risk of local recurrence and poorer outcomes compared with mid and high rectal cancers. This has been attributed to higher rates of incomplete tumor resection and positive margins.<sup>2–5</sup>

Studies in the past have shown that low rectal cancers (LRCs), anterior tumor location, T4 stage, extramural venous invasion (EMVI), and positive circumferential resection margin (CRM) on staging MRI independently increase the risk of positive surgical resection margin.<sup>6</sup> Other findings known to increase the risk of recurrence include dissection within the plane of mesorectal fascia, perforated specimen, postoperative leak, and histological characteristics such as tumor budding and poorly differentiated tumor histology.<sup>7,8</sup>

The Magnetic Resonance Imaging and Rectal Cancer European Equivalence (MERCURY) study group showed a specificity of 92% for the prediction of negative resection margin on restaging MRI after neoadjuvant chemoradiotherapy (NCRT).<sup>9</sup> However, similar findings could not be reproduced in other studies.<sup>10</sup> Predicting CRM and surgical plane safety on restaging MRI in low rectal patients is particularly challenging, and overstaging is common.<sup>11</sup> This is due to little mesorectal fat around the low rectum due to the natural tapering of the conical-shaped mesorectal space, obliteration of the tissue planes by fibrosis or mucin reaction that follows neoadjuvant therapy, and difficulty in identifying residual tumor amidst fibrosis.<sup>11</sup> Diffusion-weighted imaging (DWI) is known to be helpful in differentiating a tumor from a fibrosis and a combination of T2 high-resolution (HR) + DWI was shown to be better at finding the complete response to neoadjuvant CRT.<sup>12–14</sup> There is only one prior study that showed promising results with the use of DWI along with T2-HR in predicting CRM in the restaging setting.<sup>15</sup> Thus, in this study, we aimed to characterize the type of tissue involving the radial margin on restaging MRI of patients with LRC treated with NCRT using T2-HR images and DWI in patients. We studied whether consideration of the tissue type involving the radial margin in LRC patients improves the diagnostic performance of margin prediction on restaging MRI with surgical pathology as the reference.

## Materials and Methods

### Setting

This was an institutional review board approved (IRB min no. 12981) retrospective study conducted by the departments of

radiology, radiation oncology, pathology, and colorectal surgery of a tertiary care referral center. Informed consent was waived due to the retrospective nature of the study.

### Management Protocol

All biopsy-proven rectal adenocarcinomas underwent staging MRI according to standard guidelines.<sup>16</sup> LRCs were staged using the American Joint Committee on Cancer (AJCC)/Union for International Cancer Control (UICC), 8th edition, of TNM (tumor size, node involvement, and metastasis status) staging of colorectal cancers and LRC staging,<sup>17</sup> and surgical plane safety was reported in a structured format.<sup>18</sup> All the treatment decisions were taken in the weekly subspecialty colorectal multidisciplinary tumor board meetings. Patients underwent neoadjuvant long-course chemoradiotherapy (LCCRT) based on CRM involvement, extramural spread, presence of EMVI, TNM stage, LRC, and presence of lateral pelvic nodes on staging MRI. Standard LCCRT protocol included 45- to 50-Gy radiation in 25 to 28 fractions with a 5.4-Gy boost with an intravenous 5-fluorouracil infusion or oral capecitabine in standard radiosensitizing doses. Restaging MRI was usually performed 9 to 10 weeks following completion of neoadjuvant LCCRT and preceded 7 to 10 days prior to surgery. Patients who progressed on neoadjuvant treatment were given more chemotherapy and the rest underwent abdominoperineal excision (APE), extralevator APE (ELAPE), or ultralow anterior resection based on surgical planes and distance from the anorectal junction.

### Patients

Patients who underwent surgery for LRC between January 2014 and December 2018 were identified from a colorectal surgical database. Consecutive patients with LRC who underwent neoadjuvant LCCRT followed by surgery were included in the study. Patients who underwent upfront surgery, local excision type surgery, beyond TME type exenterating or palliative surgeries, or pan proctocolectomy; those who underwent a short course NCRT or chemotherapy alone; and those who had metastases at presentation and those with inadequate quality DWI on restaging MRI were excluded. We have reported part of the current study ( $n = 97$ ) in another work of ours that aimed at assessing the prognostic significance of EMVI, tumor deposit, lymph nodes, and pelvic side wall (PSW) disease in locally advanced rectal cancer.<sup>19</sup> In our previous study, we reported data pertaining to the stage; prognostic category variables such as EMVI, CRM, tumor deposits, PSW nodes, and mesorectal nodes; and the response. The specific aim of the current study was to identify imaging findings that help in predicting margin status in LRC treated with neoadjuvant therapy. Our previous study was not designed to address this question.

### Magnetic Resonance Imaging Protocol

All the patients underwent MRI scans in 1.5-T (Siemens Healthcare, Erlangen, Germany) or 3-T (Philips Healthcare, Best, the Netherlands) scanners using the standard imaging protocol.<sup>12</sup> No bowel preparation was given. No spasmolytics were used. T2-HR MRI of the pelvis was performed in sagittal, oblique axial (perpendicular to the rectum and the anal canal bearing the tumor), and oblique coronal (parallel to the anal canal bearing the tumor) planes. We obtain two sets of T2-HR oblique axial images for LRCs: one perpendicular to the low rectum and another perpendicular to the anal canal since low rectal tumors usually straddle the anorectal junction and often the anal canal and the low rectum are in different axes. We obtain coronal HR images parallel to the plane of the anal canal and use them to assess puborectalis and levator ani infiltration.

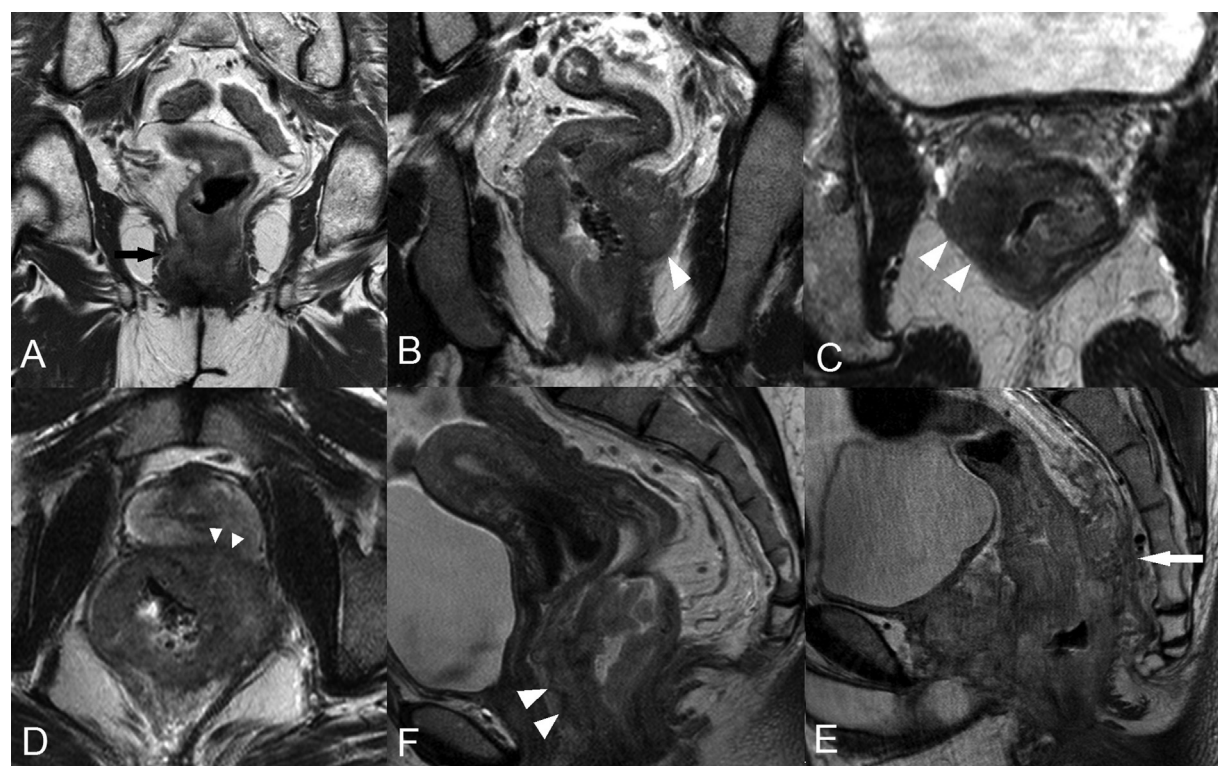
Axial DWI was obtained using respiratory-triggered, single-shot echoplanar imaging with  $b$ -values of 0, 400, and 800 s/mm<sup>2</sup>. High  $b$ -value DWI was optimal for interpretation when signals of bladder contents were well suppressed, and images devoid of motion-related artifacts or susceptibility artifacts from the air in the rectal lumen.

### Image Interpretation

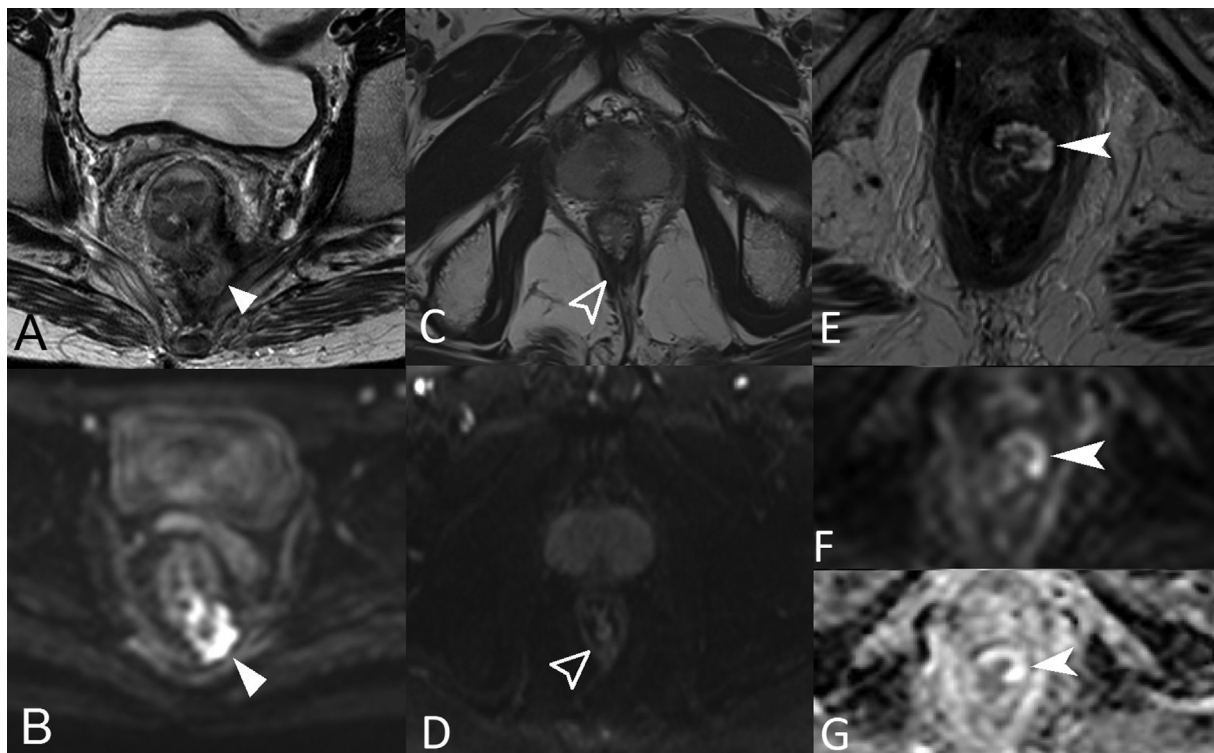
An experienced radiologist blinded to the surgical findings and outcome reread the restaging MRI on picture archiving and communication system (GE Health System, Barrington, IL, United States). Staging MRI was available for comparison.

Margins and surgical plane safety (intersphincteric plane) were assessed on staging MRI using axial and coronal T2-HR images (►Fig. 1). CRM or radial margin for LRC was defined as the least distance between one of the following: leading margin of tumor, significant node, tumor deposit, extramural vascular invasion, and the adjacent structures such as mesorectal fascia, puborectalis, levator ani muscle, prostate or seminal vesicles in males, and vagina in females.<sup>20</sup> A distance of less than 1 mm was considered as an involved CRM.<sup>9</sup> The degree of anal canal infiltration in terms of the anal sphincter and intersphincteric plane infiltration was also documented.

A judgment on whether the radial margin was involved by tumor, fibrosis, or mucin reaction was made using a combination of T2-HR and DWI and documented. Tumor was diagnosed when there was intermediate signal intensity on T2-HR images and/or diffusion restriction. Fibrosis was diagnosed when the scar tissue was homogeneously hypointense on T2-HR images and there was no restricted diffusion. When there was tumor and fibrosis involving CRM, this was labeled as a tumor. Mucin reaction was diagnosed when the mucin pool was homogeneously hyperintense on T2-HR images and showed facilitated diffusion. Since it is not possible to reliably differentiate mucinous tumors from acellular mucin pool, care was taken to diagnose mucin pool/reaction only when the primary tumor was not T2-hyperintense or mixed in signal intensity. ►Fig. 2 shows examples of tumor, fibrosis, and mucin reactions. ►Supplementary Table S1 (available in online version only) summarizes the MRI interpretation.



**Fig. 1** T2 high-resolution coronal and axial images showing examples of unsafe surgical planes on staging magnetic resonance imaging (MRI). (A) Involved intersphincteric plane (black arrow) in stage T3 low rectal cancer. (B,C) Two examples of the puborectalis and levator ani infiltration (arrowheads) in T4b, stage T4 low rectal cancer. (D) Prostate infiltration (arrowheads). (E) Vaginal infiltration (arrowheads). (F) Presacral fascial infiltration (arrow).



**Fig. 2** Examples of restaging magnetic resonance imaging (MRI) of low rectal cancer patients showing tumor, fibrosis, and mucin reaction involving the circumferential resection margin (CRM)/surgical plane. (A,B) T2 high-resolution (HR), high  $b$ -value ( $b = 800$ ) diffusion-weighted imaging (DWI) showing intermediate-signal diffusion-restricting residual tumor (arrowheads) involving the CRM. (C,D) T2-HR, high  $b$ -value ( $b = 800$ ) DWI showing T2 markedly hypointense soft tissue (arrows) with no diffusion restriction involving the puborectalis. (E–G) Axial T2-HR, DWI ( $b = 800$ ) and ADC map show mucin reaction, which is a T2-hyperintense signal in the left anterior wall of the low rectum (arrowhead in E) with facilitated diffusion (arrowheads in F and G).

We documented puborectalis and adjacent structure infiltration. The criteria used for the infiltration of adjacent structures were the loss of contiguity between the tumor-bearing portion of the low rectum and the adjacent structures, loss of contour, or replacement of adjacent structures by tumor tissue. The focal abutment meant a focal loss of plane but with maintained signal intensity and contour of adjacent structures. Such a focal abutment was not read as infiltration but documented as an unsafe surgical plane.

Other findings such as distance from the anal verge, TNM stage, EMVI, tumor deposits, and PSW disease on both staging and restaging MRI were documented. We used T2 + DWI criteria for determining response in terms of MR-TRG on restaging MRI.<sup>12</sup>

Multireader variability was assessed on a subset ( $n = 25$ ) of LRC MRI. Three independent radiologists (2–5 years of experience in abdominal radiology and training in rectal cancer MRI) other than the primary readers who were not involved in primarily reporting these MRI studies systematically documented y-mr-T stage, y-mr-N stage, MR-TRG, and CRM, and noted if CRM was involved by fibrosis, mucin reaction, or tumor.

#### Reference Standard

Surgical histopathology was the reference standard. The staging was performed in accordance with the 7th edition of the AJCC guidelines, and we noted that there was no

change in the T stage between the 7th and 8th editions of the AJCC. The pathological response was assessed using Mandard's grading system. Pathological circumferential resection margin (pCRM) was considered involved if the tumor was found within 1 mm of the resection margin. Surgical specimens were assessed for completeness of the TME using previously published criteria for assessing the quality of the TME. Complete specimens had smooth intact mesorectum, defect less than 5 mm, no coning, and smooth regular CRM. The specimens were labeled as incomplete if there was one of the following: little mesorectal bulk, defects till the muscularis propria, coning, or irregular CRM.

#### Demographic and Follow-Up Data

Demographic data, histopathology type, details of neoadjuvant therapy, surgery, and surgical histopathology were obtained from electronic medical records.

#### Statistical Analysis

Descriptive statistics were reported as mean (standard deviation [SD]) and range for continuous variables and number with percentage for categorical variables. Association between imaging findings and pathological margin in LRC was determined using an independent sample  $t$ -test, nonparametric Mann-Whitney  $U$  test, and Pearson's chi-squared test. The binary logistic regression analysis was used to identify the best imaging predictors of the surgical margin. The prevalence of



tumor, fibrosis, and mucin reaction involving margin and the chance of them showing tumor cells at histopathology was expressed in percentage. The diagnostic performance of using a tumor involving margin on restaging MRI to predict the pathological margin was assessed using a 2 × 2 contingency table and compared with the diagnostic performance of predicting margin based on distance alone. Fleiss multirater kappa statistics were used to calculate interobserver agreement between three independent radiologists. All statistical analyses were performed using IBM SPSS Analytics 22.0 software.

## Results

### Patient Demographics

► **Fig. 3** shows the consort flowchart of patients included and excluded from the study. A total of 133 patients with a mean age of 44.7 ± 13.2 years (range: 21–86 years) fulfilled the inclusion criteria. ► **Table 1** summarizes the patient demographics.

### Tumor Characteristics on Staging MRI

Baseline tumor characteristics have been summarized in ► **Table 1**. The majority (89%) of patients had T3 (*n* = 58) or T4 (*n* = 60) stage disease. Twenty-five percent had N1/N2 stage pelvic lymph nodes. CRM was involved in 97% (by a tumor in *n* = 123 and by EMVI in *n* = 6). Diagnostic quality DWI was available in 126 patients. Of these, 63% of tumors

**Table 1** Patient demographics

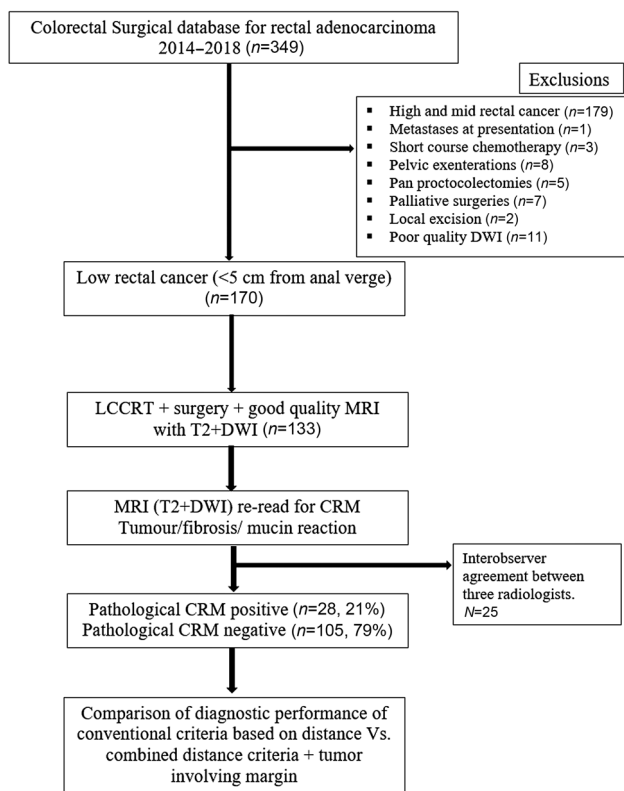
Patient and baseline tumor features	N = 133
Age (y)	44.7 ± 13.2 (range: 21–86)
Gender (males/females)	80/53
Biopsy	
Well or moderately differentiated carcinoma	109 (82%)
Poorly differentiated or mucin or signet ring cell cancers	24 (18%)
Length of tumor	52 ± 15 mm
Distance from anal verge	23 ± 12 mm
T2 signal	
Intermediate	99 (74.4%)
Hyperintense	20 (15%)
Mixed signal	14 (10.6%)
Annular	77 (57.8%)
Semi-annular	56 (42.2%)
T stage	
T2	15 (11.2%)
T3	58 (43.6%)
T4	60 (45.2%)
N stage	
N0	41 (30.8%)
N1/N2	33 (24.8%)
N1c	59 (44.4%)
CRM involved	129 (97%)
EMVI	44 (33%)
Tumor deposits	59 (44.3%)
Pelvic sidewall disease	24 (18%)
Intersphincteric plane	58 (43.6%)
Puborectalis	81 (60.9%)
Levator plate	38 (28.5%)
Presacral fascia	17 (12.7%)
Prostate/SV	12 (25.9% males)
Vagina/cervix/uterus	12 (42% females)
Perforated cancer	3 (8.1%)

Abbreviations: CRM, circumferential resection margin; EMVI, extramural venous invasion.

showed restricted diffusion (high signal on B800, low signal on apparent diffusion coefficient [ADC] map), 21% had facilitated diffusion (high signal on both B800 and ADC map), 11% had mixed signal with areas of diffusion restriction and facilitated diffusion, and 5% showed no restricted diffusion (low signal on B800 and ADC map).

### Tumor Characteristics on Restaging MRI

Tumor characteristics assessed on T2-HR + DWI are summarized in ► **Table 2**. There was significant downstaging



**Fig. 3** Flowchart of consort statement showing patients included and excluded from the study. CRM, circumferential resection margin; DWI, diffusion-weighted imaging; LCCRT, long-course chemoradiotherapy; MRI, magnetic resonance imaging.

**Table 2** Comparison of restaging imaging findings of patients with positive and negative pCRM

Restaging MRI	Positive pathological CRM, N = 28 (%)	Negative pathological CRM, N = 105 (%)	p-Value
Tumor length	42.3 ± 16.1 mm	35.2 ± 14 mm	0.062
Distance from anal verge	30.9 ± 17.8 mm	35 ± 13.1 mm	0.428
Distance from ano-rectal junction.	7.8 ± 10.4 mm	8.8 ± 10.3 mm	0.659
T stage			
T0	2 (7.1)	23 (21.9)	0.044
T1	0	2 (1.9)	
T2	3 (10.7)	18 (17.1)	
T3	13 (46.4)	48 (45.7)	
T4	10 (35.7)	14 (13.3)	
N stage			
N0	13 (46.4)	79 (75.2)	0.003
N1/N2 or N1c	15 (53.6)	26 (24.8)	
ymr-EMVI	10 (35.7)	21 (20)	0.081
Tumor deposits	9 (32.1)	17 (16.2)	0.059
Pelvic sidewall disease	4 (14.3)	9 (8.6)	0.279
CRM involved by			
Tumor	20 (71.4)	40 (38.1)	0.002
Fibrosis	5 (17.9)	29 (27.6)	0.212
Mucin reaction	1 (3.6)	5 (4.8)	0.629
Intersphincteric plane	14 (50)	37 (35.2)	0.153
Puborectalis	11 (39.3)	21 (20)	0.034
Presacral fascia	2 (7.1)	1 (1)	0.112
Prostate/SV	2 (7.1)	5 (4.8)	0.455
Vagina	0	2 (1.9)	0.622
Perforated cancer	2 (7.1)	2 (1.9)	0.195
mr-TRG			
1–2 (good)	2 (7)	35 (33)	0.003
3–5 (bad)	26 (93)	70 (67)	

Abbreviations: CRM, circumferential resection margin; EMVI, extramural venous invasion; MRI, magnetic resonance imaging; mr-TRG, MRI-based tumor regression grade; SV, seminal vesicle.

following LCCRT with ymrT0 in 19% ( $n = 25$ ), T1/T2 in 17% ( $n = 23$ ), T3 in 46% ( $n = 61$ ), and T4 in 18% ( $n = 24$ ). The ymrN stage was N0 in 69%, N1 in 11%, and N1c in 19%. On staging MRI, CRM was involved in 97% ( $n = 129$ ) of patients and on restaging MRI, CRM was involved in 75% ( $n = 100$ ). There was persistent involvement of the intersphincteric plane in 38% ( $n = 51$ ), puborectalis/levator plate in 24% ( $n = 32$ ), and presacral fascia in 2.3% ( $n = 3$ ). EMVI was noted in 23% ( $n = 31$ ), tumor deposits in 19% ( $n = 26$ ), and PSW disease in 10% ( $n = 13$ ) patients. There was a good response (MR tumor regression grade [mr-TRG] 1–2) in 28% ( $n = 37$ ) and a bad response (mr-TRG 3–5) in the remaining 72% ( $n = 96$ ).

### Surgery, Surgical Histopathology, and Patient Outcome

Of the 133 patients, 87 patients underwent standard APE, 2 patients underwent intersphincteric APE, 23 patients under-

went ELAPE, and 21 patients underwent ultralow anterior resection. The surgical specimen was complete in 87.2% ( $n = 116$ ) and incomplete in 12.7% ( $n = 17$ ). The specimen was perforated in 9.7% ( $n = 13$ ). The rate of pathological complete response was 12%. pCRM was positive in 21% ( $n = 28$ ) of patients. Of those with positive margins, the anterior margin was positive in 14 patients, the posterior margin in 12 patients, lateral margins in 7 patients, and the distal margin in 10 patients. There was no association between the completeness of the surgical specimens and pCRM ( $p = 0.113$ ).

### Association between MRI Findings and pCRM

–Tables 1 and 2 summarize the association between the tumor characteristics on staging and restaging MRI with pCRM. There was no statistically significant association

between surgical margins and age ( $p=0.149$ ), gender ( $p=0.615$ ), histopathological type of rectal cancer ( $p=0.610$ ), and baseline MRI findings (►Table 1). In restaging MRI, CRM involvement by a tumor on T2-HR + DWI ( $p=0.002$ ), puborectalis infiltration ( $p=0.034$ ), T stage ( $p=0.04$ ), persistent nodes or tumor deposits ( $p=0.003$ ), and good versus bad response ( $p=0.005$ ) significantly correlated with positive pCRM. In all, 35.7% ( $n=10$ ) of patients with pCRM showed persistent EMVI on restaging MRI, but there was no significant association with the surgical margin. A multivariate analysis showed that the radial margin involved by the tumor ( $b$ -value of 1.5,  $p=0.03$  with odds ratio of 4.6) determined with combined T2-HR + DWI criteria was the only imaging finding that was predictive of the margin status. Good versus bad response as determined by mr-TRG only had a trend toward significant association with margin status ( $b$ -value of 1.4,  $p=0.07$  with odds ratio of 4.2).

### Prevalence of Tumor, Fibrosis, and Mucin Reaction Involving Margin

Of the 100 patients with involved margin on restaging MRI, the margin was involved by the tumor in 60 patients, fibrosis in 34 patients, and mucin reaction in 6 patients. The tumor, fibrosis, and mucin reaction reported on restaging MRI had tumor cells at pathology in 33% (20 of 60), 14.7% (5 of 34), and 16.6% (1 of 6) patients.

### Effect of the Modified Definition of Involved Margin on Restaging MRI

The diagnostic accuracy for predicting pCRM on restaging MRI improved from 39% to 66% when distance criteria was combined with tumour involving the margin (►Table 3). Similarly, the positive likelihood ratio (LR+) for predicting

margin improved (►Table 3). Since the type of surgery could influence the rate of positive margins at pathology, a subgroup analysis of only the patients who underwent standard abdominoperineal resection (APR;  $n=87$ ) was performed. The pCRM rate among them was 27.6% ( $n=24$ ), which was like the entire cohort. Restaging MRI showed involved margins in 77% of patients who underwent standard APR and out of them MRI identified tumor involved the margins in 50.6% ( $n=44$ ) of patients. Using a combination of tumor involving the margin along with the distance criteria improved the diagnostic accuracy for predicting pCRM from 47 to 62% among patients who underwent standard APR (►Table 3).

### Interobserver Agreement between Three Independent Readers

The inter-reader agreement was fair for assigning y-mr-T ( $\kappa=0.369$ ), y-mr-N stages ( $\kappa=0.271$ ), and mr-TRG ( $\kappa=0.266$ ;  $p<0.05$ ). The proportion of restaging MRI that was reported as involving CRM ranged between 84 and 100%. There was substantial agreement among radiologists for determining if CRM was involved or not ( $\kappa=0.641$ ) and moderate agreement among them for determining the type of tissue involving CRM ( $\kappa=0.471$ ,  $p<0.001$ ). ►Table 4 summarizes the results of multireader variation.

### Discussion

We had set out to determine if characterizing the type of tissue involving the radial margin on restaging MRI could positively predict pathological margins on restaging MRI of patients with LRC treated with NCRT and surgery. In this study of 133 patients with LRC, we found tumor, fibrosis, and mucin reaction involved margins in 45, 25.5, and 4.5% of

**Table 3** Comparison of the diagnostic performance of margin prediction using conventional distance criteria alone with tumor involving margin on restaging MRI

	All patients ( $N=133$ )		Standard APR only ( $N=87$ )	
	Distance criteria only	Tumor involving margin	Distance criteria only	Tumor-involving margin
TP	28	23	21	16
FP	81	40	46	28
TN	24	65	20	38
FN	0	5	0	5
Sensitivity	100%	82.1%	100%	76.1%
Specificity	22%	62%	30.3%	57.5%
PPV	26%	36.5%	31.3%	36.3%
NPV	100%	93%	100%	88.3%
Accuracy	39%	66%	47.1%	62%
LR+ for positive pCRM	1.3	2.2	1.43	1.80
LR- for positive pCRM	0	0.29	0	0.41

Abbreviations: APR, abdominoperineal resection; FN, false negative; LR, likelihood ratio; NPV, negative predictive value; pCRM, pathologic circumferential resection margin; PPV, positive predictive value; TN, true negative.

**Table 4** Multirater variability in a subset ( $n = 25$ )

	Reader 1, N (%)	Reader 2, N (%)	Reader 3, N (%)	Fleiss multirater, kappa, p-Value
<b>y mr-T stage</b>				
T0	–	–	0	0.369, <0.001
T1/T2	2 (8%)	5 (20%)	9 (36%)	
T3	23 (92%)	16 (64%)	13 (52%)	
T4	–	4 (16%)	3 (12%)	
<b>y mr-N stage</b>				
N0	19 (76%)	13 (52%)	20 (80%)	0.271, $p = 0.005$
N1/N2	6 (24%)	12 (48%)	5 (20%)	
<b>mr-TRG</b>				
1: complete response	–	1 (4%)	3 (12%)	0.266, $p < 0.001$
2: near-complete response	7 (28%)	7 (28%)	4 (16%)	
3–5: incomplete response	18 (72%)	17 (68%)	18 (72%)	
CRM involved	25 (100%)	21 (84%)	21 (84%)	0.641, $p < 0.001$
<b>CRM involved by</b>				
Tumor	11 (44%)	14 (56%)	14 (56%)	0.471, $p < 0.001$
Fibrosis	12 (48%)	10 (40%)	9 (36%)	
Mucin reaction	2 (8%)	1 (4%)	2 (8%)	

Abbreviations: CRM, circumferential resection margin; mr-TRG, MRI-based tumor regression grade.

patients, respectively, and tumor cells were found at pathology in 33, 14.7, and 16.6% of them, respectively. By using tumor involving margins on restaging MRI, the LR+ for predicting positive margins improved from 1.3 to 2.2. Despite tradeoffs between sensitivity and specificity, the overall accuracy improved to 66 from 38%. This is because of the value addition brought by DWI by accurately differentiating tumor and posttreatment fibrosis, which can be indistinguishable on T2-HR images alone.

Accurate margin prediction in LRC patients is clinically relevant. This can help in choosing the right patients for ELAPE and beyond TME-type surgeries and prevent extensive surgeries, which might be undertaken because of overstaging and overcalling of margin involvement on restaging MRI. This is related to the challenges in differentiating between posttreatment fibrosis and residual tumor and compounded by posttreatment-related intense desmoplastic reactions that obliterate the tissue planes. Thus, knowledge of the type of tissue involving the margin and the proportion of tumor, fibrosis, and mucin reaction identified on MRI (T2 + DWI) that may have tumor cells in pathology can help the surgeons make an informed decision regarding the type of surgery (TME vs. beyond TME) and the plane of dissection, especially in LRCs.

A meta-analysis of 1,556 patients had shown an overall sensitivity of 76%, specificity of 86%, LR+ of 5.4, and LR– of 0.28 for predicting CRM on restaging MRI. However, there was severe heterogeneity in the results, with sensitivity varying between 21 and 97% ( $I^2 = 86.3\%$ ) and specificity varying between 43 and 100% ( $I^2 = 46.2\%$ ).<sup>10</sup> This heteroge-

neity in the results could have been due to the differences in the tumor height, tumor stage, and inherent difficulty in differentiating tumors from posttreatment fibrosis on restaging MRI. In LRC, dense posttreatment fibrosis can obliterate relevant surgical planes despite a good response to neoadjuvant therapy. This can lead to overstaging, particularly in patients who had involved CRM or unsafe surgical planes on staging MRI. The results of our study and other previous studies emphasize the influence of tumor location on the diagnostic performance of restaging MRI for predicting CRM.<sup>21,22</sup>

Our results concurred with the findings of a previous study by Park et al, which showed significant improvement in the diagnostic performance and inter-reader reliability of predicting CRM with a combination of T2-HR and DWI.<sup>15</sup> Being a study on LRC patients, the diagnostic accuracy in our study was not as high as the previous study, which had shown an accuracy of 91 to 96%.<sup>15</sup> Many previous studies demonstrated the relationship between MRI characteristics and surgical resection margin.<sup>6,10,11,18,23–26</sup> Roodbeen et al in a prospective study of 2,653 patients reported an independent positive association of T4 tumors with involved CRM on staging MRI with positive margins at surgery.<sup>6</sup> Also, anterior tumor location and positive EMVI were reported by others to be significant predictors of positive margin.<sup>6,18</sup> However, our study did not show comparable results. This could be due to the large-sized clinical T3/T4 stage tumors seen in our cohort and our results concur with previous work from a similar tertiary care referral center in India.<sup>22</sup> Our results show that involvement of margin by the



tumor as determined by T2-HR + DWI and bad response (mr-TRG 3–5) were the most useful predictors of margin status and when present was associated with fourfold increased risk of positive surgical margins in LRC patients treated with neoadjuvant therapy. There was a fair and a moderate multi-reader agreement for mr-TRG and for determining the tissue type involving CRM, respectively. It is well known that CRM is a significant prognostic marker for local recurrence, distant metastases, and overall survival. Thus, the ability to accurately predict CRM on restaging MRI will not only affect surgical planning and its outcome but also have important implications and impact on the designing of prognostic multimodal models based on language and imaging data in the future, which is especially important in a difficult-to-treat cancer such as LRC.

The limitations of our study include the use of pathology as a reference standard. Since the surgical approach and extent of surgery are guided by findings on restaging MRI, this is likely to have affected the rate of positive margins at pathology. We did not attempt to differentiate tumor and fibrosis on T2-HR images alone and thus data on the proportion of T2-HR diagnosed tumor, fibrosis, and mucin reaction with tumor cells at pathology could not be derived. We did not exclude those with incomplete surgical specimens because some coning of the specimen, irregular CRM, and little mesorectal space are expected, especially among those treated with LCCRT in advanced LRC like in our cohort. This may have influenced the result due to the less-than-perfect gold standard in a small subset. A single expert read all the MR images and multireader variability and reproducibility were assessed only on a subset. Due to the constraints of time, it was beyond the scope of the current work to have multiple readers assess the entire study cohort. Finally, our study cohort was a superselective cohort of nonmetastatic LRC patients treated with LCCRT and surgery. The majority of our cohort had large-sized clinical T3/T4 stage tumors, which reflect our practice as a referral center. Thus, the results are only applicable to similar LRC patients treated in other centers and cannot be generalized to all rectal cancers.

## Conclusion

In conclusion, identifying tissue types involving CRM on restaging MRI improves margin prediction in LRC patients. When restaging MRI showed margin involvement by tumor and bad response (mr-TRG 3 to 5), there was over fourfold higher risk of positive margin in LRC patients.

### Ethical Approval

Institutional review board approval was obtained for this article (IRB min no. = 12981, obtained on June 24, 2020).

### Informed Consent

Written informed consent was waived by the IRB.

### Funding

None.

### Conflict of Interest

None declared.

### Acknowledgments

We thank Ms. Reka Karuppusami, Lecturer in the Department of Biostatistics, Christian Medical College, Vellore, for helping us with statistical analyses.

## References

- Kim MJ, Jeong S-Y, Park JW, et al. Oncologic outcomes in patients who undergo neoadjuvant chemoradiotherapy and total mesorectal excision for locally advanced rectal cancer: a 14-year experience in a single institution. *Ann Coloproctol* 2019;35(02):83–93
- den Dulk M, Marijnen CAM, Putter H, et al. Risk factors for adverse outcome in patients with rectal cancer treated with an abdominoperineal resection in the total mesorectal excision trial. *Ann Surg* 2007;246(01):83–90
- Hiranyakas A, da Silva G, Wexner SD, Ho Y-H, Allende D, Berho M. Factors influencing circumferential resection margin in rectal cancer. *Colorectal Dis* 2013;15(03):298–303
- Warrier SK, Kong JC, Guerra GR, et al. Risk factors associated with circumferential resection margin positivity in rectal cancer: a binational registry study. *Dis Colon Rectum* 2018;61(04):433–440
- Shihab OC, Brown G, Daniels IR, Heald RJ, Quirke P, Moran BJ. Patients with low rectal cancer treated by abdominoperineal excision have worse tumors and higher involved margin rates compared with patients treated by anterior resection. *Dis Colon Rectum* 2010;53(01):53–56
- Roodbeen SX, de Lacy FB, van Dieren S, et al; International TaTME Registry Collaborative. Predictive factors and risk model for positive circumferential resection margin rate after transanal total mesorectal excision in 2653 patients with rectal cancer. *Ann Surg* 2019;270(05):884–891
- Compton CC. Pathologic prognostic factors in the recurrence of rectal cancer. *Clin Colorectal Cancer* 2002;2(03):149–160
- Guzińska-Ustymowicz K. The role of tumour budding at the front of invasion and recurrence of rectal carcinoma. *Anticancer Res* 2005;25(2B):1269–1272
- MERCURY Study Group. Diagnostic accuracy of preoperative magnetic resonance imaging in predicting curative resection of rectal cancer: prospective observational study. *BMJ* 2006;333(7572):779
- van der Paardt MP, Zagers MB, Beets-Tan RGH, Stoker J, Bipat S. Patients who undergo preoperative chemoradiotherapy for locally advanced rectal cancer restaged by using diagnostic MR imaging: a systematic review and meta-analysis. *Radiology* 2013;269(01):101–112
- Jia X, Zhang Y, Wang Y, et al. MRI for restaging locally advanced rectal cancer: detailed analysis of discrepancies with the pathologic reference standard. *Am J Roentgenol* 2019;213(05):1081–1090
- Chandramohan A, Siddiqi UM, Mittal R, et al. Diffusion weighted imaging improves diagnostic ability of MRI for determining complete response to neoadjuvant therapy in locally advanced rectal cancer. *Eur J Radiol Open* 2020;7:100223
- Schurink NW, Lambregts DMJ, Beets-Tan RGH. Diffusion-weighted imaging in rectal cancer: current applications and future perspectives. *Br J Radiol* 2019;92(1096):20180655
- Lambregts DM, Vandecaveye V, Barbaro B, et al. Diffusion-weighted MRI for selection of complete responders after chemoradiation for locally advanced rectal cancer: a multicenter study. *Ann Surg Oncol* 2011;18(08):2224–2231
- Park MJ, Kim SH, Lee SJ, Jang KM, Rhim H. Locally advanced rectal cancer: added value of diffusion-weighted MR imaging for

- predicting tumor clearance of the mesorectal fascia after neoadjuvant chemotherapy and radiation therapy. *Radiology* 2011; 260(03):771–780
- 16 Beets-Tan RGH, Lambregts DMJ, Maas M, et al. Magnetic resonance imaging for clinical management of rectal cancer: Updated recommendations from the 2016 European Society of Gastrointestinal and Abdominal Radiology (ESGAR) consensus meeting. *Eur Radiol* 2018;28(04):1465–1475
  - 17 Battersby NJ, Moran B, Yu S, Tekkis P, Brown G. MR imaging for rectal cancer: the role in staging the primary and response to neoadjuvant therapy. *Expert Rev Gastroenterol Hepatol* 2014;8(06):703–719
  - 18 Battersby NJ, How P, Moran B, et al; MERCURY II Study Group. Prospective validation of a low rectal cancer magnetic resonance imaging staging system and development of a local recurrence risk stratification model: the MERCURY II study. *Ann Surg* 2016; 263(04):751–760
  - 19 Chandramohan A, Mittal R, Dsouza R, et al. Prognostic significance of MR identified EMVI, tumour deposits, mesorectal nodes and pelvic side wall disease in locally advanced rectal cancer. *Colorectal Dis* 2022;24(04):428–438
  - 20 Shihab OC, Moran BJ, Heald RJ, Quirke P, Brown G. MRI staging of low rectal cancer. *Eur Radiol* 2009;19(03):643–650
  - 21 Kulkarni T, Gollins S, Maw A, Hobson P, Byrne R, Widdowson D. Magnetic resonance imaging in rectal cancer downstaged using neoadjuvant chemoradiation: accuracy of prediction of tumour stage and circumferential resection margin status. *Colorectal Dis* 2008;10(05):479–489
  - 22 Patra A, Baheti AD, Ankathi SK, et al. Can post-treatment MRI features predict pathological circumferential resection margin (pCRM) involvement in low rectal tumors. *Indian J Surg Oncol* 2020;11(04):720–725
  - 23 Kim SH, Lee JM, Park HS, Eun HW, Han JK, Choi BI. Accuracy of MRI for predicting the circumferential resection margin, mesorectal fascia invasion, and tumor response to neoadjuvant chemoradiotherapy for locally advanced rectal cancer. *J Magn Reson Imaging* 2009;29(05):1093–1101
  - 24 Ma X, Li X, Xu L, et al. Characteristics and prognostic significance of preoperative magnetic resonance imaging-assessed circumferential margin in rectal cancer. *Gastroenterol Res Pract* 2015; 2015:410150
  - 25 McGlone ER, Shah V, Lowdell C, Blunt D, Cohen P, Dawson PM. Circumferential resection margins of rectal tumours post-radiotherapy: how can MRI aid surgical planning? *Tech Coloproctol* 2014;18(10):937–943
  - 26 Vliegen RFA, Beets GL, Lammering G, et al. Mesorectal fascia invasion after neoadjuvant chemotherapy and radiation therapy for locally advanced rectal cancer: accuracy of MR imaging for prediction. *Radiology* 2008;246(02):454–462