



Clinical and Imaging Research in the Diagnosis of Anorectal Melanoma with Surgical Outcome: A Case Report and Literature Review

Ana Luiza Moraes Rocha¹ Gabriella Giandotti Gomar² João Pedro Cruz Lima Chagas³
Dayara Mussi Salomão¹ Luciana Clivatti⁴

¹ Department of Medicine, Pontifical Catholic University of Paraná, Curitiba, PR Brazil

² Department of Medicine, Faculdade Pequeno Príncipe, Curitiba, PR, Brazil

³ Department of Medicine, Positiv University, Curitiba, PR, Brazil

⁴ Department of Coloproctology, Santa Casa de Curitiba, Curitiba, PR, Brazil

Address for correspondence Gabriella Giandotti Gomar, Medical Student, Av. Iguazu, 333 - Rebouças, Curitiba - PR, 80230-020, Brazil (e-mail: gabriellagomar@yahoo.com).

J Coloproctol 2023;43(3):e221–e223.

Abstract

Objective This study aims to report the case of a 69-year-old female patient with a diagnosis of anorectal melanoma (AM) established by immunohistochemistry.

Methods Clinical case report, a descriptive and qualitative study.

Results The patient had a nodular and ulcerative lesion in the anal region, the imaging exams revealed an expansive lesion that affected the rectum and the vaginal wall. The chosen course of treatment was initial surgical intervention, the surgery and postoperative course progressed without complications, and the anatomopathological examination confirmed the diagnosis of invasive malignant melanoma of the distal rectum of anorectal transition. The anatomopathological examination confirmed the diagnosis of invasive malignant melanoma located in the distal rectum of the anorectal transition. Immunohistochemistry analysis showed infiltrative melanoma with microsatellites, as well as peri and intratumoral lymphocytic infiltrate, angiolymphatic invasion, and perineural invasion. The surgical resection margins, ovaries, posterior vaginal wall, and parametrium showed no signs of neoplastic involvement. Following the surgery, the patient began immunotherapy, which she is still undergoing.

Conclusions The survival rate of AM can be improved through various diagnostic and therapeutic modalities. However, further exploration of this topic through clinical studies is necessary to enhance both diagnosis and treatment.

Keywords

- ▶ Melanoma
- ▶ Neoplasms
- ▶ Anus Neoplasms
- ▶ Colorectal Surgery

Introduction

Anorectal melanoma (AM) is a type of cancer with an incidence rate of 4.8 per 10 million per year, accounting for only 0.4–1.6 percent of all malignant melanomas.¹ The condition typically

affects females who are over 60 years old and of white ethnicity. The diagnosis of AM can be challenging due to the non-specific symptoms, and it may be mistaken for other conditions such as hemorrhoids, polyps, or colorectal cancer.^{1,2}

After suspecting or confirming the diagnosis, a comprehensive evaluation should be conducted to eliminate the

Santa Casa de Curitiba, Paraná, Brasil

received
November 4, 2022
accepted after revision
June 21, 2023

DOI <https://doi.org/10.1055/s-0043-1774735>.
ISSN 2237-9363.

© 2023. Sociedade Brasileira de Coloproctologia. All rights reserved.

This is an open access article published by Thieme under the terms of the Creative Commons Attribution-NonDerivative-NonCommercial-License, permitting copying and reproduction so long as the original work is given appropriate credit. Contents may not be used for commercial purposes, or adapted, remixed, transformed or built upon. (<https://creativecommons.org/licenses/by-nc-nd/4.0/>)

Thieme Revinter Publicações Ltda., Rua do Matoso 170, Rio de Janeiro, RJ, CEP 20270-135, Brazil

possibility of metastasis, as 20–40% of cases have regional spread or metastasis during the initial diagnosis. Surgical intervention is the mainstay of treatment for anorectal melanoma. However, the prognosis remains bleak despite resection. Patients with recurrent or metastatic disease have a median survival rate of less than 10 months.^{1–3}

Clinical Case

A 69-year-old female patient with no previous comorbidities, medication use, history of smoking, alcoholism, or allergies was admitted to the coloproctology service due to the presence of a nodular ulcerative lesion in the anal region.

Despite being asymptomatic, the patient's son was diagnosed with colorectal cancer at the age of 46. As a result, she underwent laboratory tests, colonoscopy, and imaging tests for screening upon admission. The laboratory results showed an increased fecal calprotectin level of 283 mcg/g and a positive antinuclear factor. During the colonoscopy, an elevated formation was observed on the internal anal border. The formation was roughly 3 cm in diameter, rounded and hardened, and covered with fibrin. Due to the risk of bleeding, a biopsy was not performed during the exam (→Fig. 1).

Pelvic magnetic resonance imaging revealed a 25 × 19 × 16 mm expansive lesion that affected the mucosa and submucosa of the distal rectum, adjacent to the anal border. The lesion had a transmural component that infiltrated the serosa of the anterior rectum and compromised the posterior vaginal wall, forming a nodular image measuring 32 × 26 × 18 mm.

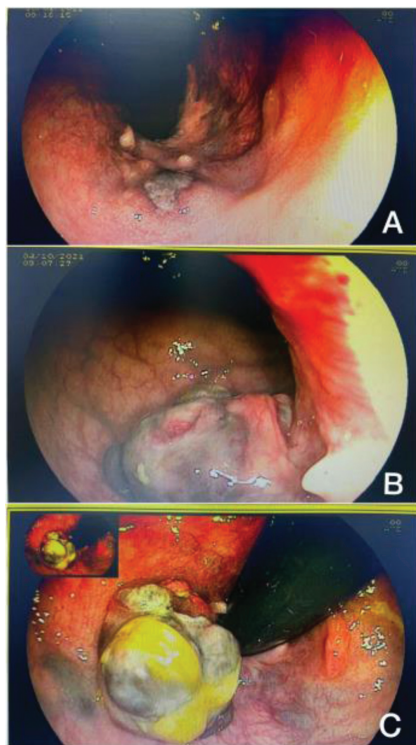


Fig. 1 Colonoscopy.
A - Colonoscopy showing ulcerated lesion in distal rectum
B - Colonoscopy of distal rectum
C - Retrovision of distal rectum

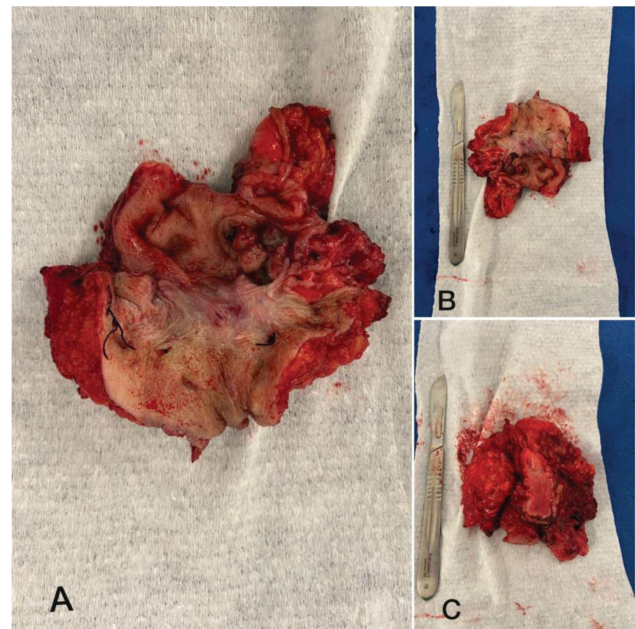


Fig. 2 Product of rectosigmoidectomy. A and B - Anatomical specimen: anorectal segment with melanoma in the distal rectum
C - Anatomical specimen: posterior wall of the vagina

The chest CT scan showed a 16 × 16 mm nodule in the left lower lobe, which was possibly a secondary lesion. The patient was referred for thoracic surgery and underwent a CT-guided lung biopsy within a month, which yielded negative results for malignancy. The CT scan of the abdomen and pelvis did not reveal any new information.

Following the anal lesion biopsy, the results showed an undifferentiated neoplasm possibly indicating sarcoma or melanoma. Subsequently, immunohistochemistry and a PET-CT scan were ordered. In January 2022, the immunohistochemistry results indicated an infiltrating melanoma in the squamous mucosa of the distal rectum. Upon discussion with clinical oncology, it was determined that neoadjuvant chemotherapy and radiotherapy would not be beneficial, and upfront surgery was initiated. After the melanoma diagnosis was confirmed, the patient reported experiencing vaginal bleeding.

Three months following admission, the patient underwent laparoscopic abdominoperineal amputation of the rectum (→Fig. 2) along with pelvic lymphadenectomy, partial vulvectomy, bilateral oophorectomy, and terminal colostomy. During surgery, there was no evidence of intraperitoneal lesion or free fluid in the cavity. A perineal amputation was performed, which involved the removal of the sphincter complex, anal canal, and extended to the posterior wall of the vagina and vulva. The reason for selecting extended surgery in this patient was due to the involvement of the vaginal wall and the anterior rectal serosa by the transmural infiltrative lesion, in addition to the vaginal bleeding and the risk of lung metastasis.

Following the surgery, the patient was admitted to the intensive care unit for one day and stayed in the hospital ward for four days with no complications.

The pathology report confirmed the diagnosis of invasive malignant melanoma in the anorectal transition area of the distal rectum. The tumor measured 1.9 cm at its maximum

extent and invaded the perirectal fat. The growth pattern was infiltrative with microsatellite present, and there was peri and intratumoral lymphocytic infiltrate. The tumor had invaded the angiolymphatic and perineural spaces. The surgical resection margins proximal and distal to the tumor were free of neoplastic involvement. Ten lymph nodes were examined, three of which showed evidence of neoplasia with extra-nodal extension. The ovaries, posterior vaginal wall, parametrium, and proximal margin of the rectosigmoidectomy were free of neoplastic involvement.

The patient received two cycles of α -interferon immunotherapy and remained stable on screening tests for six months. However, a recent discovery of a nodule in the right adrenal gland prompted the initiation of radiotherapy.

Discussion

Melanoma of the anus usually arises from the anal canal and can spread to adjacent lymph nodes, as well as distant locations such as the lungs, liver, and brain.²

Frequently, patients exhibit nonspecific symptoms such as rectal bleeding, anal pain, constipation, diarrhea, changes in bowel habit, tenesmus, pruritus, and a palpable anal mass. Hemorrhoids are the most common symptom. On average, patients experience symptoms for 4–5 months before receiving a diagnosis, and up to 8–16% of patients are only diagnosed after undergoing hemorrhoidectomy surgery.^{1–3} In this study, the patient was diagnosed within a relatively short period of time despite being asymptomatic. The patient sought medical attention after noticing a nodule near the anal border, and within six months underwent surgical treatment after further investigation.

A definitive diagnosis is usually established by biopsy and immunohistochemistry. Lesions are characterized by histological examination and the main features are epithelioid cells, high pleomorphism in the nucleus, and melanin granules.²

The optimal management approach for treating melanoma remains unclear as there are no established guidelines from randomized trials. Current treatment options include surgery, radiation therapy, chemotherapy, and immunotherapy.^{4,5}

The primary treatment for localized disease is still surgical resection, and the presence or absence of lymphatic metastasis has not been found to have a significant impact on prognosis.^{4,5}

Surgical treatments include abdominoperineal resection (APR) and extended local excision (WLE). WLE is a preferred choice due to its minimal morbidity and preservation of local function, including the anal sphincter. However, it may not be suitable for advanced cases with metastasis involving adjacent organs or complications like obstruction and bleeding. On the other hand, APR can treat adjacent organs and address complications such as bleeding, obstruction, and infiltration of the anal sphincter, but is associated with a high rate of morbidity and functional impairment.^{5–7}

For patients with early and limited disease, WLE is typically the preferred treatment option when feasible, as it preserves local function, although APR is associated with lower local recurrence rates. In this particular case, it was

decided to perform an APR due to the transmural component of the lesion and the symptom of vaginal bleeding that the patient developed after the diagnosis.⁶

Although APR was traditionally considered the best treatment option for initial disease without regional invasion, recent studies have compared conservative and radical approaches and reported not only no difference in survival, but also growing evidence suggesting that survival outcomes may be the same as those seen in patients undergoing local excision only, with the benefit of lower perioperative morbidity.^{5,6}

When primary tumors are large or distant metastases are present, palliative surgery options such as local segmental resection or bypass colostomy for bowel obstruction may be considered.⁵

In the last few decades, various adjuvant therapies have emerged as options, including immunotherapy using α -interferon, brachytherapy utilizing 117-Cesium, and chemotherapy involving dacarbazine, vincristine, and nimustine hydrochloride.⁵

The use of radiotherapy and chemotherapy did not yield favorable results in improving survival rates or enhancing the quality of life for patients. However, for individuals with mucosal melanomas and positive nodal involvement, α -interferon demonstrated a potential benefit by prolonging overall survival, indicating that immunotherapy may serve as a suitable adjuvant or neoadjuvant option.^{5,7}

In summary, AM carries a poorer prognosis due to delayed diagnosis, highlighting the need for further investigation in clinical studies to establish early diagnosis and treatment guidelines. Also, successful treatment outcomes require effective communication between surgical and clinical oncology teams.

Conflicts of Interest

The authors declare no conflicts of interest.

References

- Jutten E, Kruijff S, Francken AB, et al. Surgical treatment of anorectal melanoma: a systematic review and meta-analysis. *BJS Open* 2021;5(06):zrab107. Doi: 10.1093/bjsopen/zrab107
- de Meira Júnior JD, Sobrado LF, Guzela VM, Nahas SC, Sobrado CW. Anorectal Mucosal Melanoma: A Case Report and Literature Review. *Am J Case Rep* 2021;22:e933032. Doi: 10.12659/AJCR.933032
- Apostu RC, Stefanescu E, Scurtu RR, Kacso G, Drasovean R. Difficulties in diagnosing anorectal melanoma: A case report and review of the literature. *World J Clin Cases* 2021;9(36):11369–11381. Doi: 10.12998/wjcc.v9.i36.11369
- Husa A, Höckerstedt K. Anorectal malignant melanoma. A report of fourteen cases. *Acta Chir Scand* 1974;140(01):68–72
- Abbas JS, Karakousis CP, Holyoke ED. Anorectal melanoma: clinical features, recurrence and patient survival. *Int Surg* 1980;65(05):423–426
- Droesch JT, Flum DR, Mann GN. Wide local excision or abdominoperineal resection as the initial treatment for anorectal melanoma? *Am J Surg* 2005;189(04):446–449
- Latteri S, Teodoro M, Malaguarnera M, Mannino M, Currò G, La Greca G. Abdominal perineal resection or wilde local excision in primary anorectal malignant melanoma. Case report and review. *Ann Med Surg (Lond)* 2017;19(19):74–77