



# Pneumatic Insufflation to Confirm Distal Stoma When in Doubt

Akshay Kumar Saxena<sup>1</sup> Pavithra Subramanian<sup>1</sup> Anmol Bhatia<sup>1</sup> Kushaljit Singh Sodhi<sup>1,2</sup>

<sup>1</sup>Department of Radiodiagnosis and Imaging, Postgraduate Institute of Medical Education and Research, Chandigarh, India

<sup>2</sup>Mallinckrodt Institute of Radiology, Washington University in St. Louis School of Medicine, St. Louis, Missouri, United States

Address for correspondence Akshay Kumar Saxena, MD, Department of Radiodiagnosis and Imaging, Postgraduate Institute of Medical Education and Research, Chandigarh 160011, India (e-mail: fatakshay@yahoo.com).

Indian J Radiol Imaging 2024;34:154–155.

## Abstract

### Keywords

- ▶ colostogram
- ▶ colostomy
- ▶ distal stoma
- ▶ ileostogram
- ▶ ileostomy
- ▶ pneumatic insufflation

**Background** Distal colostogram and ileostogram are commonly performed radiological procedures in the pediatric population. It is sometimes difficult to identify the distal stoma while performing these procedures.

**Aim** The aim of this study was to describe a technique for the confident identification of distal stoma.

**Methods** Injection of a small quantity of air through the catheterized stoma and following it can help to identify the stoma, as proximal or distal, based on anatomy of the delineated bowel.

**Conclusion** Pneumatic insufflation is a simple, quick procedure to confidently identify the distal stoma whenever in doubt.

## Clinical Problem

Colostomy and ileostomy are frequently performed surgical procedures in the pediatric population for initial treatment of anorectal malformations<sup>1</sup> and for bowel perforation.<sup>2</sup> The patency of distal bowel is subsequently evaluated radiologically by distal colostogram/ileostogram. These procedures involve catheterization of distal stoma and injection of water-soluble urographic contrast agent. Difficulty is sometimes faced by radiologists in identifying the distal stoma especially if the parents/attendants are unable to point out the site from which feces exit.

## Technique

To overcome the problem of inadvertent injection of contrast into the proximal bowel, we propose that the radiologist injects a small volume of air through the catheterized stoma and follow the injected air. If it conforms to the configuration of

distal bowel (ileum/ colon), water-soluble urographic contrast agent can be injected through the same catheter. If the air passes into proximal colon/small bowel, the other stoma can be catheterized and soluble urographic contrast agent injected.

## Discussion

In the patients scheduled for distal colostogram/ileostogram, inadvertent catheterization of proximal stoma and injection of contrast may lead to opacification of the proximal bowel (▶ **Fig. 1A**). Under such circumstances, radiologists prefer to wait for the injected contrast to clear from the bowel loops to avoid diagnostic confusion. This leads to loss of time (▶ **Fig. 1B and C**), disrupts workflow, and causes inconvenience to the patient. In case there is delay in clearance of contrast from the proximal bowel (as may happen in patients scheduled for distal ileostogram), the procedure may need to be postponed to a later date causing increase in the cost of treatment (because of the necessity of visiting the radiology

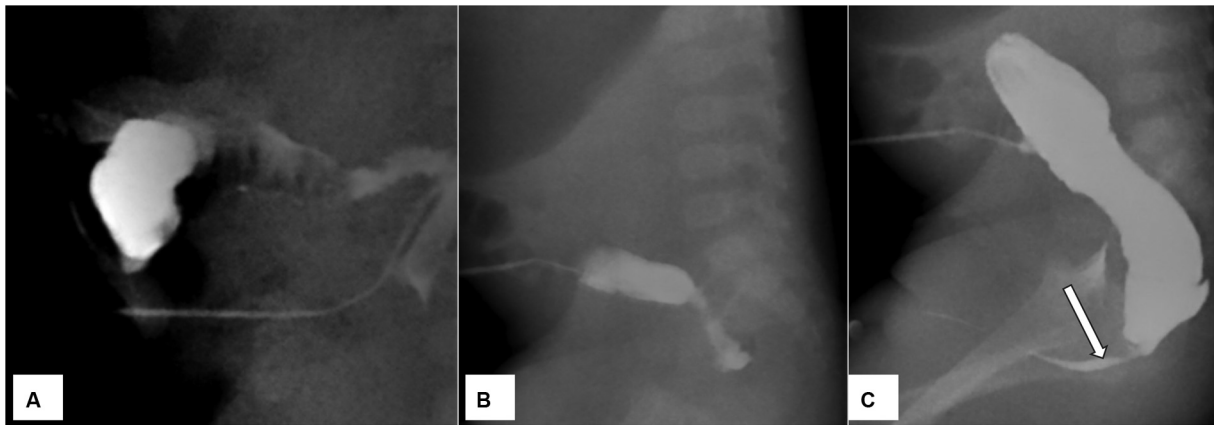
article published online  
October 10, 2023

DOI <https://doi.org/10.1055/s-0043-1774782>.  
ISSN 0971-3026.

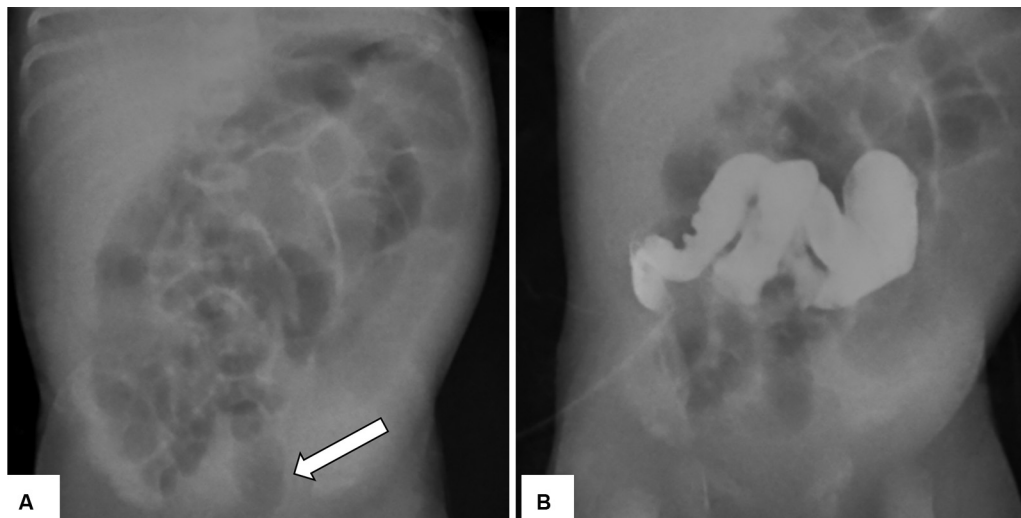
© 2023. Indian Radiological Association. All rights reserved.

This is an open access article published by Thieme under the terms of the Creative Commons Attribution-NonDerivative-NonCommercial-License, permitting copying and reproduction so long as the original work is given appropriate credit. Contents may not be used for commercial purposes, or adapted, remixed, transformed or built upon. (<https://creativecommons.org/licenses/by-nc-nd/4.0/>)

Thieme Medical and Scientific Publishers Pvt. Ltd., A-12, 2nd Floor, Sector 2, Noida-201301 UP, India



**Fig. 1** A 6-month-old infant patient, who is a follow-up case of anorectal malformation with rectourethral fistula, was referred for distal colostogram. Identification of distal stoma was done in accordance with the information provided by the parents. Injection of water-soluble urographic contrast (A) opacified the proximal colon. The catheter was removed and study repeated after a few hours by catheterizing the correct distal stoma (B and C) that showed patency of distal colon, rectourethral fistula (arrow), and clearance of contrast from the proximal colon.



**Fig. 2** In a 10-day old infant girl child (who had total colonic aganglionosis and proximal stoma negative for ganglion cells) scheduled for proximal colostogram, the identification of proximal stoma was uncertain. One of the stomas were catheterized with Foley's catheter and air injected (A). The passage of air up to the rectum (arrow) confirmed it to be distal stoma. Subsequently, the other stoma was catheterized and proximal colostogram (B) done.

department again). Further, this delays the surgical procedure for the restoration of continuity of the bowel. Our technical innovation (– Fig. 2) can help avoid these problems.

## Conclusion

In case of difficulty in identification of distal stoma, pneumatic insufflation can be of help to the radiologist.

**Conflict of Interest**  
None declared.

## References

- 1 Pena A, Migotto-Krieger M, Levitt MA. Colostomy in anorectal malformations: a procedure with serious but preventable complications. *J Pediatr Surg* 2006;41(04):748–756, discussion 748–756
- 2 Massenga A, Chibwae A, Nuri AA, et al. Indications for and complications of intestinal stomas in the children and adults at a tertiary care hospital in a resource-limited setting: a Tanzanian experience. *BMC Gastroenterol* 2019;19(01):157