



# Endoscopic Endonasal Approach to Orbital Malignant Peripheral Nerve Sheath Tumor: A Minimally Invasive Method for Rare Orbital Tumor—Case Report and Review of Literature

Praveen M. Ganigi<sup>1</sup> Arijit Chakraborty<sup>1</sup> K.M. Bopanna<sup>2</sup> Sathwik R. Shetty<sup>1</sup>

<sup>1</sup>Manipal Hospital Bangalore, Bengaluru, Karnataka, India

<sup>2</sup>Department of Neurosurgery, Manipal Hospital Bangalore, Bengaluru, Karnataka, India

**Address for correspondence** Praveen M. Ganigi, MBBS, Mch Neurosurgery (NIMHANS), Consultant Neurosurgeon, Manipal Hospital Bangalore, Bengaluru, Karnataka, India (e-mail: praveenganigi@gmail.com).

Indian J Neurosurg

## Abstract

Malignant peripheral nerve sheath tumors (MPNSTs) are uncommon tumors that rarely occur in the orbit. Malignant orbital tumors are always a challenge to remove completely. We present the case of a 42-year man with painful movement of the left eye and restriction of adduction of the left eye causing double vision. Magnetic resonance imaging (MRI) of the brain/orbit revealed intraconal tumor located inferomedial to the optic nerve. The imaging features were suggestive of schwannoma or cavernoma. Gross total resection of the tumor was done with an endoscopic endonasal intraconal approach. The histopathology revealed an MPNST. The patient received adjuvant radiotherapy and chemotherapy. His left eye adduction recovered completely and he had no local recurrence or systemic metastasis on follow-up evaluation.

## Keywords

- ▶ MPNST
- ▶ extremely rare
- ▶ malignant
- ▶ intraconal
- ▶ endoscopic transnasal
- ▶ gross total

## Introduction

The incidence of malignant peripheral nerve sheath tumors (MPNST) is approximately 0.001%,<sup>1</sup> and primary tumors are extremely rare. The most suitable treatment plan for these tumors involves excision followed by postoperative adjuvant radiotherapy and chemotherapy. Nevertheless, tumors that are primarily located in the inferior or medial part of the orbit pose a surgical challenge when using traditional transcranial or orbital approaches. While minimally invasive transnasal endoscopic approaches were utilized for intraconal lesions positioned medially and inferiorly to optic nerve, the literature contains limited reports on the efficacy of endoscopic intraorbital surgery for the removal of invasive skull base tumors.<sup>2</sup> Here we present the case of a 42-year-old gentleman with orbital MPNST located inferomedial to the optic nerve. He successfully underwent a gross total

excision of the tumor with an endoscopic endonasal intraconal approach. The patient received adjuvant radiotherapy and chemotherapy without local/systemic recurrence.

## Case Report

A 42-year-old gentleman with no known comorbidity presented with a 2-month history of painful left eye movement on looking toward the right along with double vision. On examination, there was mild ptosis and mild proptosis of the left eye with restricted left eye adduction. He had normal visual acuity. Magnetic resonance imaging (MRI) of the brain/orbit revealed intraconal lesion located inferomedial to the optic nerve, in between the inferior rectus muscle and the medial rectus muscle, extending up

DOI <https://doi.org/10.1055/s-0043-1775973>.  
ISSN 2277-954X.

© 2023. The Author(s).

This is an open access article published by Thieme under the terms of the Creative Commons Attribution License, permitting unrestricted use, distribution, and reproduction so long as the original work is properly cited. (<https://creativecommons.org/licenses/by/4.0/>)

Thieme Medical and Scientific Publishers Pvt. Ltd., A-12, 2nd Floor, Sector 2, Noida-201301 UP, India

to the orbital apex. The lesion was hypointense on T1, mixed hyper-/isointense on T2 with heterogeneous enhancement on contrast. The MRI features were suggestive of schwannoma. Cavernoma was another differential that was considered. He underwent surgical excision using an endoscopic endonasal translamina papyracea intraconal approach.

The patient was positioned supine with the head resting in a neutral position. A binostril approach was used. The left nostril was accessed initially. To get a better space for manipulation of instrumentation and direct trajectory to the tumor, posterior septectomy was done to enable a binostril approach. The lower one-third of the middle turbinate was removed to get better exposure. The ethmoid air sinuses were removed. The maxillary sinus was accessed by excising the lateral wall of the nasal cavity surrounding the uncinate process, while the orbital bone was removed inside the pathway of the infraorbital nerve. The lamina papyracea (medial wall of the orbit) was exposed and removed anterior to posterior along the optic canal. The periorbita was opened till the orbital apex. Retrobulbar fat was exposed and dissected up to the extraocular muscles. With the help of an ophthalmologist, the medial rectus muscle was tagged externally to facilitate confirmation of its intraoperative intraocular location. The tumor was noted in between the medial and inferior rectus muscles. The tumor was firm in consistency and was removed piecemeal. Gross total excision of the tumor was done.

The histopathological diagnosis was MPNST. There was complete recovery of left eye adduction and proptosis on follow-up visit. He received external radiotherapy (RT) at a dose of 54 Gy in 30 portions in 6 weeks (fractionated RT reduces chances of RT-induced optic neuropathy) and four cycles of chemotherapy with Adriamycin and ifosfamide (every 3 weeks). Positron emission tomography computed tomography (PET-CT) scan done at 3 months of follow-up was negative for systemic metastasis. The 3- and 9-month follow-up MRI showed no local recurrence (► Figs. 1–4).

## Discussion

MPNSTs are rare tumors constituting 5% of all sarcomas. Seventy percent are related to neurofibromatosis type 1 (NF-1). Typically, they originate from the peripheral nerves or somatic soft tissues in young adults (20–50 years).

MPNSTs are most prevalent in the extremities and trunk, typically affecting the sciatic nerve (the most common), brachial plexus, and sacral plexus; only 8 to 16% cases occur in the neck and head.<sup>3</sup> MPNSTs are extremely rare in the orbit, accounting for 0 to 0.2% of all orbital tumors.<sup>4</sup> To our knowledge, 42 orbital MPNST patients have been documented in the medical literature.<sup>5,6</sup> Orbital PNSTs such as schwannomas and neurofibromas were found with lid swelling and proptosis in 50%, followed by blurred vision, ptosis, and diplopia in 4 to 20%. Late indications such as visual obscuration and discomfort are potentially concerning signs of globe indentation, nerve root compression, or progression to invasive tumor forms like MPNSTs.<sup>3</sup> Clinical

differential diagnosis of PNSTs includes meningioma, cavernoma, lymphangioma, fibrous histiocytoma, hemangiopericytoma, and dermoid cyst. An increase in the rate of growth or the emergence of new discomfort is unusual for benign PNSTs and must raise suspicions of high-grade tumors or malignancies. The imaging properties of MPNSTs vary more than those of the other PNSTs. On CT, they look like well-defined lesions with adjacent bony erosion. On MRI, they are isointense on T1, and hyperintense on T2 with diffuse enhancement in contrast with some areas of intense enhancement.

In this study, we reported the case of the patient with intraconal MPNST who presented mainly with painful left eye movement along with diplopia. He also had mild ptosis and proptosis. Although the MRI features were not indicative of invasive or malignant pathology, the presence of pain indicated the same.

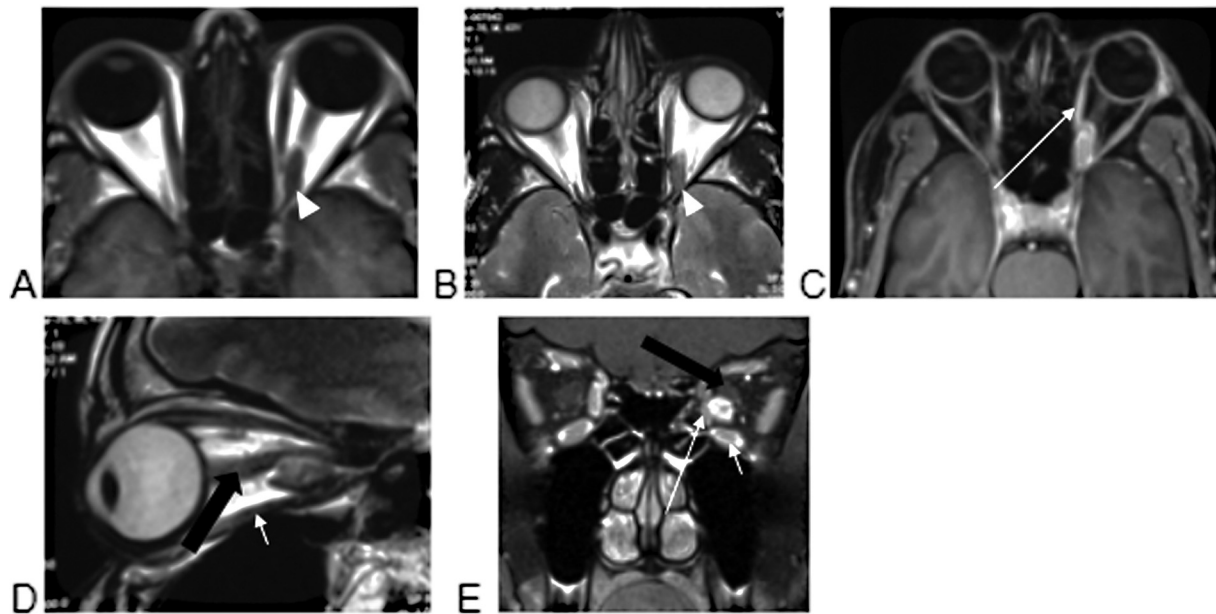
For medially located intraconal lesions, the traditional approaches like medial orbitotomy and transconjunctival approach have been limited by suboptimal exposure and scar formation and medial canthal web formation during healing.<sup>7</sup> The endoscopic endonasal technique is recommended to treat intraconal lesions that are situated inferiorly and medially to optic nerve, as was the situation in the present case research. There was a sufficient surgical corridor between the rectus muscles or between the superior oblique and medial rectus muscles on preoperative radiographic imaging. Thus, this particular tumor in our study was approached in the endoscopic transnasal route. For intraconal cancers, a large opening of the periorbital window is recommended to preserve a suitable surgical route for tumor removal.<sup>3</sup> The lesions can be easily manipulated and excised by this approach without neurological complications.<sup>7,8</sup>

As per the literature, metastases develop in 39% of patients with MPNST. von Recklinghausen's illness, tumor size greater than 5 cm, and the extent of resection are among the key features that have a negative impact on prognosis for MPNSTs. The treatment of choice is gross total excision followed by adjuvant RT and chemotherapy.<sup>1,4</sup> With this line of treatment, our patient has clinically improved with no sign of recurrence or systemic metastasis at 9 months of follow-up.

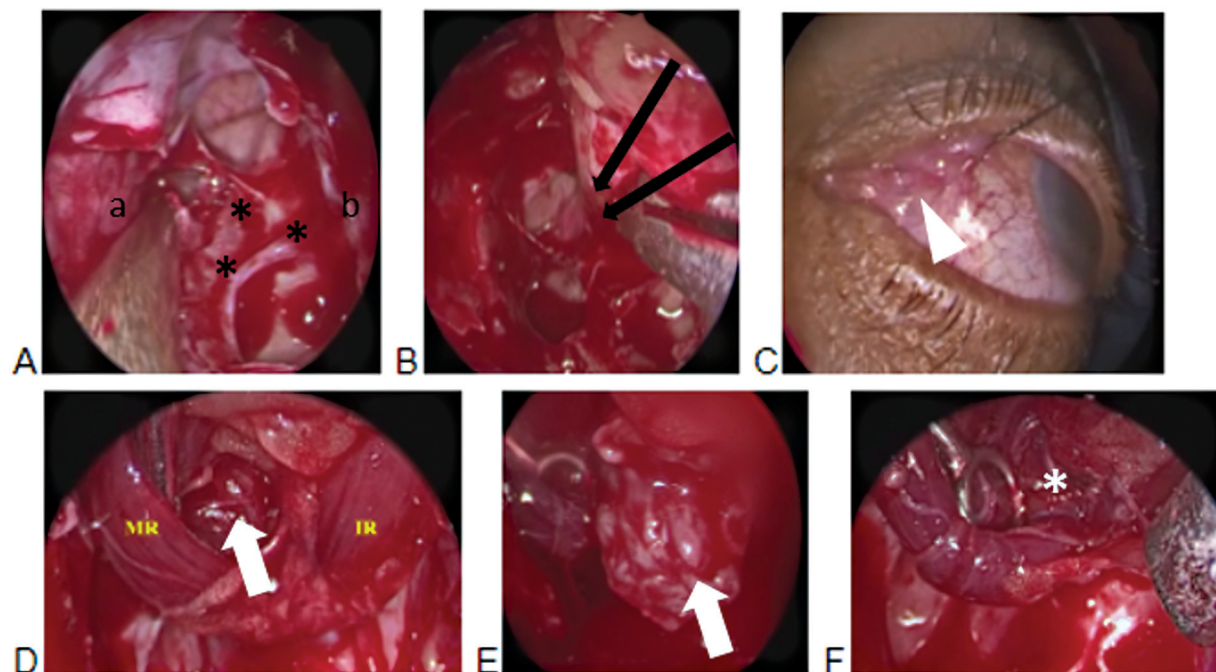
In the cases where complete tumor removal is not feasible, the optimal alternative treatment appears to be a combination of excision and high-dose radiation. Orbital exenteration with a craniotomy is advised if there is intracranial invasion and substantial vision impairment.<sup>5</sup>

## Conclusion

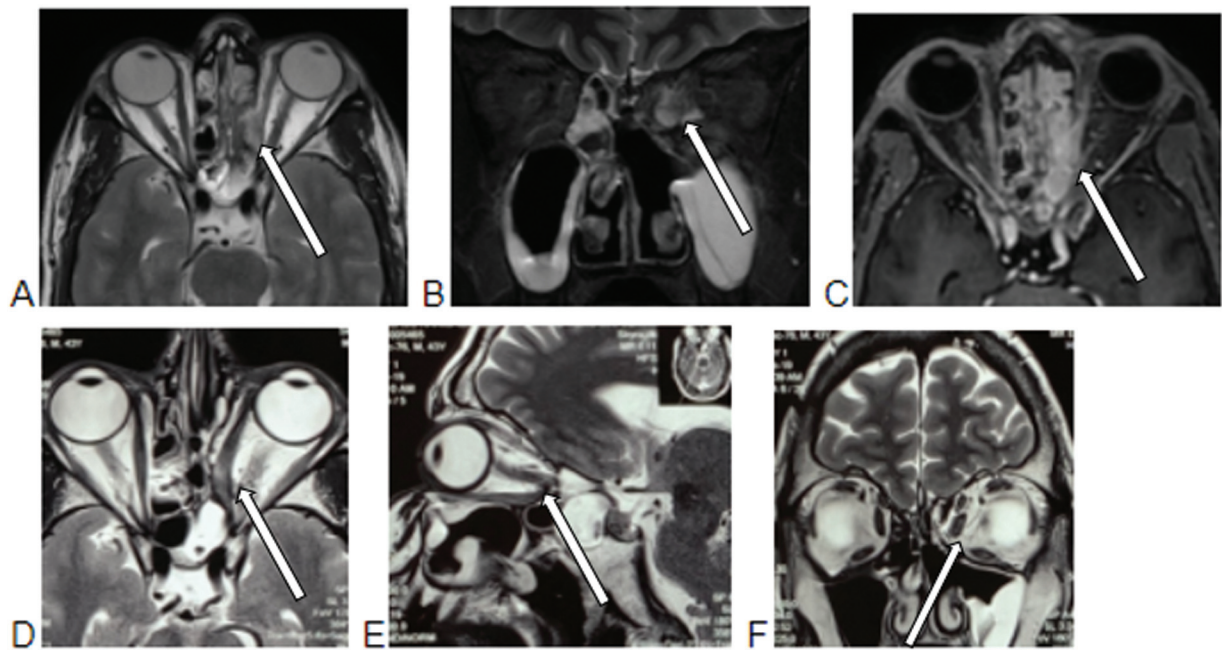
The occurrence of MPNSTs in the orbit is extremely rare. Gross total excision with adjuvant treatment and regular follow-up would be the best treatment strategy. Medially and inferiorly located intraconal orbital lesions can be addressed by the endoscopic endonasal approach. It is a minimally invasive approach that provides a safe corridor for gross total excision of locally aggressive tumors.



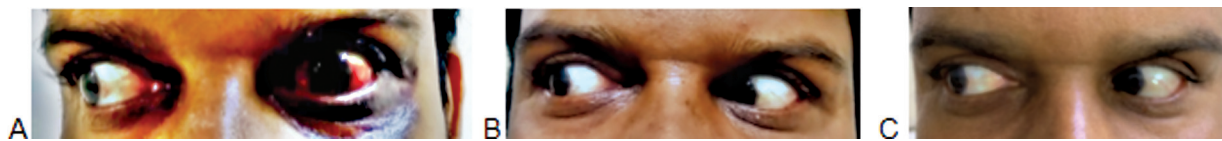**Fig. 1** Pre-op magnetic resonance imaging (MRI). The tumor (*white arrowhead*) is (A) hypointense to the parenchyma on T1 and (B) isointense to mixed intensity on T2, with (C) postcontrast heterogeneous enhancement. (D) Sagittal T2 and (E) coronal contrast images show the location/relation of the tumor to the optic nerve (*big black arrow*) and the extraocular muscles. The tumor is inferomedial to the optic nerve and in between the medial rectus (*long white arrow*) and the inferior rectus (*small white arrow*) muscles.



**Fig. 2** Intraoperative. (A) Removing the ethmoid air cells (*black asterisks*). a, medial/midline; b, lateral/orbital side. (B) Opening the periorbital till the orbital apex (*black arrow* indicates the periorbital and the direction of *arrow* indicates the periorbital opening from anterior to posterior). (C) The medial rectus (MR; *white arrowhead*) is tagged externally. (D) The tumor (*white arrow*) in relation to the MR and the Inferior Rectus (IR). (E) Tumor mass (*white arrow*). (F) There is no residual post excision (*white asterisk*).



**Fig. 3** Post-op magnetic resonance imaging (MRI). Post-op changes: there is no residual lesion (the white arrow indicates the previous location of the tumor). (A–C) At the 3-month follow-up, postoperative changes are evident. (D–F) at the 9-month follow-up.



**Fig. 4** (A) At 10 days post-op, restriction of adduction of the left eye is apparent. Post-op pictures (B) at 3 months and (C) 9 months show restoration of adduction of the left eye. (Pre-op images were not available.)

**Conflict of Interest**

None declared.

**References**

- 1 Ziadi A, Saliba I. Malignant peripheral nerve sheath tumor of intracranial nerve: a case series review. *Auris Nasus Larynx* 2010; 37(05):539–545
- 2 Shin M, Kondo K, Hanakita S, et al. Endoscopic transnasal approach for resection of locally aggressive tumors in the orbit. *J Neurosurg* 2015;123(03):748–759
- 3 Sweeney AR, Gupta D, Keene CD, et al. Orbital peripheral nerve sheath tumors. *Surv Ophthalmol* 2017;62(01):43–57
- 4 Abdolkarimi B, Zareifar S, Shokripoor M. Successful treatment of primary intracranial malignant peripheral nerve sheath tumor in Iranian child: case report. *J Neurol Neurosci* 2016;7(04):136
- 5 Wy S, Kim N. Orbital malignant peripheral nerve sheath tumor arising from neurofibroma. *Korean J Ophthalmol* 2019;33(03): 301–302
- 6 Cheng SF, Chen YI, Chang CY, Peng Y, Liao SL. Malignant peripheral nerve sheath tumor of the orbit: malignant transformation from neurofibroma without neurofibromatosis. *Ophthalm Plast Reconstr Surg* 2008;24(05):413–415
- 7 Muscatello L, Seccia V, Caniglia M, Sellari-Franceschini S, Lenzi R. Transnasal endoscopic surgery for selected orbital cavernous hemangiomas: our preliminary experience. *Head Neck* 2013;35 (07):E218–E220
- 8 Signorelli F, Anile C, Rigante M, Paludetti G, Pompucci A, Mangiola A. Endoscopic treatment of orbital tumors. *World J Clin Cases* 2015;3(03):270–274