



Comparative Diagnostic Accuracy of Computed Tomography Scan versus Magnetic Resonance Imaging in the Emergency Department for the Evaluation of Dizziness: A Systematic Review

Ishfaq Nabeel Ashiq¹ Safer Khan² Adil Yousaf³

¹Department of Emergency Medicine, Hamad Medical Corporation, Doha, Qatar

²Department of Pharmaceutical Sciences, Institute of Chemical Sciences, Government College University, Lahore, Punjab, Pakistan

³Green Health Pharmaceutical Company, Riyadh, Kingdom of Saudi Arabia

Address for correspondence Safer Khan, MS (Pharmacy), Department of Pharmaceutical Sciences, Institute of Chemical Sciences, Government College University, Lahore 54000, Punjab, Pakistan (e-mail: dr.safeerktk@yahoo.com).

Indian J Radiol Imaging 2024;34:488–495.

Abstract

Introduction Both computed tomography (CT) and magnetic resonance imaging (MRI) play significant roles in assessing patients with dizziness. However, understanding the comparative capabilities of these imaging methods in detecting pathological causes is crucial for determining the most suitable modality. This review aims to evaluate the diagnostic accuracy and clinical utility of MRI and CT scans in managing patients with acute dizziness in the emergency department.

Methods Following Preferred Reporting Items for Systematic Reviews and Meta-Analyses (PRISMA) guidelines, we conducted a comprehensive search in various databases (PubMed, Google Scholar, Cochrane library, British Medical Journals, and ScienceDirect) from 2010 to 2023. We used the QUADAS-2 tool to assess bias risk, considering MRI as the reference standard and CT scan as the index test.

Results The final analysis included six studies, with 3,993 patients (48% male, 52% female; average age: 56.7 years). Three studies were of high quality, two of medium quality, and one of low quality. Central ischemia was the predominant diagnosis for dizziness. MRI demonstrated higher diagnostic efficacy for stroke compared with CT scans, while mixed results were observed for other multiple diseases when both MRI and CT scans were used.

Conclusion MRI outperforms CT scans in diagnosing dizziness-related strokes. However, for other causes of dizziness, there is no significant difference between these techniques. Nevertheless, it is crucial to acknowledge the limitations associated with MRI. Consequently, to address these concerns, the selection of an imaging technique should be tailored to the individual based on factors such as their clinical presentation, comorbidities, and socioeconomic circumstances.

Keywords

- ▶ dizziness assessment
- ▶ diagnostic accuracy
- ▶ computed tomography (CT) scan
- ▶ magnetic resonance imaging
- ▶ emergency department

article published online
January 27, 2024

DOI <https://doi.org/10.1055/s-0044-1778726>
ISSN 0971-3026.

© 2024. Indian Radiological Association. All rights reserved.
This is an open access article published by Thieme under the terms of the Creative Commons Attribution-NonDerivative-NonCommercial-License, permitting copying and reproduction so long as the original work is given appropriate credit. Contents may not be used for commercial purposes, or adapted, remixed, transformed or built upon. (<https://creativecommons.org/licenses/by-nc-nd/4.0/>)
Thieme Medical and Scientific Publishers Pvt. Ltd., A-12, 2nd Floor, Sector 2, Noida-201301 UP, India

Introduction

Dizziness, a prevalent symptom in medical practice, ranks as the third most common major symptom, with a lifetime prevalence of 30%.^{1,2} It is frequently reported by patients in the emergency department (ED),^{3,4} accounting for approximately 5% of all presentations in both EDs and outpatient clinics.^{3,5,6}

Dizziness is categorized into peripheral or vestibular and central types depending on the underlying cause.⁷ Central vertigo, affecting the central vestibular pathway, can be potentially life-threatening, particularly when associated with a stroke. Thus, it is essential to distinguish between central and peripheral vertigo.^{8,9} It has a diverse range of causes, contributing to its occurrence. The majority of dizziness cases are attributed to vasovagal syncope or orthostatic hypotension, accounting for 22.3% of cases. Vestibular causes follow closely behind at 19.9%, with fluid and electrolyte disorders at 17.5%.¹

However, dizziness is a frequent complaint that leads individuals to seek medical care in the ED.¹⁰ However, diagnosing the underlying cause of dizziness presents challenges for several reasons. First, dizziness can originate from various conditions, including both life-threatening disorders and normal physiological responses. Second, there is a limited availability of diagnostic tools that can definitively determine the precise cause of dizziness in the majority of cases. Consequently, the diagnosis heavily depends on a thorough evaluation of clinical characteristics acquired through detailed patient history and meticulous bedside examinations.¹¹ Due to these reasons, emergency physicians face a diagnostic challenge when encountering patients in the ED who present with acute vertigo or dizziness.¹² As a result, misdiagnosis of these symptoms can lead to adverse effects on treatment, quality of life, and overall patient outcomes.¹³

In case, when clinical findings are uncertain, neuroimaging is often sought by patients experiencing vertigo.⁸ The decision regarding which imaging method to use for investigating dizziness typically boils down to two choices: magnetic resonance imaging (MRI) and computed tomography (CT) scan. According to a study examining the records of 805,454 individuals diagnosed with dizziness, CT scans were the most commonly utilized test. Within a span of 6 months following the initial presentation, a head CT scan remained the most frequently used test, constituting 47% of all tests conducted. The subsequent most utilized tests included brain MRI, accounting for 25%, cerebrovascular ultrasonography at 15%, and magnetic resonance angiography at 9%.¹⁴ However, there is conflicting evidence regarding the effectiveness of MRI and CT scans in evaluating dizziness, as different studies have reported inconsistent outcomes.

In the quest to determine the cause of dizziness, CT scans are capable of identifying posterior fossa hemorrhage and large infarcts.¹⁵ They are easily accessible, swift in execution, and generally more cost-effective when compared with MRI. On the other hand, MRI provides advanced diagnostic capabilities for assessing specific structures associated with vertigo, including the cerebellopontine angle, internal auditory

meatus, and related neural components. This makes MRI a potent tool in detecting conditions such as vestibular schwannomas and meningiomas.¹⁵

Despite the disappointing sensitivity of CT scans in identifying strokes (one of the leading causes of dizziness) during the acute phase, which was found to be only 26% by Chalela et al,¹⁶ MRI demonstrates higher sensitivity in stroke detection. However, within the first 24 hours, MRI's sensitivity is at its lowest, especially for brainstem or cerebellar lesions. Serial evaluation may be necessary to confirm a stroke, as initial diffusion-weighted MRI can result in false negatives for 12 to 20% of stroke patients within the first 48 hours. It is important to note that MRI cannot detect isolated labyrinthine infarctions, which may later extend to impact areas of the brainstem and cerebellum supplied by the anterior inferior cerebellar artery.¹⁶⁻¹⁸

In conclusion, both CT and MRI play significant roles in assessing patients with dizziness.¹⁹ Understanding the comparative capabilities of MRI and CT scans in detecting pathological causes in dizziness patients would be beneficial in determining the optimal imaging modality for such individuals. Therefore, the objective of this systematic review is to conduct a comparative analysis of MRI and CT scan in the ED for dizziness assessment. The review aims to evaluate the diagnostic accuracy and clinical utility of these imaging modalities in the management of patients presenting with acute dizziness in the ED settings.

Methodology

Search Strategy

In accordance with the Preferred Reporting Items for Systematic Reviews and Meta-Analyses (PRISMA) guidelines,²⁰ we performed a comprehensive search of multiple databases, including PubMed, Google Scholar, Cochrane library, British Medical Journals, and ScienceDirect. In addition, we reviewed relevant journal articles and performed a bibliographic analysis of systematic reviews and meta-analyses to identify articles that met our predetermined inclusion criteria. Our search aimed to identify full-text, peer-reviewed literature published from January 2010 to June 2023.

“Neuroimaging” OR “Magnetic resonance imaging” OR “MRI” OR “Computed tomography” OR “CT scan” OR “Radiography” AND “Acute dizziness” OR “Acute vertigo” AND “Diagnostic accuracy” OR “Sensitivity” OR “Specificity” AND “Emergency department” OR “Emergency medicine” AND “Comparative analysis”

These terms were combined using Boolean operators (AND) and (OR), and Medical Subject Subheadings terms and key text words were also considered. To ensure the inclusion of relevant studies, a thorough assessment of titles, abstracts, and full-text articles was performed, eliminating studies that did not meet our predetermined inclusion criteria.

Inclusion Criteria for the Selected Studies

The eligibility criteria were established based on the Population, Intervention, Comparators, Outcomes, Timing/Setting (PICOTS) framework.²¹ The following inclusion criteria were applied: Population: ED patients presenting with acute

vertigo or dizziness; Intervention: Neuroimaging techniques; Comparators: Diagnostic reference standards; Outcomes: Diagnostic accuracy measures, such as sensitivity and specificity, for neuroimaging in detecting the underlying causes of acute vertigo or dizziness; Timing/Setting: Studies conducted in ED settings, with no specific timing restrictions.

Additional inclusion criteria included randomized controlled trials and observational studies, without restrictions on gender, age, or associated pathology. The full-text articles had to be written in English and published between January 1, 2010, and May 31, 2023.

Exclusion Criteria for the Selected Studies

The following exclusion criteria were applied: (1) Duplicate datasets, including reanalysis of previously reported datasets; (2) Inadequate data that did not enable the assessment of diagnostic accuracy of neuroimaging techniques, (3) Dissertations, conference proceedings, commentaries, editorials, letters, books, book chapters, duplicate datasets, and reviews were also excluded.

Data Extraction and Quality Appraisal

The screening process involved a dual review by the authors, who assessed titles and abstracts for inclusion or exclusion based on the predefined criteria. Full texts of potentially eligible studies were obtained and independently evaluated by two members of the review team for eligibility. In cases where there was disagreement regarding the eligibility of specific studies, all authors engaged in discussions to reach a consensus.

All authors participated in evaluating various aspects of the study selection process, quality assessment, and data extraction. Data collection was conducted in duplicates using a standardized data form, and the following information was extracted from the included studies: source article, study design, sample size, sample demographics, selection criteria, details of interventions, main findings, conclusion, and limitations.

We assessed the risk of bias in the included studies using the QUADAS-2 tool.²² Seven key questions were evaluated that were deemed to have the most significant impact on the risk of bias. These questions pertained to patient selection, index test, reference standard, and flow and timing. Moreover, the MRI was taken as the reference standard and CT scan as the index test for our review. The responses were recorded as yes, no, or unclear. Responses of no and unclear were assigned a value of zero, while yes was assigned a value of one. Studies that met 100% of the relevant criteria were considered excellent quality, those meeting 75 to 99% were rated as high quality, studies meeting 50 to 74% were considered medium quality, and those below 50% were deemed low quality.

Statistical Analysis

Given the heterogeneity of the studies and outcome measures, a statistical meta-analysis could not be conducted. However, our descriptive analysis has provided a compre-

hensive summary of the relationship between the variables involved in our study.

Results

Literature Search

A total of 1,869 records were initially identified from five databases. After removing 453 duplicates, the screening process of titles, abstracts, and full-text articles was applied. In the end, 54 articles were selected. However, 48 of these articles did not meet the inclusion criteria, as they were not from the ED, lacked comparative analysis, pertained to pathologies where dizziness was not a symptom, or had improper study types. Eventually, six studies spanning from January 2010 to June 2023 were selected for final analysis.^{23–28} The flowchart of the searching and screening studies is presented in ►Fig. 1.

Quality Assessment of Included Studies

By implementing the QUADAS-2 tool,²² we assessed the quality of our six selected studies. Based on our predetermined criteria as discussed in section of methodology, three studies were classified as high quality,^{23,25,28} two studies as medium quality,^{24,27} and one study as low quality.²⁶ The one signaling questions that received a zero rating in all studies were: “Were the reference standard results interpreted without knowledge of the results of the index test?” The details of quality assessment of included studies are presented comprehensively in ►Table 1.

Baseline Characteristics of Included Studies

A total of 3,993 patients were included, comprising 48% males and 52% females, with an average age of 56.7 years. The most commonly employed study design was retrospective, utilized in four studies,^{24–27} while cross-sectional²³ and prospective design²⁸ were each employed in one study. In three studies, there were no strict selection criteria, and all patients presenting with dizziness to the ED within a specific time period were included.^{23,27,28} In the remaining three studies, a predetermined exclusion criteria were applied.^{24–26} The baseline characteristics of the included studies are presented in ►Table 2.

Interventional Characteristics of Included Studies

Among the selected studies, the common intervention involved was conducting head CT scans followed by MRI.^{23–25,28} Other studies utilized either single or combination of both head CT and MRI²⁷ or employed specialized imaging techniques such as head and neck computed tomography angiography (CTA), contrast-enhanced brain MRI, and MRI of internal auditory canals and temporal bones.²⁶ The predominant diagnosis for the cause of dizziness was central ischemia. Upon analyzing the findings of our studies, it can be concluded that MRI demonstrated higher diagnostic efficacy for stroke compared with CT scans, while mixed results were observed for other multiple diseases when both MRI and CT scans were used. The interventional characteristics of included studies are presented in ►Table 3.

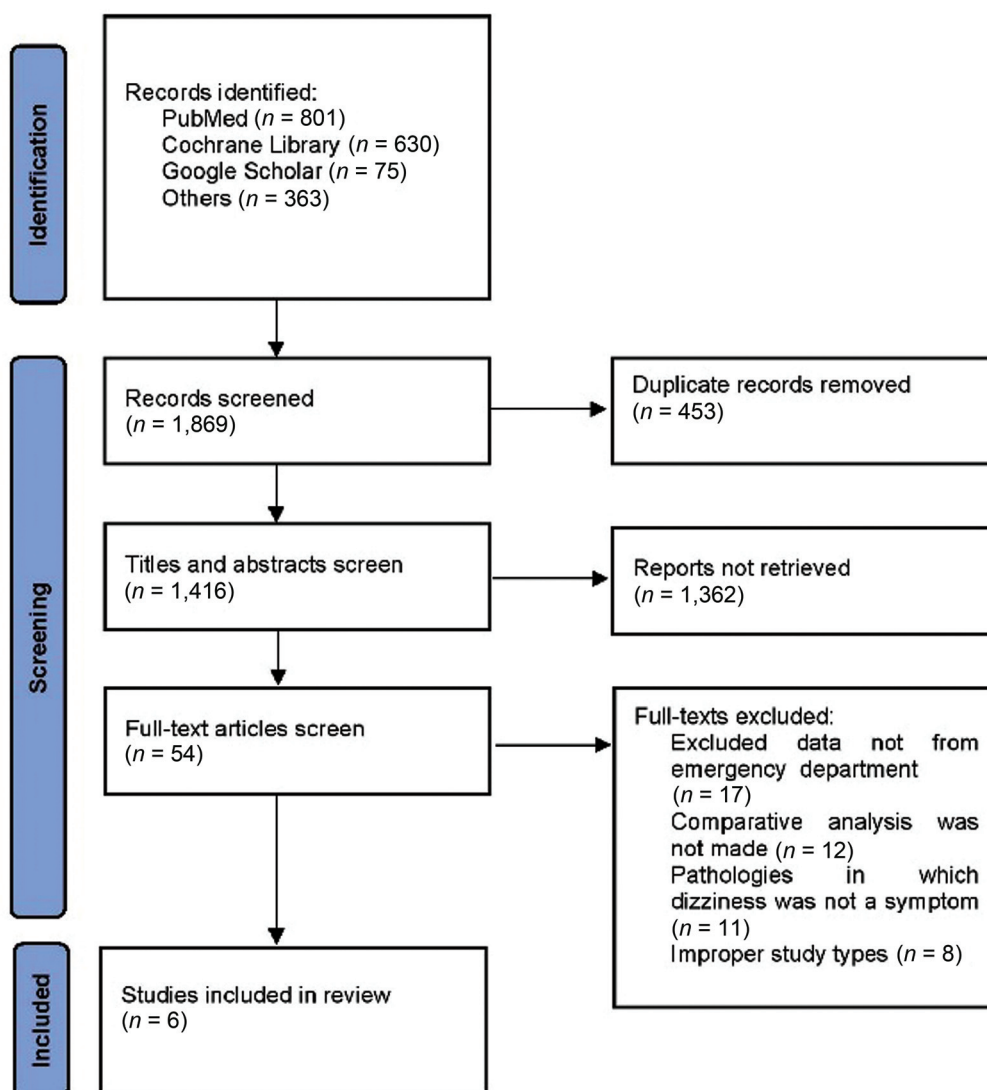


Fig. 1 Preferred Reporting Items for Systematic Reviews and Meta-Analyses (PRISMA) flowchart of the searching and screening studies.

Discussion

In this systematic review comparing the diagnostic test accuracy of CT scans versus MRI for ED patients with acute dizziness, we observed that MRI yielded superior results in diagnosing stroke associated with dizziness in ED. However, for other multiple diseases, our concluded studies did not show a significant difference between these two imaging techniques.

Out of the six selected studies, four studies specifically favored the utilization of MRI for diagnosing stroke associated with dizziness in ED.^{23–25,28} In contrast, two studies reported no significant difference between CT scans and MRI. Fakhran et al employed three different diagnostic modalities: head and neck CTA, contrast-enhanced brain MRI (CE-MR), and contrast-enhanced MRI of internal auditory canals and temporal bones. According to the conclusions drawn from the study, in cases where the cause of dizziness is unspecified or involves multiple other diseases, both CT scans and MRI can be helpful in diagnosis.²⁶ The other study

by Ahsan et al considered both the cost and utility of both CT scan and MRI in various conditions. Similar findings were noted for both techniques in conditions associated with dizziness such as vertebrobasilar stenosis, pituitary tumor, abnormal internal carotid artery, empty sella, right frontal lobe lesion, and cavernous malformation. However, the diagnosis of stroke was observed specifically on MRI and not on CT scan.²⁷ This finding aligns with the results obtained from the other four studies.

The reliance on noncontrast brain CT as a diagnostic tool for acute dizziness is common in clinical practice. However, our systematic review and previous literature consistently demonstrate its low diagnostic accuracy of noncontrast CT in identifying central causes, particularly stroke, in cases of acute dizziness. Due to which, it tends to miss a significant number of acute ischemic strokes during the early stages of symptom onset.¹⁶ Despite its limited diagnostic accuracy for detecting ischemic strokes, noncontrast CT remains relatively accurate in identifying acute brain hemorrhages. Therefore, it may still be preferred as the initial choice for

Table 1 Quality assessment of included studies by using the QUADAS-2 tool²²

Study	Was a consecutive or random sample of patients enrolled?	Did the study avoid inappropriate exclusions?	Was a case-control design avoided?	Were the index test results interpreted without knowledge of the results of the reference standard?	Were the reference standard results interpreted without knowledge of the results of the index test?	Did all patients receive the same reference standard?	Were all patients included in the analysis?	Questions satisfied (%)
Alawneh et al 2021 ²⁴	Yes	Yes	Yes	Yes	No	No	Yes	71.4
Hamzah & Ayad 2017 ²³	Yes	Yes	Yes	Yes	No	Yes	Yes	85.7
Hammoud et al 2016 ²⁵	Yes	Yes	Yes	Yes	No	Yes	Yes	85.7
Fakhran et al 2013 ²⁶	Yes	Yes	Yes	Unclear	Unclear	No	No	42.8
Ahsan et al 2013 ²⁷	Yes	Yes	Yes	Unclear	Unclear	No	Yes	57.1
Hwang et al 2012 ²⁸	Yes	Yes	Yes	Yes	No	Yes	Yes	85.7

A response of "No" was given a score of "00," a response of "Yes" was indicated by a score of "01," and unclear responses were also assigned a score of "00."

neuroimaging when the objective is to rule out hemorrhages.²⁹

However, MRI in the selected studies has been proven to offer superior diagnostic outcomes. However, there are various limitations associated with MRI access.¹⁴ The most important one is its high cost, which can contribute to increased healthcare utilization. For instance, in one of the selected studies, the charges for a single CT scan within the health system were found to be \$1,220 per study, while the charges for brain MRI within the same system were \$2,696 per study.²⁷ Similarly, a study examining commercial and Medicare Advantage claims involving 800,000 adults diagnosed with new-onset dizziness revealed that CT scans were the most commonly used imaging test, accounting for 92% of the patients who underwent imaging for dizziness. The total expenditure on neuroimaging for this population amounted to \$88 million, with MRI accounting for 70% of the overall cost.¹⁴ In addition, MRI may not be readily available in the emergency settings. Due to which, CT scans often serve as the initial imaging technique of choice across numerous institutions, favored for their quick execution and wider availability.²⁷

To address the limitations and capabilities of CT scans and MRIs, selecting the appropriate imaging test should be customized to the individual patient. This choice should incorporate an evaluation of the patient's clinical presentations, existing comorbidities, and their medical and socio-economic history. Alongside this, the HINTS (Head-Impulse, Nystagmus, Test of Skew) exam has established its efficacy as a clinical instrument for discerning central etiologies of vertigo, like strokes, from peripheral vestibular conditions.³⁰ Its strategic implementation in the ED can refine the decision-making process for patient-specific imaging approaches. By effectively detecting patients at increased risk of stroke, particularly where initial CT scans are non-revelatory, the HINTS exam can guide the targeted use of MRI, allocating this advanced imaging selectively to those who may derive significant benefit.¹ Additionally, the application of HINTS may reduce the immediate demand for MRI, allowing clinicians to categorize patients based on neuroimaging urgency, potentially leading to enhanced patient outcomes and more efficient ED operations.³¹

The systematic review has several limitations that should be acknowledged. First, the importance of timing for accurate diagnosis cannot be overlooked for both CT scan and MRI, as it is evident from the literature that a different time between onset of symptoms and diagnostic imaging test leads to altered results.³² In usual cases, CT is performed promptly due to its accessibility, while MRI, being a follow-up, may be delayed by hours to days.¹⁶ This interval can lead to diagnostic disparities attributable to disease progression rather than the intrinsic accuracy of the imaging modalities. In our case due to the retrospective design of the studies, the exact time between CT scan and MRI could not be reported by four out of six the studies. Similarly, the reliance of majority of studies on retrospective study designs could also introduce potential biases and impact the reliability of the results. Second, the lack of information on specific subtypes of

Table 2 Baseline characteristics of included studies

Study	Study design	Selection criteria	Sample
Alawneh et al 2021 ²⁴	Retrospective design	Adult patients presenting to the ED between July 2015 to June 2018 for dizziness complaints. Exclusions included children, those with recent neurosurgery, pre-existing neurological disorders, and dizzy patients without a head CT scan within 3 months. Excluded patients also lacked medical notes	$n = 326$ participants, 47.5% male, 83.1% were older than 44 years. Among the patients, 40.2% had comorbid diabetes mellitus, followed by a history of stroke in 33.7% of cases, and hypertension in 20.6% of cases.
Hamzah & Ayad 2017 ²³	Cross-sectional design	Between December 2016 and August 2017, patients with vertigo that sought consultation at a teaching hospital	$n = 100$ patients, 51% male, and average age 48 years. Among the participants, 60% had a positive history of chronic disease. Furthermore, 80% patients presented with associated symptoms alongside vertigo, while 20% experienced vertigo without any associated symptoms.
Hammoud et al 2016 ²⁵	Retrospective design	Patients who presented from January 2009 to December 2014 to the ED with symptoms and had a negative noncontrast head CT, followed by head MRI within 24 hours of the initial CT. Exclusion criteria encompassed patients with typical stroke syndromes, trauma patients, those under 18 years of age, individuals with the complaint of “worst headache of life,” patients lacking clinical data, those with metabolic derangements, and patients with ambiguous CT findings requiring an MRI for further evaluation	$n = 252$, 48.8% male, and average age 59.4 years
Fakhran et al 2013 ²⁶	Retrospective design	Patients who visited between January 2011 and June 2012, presenting with dizziness, and excluded patients displaying signs or symptoms indicating other neurologic conditions or having a history of abnormalities known to be associated with dizziness	$n = 798$ (32% presented to ED), 40% male, and average age 55 years
Ahsan et al 2013 ²⁷	Retrospective design	Between January 2008 and January 2011, patients who sought medical care at ED and were diagnosed with dizziness and vertigo	$n = 1,681$, 33% male, and average age 56.9 years
Hwang et al 2012 ²⁸	Prospective design	Patients presented to an ED with stroke symptoms between 2003–2007	$n = 836$, 67.5% male, and average age 64.2 years

Abbreviations: CT, computed tomography; ED, emergency department; MRI, magnetic resonance imaging.

Table 3 Interventional characteristics of included studies

Study	Detail of intervention	Common pathology diagnosed	Main findings	Main limitations
Alawneh et al 2021 ²⁴	Nonenhanced head CT scans followed by MRI in 70% of the follow-up studies	Acute ischemic stroke	MRI was found to be a more precise imaging technique than CT scans for evaluating dizziness in ED	Recall bias, small sample size, and no information on different types of dizziness
Hamzah & Ayad 2017 ²³	Head CT scans followed by MRI in all included patients	Cerebral ischemia	The CT scan exhibited a sensitivity of 50.58% as compared with 83% of MRI in detecting central causes of vertigo	Not reported
Hammoud et al 2016 ²⁵	Negative noncontrast head CT, followed by head MRI within 24 hours	Acute or subacute infarction of cortex or deep white and gray matter	In the diagnosis of stroke associated with dizziness, MRI demonstrated superior results compared with CT scans	Small sample size, reliance on clinical data, and retrospective study design

(Continued)

Table 3 (Continued)

Study	Detail of intervention	Common pathology diagnosed	Main findings	Main limitations
Fakhran et al 2013 ²⁶	Head and neck CTA, contrast-enhanced brain MRI (CE-MR), and contrast-enhanced MRI of internal auditory canals and temporal bones	Not reported	No significant difference was found between the diagnostic efficacies of three interventions for uncomplicated dizziness	Large number of exclusions and no information on different types of dizziness
Ahsan et al 2013 ²⁷	Head CT and MRI	Multiple disease	To perform CT and MRI scans without careful consideration in ED patients experiencing dizziness, leads to a low number of positive results	Retrospective study design and potential underreporting resulting from selective criteria
Hwang et al 2012 ²⁸	NCCT within 30 hours of symptom onset and brain DWI-MRI performed within 6 hours of the NCCT	Acute posterior fossa infarct	In cases where a posterior fossa stroke is suspected and a NCCT scan does not provide a definitive diagnosis, then MRI is the recommended imaging method	Attending neuroradiologist's interpretation at the time of performing each NCCT scan, and not all of our patients had documented formal NIHSS scores at the time of their presentation to the ED

Abbreviations: CT, computed tomography; CTA, computed tomography angiography; DWI, diffusion-weighted imaging; MRI, magnetic resonance imaging; NCCT, noncontrast head computed tomography; NIHSS, National Institutes of Health Stroke Scale.

dizziness limits our ability to make precise conclusions for each subtype. Additionally, the relatively small number of studies included in the review may restrict the generalizability of the findings and limit the overall strength of the evidence. Therefore, it is crucial to conduct prospective studies with larger sample sizes that specifically investigate the diagnostic efficacy of CT and MRI for distinct subtypes of dizziness.

Conclusion

In synthesizing the outcomes of the systematic review, it is evident that MRI has a superior diagnostic accuracy over CT scans in identifying strokes associated with dizziness. However, for nonstroke causes of dizziness, both imaging modalities demonstrate comparable efficacy. However, the practical application of MRI is limited by factors including its accessibility, usage, and cost. This reality advocates for a customized approach to choosing an imaging modality, with decisions made based on a comprehensive assessment of each patient's clinical situation, including symptoms, comorbidities, and socioeconomic factors. Furthermore, the HINTS exam emerges as a valuable tool, especially in situations where CT scans fail to detect strokes, by enhancing the selection process for MRI use. This targeted application ensures MRI resources are allocated effectively to those most likely to benefit. To reinforce these findings and explore identified research gaps, future studies should be designed as prospective in nature, encompassing robust sample sizes aimed at assessing the diagnostic accuracy of CT and MRI in diverse presentations of dizziness.

Funding

None.

Conflict of Interest

None declared.

References

- Tarnutzer AA, Berkowitz AL, Robinson KA, Hsieh YH, Newman-Toker DE. Does my dizzy patient have a stroke? A systematic review of bedside diagnosis in acute vestibular syndrome. *CMAJ* 2011;183(09):E571–E592
- Strupp M, Kremmyda O, Brandt T. Pharmacotherapy of vestibular disorders and nystagmus. *Semin Neurol* 2013;33(03):286–296
- Newman-Toker DE, Hsieh YH, Camargo CA Jr, Pelletier AJ, Butchy GT, Edlow JA. Spectrum of dizziness visits to US emergency departments: cross-sectional analysis from a nationally representative sample. *Mayo Clin Proc* 2008;83(07):765–775
- Saber Tehrani AS, Coughlan D, Hsieh YH, et al. Rising annual costs of dizziness presentations to U.S. emergency departments. *Acad Emerg Med* 2013;20(07):689–696
- Kroenke K, Jackson JL. Outcome in general medical patients presenting with common symptoms: a prospective study with a 2-week and a 3-month follow-up. *Fam Pract* 1998;15(05):398–403
- Newman-Toker DE, Cannon LM, Stofferahn ME, Rothman RE, Hsieh YH, Zee DS. Imprecision in patient reports of dizziness symptom quality: a cross-sectional study conducted in an acute care setting. *Mayo Clin Proc* 2007;82(11):1329–1340
- Mohamed S, Khan I, Iliodromiti S, Gaggini M, Kontorinis G. Ménière's disease and underlying medical and mental conditions: towards factors contributing to the disease. *ORL J Otorhinolaryngol Relat Spec* 2016;78(03):144–150
- Lempert T. Recurrent spontaneous attacks of dizziness. *Continuum (Minneapolis)* 2012;18(5 Neuro-otology):1086–1101

- 9 Navi BB, Kamel H, Shah MP, et al. The use of neuroimaging studies and neurological consultation to evaluate dizzy patients in the emergency department. *Neurohospitalist* 2013;3(01):7-14
- 10 Cappello M, di Blasi U, di Piazza L, et al. Dizziness and vertigo in a department of emergency medicine. *Eur J Emerg Med* 1995;2(04):201-211
- 11 Baloh RW. Vertigo. *Lancet* 1998;352(9143):1841-1846
- 12 Gerlier C, Hoarau M, Fels A, et al. Differentiating central from peripheral causes of acute vertigo in an emergency setting with the HINTS, STANDING, and ABCD2 tests: a diagnostic cohort study. *Acad Emerg Med* 2021;28(12):1368-1378
- 13 Spiegel R, Kirsch M, Rosin C, et al. Dizziness in the emergency department: an update on diagnosis. *Swiss Med Wkly* 2017;147:w14565
- 14 Adams ME, Karaca-Mandic P, Marmor S. Use of neuroimaging for patients with dizziness who present to outpatient clinics vs emergency departments in the US. *JAMA Otolaryngol Head Neck Surg* 2022;148(05):465-473
- 15 Kontorinis G. The imaging of the dizzy patient: computed tomography versus magnetic resonance imaging. *Eur Radiol* 2018;28(07):2914-2915
- 16 Chalela JA, Kidwell CS, Nentwich LM, et al. Magnetic resonance imaging and computed tomography in emergency assessment of patients with suspected acute stroke: a prospective comparison. *Lancet* 2007;369(9558):293-298
- 17 Oppenheim C, Stanescu R, Dormont D, et al. False-negative diffusion-weighted MR findings in acute ischemic stroke. *AJNR Am J Neuroradiol* 2000;21(08):1434-1440
- 18 Kim JS, Cho KH, Lee H. Isolated labyrinthine infarction as a harbinger of anterior inferior cerebellar artery territory infarction with normal diffusion-weighted brain MRI. *J Neurol Sci* 2009;278(1-2):82-84
- 19 Patkar D, Yevankar G, Parikh R. Radiology in vertigo and dizziness. *Int J Otorhinolaryngol Clin* 2012;4(02):86-92
- 20 Moher D, Liberati A, Tetzlaff J, Altman DG, PRISMA Group. Preferred reporting items for systematic reviews and meta-analyses: the PRISMA statement. *Ann Intern Med* 2009;151(04):264-269, W64
- 21 Matchar DB. Chapter 1: introduction to the methods guide for medical test reviews. *J Gen Intern Med* 2012;27(Suppl 1, Suppl 1):S4-S10
- 22 Whiting PF, Rutjes AW, Westwood ME, et al; QUADAS-2 Group. QUADAS-2: a revised tool for the quality assessment of diagnostic accuracy studies. *Ann Intern Med* 2011;155(08):529-536
- 23 Hamzah KH, Ayad O. Role of MRI versus CT scan in evaluation of patient with vertigo. *Med J Babylon* 2017;14:550-557
- 24 Alawneh KZ, Raffee LA, Oqlat AA, et al. The utility of brain CT scan modality in the management of dizziness at the emergency department: a retrospective single-center study. *Ann Med Surg (Lond)* 2021;64:102220
- 25 Hammoud K, Lanfranchi M, Li SX, Mehan WA. What is the diagnostic value of head MRI after negative head CT in ED patients presenting with symptoms atypical of stroke? *Emerg Radiol* 2016;23(04):339-344
- 26 Fakhran S, Alhilali L, Branstetter BF IV. Yield of CT angiography and contrast-enhanced MR imaging in patients with dizziness. *AJNR Am J Neuroradiol* 2013;34(05):1077-1081
- 27 Ahsan SF, Syamal MN, Yaremchuk K, Peterson E, Seidman M. The costs and utility of imaging in evaluating dizzy patients in the emergency room. *Laryngoscope* 2013;123(09):2250-2253
- 28 Hwang DY, Silva GS, Furie KL, Greer DM. Comparative sensitivity of computed tomography vs. magnetic resonance imaging for detecting acute posterior fossa infarct. *J Emerg Med* 2012;42(05):559-565
- 29 Salmela MB, Mortazavi S, Jagadeesan BD, et al; Expert Panel on Neurologic Imaging. ACR appropriateness criteria® cerebrovascular disease. *J Am Coll Radiol* 2017;14(5S):S34-S61
- 30 Gottlieb M, Peksa GD, Carlson JN. Head impulse, nystagmus, and test of skew examination for diagnosing central causes of acute vestibular syndrome. *Cochrane Database Syst Rev* 2023;11(11):CD015089
- 31 Kattah JC, Talkad AV, Wang DZ, Hsieh YH, Newman-Toker DE. HINTS to diagnose stroke in the acute vestibular syndrome: three-step bedside oculomotor examination more sensitive than early MRI diffusion-weighted imaging. *Stroke* 2009;40(11):3504-3510
- 32 Smith AG, Rowland Hill C. Imaging assessment of acute ischaemic stroke: a review of radiological methods. *Br J Radiol* 2018;91(1083):20170573