



A Retrospective Study of Nasopharyngeal Carcinoma: Clinical and Treatment Outcome

Megha Madhu¹  Marina Saldanha¹  Vadish Bhat¹  Rajeshwary Aroor¹ 

¹Department of Otorhinolaryngology, KS Hegde Medical Academy, NITTE (deemed to be University), Mangalore, Karnataka, India

Address for correspondence Marina Saldanha, MBBS, MS (ENT), Department of Otorhinolaryngology, K.S. Hegde Medical Academy, NITTE (deemed to be University), Mangalore 575018, Karnataka, India (e-mail: saldanhamarina@gmail.com).

J Health Allied Sci^{NU}

Abstract

Background Nasopharyngeal carcinoma is an uncommon disease endemic to Southern China, Southeast Asia, North Africa, and the Arctic. It is uncommon in southern India, and hence its treatment outcome and prognosis are not widely studied in these areas. In this study, our primary objective was to document the clinical presentation of patients with nasopharyngeal carcinoma in southern India and to analyze the response to treatment and follow-up.

Materials and Methods The study is an institutional-based retrospective study including 26 patients with histology-proven nasopharyngeal carcinoma from January 2011 to December 2017. All patients were treated with standard protocol of intensity modulated radiotherapy with concurrent chemotherapy. Data on patient demographics, clinical presentation, treatment, and follow-up were analyzed.

Results The median age at presentation in our study was 53.5 years. The most common histopathology subtype was nonkeratinizing undifferentiated carcinoma (65%). Nodal metastasis was the most common clinical presentation seen in 88% of the patients. Post-treatment, distant metastasis to the iliac bone, lung, liver, and spleen was seen in two patients. Complete remission was achieved in 65%, whereas three patients developed recurrence after the completion of treatment. Five-year progression-free survival was 69%.

Conclusion Nasopharyngeal carcinoma has a good response to concurrent chemoradiation. Long-term follow-up and planning surveillance strategies are essential post-treatment. Disease awareness to aid in early diagnosis and optimize management is imperative as observed from the delayed presentations in southern India.

Keywords

- ▶ nasopharyngeal carcinoma
- ▶ nonkeratinizing undifferentiated carcinoma
- ▶ concurrent chemoradiation
- ▶ metastasis
- ▶ endemic locations

Introduction

Nasopharyngeal carcinoma (NPC) is a rare head and neck cancer with significant geographical variation.¹ It is an undifferentiated form of squamous cell carcinoma arising from the epithelium of the nasopharynx. The interplay of genetic susceptibility, Epstein–Barr virus (EBV) infection, and environmental factors are the causative factors leading to the development of NPC.²

A high incidence is seen in the southern part of China (25 to 50 cases per 100,000) and is endemic to parts of Asia and Africa. It has a low incidence in India, except in the north-eastern region of the country.³

In Northeast India, the incidence ranges from the lowest (0.5/100 000 to 2.0/100 000 among Caucasoid) to the highest (~20/100 000 among Cantonese/Zhongshan dialect Chinese). The age-adjusted rate of NPC in Kohima District of Nagaland State is 19.4/100 000.⁴

DOI <https://doi.org/10.1055/s-0044-1787106>.
ISSN 2582-4287.

© 2024. The Author(s).

This is an open access article published by Thieme under the terms of the Creative Commons Attribution License, permitting unrestricted use, distribution, and reproduction so long as the original work is properly cited. (<https://creativecommons.org/licenses/by/4.0/>)

Thieme Medical and Scientific Publishers Pvt. Ltd., A-12, 2nd Floor, Sector 2, Noida-201301 UP, India

The studies on the outcome and prognostic factors are from endemic high-risk regions, and there is limited data on its epidemiology and outcomes reported from southern India.³

In this study, our aim was to document the clinical presentation of patients with NPC in our tertiary care center and to analyze the response to treatment and follow-up.

Methodology

The study is an institutional-based retrospective study from January 2011 to December 2017. The approval of the Institutional Review Board was taken to look into the medical records of patients (IEC dated 6/5/22, reg no. EC/NEW/INST/2020/834). The data was retrieved from the Medical Records Department using the International Classification of Diseases code (code number C 11.9). Twenty-six patients with histology-proven NPC and treated with intensity modulated radiotherapy (IMRT) with concurrent chemotherapy were included in the study. All the patients were from southern India. The data of the pre-treatment evaluation collected included a complete history, physical examination, diagnostic nasal endoscopy, complete blood cell counts, blood biochemistry, chest radiographs, and magnetic resonance imaging (MRI) of the head and neck was collected. The staging of the disease according to the 8th edition of the American Joint Committee on Cancer classification was documented.

All patients underwent IMRT with concurrent chemotherapy weekly with 30 mg/m² of cisplatin for 6 weeks. Three patients also received adjuvant chemotherapy due to the advanced stage of the disease (stage IV).

The patients were evaluated daily in the hospital for the assessment and management of acute radiation-related toxicities during the course of chemoradiation. After the completion of radiotherapy, follow-up was done after 1 month, followed by 3 monthly for 5 years and every 6 months thereafter. Evaluation at each follow-up visit included evaluation by the otorhinolaryngologist and the oncologist. A clinical history, ear, nose and throat examination, and diagnostic nasal endoscopy were performed at each visit. An MRI of the head and neck was done when any signs of recurrence were suspected, like complaints of ear block, nasal bleeds, anosmia, and neck nodes. Distant metastases were diagnosed by physical examination and suitable imaging studies (positron emission tomography, computed tomography [CT] scan, or MRI).

Results

Majority of the patients belonged to the 51 to 60 age group (30%; ►Fig. 1); the median age at presentation was 53.5 years. The male population was 80.8% (21 patients). When histology was compared, 65% (17 patients) had an undifferentiated subtype of NPC, 23% (6 patients) had a differentiated type, and 11% (3 patients) had a keratinizing type. At presentation, the patients had varied symptoms consisting

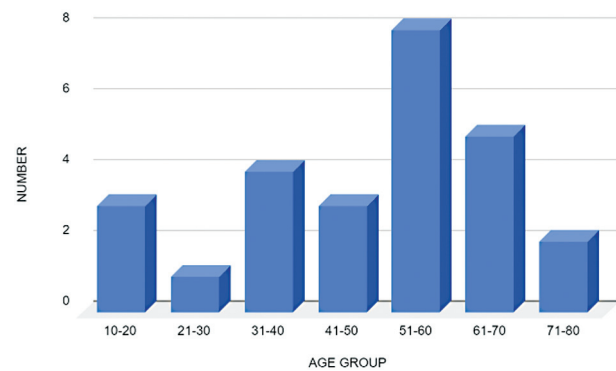


Fig. 1 Age distribution of nasopharyngeal carcinoma.

of nasal bleeds (35%), ear blocks (12%), anosmia (8%), and hearing loss (4%; ►Table 1).

Nodal metastasis to levels Ib, II, III, and V was seen in 88% (23 patients) of the cases, of which 18 patients had bilateral nodal metastasis to levels Ib, II, III, and V. Post-treatment distant metastases were seen in two patients; one patient had metastasis to the iliac bone and cranial nerve II, III, IV, and V palsy. The other patient had metastasis to the temporal lobe, lung, liver, and spleen, and cranial nerve III, V, VI, VII, VIII, IX, and X palsies (►Table 2).

The majority of the patients belonged to stage III (42%), followed by stage IV (30%), stage II (15%), and stage I (11%). Complete remission was achieved in 65% (17 patients), whereas three patients developed recurrence after the completion of treatment. One, three, and five-year survival rates were analyzed. The 5-year overall survival rate was 69% (18 patients). Two patients expired during the course of the study. The disease-free survival rate was 65% (17 patients) at the end of 5 years. Three patients developed local recurrence, which was detected on diagnostic nasal endoscopy. The nasopharynx examination showed proliferative mass that bled on touch. Three patients developed recurrence to lymph nodes in level II, III, and V lymph nodes during the follow-up period. Six patients were lost to follow-up.

Radiation-induced adverse effects such as xerostomia, oral mucositis, and dry and moist desquamation were seen in all patients. Two patients developed dyspnea due to lung consolidation, of which one developed sepsis, pleural effusion, and metastasis to the skeletal system. Both patients also developed multiple cranial nerve palsies. Both patients had expired during the course of the study.

Discussion

NPC deserves special consideration because of its many distinctive features that set it apart from other carcinomas in the head and neck region, such as the primary location, which can be missed initially, the late presentation of the disease, varying symptoms, and its rarity in southern India. The area with the highest incidence is in southern China, among the Cantonese population of Guangdong Province.⁵

Table 1 Clinical presentation of NPC

Symptoms	Symptom	Number	Frequency (%)
Ear complaints	Ear block	3	12
	Hearing loss	1	4
	Ear pain	1	4
Nasal complaints	Nasal obstruction	8	31
	Epistaxis	9	35
	Anosmia	2	8
	Nasal discharge and recurrent rhinitis	4	15
Neck pain		2	8
Neck swelling		23	88
Headache		5	19
Throat pain		1	4
Cranial nerve involvement	Dysphagia	4	15
	Voice change	1	4
	Vision loss	1	4
	Diplopia	2	8
Generalized weakness	Generalized weakness	1	4
Dyspnea		1	4

Abbreviation: NPC, nasopharyngeal carcinoma.

The high incidence in these regions is due to combined genetic and environmental factors. It was observed that migrants from high-risk populations who settle in low-incidence areas have higher incidences than the native population, though the incidence reduces in later generations, like Southern Chinese emigrants to North America.⁶

In endemic locations, it is mostly linked to EBV infection, while genetic and dietary factors, such as preserved smoked foods, may also play a role in its genesis. Well-differentiated variants may also be linked to smoking.¹ EBV titers could not be measured because our study was retrospective.

The tumor can affect pediatric to geriatric age groups. In low-risk regions, the disease incidence is found to increase with age, while in high-incidence areas, there is a bimodal distribution noted with a small peak in adolescent and young adults and a larger later peak at around 50 to 55 years of age.¹

Table 2 Sites of post-treatment distant metastases

Distant metastasis	Number of patients
Temporal lobe metastasis	1
II, III cranial nerve palsy	2
IV, V, VI cranial nerve palsy	2
VII, VIII cranial nerve palsy	1
IX, X cranial nerve palsy	1
Lung metastasis	1
Liver metastasis	1
Bone metastasis	2

The median age in our population was 53.5 years, which is similar compared with other parts of the world. A review of several large screening studies conducted in high-incidence areas of China was done by Cao et al.⁷ It was observed that NPC incidence among high-risk Cantonese of both sexes increased with age until it peaks between 40 and 59 years. In a study done in southern India by Haleshappa et al,¹ the median age at presentation was 35 years.

The disease is two to three times more frequently seen in males than in females.⁸ The male-female ratio found in our series was 4.2:1, which is similar to studies by Cao et al⁷ (2-3:1) and Haleshappa et al¹ (2.8:1).

Hoppe et al⁹ reported neck swellings (71%), nasal symptoms (54%), ear symptoms (51%), and cranial involvement (12%) in their series. Haleshappa et al¹ observed neck swelling (80%), nasal obstruction and/or epistaxis (28%), ear symptoms (24.5%), and cranial involvement (15%), with the most common involvement of the fifth nerve.

In our study, when compared, it was observed as 88% neck swelling, 88% nasal symptoms, 19% ear symptoms, and 30% cranial involvement.

Awareness of the disease is crucial. A lot of patients present at a later stage due to ignorance. Our study shows that NPC needs to be considered as a differential diagnosis for a patient with epistaxis.

EBV titers could not be measured as our study was retrospective. The study population was small, owing to nonendemic regions of study. Lack of follow-up for all patients is a drawback of our study. Patients should be counseled about the need for post-treatment surveillance and regular for better treatment outcomes.

Conclusion

IMRT with concurrent chemotherapy improves the outcome of NPC treatment. In advanced stages, this is combined with adjuvant or neoadjuvant CT.

Distant metastasis is the major cause of treatment failure. Early diagnosis and treatment are important for improving the treatment outcome. It is necessary to do additional prospective studies to evaluate further and to identify newer modalities for detecting post-treatment recurrence.

Ethical Clearance

Institutional ethics committee clearance was obtained prior to the study. Confidentiality was ensured throughout.

Funding

None.

Conflict of Interest

None declared.

Acknowledgment

The authors would like to thank all staff of the Department of Oncology who have contributed to the study.

References

- 1 Haleshappa RA, Thanky AH, Kuntegowdanahalli L, Kanakasetty GB, Dasappa L, Jacob L. Epidemiology and outcomes of nasopharyngeal carcinoma: experience from a regional cancer center in Southern India. *South Asian J Cancer* 2017;6(03):122–124
- 2 Tsao SW, Yip YL, Tsang C-M, et al. Etiological factors of nasopharyngeal carcinoma. *Oral Oncol* 2014;50(05):330–338
- 3 Kunheri B, Agarwal G, Sunil PS, Nair AR, Pushpaja KU. Nasopharyngeal carcinoma: experience and treatment outcome with radical conformal radiotherapy from a tertiary care center in India. *Indian J Cancer* 2017;54(03):502–507
- 4 Katak AC, Simons MJ, Das AK, Sharma K, Mehra NK. Nasopharyngeal carcinoma in the Northeastern states of India. *Chin J Cancer* 2011;30(02):106–113
- 5 Chang ET, Ye W, Zeng YX, Adami HO. The evolving epidemiology of nasopharyngeal carcinoma. *Cancer Epidemiol Biomarkers Prev* 2021;30(06):1035–1047
- 6 Buell P. The effect of migration on the risk of nasopharyngeal cancer among Chinese. *Cancer Res* 1974;34(05):1189–1191
- 7 Cao SM, Simons MJ, Qian CN. The prevalence and prevention of nasopharyngeal carcinoma in China. *Chin J Cancer* 2011;30(02):114–119
- 8 Ferlay J, Soerjomataram I, Dikshit R, et al. Cancer incidence and mortality worldwide: sources, methods and major patterns in GLOBOCAN 2012. *Int J Cancer* 2015;136(05):E359–E386
- 9 Hoppe RT, Goffinet DR, Bagshaw MA. Carcinoma of the nasopharynx. Eighteen years' experience with megavoltage radiation therapy. *Cancer* 1976;37(06):2605–2612