

# “Lentiform fork sign” in uremic striatopallidal syndrome: a rare cause of parkinsonism

## “Sinal da forquilha lentiforme” na síndrome estriado-palidal urêmica: uma causa rara de parkinsonismo

Trajano Aguiar Pires Gonçalves<sup>1</sup>  Pedro José Tomaselli<sup>1</sup> 

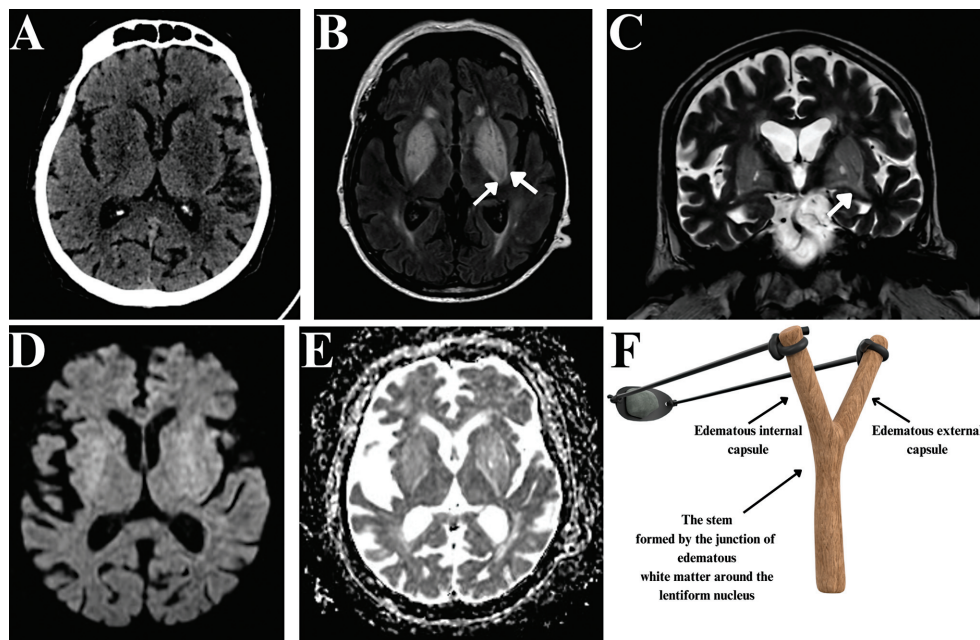
<sup>1</sup> Universidade de São Paulo, Faculdade de Medicina de Ribeirão Preto, Departamento de Neurociências e Ciências Comportamentais, Ribeirão Preto SP, Brazil.

Address for correspondence Trajano Aguiar Pires Gonçalves (email: trajanoapg@gmail.com)

Arq. Neuro-Psiquiatr. 2024;82(8):s00441787763.

An 88-year-old diabetic man, with end-stage chronic kidney disease, on dialysis, presented with nausea and diarrhea for 2 days. After this period, the patient's family sought emergency care due to a significant and acute reduction in movement, dysphonia, and dysphagia. His physical examina-

tion was consistent with akinetic-rigid parkinsonian syndrome. A brain magnetic resonance imaging scan was performed, and the lentiform fork sign was identified (→ **Figure 1**), which, associated with metabolic acidosis, corroborated the diagnosis of uremic striatopallidal syndrome.



**Figure 1** Head computed tomography (CT) scan showing symmetrical hypodensity in the lentiform nuclei bilaterally (A). Brain magnetic resonance imaging (MRI) scan in fluid-attenuated inversion recovery (FLAIR) (B) and T2-weighted (C) sequences demonstrating hyperintensity in the lentiform nuclei bilaterally. The white arrows show T2 and FLAIR hyperintensity in the white matter surrounding the lentiform, representing edema in the internal and external capsules. This finding forms the basis of the fork of the “lentiform fork sign”. Facilitated diffusion can be seen on the diffusion-weighted imaging (DWI) (D) and apparent diffusion coefficient (ADC) (E) sequences. Illustrative representation of a fork (F).

received  
February 28, 2024  
received in its final form  
March 29, 2024  
accepted  
April 6, 2024

DOI <https://doi.org/10.1055/s-0044-1787763>.  
ISSN 0004-282X

Editor-in-Chief: Hélio A. G. Teive.  
Associate Editor: Leandro Lucato.

© 2024. The Author(s).

This is an open access article published by Thieme under the terms of the Creative Commons Attribution 4.0 International License, permitting copying and reproduction so long as the original work is given appropriate credit (<https://creativecommons.org/licenses/by/4.0/>).  
Thieme Revinter Publicações Ltda., Rua do Matoso 170, Rio de Janeiro, RJ, CEP 20270-135, Brazil

Uremic striatopallidal syndrome is a rare cerebral complication of metabolic acidosis. It may present in the form of chorea or, more commonly, acute parkinsonism.<sup>1</sup>

#### Authors' Contributions

TAPG, PJT: writing and review of the manuscript. All authors approved the final version of the manuscript and agree to be responsible for all aspects of the work.

#### Conflict of Interest

The authors have no conflict of interest to declare.

#### Acknowledgments

Pedro José Tomaselli is supported by a strategic award from the medical research council (MRC) to establish an International Center for Genomic Medicine in Neuromuscular Diseases (ICGNMD) MR/S005021/1.

#### Reference

- 1 Bhowmick SS, Lang AE. Movement Disorders and Renal Diseases. *Mov Disord Clin Pract (Hoboken)* 2020;7(07):763–779. Doi: 10.1002/mdc3.13005 PMID: 33043074; PMCID: PMC7534014