



Rett syndrome due to mutation in the *MECP2* gene and electroencephalographic findings

Síndrome de Rett devido a mutação no gene MECP2 e achados eletroencefalográficos

Marta Rodrigues de Carvalho¹ Thiago Toscano Cavalcante¹ Pedro Sudbrack Oliveira¹
Pedro Vicente Ferreira Naves¹ Paulo Emidio Lobão Cunha¹

¹ Universidade de Brasília, Hospital Universitário de Brasília (HUB), Setor de Neurofisiologia Clínica, Brasília DF, Brazil.

Address for correspondence Marta Rodrigues de Carvalho (email: marta_rodrigues12@hotmail.com).

Arq. Neuro-Psiquiatr. 2024;82(8):s00441787801.

A 6-year-old girl with *MECP2*-positive Rett syndrome presented for investigation of seizures. The electroencephalogram (EEG) showed markedly disorganized cerebral activity, epileptiform paroxysms and a quasiperiodic pattern, followed by attenuation after paroxysmal activity (► **Figures 1** and **2**). In *MECP2*-positive patients, there is a progression of EEG findings in stages. First, seizures are not a prominent feature, and the EEG may be normal. Second, focal spikes may be observed, especially in the centrotemporal regions. Third, there is an accentuation of epileptiform activity, abnormalities during sleep, and the presence of bilaterally synchronous discharges of pseudoperiodic delta activity and generalized rhythmic spike discharges. Fourth, there are theta waves in the central and frontal regions, multifocal epileptiform activity in the waking state, and generalized slow spike and wave activity during sleep.^{1,2}

Authors' Contributions

MRC: conceptualization and design of the work, data acquisition, analysis, and interpretation, and writing of

the manuscript; TTC: data acquisition and writing of the manuscript; PSO, PVFC: analysis and interpretation of data, review of the manuscript; PELC: analysis and interpretation of data, and writing and review of the manuscript. All authors have approved the final version of the manuscript and agreed to be responsible for all aspects of the work.

Conflict of Interest

The authors have no conflict of interest to declare.

References

- Operto FF, Mazza R, Pastorino GMG, Verrotti A, Coppola G. Epilepsy and genetic in Rett syndrome: A review. *Brain Behav* 2019;9(05):e01250. Doi: 10.1002/brb3.1250
- Spagnoli C, Fusco C, Pisani F. Rett Syndrome Spectrum in Monogenic Developmental-Epileptic Encephalopathies and Epilepsies: A Review. *Genes (Basel)* 2021;12(08):1157. Doi: 10.3390/genes12081157

received
February 3, 2024
accepted
April 6, 2024

DOI <https://doi.org/10.1055/s-0044-1787801>.
ISSN 0004-282X.

Editor-in-Chief: Hélio A. G. Teive
Associate Editor: Luciano de Paola.

© 2024. The Author(s).

This is an open access article published by Thieme under the terms of the Creative Commons Attribution 4.0 International License, permitting copying and reproduction so long as the original work is given appropriate credit (<https://creativecommons.org/licenses/by/4.0/>).

Thieme Revinter Publicações Ltda., Rua do Matoso 170, Rio de Janeiro, RJ, CEP 20270-135, Brazil

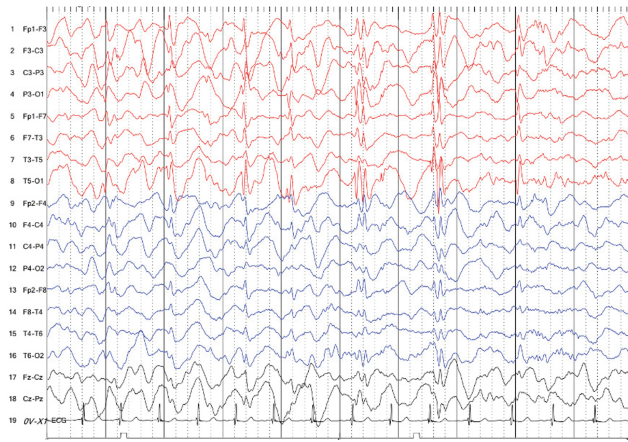


Figure 1 Bipolar longitudinal. Source: Image collection of the Clinical Neurophysiology Sector of Hospital Universitário de Brasília. (Sensitivity: 10 μ V; High filter: 70 Hz; Low filter: 1 Hz).

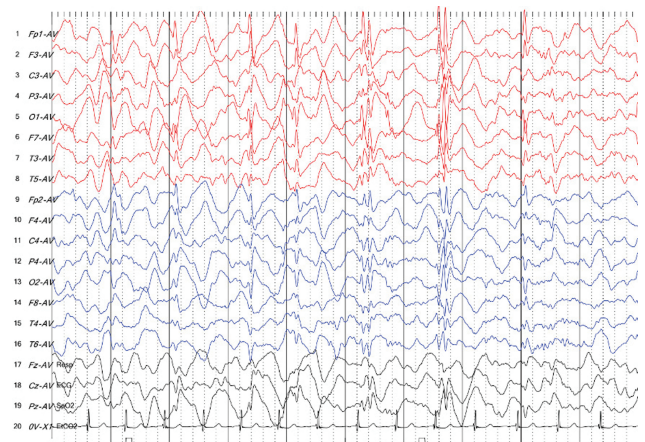


Figure 2 Average referential. Source: Image collection of the Clinical Neurophysiology Sector of Hospital Universitário de Brasília. (Sensitivity: 10 μ V; High filter: 70 Hz; Low filter: 1 Hz).

Appendix A

Quiz

1. What is the main gene involved in typical cases of Rett syndrome?

- a) *CDKL5*
- b) *FOXP1*
- c) *MECP2*
- d) *SCNA1*

answer: c

2. In a patient with Rett syndrome due to a mutation in the *MECP2* gene, in how many stages does the progression of electroencephalographic findings occur?

- a) 3
- b) 4
- c) 5
- d) 6

answer: b

3. A patient with Rett syndrome due to a mutation in the *MECP2* gene who presents a pattern of pseudoperiodic discharges on the electroencephalogram can be classified into which stage?

- a) 3
- b) 4
- c) 5
- d) 6

answer: a