




Evaluating Hyperbaric Oxygen Therapy to Improve Single-Stage Dermal Substitute and Skin Grafting: A Comparative Study

Pradeoth Mukundan Korambayil¹ Hemang Arvind Sanghvi¹ Vinoth Kumar Dilliraj²
Prashanth Varkey Ambookan¹

¹Department of Plastic Surgery and Burns, Jubilee Mission Medical College and Research Institute, Thrissur, Kerala, India

²Department of Plastic Surgery, Vijaya Hospital, Chennai, Tamil Nadu, India

Address for correspondence Pradeoth Mukundan Korambayil, MBBS, MS, MCh, Department of Plastic Surgery and Burns, Jubilee Mission Medical College and Research Institute, Thrissur 680005, Kerala, India (e-mail: pradeoth@gmail.com).

Indian J Plast Surg

Abstract

Background Dermal substitutes offer a valuable tool in soft-tissue reconstruction, reducing the need for donor site tissue and its associated complications. However, conventional approaches often require multiple surgeries. This study aimed to compare the effectiveness of a single-stage procedure combining dermal substitute and skin grafting with hyperbaric oxygen (HBO) therapy to the standard multistage protocol.

Materials and Methods A comparative study was conducted from January 2022 to December 2023. The medical records of 24 patients who underwent soft-tissue reconstruction were reviewed. Patients were categorized into two groups based on whether they received HBO therapy (HBO group) or followed the standard multistage protocol (control group). Outcomes were compared between the groups.

Results The study included 18 males and 6 females with an average age of 43 years (range: 5–91 years). Underlying medical conditions included diabetes mellitus ($n = 11$) and peripheral vascular disease ($n = 2$). Wounds were due to various causes, including necrotizing fasciitis ($n = 2$), trauma ($n = 10$), diabetic ulcers ($n = 6$), postburn hypertrophic scars/contractures ($n = 3$), chronic ulcers ($n = 1$), and sternal wound dehiscence ($n = 1$). All the patients achieved successful wound closure with dermal substitute application, eliminating the need for additional surgery. Notably, the group receiving HBO therapy experienced a shorter overall hospital stay compared with the standard multistage group.

Conclusion This study demonstrates the effectiveness of dermal substitutes in soft-tissue reconstruction. Furthermore, the addition of HBO therapy in a single-stage procedure appears beneficial for successful outcomes, potentially reducing hospital stay compared with the traditional multistage approach.

Keywords

- ▶ hyperbaric oxygen therapy
- ▶ dermal substitute
- ▶ soft-tissue defect
- ▶ skin grafting

DOI <https://doi.org/10.1055/s-0044-1788592>.
ISSN 0970-0358.

© 2024. Association of Plastic Surgeons of India. All rights reserved. This is an open access article published by Thieme under the terms of the Creative Commons Attribution-NonDerivative-NonCommercial-License, permitting copying and reproduction so long as the original work is given appropriate credit. Contents may not be used for commercial purposes, or adapted, remixed, transformed or built upon. (<https://creativecommons.org/licenses/by-nc-nd/4.0/>)
Thieme Medical and Scientific Publishers Pvt. Ltd., A-12, 2nd Floor, Sector 2, Noida-201301 UP, India

Introduction

Full-thickness skin defects often require split-thickness skin grafting (STSG) for reconstruction. However, STSG alone can lead to significant complications, such as contractures limiting movement and hypertrophic scar formation.¹ To address these limitations, dermal substitutes are increasingly used in conjunction with STSG to provide additional support and durability to the reconstructed tissue.² However, traditional approaches with dermal substitutes involve a multistage process: initial wound debridement and dermal substitute application, followed by a separate stage for STSG, typically separated by a week.²

Hyperbaric oxygen (HBO) therapy offers a promising alternative by delivering 100% oxygen to the wound bed. This increased oxygenation promotes new blood vessel formation (neovascularization) and enhances oxygen diffusion, ultimately accelerating wound healing.³ This study investigates the potential of HBO therapy to expedite the treatment of soft-tissue defects by enabling a single-stage procedure combining dermal substitute application and STSG. By leveraging the enhanced wound healing properties of HBO, this approach aims to reduce overall treatment time and improve patient outcomes by minimizing surgical interventions and promoting functional wound closure.

Materials and Methods

Study Design

This single-center, comparative study investigated the efficacy of HBO therapy in expediting soft-tissue reconstruction with dermal substitute and skin grafting. The study was retrospective, conducted between January 2022 and December 2023, and received ethical approval from the institutional review board.

Participants: The medical records of 24 patients who underwent soft-tissue reconstruction were reviewed. Patients were categorized into two groups based on whether they received HBO therapy (HBO group) or followed the standard multistage protocol (control group). Demographic and baseline clinical data were collected for all participants.

Interventions

Single-stage group with HBO: Patients in this group underwent a single-stage surgical procedure combining wound debridement, dermal substitute application, skin grafting, and negative pressure wound therapy (NPWT). Following surgery, patients received a regimen of HBO therapy in a monoplace chamber. The hyperbaric session was started on postoperative day 1. The sessions were continued from postoperative day 1 to 7. The standard protocol consisted of six daily sessions, each lasting 90 minutes. The chamber was pressurized to 2.4 atmospheres (ATM) of pressure.

Control group (standard multistage protocol): Patients in this group followed the traditional approach involving separate stages. Stage 1 consisted of wound debridement, dermal substitute application, and NPWT followed by a 1-week interval. Stage 2 involved STSG and NPWT.

Exclusion Criteria

Patients with the following conditions were excluded from the HBO group: inability to follow instructions during treatment, history of barotrauma (pressure injury), presence of ear implants incompatible with HBO, implanted cardiac pacemakers, and pregnancy.

MatriDerm (Skin and Health Care AG, Billerbeck, Germany) served as the dermal substitute in this case. This material is a structurally intact scaffold composed of bovine type I collagen and elastin, specifically designed to promote dermal regeneration. MatriDerm should be meticulously trimmed to precisely match the dimensions of the wound. Using gloved hands, gently place the matrix onto the wound bed, ensuring complete contact across the entire wound surface. Carefully smooth the edges of the matrix to eliminate any air bubbles trapped between the wound bed and promoting optimal adhesion. The skin graft was placed over the MatriDerm and secured to the wound bed. For 1 week following surgery, NPWT was applied to further support healing.⁴

NPWT procedure: The wound or defect is filled with specifically designed foam or open-celled gauze. A drainage tube with perforations along its side is placed within the foam. The foam and surrounding skin are covered with a transparent, airtight dressing. The drainage tube is connected to a suction device, such as a vacuum bottle, which generates negative pressure within the foam. This draws out necrotic tissue and fluid (exudate) from the wound.

Outcomes

Data on various outcomes were collected and compared between the two groups. These outcomes may include the following: wound healing rate, time to complete wound closure, length of hospital stay, and incidence of complications (e.g., infection, graft failure). Statistical analysis will be performed to compare outcomes between the HBO and control groups. We performed a chi-squared test to assess the differences in the proportions of patients experiencing successful reconstruction between the HBO and control groups.

Results

A total of 24 patients, comprising 18 males and 6 females, participated in the study (► **Tables 1** and **2**). The mean age was 43 years (range: 5–91 years). Underlying medical conditions included diabetes mellitus ($n=11$) and peripheral vascular disease ($n=2$). The causes of soft-tissue defects were diverse, encompassing necrotizing fasciitis ($n=2$), trauma ($n=10$), diabetic ulcers ($n=6$), postburn hypertrophic scars/contractures ($n=3$), chronic ulcers ($n=1$), and sternal wound dehiscence ($n=1$). Importantly, all patients in both the single-stage HBO group and the standard multistage control group achieved successful wound closure with the use of dermal substitutes. This eliminated the need for additional surgical procedures. One key finding was a difference in hospital stay duration between the groups. Patients receiving HBO therapy in the single-stage group experienced

Table 1 Patients underwent soft-tissue cover with dermal matrix without hyperbaric oxygen therapy

Sl. no.	Name	Age (y)	Sex	Comorbidity	Diagnosis	Procedure	Duration for soft-tissue cover in the desired area (wk)
1	V	55	M	Diabetic	Necrotizing fasciitis of the right lower limb with exposed tendon at the lateral aspect knee	Multiple Wound debridement + NPWT + MatriDerm + SSG	4
2	L	60	F	Diabetic	Nonhealing ulcer heel following failed reverse sural artery flap	Wound debridement + NPWT MatriDerm + SSG	4–5
3	M	5	M	Nil	Traumatic injury to dorsum with the first metatarsal joint exposed	WD + NPWT + MatriDerm + SSG	4
4	A	45	M	Nil	Traumatic injury to the dorsum of the foot with the second and third metatarsophalangeal joint exposed	WD + multiple NPWT + MatriDerm + SSG	5
5	N	40	M	Diabetic	Necrotizing fasciitis of the right upper limb with the dorsum tendon exposed	WD + NPWT + MatriDerm + SSG	4–5
6	T	39	M	Nil	Right foot injury with exposed tendon	Wd + NPWT + MatriDerm + SSG	4
7	R	48	M	Nil	Right foot medial planter injury with exposed tendon	Wd + NPWT + MatriDerm + SSG	4
8	A	22	F	Nil	Posttraumatic right hip keloid scar	Excision + NPWT + MatriDerm + SSG	3
9	By	48	M	Diabetic	Ulcer in the heel pad region	Debridement + NPWT + MatriDerm + SSG	3
10	S	35	M	Chronic ulcer	Long-standing ulcer on the right lateral leg ankle region	Debridement + NPWT + MatriDerm + SSG	4
11	T	56	M	Nil	Posttraumatic soft-tissue defect in the tendoachilles region	Debridement+ NPWT + MatriDerm + SSG	3
12	D	63	M	Diabetic	Infected ulcer in the right ankle region with talus bone exposure	Debridement+ NPWT + MatriDerm + SSG	3

Abbreviations: NPWT, negative pressure wound therapy; SSG, split-thickness skin grafting.

a notably shorter overall hospital stay compared with those undergoing the traditional multistage protocol. Our chi-squared test analysis found a statistically significant association ($p < 0.05$) between the HBO therapy and hospital stay categories, suggesting that patients with HBO therapy may have different lengths of stay in the hospital compared with those without HBO therapy sessions.

Cases

Case 1: Without Hyperbaric Oxygen

A 35-year-old man presented with chronic and recurrent ulcers on the lateral aspect of his right ankle and foot. These

ulcers stemmed from a road traffic accident 15 years prior. Despite undergoing multiple soft-tissue reconstruction procedures, the wounds persisted (→Fig. 1a). To address this persistent issue, the patient underwent surgical debridement of the unhealthy tissue followed by NPWT to promote a healthy wound bed. Once the wound showed signs of healing, a dermal substitute was applied (→Fig. 1b), followed by skin grafting using tissue harvested from the patient's right thigh (→Fig. 1c). Following skin graft placement, NPWT was continued for 1 week. The postoperative course was uneventful, with complete engraftment of the skin graft. A follow-up examination at 9 months postsurgery revealed adequate soft-tissue stability and closure of the chronic ulcers (→Fig. 1d).

Table 2 Patients underwent soft-tissue cover with dermal matrix with hyperbaric oxygen therapy

Sl. no.	Name	Age (y)	Sex	Comorbidity	Diagnosis	Procedure	Duration for soft-tissue cover in desired area (wk)
1	R	91	M	Diabetic	Posttraumatic defect the dorsum of the hand	Debridement + MatriDerm + SSG + HBO + NPWT	2
2	P	23	M	Nil	Posttraumatic dorsum defect	Debridement + MatriDerm + SSG + HBO + NPWT	2
3	A	27	M	Nil	Posttraumatic dorsum defect	Debridement + MatriDerm + SSG + HBO + NPWT	2
4	T	25	M	Diabetic	Soft-tissue loss: left foot sole region	Debridement + MatriDerm + SSG + HBO + NPWT	2
5	G	73	F	Diabetic with PVD	Diabetic ulcer foot and tendoachilles region	Debridement + MatriDerm + SSG + HBO + NPWT	2
6	Gs	43	M	Nil	Posttraumatic soft-tissue defect popliteal region	Debridement + MatriDerm + SSG + HBO + NPWT	2
7	L	43	M	Diabetic	Long-standing ulcer in the right leg lower-third region	Debridement + MatriDerm + SSG + HBO + NPWT	1
8	F	53	F	Nil	Postburn contracture in the left side of the neck region	Contracture release + MatriDerm + SSG + HBO + NPWT	1
9	C	23	F	Nil	Postburn contracture in the left axilla, forearm, neck and chin, and presternal region	Contracture release + MatriDerm + SSG + HBO + NPWT	1
10	P	63	M	Diabetic with PVD	Diabetic ulcer tendoachilles region	Debridement + MatriDerm + SSG + HBO + NPWT	2
11	ST	72	F	Diabetic	Postsurgical dehiscence presternal wound	Debridement + MatriDerm + SSG + HBO + NPWT	2
12	V	37	M	Nil	Posttraumatic degloving injury in the right foot and the tendoachilles region	Debridement + MatriDerm + SSG + HBO + NPWT	3

Abbreviations: HBO, hyperbaric oxygen therapy; NPWT, negative pressure wound therapy; PVD, peripheral vascular disease; SSG, split-thickness skin grafting.

Case 2: Without Hyperbaric Oxygen

A 22-year-old woman presented with a keloid scar on her right groin region extending to the lateral abdomen (► Fig. 2a). To address this problem, the keloid was surgically excised (► Fig. 2b). Reconstruction involved the placement of a dermal matrix (► Fig. 2c). Following the application of the dermal matrix, NPWT was applied for 1 week to optimize wound healing. Subsequently, skin grafting was performed using tissue harvested from the patient's right thigh. The grafted area was then dressed with NPWT for another week. The postoperative course was uneventful, with good wound healing and successful skin graft integration (► Fig. 2d).

Case 3: With Hyperbaric Oxygen

A 91-year-old male patient presented to the plastic surgery department following an injury to the dorsum of his right hand, initially managed by the orthopaedic team. Examination revealed a significant soft-tissue defect on the hand's dorsum, approximately 5 × 4 × 3 cm in size, exposing the extensor tendons (► Fig. 3a). To address this complex wound, a single-stage surgical approach was undertaken. The wound was thoroughly debrided of unhealthy tissue. This was followed by immediate coverage with a dermal substitute and skin grafting (► Fig. 3b, c). Skin graft was harvested from the medial aspect of the right arm. To optimize healing,

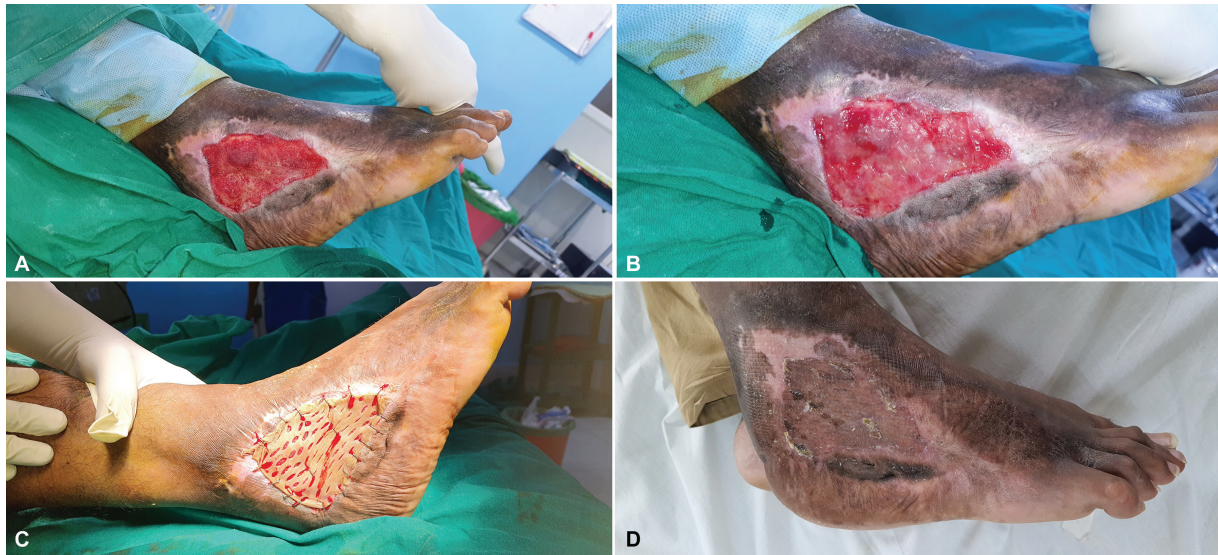

Fig. 1 (A) Recurrent chronic ulcer in the lateral aspect of the right ankle region. (B) Soft-tissue defect covered with dermal matrix. (C) Soft-tissue defect covered with skin graft following dermal matrix application after 1 week. (D) Late postoperative picture showing adequate healing and durable skin grafted site.

NPWT was applied postoperatively. Additionally, the patient received a series of six HBO therapy sessions to further enhance wound healing. The patient's postoperative course

was uneventful, and the wounds healed successfully (►Fig. 3d).

Case 4: Hyperbaric Oxygen

A 27-year-old man presented to the plastic surgery department after sustaining an injury to the dorsum of his right foot. The orthopaedic team initially managed the injury with wound debridement, sutured the avulsed skin, and stabilized a fracture in the second toe with a K-wire (►Fig. 4a). Unfortunately, the dorsal skin on the foot did not survive, and further debridement was necessary, exposing the medial aspect of the joint between the second toe and its metatarsal bone (►Fig. 4b). To reconstruct the soft-tissue defect, a single-stage surgical approach was employed. The exposed area was covered with a dermal substitute followed by skin grafting (►Fig. 4c, d). The skin graft was harvested from the medial aspect of the patient's right thigh. To promote optimal healing, NPWT was applied postoperatively. Additionally, the patient underwent six HBO therapy sessions to further enhance wound healing. The patient's postoperative course was uneventful, and the wounds healed successfully (►Fig. 4e).

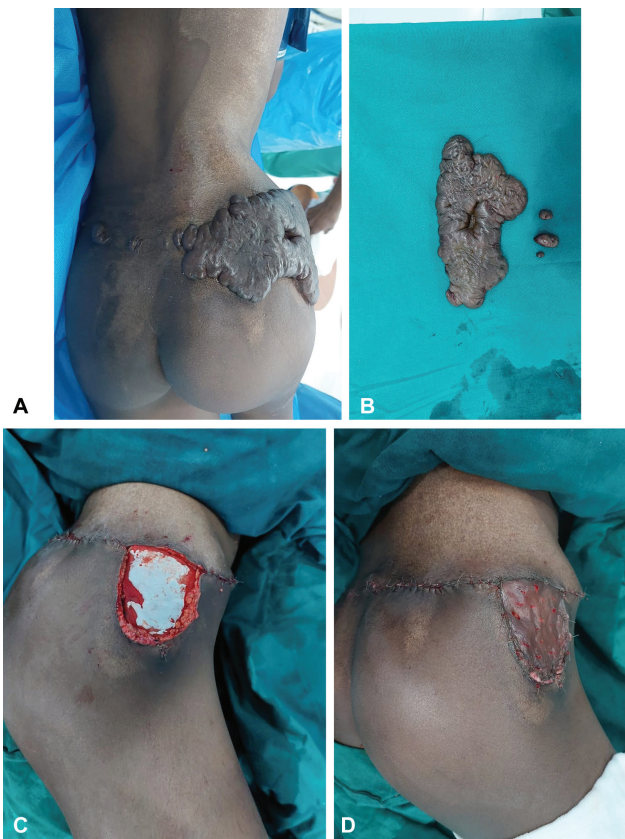


Fig. 2 (A) Postburn keloid scar in the right groin region. (B) Excised keloid tissue. (C) Soft-tissue defect covered with dermal matrix. (D) Late postoperative picture showing adequate healing and durable skin grafted site.

Discussion

Traditional wound reconstruction for soft-tissue defects often involves STSG. However, this technique, particularly when using grafts with minimal dermal components, can lead to increased contracture, limiting movement and potentially causing hypertrophic scar formation.¹ Although full-thickness skin grafts offer advantages in reducing contracture, their use is limited in larger wounds due to donor site restrictions.

Dermal substitutes offer a promising solution by integrating with split-thickness skin grafts and thereby provide additional support and durability to the reconstructed tissue. Dermal substitutes are a valuable tool for soft-tissue

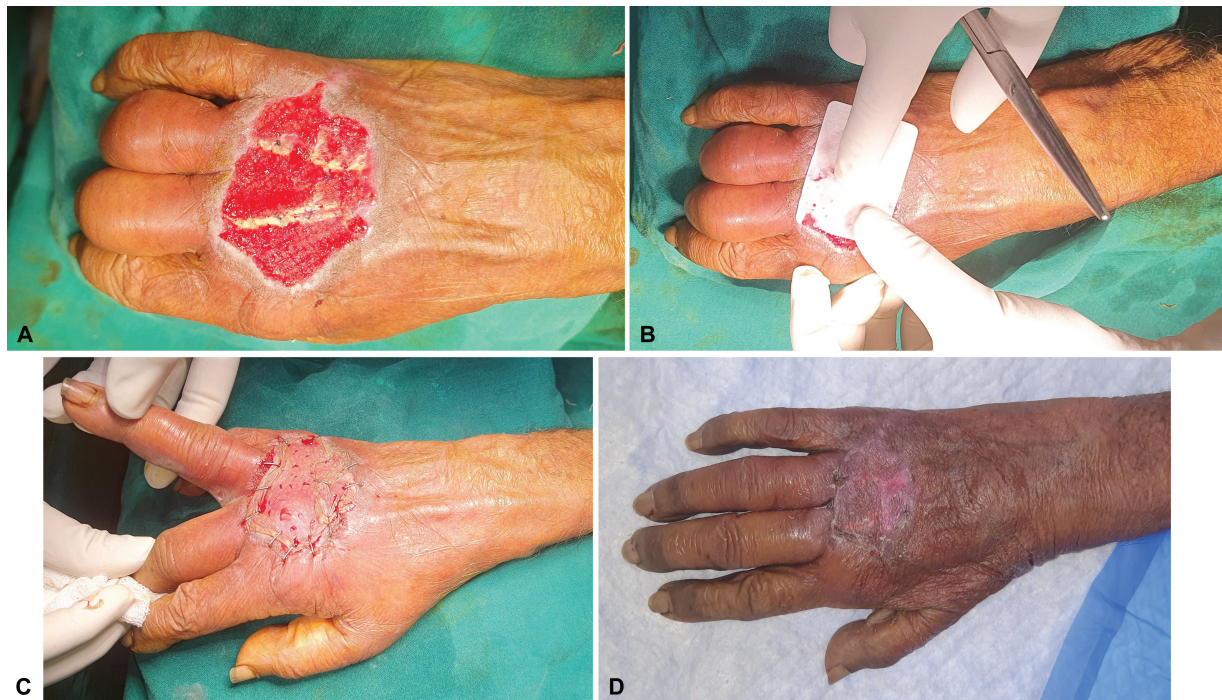

Fig. 3 (A) Soft-tissue defect exposing the extensor tendon: dorsum of the right hand. (B) Soft-tissue defect covered with dermal matrix. (C) Soft-tissue defect with dermal matrix covered with skin graft. (D) Late postoperative picture showing adequate healing and durable skin grafted site.

reconstruction, promoting regeneration in deep burns, chronic wounds, and full-thickness defects. Dermal matrix act as a scaffold, encouraging cell growth and neovascularization.⁵ As the healing process progresses, the fibroblasts deposit new extracellular matrix, and the dermal substitute gradually resorbs. Studies have shown that various dermal substitutes have comparable engraftment and vascularization rates.⁶ Notably, dermal matrix offers a distinct advantage as it allows for immediate STSG without compromising graft success.⁷ Traditionally, dermal substitute placement involves a staged surgical approach. In stage 1, the wound is debrided, the dermal substitute is applied, and NPWT is used. Then, after a 1-week interval, stage 2 involves skin grafting with continued NPWT.

In our study, patients were assigned to either a single-stage group receiving HBO therapy or a control group following the standard multistage protocol. HBO therapy served as an adjunct treatment to promote wound healing. This therapy delivers 100% oxygen to the wound bed, enhancing neovascularization and facilitating oxygen diffusion for accelerated healing.⁸ HBO therapy also increases the oxygen-carrying capacity of plasma while reducing localized edema. This combination can decrease tissue pressure and improve microvascular blood flow.⁹ Our study leveraged these properties of HBO therapy to potentially reduce treatment time for soft-tissue reconstruction using dermal substitutes and skin grafts. We observed favorable outcomes in the HBO group compared with the control group. Notably, no complications associated with HBO therapy were identified in our study. We did not find any incidence of graft failure or infection in both the groups. However, a longer follow-up period is necessary to evaluate long-term results following

the procedure. Our analysis could be further stratified by subvariables to potentially reduce bias. This could involve categorizing patients into groups based on whether they received HBO therapy within both the single-stage and multistage protocols (single-stage with HBO vs. single-stage without HBO; multistage with HBO vs. multistage without HBO). However, directly comparing a single-stage HBO group to a multistage non-HBO group would likely introduce selection bias, as these groups were not formed based on random assignment.

Previous research by Ülkür et al suggests that HBO therapy during the flap delay period can shorten the delay time and enhance its effectiveness.¹⁰ This approach of reducing the delay period could potentially be applied to this study's context to shorten the time needed for neovascularization and accelerate wound healing in dermal substitute and skin graft reconstruction. Additionally, HBO therapy offers the benefit of promoting healing in both the recipient site and the donor site. Furthermore, our findings suggest that administering HBO therapy during the integration period of the skin graft and dermal substitute appears to be safe and potentially beneficial. It may reduce postoperative edema and contribute to a more optimal outcome following tissue transfer.

At our center, HBO therapy is delivered in a monoplace chamber. The standard protocol consisted of six daily sessions, each lasting 90 minutes. The chamber was pressurized to 2.4 ATM of pressure. This single-person chamber allows for pressurization with 100% oxygen. HBO therapy is typically delivered at pressures of 2 or 3 atmospheres absolute (ATA). Individual treatment sessions typically last 60 to 90 minutes. The number of sessions varies depending on the condition being treated. Acute conditions may only require 3 to 5

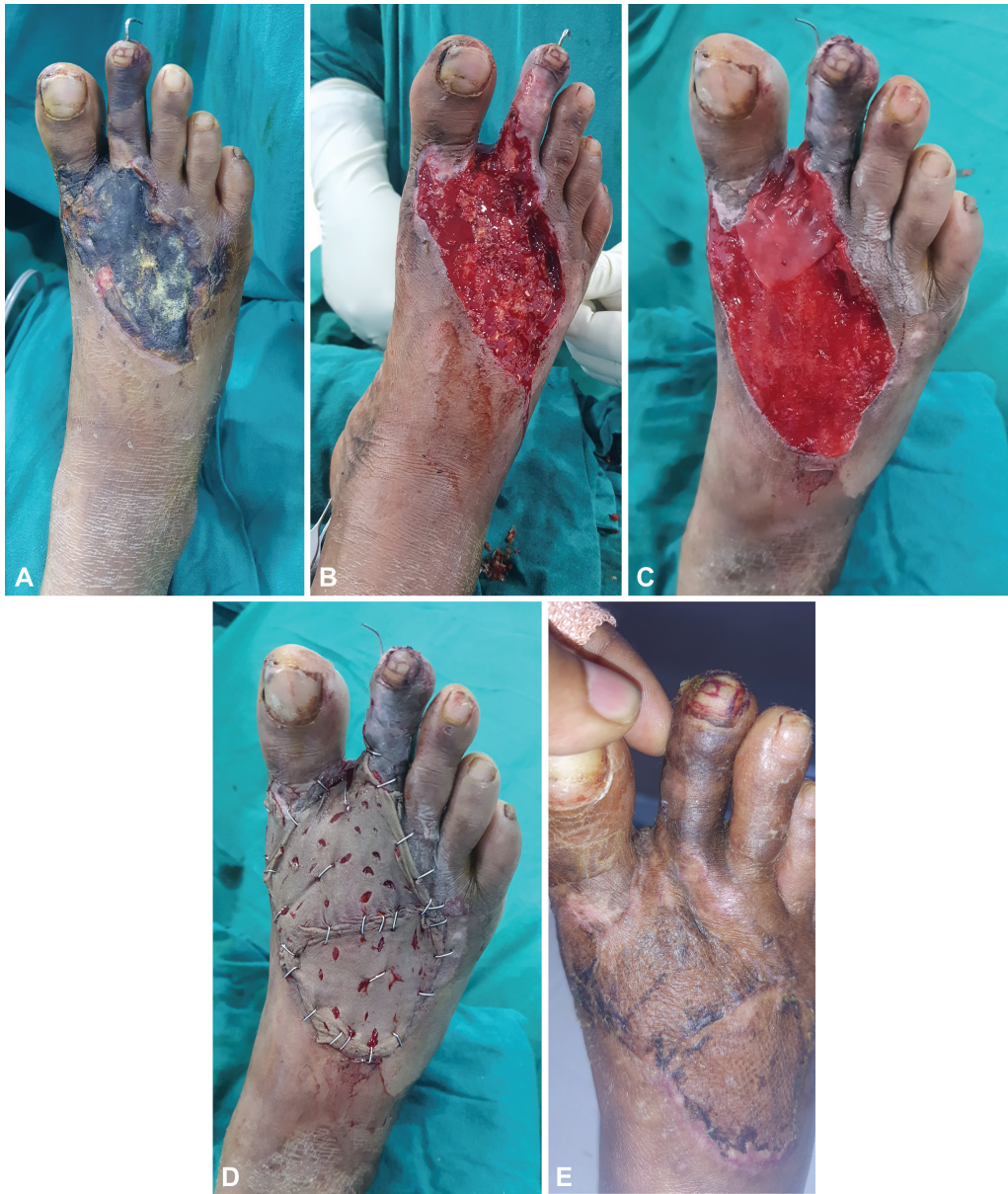

Fig. 4 (A) Necrotic tissue following trauma: right foot dorsum. (B) Soft-tissue defect exposing the extensor tendon and the metatarsophalangeal joint of the second toe: dorsum of the right foot. (C) Soft-tissue defect covered with dermal matrix. (D) Soft-tissue defect with dermal matrix covered with skin graft. (E) Late postoperative picture showing adequate healing and durable skin grafted site.

sessions, while chronic conditions like radiation illness might necessitate 50 to 60 sessions.¹¹⁻¹³ This pressurized environment can promote wound healing in several ways. The increased pressure can cause temporary vasoconstriction, leading to a reduction in swelling and edema around the reconstructed area. This can improve oxygen delivery to the newly grafted tissue with the dermal substitute. Hyperoxygenation within the chamber may stimulate the immune system by improving white blood cell function and their ability to respond to infection by effective phagocytosis.¹³ Additionally, it can promote neovascularization in areas with low oxygen levels by stimulating fibroblast activity and capillary growth.¹⁴ These factors can contribute to a more optimal integration of the dermal substitute and skin graft. Our study's findings suggest that HBO therapy allows for a

single-stage surgical approach, combining wound debridement, dermal substitute application, and skin grafting. This potentially reduces the overall treatment burden and morbidity for patients and promotes functional wound healing.

Conclusion

Our findings suggest that HBO therapy can be a valuable adjunct to single-stage reconstruction of soft-tissue defects using dermal substitutes and skin grafts. This approach has the potential to improve patient outcomes by reducing the number of surgical procedures and promoting faster wound healing. Future research should explore the optimal application of this technique. This could include investigating the efficacy of HBO therapy with different thicknesses of dermal

matrix to determine if specific combinations provide the most benefit in terms of wound healing rates, functional outcomes, and long-term scar formation.

Funding

None.

Conflict of Interest

None declared.

References

- 1 Soejima K, Nozaki M, Sasaki K, Takeuchi M, Negishi N. Reconstruction of burn deformity using artificial dermis combined with thin split-skin grafting. *Burns* 1997;23(06):501–504
- 2 Oh SJ, Kim Y. Combined AlloDerm® and thin skin grafting for the treatment of postburn dyspigmented scar contracture of the upper extremity. *J Plast Reconstr Aesthet Surg* 2011;64(02):229–233
- 3 Duzgun AP, Satir HZ, Ozozan O, Saylam B, Kulah B, Coskun F. Effect of hyperbaric oxygen therapy on healing of diabetic foot ulcers. *J Foot Ankle Surg* 2008;47(06):515–519
- 4 Halim AS, Khoo TL, Mohd Yussof SJ. Biologic and synthetic skin substitutes: an overview. *Indian J Plast Surg* 2010;43(1, Suppl): S23–S28
- 5 Ryssel H, Gazyakan E, Germann G, Ohlbauer M. The use of MatriDerm in early excision and simultaneous autologous skin grafting in burns: a pilot study. *Burns* 2008;34(01):93–97
- 6 Schneider J, Biedermann T, Widmer D, et al. Matriderm versus Integra: a comparative experimental study. *Burns* 2009;35(01): 51–57
- 7 Kolokythas P, Aust MC, Vogt PM, Paulsen F. Dermal substitute with the collagen-elastin matrix Matriderm in burn injuries: a comprehensive review. *Handchir Mikrochir Plast Chir* 2008;40(06): 367–371
- 8 Sen S, Sen S. Therapeutic effects of hyperbaric oxygen: integrated review. *Med Gas Res* 2021;11(01):30–33
- 9 Phillips JC. Understanding hyperbaric oxygen therapy and its use in the treatment of compromised skin grafts and flaps. *Plast Surg Nurs* 2005;25(02):72–80, quiz 81–82
- 10 Ülkür E, Karagoz H, Ergun O, Celikoz B, Yildiz S, Yildirim S. The effect of hyperbaric oxygen therapy on the delay procedure. *Plast Reconstr Surg* 2007;119(01):86–94
- 11 Bhutani S, Vishwanath G. Hyperbaric oxygen and wound healing. *Indian J Plast Surg* 2012;45(02):316–324
- 12 Oley MH, Oley MC, Aling DMR, et al. Effects of hyperbaric oxygen therapy on the healing of thermal burns and its relationship with ICAM-1: a case-control study. *Ann Med Surg (Lond)* 2020; 61:104–109
- 13 Niezgodna JAMD, Cianci P, Folden BWRN, Ortega RLRN, Slade JB, Storrow ABMD. The effect of hyperbaric oxygen therapy on a burn wound model in human volunteers. *Plast Reconstr Surg* 1997;99 (06):1620–1625
- 14 Francis A, Baynosa RC. Hyperbaric oxygen therapy for the compromised graft or flap. *Adv Wound Care (New Rochelle)* 2017;6 (01):23–32